

visual and auditory effects. We also thank Drs S F Damluji, L Magos, and D O Marsh for reading and criticising this paper.

The University of Rochester was supported in part by a National Science Foundation (Research Applied to National Needs) Grant GI-300978, a Centre Grant (ES-01247), and a Programme Project Grant (ES-01248) from the National Institute of Environmental Health Sciences.

## References

- <sup>1</sup> Kurland, L T, in *Mercury, Mercurials, and Mercaptans*, ed M W Miller and T W Clarkson. Springfield, Illinois, Charles C Thomas, 1973.
- <sup>2</sup> Hunter, D, Bamford, R R, and Russell, D S, *Quarterly Journal of Medicine*, 1940, **33**, 193.
- <sup>3</sup> Hunter, D, and Russell, D S, *Journal of Neurology, Neurosurgery, and Psychiatry*, 1954, **17**, 235.
- <sup>4</sup> McAlpine, D, and Araki, S, *Lancet*, 1958, **2**, 629.
- <sup>5</sup> McAlpine, D, and Araki, S, *American Medical Association Archives of Neurology*, 1959, **1**, 522.
- <sup>6</sup> Jalili, M A, and Abbasi, A H, *British Journal of Industrial Medicine*, 1961, **18**, 303.
- <sup>7</sup> Damluji, S F, *Journal of the Faculty of Medicine, Baghdad*, 1962, **4**, 83.
- <sup>8</sup> Haq, I U, *British Medical Journal*, 1963, **1**, 1579.
- <sup>9</sup> Bakir, F, *et al*, *Science*, 1973, **181**, 230.
- <sup>10</sup> Magos, L, and Clarkson, T W, *Journal of the Association of Analytical Chemistry*, 1972, **55**, 966.
- <sup>11</sup> Damluji, S F, *The Bulletin of the World Health Organisation*, 1976, **53**, suppl, p 11.
- <sup>12</sup> Miettinen, S K, in *Mercury, Mercurials, and Mercaptans*, ed M W Miller and T W Clarkson. Springfield, Illinois, Charles C Thomas, 1973.
- <sup>13</sup> McCall, R B, *Fundamental Statistics for Psychology*. New York, Harcourt Brace Jovanovich Inc, 1975.
- <sup>14</sup> Nordberg, G F, and Strangert, P, *Effects and Dose Response Relationships of Toxic Metals*. Amsterdam, Elsevier Scientific Publishing Company, 1976.
- <sup>15</sup> Shahrastani, H, and Shihab, K M, *Archives of Environmental Health*, 1974, **28**, 342.
- <sup>16</sup> Kurland, L T, Faro, S N, and Siedler, H, *World Neurology*, 1960, **1**, 370.
- <sup>17</sup> Tshchiya, K, *Keio Journal of Medicine*, 1969, **18**, 213.
- <sup>18</sup> *British Medical Journal*, 1972, **2**, 605.
- <sup>19</sup> Hill, W H, *Canadian Public Health Journal*, 1943, **34**, 158.
- <sup>20</sup> Brown, I, *American Medical Association's Archives of Neurology and Psychiatry*, 1954, **72**, 674.
- <sup>21</sup> Hay, W J, *et al*, *Journal of Neurology, Neurosurgery, and Psychiatry*, 1963, **26**, 199.
- <sup>22</sup> Harada, Y, *Infantile Minamata Disease: Study Group of Minamata Disease*. Kumamoto University, Japan, 1968.
- <sup>23</sup> Damluji, S F, Amin-Zaki, L, and Elhassani, S B, *British Medical Journal*, 1972, **4**, 489.
- <sup>24</sup> Pierce, P E, *et al*, *Journal of the American Medical Association*, 1972, **220**, 1439.
- <sup>25</sup> Mufti, A W, *et al*, *Bulletin of the World Health Organisation*, 1976, **53**, suppl, p 23.

(Accepted 5 January 1978)

# Lichenoid tattoo hypersensitivity

A TAAFFE, A G KNIGHT, R MARKS

*British Medical Journal*, 1978, **1**, 616-618

## Summary and conclusions

**Four patients are described who developed granulomatous reactions in the red portions of their tattoos. Histopathological and immunofluorescence studies showed features of lichen planus. Mercury was identified in only one patient's lesion, and hypersensitivity to mercury was shown by patch testing in one other patient.**

**Tattooing may provide a localised antigenic challenge resulting in spontaneously occurring lichen planus.**

## Introduction

Tattoos occasionally have intriguing and even disastrous consequences in addition to remorse. Fortunately most complications of tattoos are rare, but of the complications that do occur a granulomatous response in the red portion is the most common. We describe four patients who presented over a six-month period with tattoo granulomata who had the same unusual tissue reaction.

**Department of Dermatology, University Hospital of Wales, Cardiff**  
A TAAFFE, MRCP, MRCP, locum senior registrar (now senior registrar in dermatology, Royal Infirmary, Hull, and General Infirmary, Leeds)  
A G KNIGHT, MD, MRCP, consultant dermatologist

**Department of Medicine, Welsh National School of Medicine, Heath Park, Cardiff CF4 4XN**  
R MARKS, MB, FRCP, reader and consultant in dermatology

## Patients

The main clinical features of the four patients at presentation are shown in the table. The affected areas of all the tattoos were raised up to 0.5 cm above the level of the surrounding skin, were sharply confined to the red areas, and were slightly scaly or crusted in places (see fig 1). Three patients (cases 1, 2, and 4) were tattooed by the same tattooist in Cardiff within a nine-month period in 1976-7. The other patient (case 3) could not remember which tattooist was responsible for which tattoo, but knew that they were all done in Cardiff. The tattooist in cases 1, 2, and 4 was questioned about his technique. Samples of the pigments that he said had been used were obtained for analysis.

## Investigations and results

**Histological findings**—Biopsy specimens of the swollen red portions of all four patients' tattoos were examined histologically and by immunofluorescence. In all cases the histological features were similar. Scattered throughout the dermis were irregular granules and clumps of an amorphous black material that was assumed to be tattoo pigment. Most of the pigment was extracellular and did not seem to be related to the inflammatory cell infiltrate or to the degree of lichenoid change. The inflammatory cell infiltrate was dense and not aggregated around any anatomical structure. Lymphocytes and histiocytes predominated but there were also polymorphonuclear leucocytes and plasma cells. The inflamed areas were oedematous and there were small collections of extravasated red blood cells. The overlying epidermis showed quite striking lichenoid features (fig 2). There was irregular hypertrophy and hyperkeratosis interspersed with areas of epidermal atrophy. The dermoepidermal junction showed the typical "sawtooth" profile of lichen planus in some sites. The normal basal layer of the epidermis was replaced by a patchily vacuolated layer of cells that showed pronounced cytoid-body formation and was infiltrated in places by inflammatory cells. Cytoid bodies were grouped in grape-like clumps below the dermoepidermal junction (fig 3).

**Immunofluorescence**—Cryostat sections were examined by direct immunofluorescence with a Nikon microscope fitted with a

## Clinical features at presentation of four patients with granulomatous reaction to tattooing

Case No	Age (years)	Sex	Site of tattoo	Interval between tattoo and reaction	General health	Previous medical history
1	26	M	Right forearm	3 months	Good	Not relevant
2	27	M	Right forearm	1 month	Good	Not relevant
3	35	M	Right upper arm	Unknown	Chronic alcoholic	Chronic discoid lupus erythematosus since 1974. Extensively investigated for systemic lupus erythematosus with negative results
4	18	M	Right forearm	"A few weeks"	Good	Not relevant

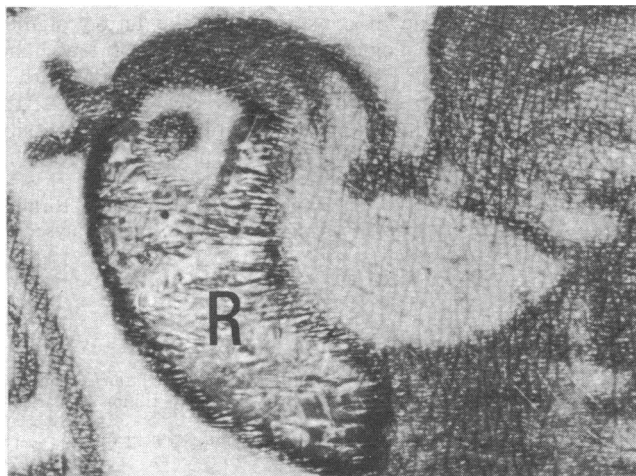
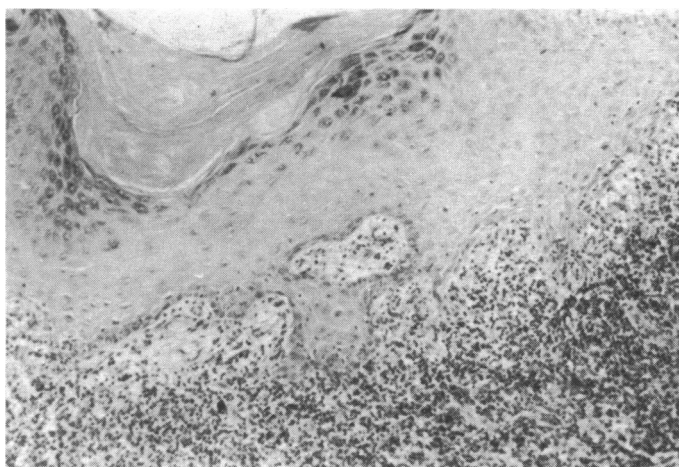


FIG 1—Case 4. Appearance of inflammation in red zone (R) of tattoo.

FIG 2—Case 4. Skin biopsy specimen showing pronounced lichenoid change, with severe degeneration of basal layer and thickening. (H and E.  $\times 80$ .)

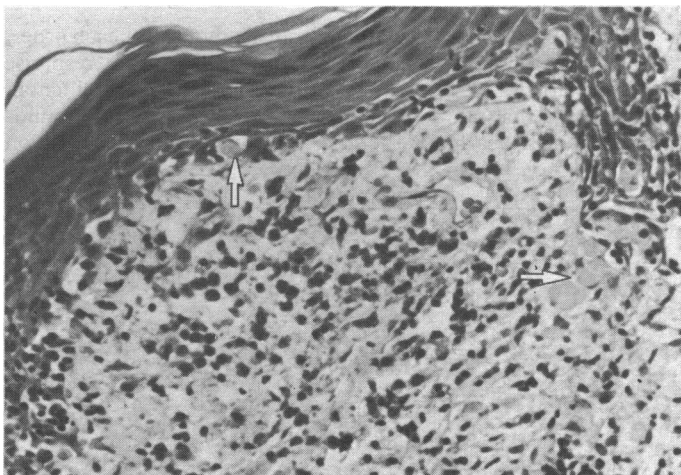
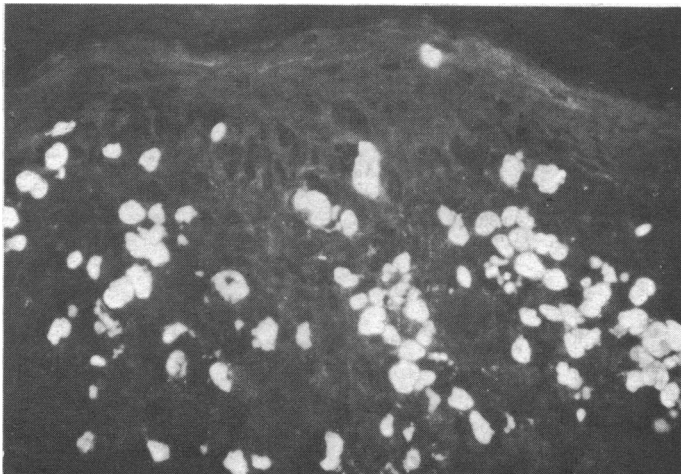
fluorescence attachment according to standard methods.<sup>1</sup> Goat anti-human IgG, IgM, IgA, fibrin, and C3 complement component reagents labelled with fluorescein isothiocyanate were used in dilutions of 1/10-1/30. All biopsy specimens showed globular areas of bright fluorescence due to IgM, IgG, and IgA that corresponded with the cytooid bodies seen on routine light microscopy (fig 4). Linear and globular areas of fluorescence were also shown with the use of the complement reagent. A "shaggy band" of immunofluorescence was seen at the dermoepidermal junction due to fibrin. Specific fluorescence was checked by blocking experiments and by examining control sections of normal skin.

*Patch tests*—All patients had occlusive patch tests as recommended by the International Contact Dermatitis Group with the standard battery of allergens (which includes mercuric chloride 0.1%). The first patient (case 1) was highly sensitive to mercuric chloride and slightly sensitive to azo dyes. The second patient was highly sensitive to azo dyes and slightly sensitive to paraphenylenediamine. The third

patient was highly sensitive to nickel sulphate and slightly sensitive to potassium dichromate. The fourth patient showed no sensitivity.

*Haematological and serological tests*—One patient (case 3) had hypochromic anaemia (haemoglobin 11.2-13.4 g/dl) and a persistently raised erythrocyte sedimentation rate (up to 75 mm in the first hour). Results of all haematological and serological tests were normal in the other three patients.

*Electron-probe microanalysis of tissue sections and pigment*—Paraffin sections of the lesions were deparaffinised in xylene, and cryostat sections were stuck to scanning electron-microscope (SEM) stubs, coated with carbon in an Edwards vacuum-coating unit, and examined in a Cambridge stereoscan SEM fitted with an Edax analysis system. Mercury was specifically sought but was detected in small amounts in granular material in the dermis in the section from only one patient (case 3). Samples of all the pigments supplied were crushed

FIG 3—Case 4. Photomicrograph of biopsy specimen showing cytooid bodies (arrowed) grouped below dermoepidermal junction. (H and E.  $\times 80$ .)FIG 4—Case 2. Skin biopsy specimen showing globular immunofluorescence due to IgG. (H and E.  $\times 80$ .)

into fine powders and stuck to SEM stubs, coated with carbon, and examined in the SEM. The main constituents of the pigments were as follows. Red: sulphur, silicon, aluminium, and chlorine; green: titanium, silicon, and copper; white: titanium, aluminium, zinc, calcium, and silicon; orange: titanium and chlorine.

## Discussion

The development of granulomatous hypersensitivity to a constituent of the red pigment used in tattoos is well documented.<sup>2</sup> Apparently mercuric sulphide is often the agent responsible.<sup>2</sup> Nevertheless, mercury now seems to be an infrequently used tattoo pigment.<sup>3</sup>

We can find no previous report of the dramatic lichenoid response seen in our patients. The resemblance to lichen planus was emphasised by the striking immunofluorescence findings, which included a fibrin band and strongly fluorescent cytooid bodies with most of the reagents tested.<sup>4</sup> Clearly, three of the patients (cases 1, 2, and 4) did not have lichen planus (or lupus erythematosus) as there were no other lesions on the skin or mucosae. The solitary tattoo reaction in case 3 was identical with that in the other three patients clinically, histologically, and on direct immunofluorescence. Nevertheless, this patient had had discoid lupus erythematosus with lichenoid features. His reaction was not merely a local expression of his lupus erythematosus induced by the trauma of tattooing as it was confined to the red portion of one tattoo. The relation between this patient's condition and his odd lichenoid reaction must remain doubtful.

These four patients presented within six months of each other, and the consistent presence of the unusual lichenoid response in all the patients' lesions surely could not have been coincidental. Scutt<sup>3</sup> stated that no more than 10 patients with tattoo granulomata are seen yearly in the United Kingdom. The question

therefore arises whether the tattooist had inadvertently included some other substance in the injected material.

Electron-probe microanalysis showed mercury in the dermis in only one section, but the amount detected was small and could have been a "contaminant." Mercury hypersensitivity on patch testing was found in only one patient (case 1). The red pigment we obtained contained no mercury. The negative patch test results in the other three patients did not necessarily mean that they were not hypersensitive to injected mercury, as their hypersensitivity had been provoked by intracutaneous injection and not epicutaneous challenge.

The lesions of lichen planus may be associated with immune reactions.<sup>5</sup> Possibly in our patients the local antigenic challenge supplied by the unknown constituent of the tattoo pigment induced a local immunological response resulting in true lichen planus. Or perhaps these patients had been inoculated with an infectious agent which caused the local tissue reaction. If this was the case it has intriguing implications for the possible aetiology of spontaneously occurring lichen planus.

We thank Mr Nick Moore, department of crystallography, Birkbeck College, London, for help with the electron-probe microanalyser.

## References

- Beutner, E H, Chorzelski, T P, and Jordan, R E, *Autosensitization in Pemphigus and Bullous Pemphigoid*. Springfield, Illinois, Charles C Thomas, 1970.
- Scutt, R M, and Gotch, C, *Skin Deep: the Mystery of Tattooing*, p 133. London, Peter Davies, 1974.
- Scutt, R M, *British Journal of Hospital Medicine*, 1972, **8**, 194.
- Abell, E, et al, *British Journal of Dermatology*, 1975, **93**, 17.
- Davies, M, et al, *British Journal of Dermatology*, 1977, **96**, 145.

(Accepted 30 December 1977)

# SIDE EFFECTS OF DRUGS

## Incidence of thrombophlebitis with naftidrofuryl

Woodhouse and Eadie<sup>1</sup> recently reported an unusually high incidence of thrombophlebitic complications with intravenous infusions of naftidrofuryl (Praxilene), a drug widely used for treating vascular insufficiency. They described 13 naftidrofuryl infusions (200 mg naftidrofuryl in 200 ml dextrose or common salt solution twice daily) given to seven elderly patients, severe rapidly progressing thrombo-

phlebitis being observed on 10 occasions. Other observers<sup>2, 3</sup> disagreed with this experience and reported a low incidence of thrombophlebitis when the drug was given in a dose of 200 mg diluted in 500 ml of dextrose.

## Survey and results

To determine the frequency of thrombophlebitic complications from the use of naftidrofuryl infusions in Germany we approached 13 angiological centres for information on their experiences with the drug. The results (see table) showed that the incidence of thrombophlebitis in patients given

Details of naftidrofuryl infusions used in 13 centres\* in Germany and incidence of thrombophlebitis

Centre	No of infusions	Period of use (years)	Average dose per infusion (mg)	Average duration of infusion (hours)	Basic solution used	Incidence of thrombophlebitis
1	15 000	8	800-1600	2-3	500 ml physiological NaCl	Extremely seldom. No serious or ascending thromboses
2	7 250	5	400-1200	2-4	NaCl	None
3	15 500	6	600-1000	1-3	Rheomacrodex or physiological NaCl	So far about 15 episodes; connection with infusions not certain
4	4 680	6	400	2	500 ml 5% glucose	None
5	11 760	6	200-400	1-2	500 ml physiological NaCl or 500 ml 5% fructose	About 2.8%
6	20 250	8	120-400	—	500 ml NaCl	No obvious association between thrombosis and infusions
7	8 500	7	200-800	—	500 ml 5% fructose	About 0.5%
8	18 000	5	400-1400	2-4	Physiological NaCl	Less than the usual risk of thrombophlebitis
9	8 000	8	≤2000	—	Physiological NaCl	None
10	11 750	4	400	1½-2½	500 ml physiological NaCl	Local reactions only
11	3 500	4	≤1200	4	500 ml physiological NaCl	About 0.5%
12	15 000	5	400	1½-2	—	Normal complication rate (3%)
13	20 000	7	≤1600	—	—	Only three clear cases of thrombosis associated with infusion

\*Details of the centres listed may be obtained from the author.