

any symptoms when they were withdrawn, and there were no notable changes in heart rate or blood pressure. Beta-blocker withdrawal produced variable results, but unlike clonidine there was no relation between the dose withdrawn and the increase in heart rates and blood pressures. The reason for this difference must lie in the different pharmacological effects of these drugs, but it is clearly important to know that violent reactions are not likely to attend accidental withdrawal of beta-blocking drugs.

The same generalisation can be made with respect to methyl-dopa, but the doses used were small and the degree of blood pressure control achieved in these patients was not good. None of the recordings showed evidence of postural or exercise hypotension, which are a feature of adequate blood pressure control with this drug, and further studies need to be done in patients taking larger doses whose blood pressure is better controlled, as defined by clinic blood-pressure readings.

References

- 1 Veterans Administration Co-operative Study Group, *Circulation*, 1975, **51**, 1107.
- 2 Hoobler, S W, *Catapres in Hypertension*, p 116. London, Butterworths, 1969.
- 3 Hokfelt, B, Hedeland, H, and Dymling, J F, *European Journal of Pharmacology*, 1970, **10**, 389.
- 4 Hansson, L, et al, *American Heart Journal*, 1973, **85**, 605.
- 5 Goldberg, A D, Wilkinson, P R, and Raftery, E B, *Postgraduate Medical Journal*, 1976, **52**, suppl No 7, p 128.
- 6 Goldberg, A D, Raftery, E B, and Green, H L, *Postgraduate Medical Journal*, 1976, **52**, suppl No 7, p 104.
- 7 Langer, S Z, *Biochemical Pharmacology*, 1974, **23**, 1793.
- 8 Davies, D S, et al, *Clinical Science and Molecular Medicine*, 1976, **51**, 6395.
- 9 Furst, C I, *Advances in Drug Research*, 1967, **4**, 133.
- 10 Boura, A L A, and Green, A F, *Annual Review of Pharmacology*, 1965, **5**, 183.

(Accepted 11 March 1977)

Undescribed toxin in pseudomembranous colitis

H E LARSON, J V PARRY, A B PRICE, D R DAVIES, J DOLBY, D A J TYRRELL

British Medical Journal, 1977, **1**, 1246-1248

Summary

A girl aged 12 developed pseudomembranous colitis after a short course of oral penicillin. She had no history of adverse reaction to penicillin before or after the illness. No pathogenic bacteria, mycoplasmas, or viruses were found in her faeces, but they did contain a toxin. Toxin was also found in four of five other patients with pseudomembranous colitis but not in six specimens obtained from patients with diarrhoea caused by other disorders. Further studies may show that pseudomembranous colitis is caused by a bacterial toxin.

Introduction

Pseudomembranous colitis is an uncommon condition often occurring in association with the administration of antibiotics. The cause is unknown but drug toxicity, bowel ischaemia, altered intestinal bacterial flora, and viruses have all been suggested¹⁻⁴. We describe intensive studies performed on one patient with this condition in an attempt to determine its cause.

Case report

A 12-year-old schoolgirl was admitted to hospital after four weeks of abdominal pain, vomiting, and diarrhoea. She had been well until

she developed a sore throat, for which she took 16 250-mg doses of phenoxymethylpenicillin by mouth over four days. For the next three weeks she had intermittent colicky abdominal pain, diarrhoea, and vomiting, attended school for only one and a half days, and lost 6.4 kg. Before admission her symptoms worsened and she developed a fever. There was no history of allergy or adverse reactions to drugs and she had taken oral penicillin previously without ill effects.

She was acutely ill with a dry mouth, a temperature of 37.5°C, and a pulse of 120/min. She weighed 35 kg. The abdomen was not distended but was very tender over the hypogastrium and in the left lumbar and iliac areas. There was guarding and severe peritonism, but bowel sounds were active. The peripheral white cell count was $28.9 \times 10^9/l$ ($28\,900/mm^3$) with an excess of neutrophils and occasional metamyelocytes. Microscopy of fresh faeces showed many leucocytes and a few red blood cells, but no parasites. Results of faecal cultures were negative, as were antibody titres to *Salmonella* and *Yersinia*.

Sigmoidoscopy showed a hyperaemic, but intact, nonfriable mucosa, covered with patches of thick, creamy, semi-adherent pus. At laparotomy the entire serosa of the large bowel was injected. The peritoneal cavity contained 200 ml of turbid but sterile fluid. Subsequent histological examination of a rectal biopsy specimen showed the classic features of the type 1 lesions of pseudomembranous colitis.⁵ The patient was treated with codeine phosphate and intravenous fluids, progressing to a light diet as she improved. She received no antibiotics in hospital. When discharged after 25 days she was well, and two weeks later at outpatient attendance she had gained weight and was having one formed stool per day.

SPECIAL STUDIES

Conventional scratch, intradermal, and patch skin tests with benzylpenicillin and a sterile penicillin solution made from the patient's own tablets gave entirely negative results. Stool and rectal biopsy specimens taken during the acute illness and during convalescence were placed in transport medium and quantitatively assayed for aerobic and anaerobic bacteria. The cultures showed only minor qualitative and quantitative differences. Nonfaecal streptococci and one species of *Bacteroides* were found during the acute phase but not during convalescence and more *Arachnia* sp were also present during the acute phase. Electron microscopy of negatively stained grids prepared from ultracentrifuged and immune-precipitated stool suspension failed to show any virus particles. Nevertheless, thin sections of colonic exudate fixed in Karnovsky's fixative did show 40-nm diameter spherical membrane-bound "viral-like" particles.

Northwick Park Hospital and Clinical Research Centre, Harrow, Middlesex HA1 3UJ

H E LARSON, MRCP, member of scientific staff

J V PARRY, BSC, AIMS, research officer

A B PRICE, MRCPATH, consultant histopathologist

J DOLBY, PHD, member of scientific staff

D A J TYRRELL, FRCPATH, FRS, deputy director of centre

St Thomas's Hospital Medical School, London, SE1 7EH

D R DAVIES, MRCPATH, senior lecturer in morbid anatomy

DEMONSTRATION OF TOXIN

During initial attempts to isolate viruses tissue cultures were inoculated with faecal suspensions and a toxic effect observed after overnight incubation. The effect was seen in HeLa and Rhesus monkey kidney cells, but was most noticeable in human embryonic lung fibroblast cells (MRC 5). It was also shown when highly diluted faeces were inoculated, and was not prevented by removing the inoculum after three hours and refeeding with fresh maintenance medium.

The cytopathic effect had a characteristic pattern, occurring diffusely and simultaneously throughout the cell sheet, progressing to a maximum at 48 h. Cells became rounded and refractile and then came off the glass (figs 1 and 2). Two successive tissue culture supernatant passes, representing tenfold and one hundredfold dilutions of the original suspension, reproduced the effect in a milder form. It could not be serially propagated. No virus particles were seen in cell culture thin sections or in negatively stained grids of culture supernatant. The toxin was present in high titres in specimens obtained during the acute illness, but not after convalescence (table I). It was also detected in the suspension prepared from a rectal biopsy specimen taken while the disease was still active.

We also examined material from five other patients with pseudomembranous colitis proved by biopsy specimens. Table II shows

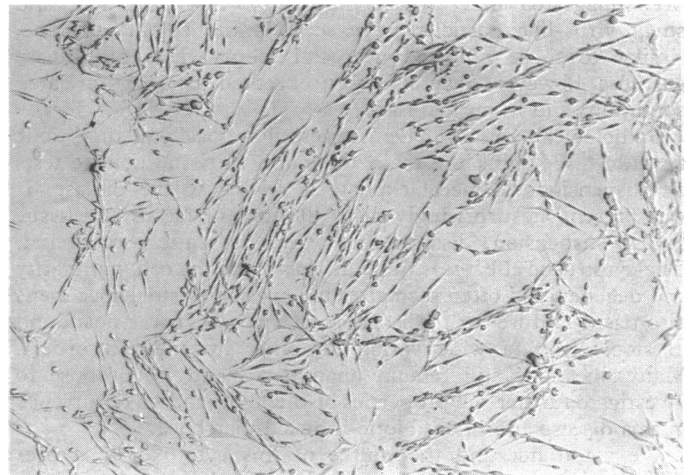


FIG 2—Toxic cytopathic effect of faecal suspensions in MRC 5 cells ($\times 79$; unstained).

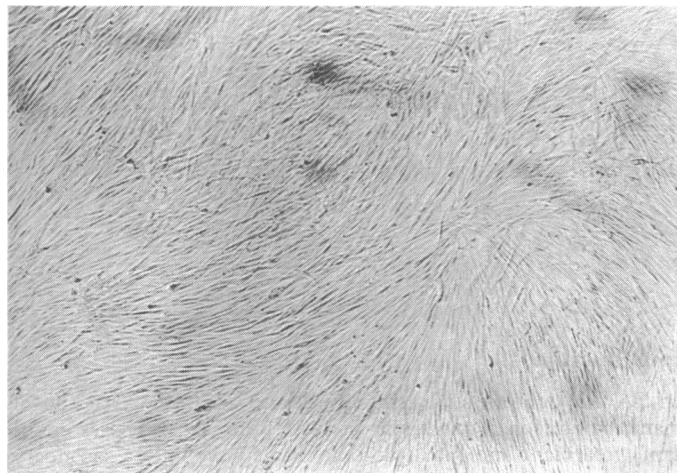


FIG 1—Uninoculated cultures of human embryonic lung fibroblasts (MRC 5) ($\times 79$; unstained).

TABLE I—Demonstration of toxin in stool and rectal biopsy specimens from patient with pseudomembranous colitis

Day	Clinical state	Specimen	Titre of toxin*
3	Acutely ill; results of sigmoidoscopy and biopsy positive	Stool (fluid)	1/1000
6	Still ill	Stool (fluid)	1/5000
13	Improving; rectal biopsy specimen shows only "colitis"	Biopsy specimen	1/100
After discharge (1 month)	Well	Stool (formed)	Negative; 1/5

*Titre represents highest dilution of original clinical material to produce definite degeneration 48 h after inoculating 0.1 ml of diluted material into cultures of MRC 5 cells.

TABLE II—Tissue culture toxicity, clinical state, and previous antibiotic treatment in five patients with pseudomembranous colitis

Age (years)	Sex	Clinical presentation	Previous antibiotic treatment	Toxicity	Specimen	Outcome
61	M	Ventricular aneurysm; surgery	Cloxacillin; ampicillin; lincomycin	Present	Stool	Recovered
55	F	Diverticulitis; peritonitis	Clindamycin; gentamicin	Present	Stool	Recovered
24	F	Dental abscess	Erythromycin; clindamycin	Present	Stool	Recovered
85	F	Subacute obstruction; localised peritonitis	Ampicillin; gentamicin	Present	Stool; postmortem tissue	Died
63	M	Osteomyelitis; psoas abscess	None	Absent	Postmortem tissue	Died

their clinical presentation and antibiotic history. Specimens from six patients with other causes for diarrhoea (three with ulcerative colitis, three with salmonellosis) gave negative results. In addition it has not been seen in MRC 5 cells inoculated with faecal specimens in routine efforts to isolate viral agents from patients with diarrhoea and various other illnesses.

We examined the properties of the toxic factor. The effect on tissue culture was not inhibited by mixing a 1/50 dilution of the stool suspension with an equal volume of the convalescent patient's serum. It was completely inactivated by heating at 56°C for 30 minutes, but not restored by the addition of fresh guinea pig complement. It retained activity after storage at -70°C for 12 months. It was not sedimented by centrifugation at 100 000 g for one hour, and passed a 50-nm membrane filter (Millipore). The titre of activity was not reduced by dialysis against saline at 4°C overnight. The cytopathic effect in mouse Y-1 adrenal cells did not resemble that of *Escherichia coli* enterotoxin. It thus appeared to be a heat-labile substance with a molecular weight of over 6000. Because the toxin might have been produced by bacterial species present only during the illness, cultures of some of the bacteria isolated from the patients' faecal specimens were investigated. After centrifugation at 8000 g the supernatants were inoculated into MRC 5 tissue cultures. No cytopathic effect was observed.

Discussion

One cause of pseudomembranous colitis may be toxicity or allergy to antibiotics.⁶ Our patient, however, had received oral penicillin before her illness, and intramuscular penicillin afterwards, without ill effect. Furthermore, the disease progressed long after the drug had been stopped. We cannot see how direct toxicity or the usual sort of hypersensitivity could have been implicated in this case. Another hypothesis is that pseudomembranous colitis is due to alterations in the intestinal bacterial flora.⁷ More extensive quantitative bacteriological studies would be required to disprove this idea, but results of stool studies in our patient did not seem to be abnormal. Unusual intestinal microbes might be the cause. We looked for mycoplasmas and mycobacteria and found none. It has also

been suggested that viruses may cause this condition, and small virus-like particles were seen in the colonic exudate, similar to those reported in rectal biopsy findings.³ These particles, however, have also been observed in other unrelated conditions and in normal tissue.^{6-8,9}

Pathological studies have suggested a locally acting toxic agent.^{1,5,6} We think the toxin we found in tissue culture tests on suspensions of faecal exudate is related to the disease. It was present at surprisingly high dilutions of faeces and tissue biopsy suspension, disappearing when the patient recovered. The cytopathic effect was quite distinct from the cell granularity and degeneration often seen after inoculation of stool specimens into tissue culture for the isolation of viruses. It was not found in stools from a wide variety of other intestinal disorders. Many questions still remain unanswered and we propose to investigate further the properties of the toxin and its occurrence in this disease and in antibiotic-induced diarrhoea.

We could not find the source of this cytotoxin in a preliminary screening of the bacteria isolated, but special in-vivo conditions may be required for its production. It might result from tissue breakdown or inflammation, though we have not found it in other cases of infective diarrhoea or inflammatory

bowel disease. Since pseudomembranous colitis is uncommon we hope this preliminary report will encourage others to look for similar tissue culture effects in the disease. If it is proved to be caused by a bacterial toxin then it may become possible to treat it with specific antibacterial measures.

We thank Sir Graham Bull for referring the patient, Drs R Dourmashkin and S Patterson for help with electron microscopy, and Dr C Hawkey for immunological studies.

References

- ¹ Goulston, S J M, and McGovern, V J, *Gut*, 1965, **6**, 212.
- ² Keusch, G T, and Present, D H, *Journal of Infectious Diseases*, 1976, **133**, 578.
- ³ Steer, H W, *Gut*, 1975, **16**, 695.
- ⁴ Whitehead, R, *Gut*, 1971, **12**, 912.
- ⁵ Price, A B, and Davies, D R, *Journal of Clinical Pathology*, 1977, **30**, 3.
- ⁶ Pittmann, F E, et al, *Archives of Internal Medicine*, 1974, **134**, 368.
- ⁷ Marr, J J, et al, *Gastroenterology*, 1975, **69**, 352.
- ⁸ Dourmashkin, R, personal communication.
- ⁹ Owen, R L, *Gastroenterology*, 1976, **70**, 1185.

(Accepted 8 March 1977)

Comparative trial of endocrine versus cytotoxic treatment in advanced breast cancer

T PRIESTMAN, M BAUM, VERA JONES, J FORBES

British Medical Journal, 1977, **1**, 1248-1250

Summary

Ninety-two women with advanced breast cancer were allocated at random to receive either cytotoxic or endocrine treatment. Out of 45 women included in the cytotoxic treatment group, 22 (49%) achieved complete or partial remission of their disease, whereas of the 47 included in the endocrine treatment group, only 10 (21%) achieved such remission. Significantly longer survival times in the cytotoxic treatment group were most apparent among premenopausal women, 75% of such patients responding to cytotoxic drugs (median survival 46 weeks) compared with only 11% benefiting from ovarian ablation (median survival 12 weeks). In postmenopausal women with predominantly soft-tissue disease, however, additive hormonal treatment with tamoxifen produced remission rates and survival times equivalent to those produced by cytotoxic drugs.

Cardiff Breast Clinic, Velindre Hospital, Cardiff CF4 7XL

T PRIESTMAN, MRCP, FRCP, consultant in radiotherapy and oncology
(present address: Wellcome Research Laboratories, Beckenham, Kent)
VERA JONES, MB, BS, medical assistant

Surgical Unit, University Hospital of Wales, Cardiff

M BAUM, MChir, FRCS, senior lecturer
J FORBES, MS, FRCS, Nuffield fellow in surgery

Introduction

In Britain doctors still generally accept that the first line of management for recurrent or metastatic breast cancer is endocrine treatment and that cytotoxic drugs have only a secondary role. Various investigators have reported remarkably good results using combination cytotoxic treatment in late breast cancer in recent years,¹⁻³ and some have suggested that traditional endocrine measures may have little further part to play.⁴ Many such results have come from uncontrolled series, which, combined with arguments that the side effects of cytotoxic treatment are greater and the duration of remission is shorter than with endocrine treatment, has reduced the credibility of the chemotherapists' claims. We therefore decided to design a prospective trial comparing these two approaches to management.

Patients and methods

All women with locally recurrent or metastatic adenocarcinoma of the breast who had not received previous systemic treatment were admitted to the study provided that they had clinically or radiologically assessable disease. By means of treatment cards drawn from sequentially numbered sealed envelopes they were allocated at random to receive appropriate endocrine treatment or combination cytotoxic therapy. The policy of endocrine treatment adopted evolved from the following considerations.

Premenopausal women and those within two years of their last menstrual period underwent either oophorectomy or induction of menopause by radiation. In a previous study at the Cardiff Breast Clinic oestrogen, androgen, and progesterone treatments were compared in postmenopausal women with breast cancer.⁵ Patients with secondary deposits predominantly in bone responded best to androgens, and those with secondary deposits in soft tissue or lung parenchyma responded particularly well to stilboestrol. A later study in Cardiff looked at tamoxifen treatment in women who were