

Anatomical Alterations of the Visual Motion Processing Network in Migraine with and without Aura

Cristina Granziera¹✉, Alexandre F. M. DaSilva¹✉, Josh Snyder¹, David S. Tuch^{1,2}, Nouchine Hadjikhani^{1,2*}

1 Athinoula A. Martinos Center for Biomedical Imaging, Massachusetts General Hospital, Harvard Medical School, Charlestown, Massachusetts, United States of America, **2** Division of Health Sciences and Technology, Harvard-Massachusetts Institute of Technology, Cambridge, Massachusetts, United States of America

Funding: This work was supported by NIH grant 5P01 NS 35611–09 (AFMD, JS, NH), the Swiss Heart Foundation (CG), and the National Alliance for Medical Image Computing (NIBIB U54 EB05149), which is funded through the NIH Roadmap for Medical Research (JS, DST) and the Dean's award of Harvard School of Dental Medicine (AFMD). The funders had no role in study design, data collection and analysis, decision to publish, or preparation of the manuscript.

Competing Interests: The authors have declared that no competing interests exist.

Academic Editor: Arne May, University of Hamburg, Germany

Citation: Granziera C, DaSilva AFM, Snyder J, Tuch DS, Hadjikhani N (2006) Anatomical alterations of the visual motion processing network in migraine with and without aura. *PLoS Med* 3(10): e402. DOI: 10.1371/journal.pmed.0030402

Received: February 23, 2006

Accepted: July 31, 2006

Published: October 17, 2006

DOI: 10.1371/journal.pmed.0030402

Copyright: © 2006 Granziera et al. This is an open-access article distributed under the terms of the Creative Commons Attribution License, which permits unrestricted use, distribution, and reproduction in any medium, provided the original author and source are credited.

Abbreviations: CSD, cortical spreading depression; DTI, diffusion tensor imaging; FA, fractional anisotropy; HC, healthy control; LGN, lateral geniculate nucleus; SD, standard deviation; MWA, migraine with aura; MWOA, migraine without aura; WM, white matter

* To whom correspondence should be addressed. E-mail: nouchine@nmr.mgh.harvard.edu

✉ These authors contributed equally to this work.

ABSTRACT

Background

Patients suffering from migraine with aura (MWA) and migraine without aura (MWOA) show abnormalities in visual motion perception during and between attacks. Whether this represents the consequences of structural changes in motion-processing networks in migraineurs is unknown. Moreover, the diagnosis of migraine relies on patient's history, and finding differences in the brain of migraineurs might help to contribute to basic research aimed at better understanding the pathophysiology of migraine.

Methods and Findings

To investigate a common potential anatomical basis for these disturbances, we used high-resolution cortical thickness measurement and diffusion tensor imaging (DTI) to examine the motion-processing network in 24 migraine patients (12 with MWA and 12 MWOA) and 15 age-matched healthy controls (HCs). We found increased cortical thickness of motion-processing visual areas MT+ and V3A in migraineurs compared to HCs. Cortical thickness increases were accompanied by abnormalities of the subjacent white matter. In addition, DTI revealed that migraineurs have alterations in superior colliculus and the lateral geniculate nucleus, which are also involved in visual processing.

Conclusions

A structural abnormality in the network of motion-processing areas could account for, or be the result of, the cortical hyperexcitability observed in migraineurs. The finding in patients with both MWA and MWOA of thickness abnormalities in area V3A, previously described as a source in spreading changes involved in visual aura, raises the question as to whether a "silent" cortical spreading depression develops as well in MWOA. In addition, these experimental data may provide clinicians and researchers with a noninvasively acquirable migraine biomarker.

The Editors' Summary of this article follows the references.

Introduction

Migraine is a widespread and debilitating disorder and one of the most common disorders of the nervous system, according to the World Health Organization. Prevalence studies estimate that migraine affects 15%–25% of women and 6%–8% of men [1–4]. More than 2.5 million people in North America have at least one day of migraine per week. Despite the public health significance of this problem, the pathophysiology of migraine is not yet fully understood, and no biomarkers are available for the diagnosis.

Migraineurs exhibit abnormalities in motion processing between attacks [5–8]. Differences in sensitivity to temporal and spatial contrast, color, and orientation have been observed, and many migraineurs report abnormal visual discomfort when viewing striped patterns (e.g. [7,9–16]). In addition, migraineurs are unusually susceptible to visually induced motion sickness [17], which is predictive of migraine development [18].

Motion perception is a complex phenomenon involving subcortical (lateral geniculate nucleus [LGN], superior colliculus, and pulvinar [19]) and cortical structures (visual cortical areas MT+ and V3A [20,21]). In humans, area MT+ is located between the lateral and the inferior occipital sulcus in the occipitotemporal region and is characterized by a well-defined pattern of dense myelination and distinguishing architectonic features [22]. Area V3A is located in the transverse occipital sulcus and is specifically activated by coherent motion [20].

Motion perception deficits have frequently been reported in patients with MWA and MWOA, both in the acute phase and in the interictal period [6,7,11,23,24], and abnormal functions of areas MT+ and V3A have been evidenced in migraineurs. Transcranial magnetic stimulation studies have shown that MWA and MWOA patients have a lower phosphene threshold than HCs when transcranial magnetic stimulation is delivered over V1 and over area MT+ [6,23]. Moreover, psychophysical studies show that both groups of migraineurs exhibit a decreased ability to detect coherent motion [7] between attacks.

One of the leading hypotheses in migraine pathophysiology is that the brains of migraineurs are hyperexcitable [6,23,25]. Enhanced neuronal excitation results in increased extracellular K^+ . If the reuptake and other transport processes are not efficient in controlling glutamate release, a wave of cortical spreading depression (CSD) [26] is likely to arise as a consequence of this extracellular K^+ increase. CSD is a slow, self-propagating wave of neuronal and glial depolarization, followed by long-lasting suppression of neural activity. CSD has been directly demonstrated in humans suffering from brain trauma or cerebral hemorrhage [27].

In MWA, several studies report the presence of changes that can be related to CSD [28,29], and a phenomenon similar to CSD underlies occipital lobe dysfunction during visual aura [28–37]. In a previous study, which used functional imaging to examine patients during visual aura, we found eight characteristics of CSD using continuous functional resonance magnetic imaging recording, including typical propagation velocity, duration, and suppression of activity [29]. These changes started in area V3A in two recorded attacks.

Functional studies point to hyperexcitability in regions of

the visual cortex known to be involved in motion processing in patients with both MWA and MWOA [6,7,11,23,38] (but see [39,40]).

In order to investigate the anatomical substrate of these visual processing abnormalities, we used cortical thickness measurements and DTI to characterize the integrity of the gray and white matter (WM) of regions supporting motion perception in migraineurs.

Methods

Participants

In total 24 individuals with migraine (12 with MWA and 12 MWOA), and 15 HCs were enrolled in the study. The patients all met the criteria of the International Classification of Headache Disorders (2nd Ed) criteria for the diagnosis of migraine [41]. Demographic characteristics are given in Table 1. All participants with aura suffered from visual aura in at least half of the attacks (the other half were attacks of MWOA). None had their aura/headache systematically on the same side.

Informed written consent was obtained for each participant before the scanning session, and the Massachusetts General Hospital Human Studies Committee approved all procedures under Protocol #2002P-000652.

Imaging

Two high-resolution ($1.0 \times 1.0 \times 1.25$ mm) structural images were obtained with a MP-RAGE (magnetization-prepared rapid acquisition with gradient echoes) sequence, (128 slices; 256×256 matrix; echo time (TE) = 3.44 ms; repetition time (TR) = 7.25 ms; flip = 7°) on a 3.0 Tesla Allegra MR scanner (Siemens, Erlangen, Germany). The two scans were motion-corrected with AFNI and averaged to create a single image volume with a high contrast-to-noise ratio.

Whole-head DTI scans were acquired (TR/TE = 8,300/89 ms; slice thickness = 2 mm (0 mm gap); 60–64 slices total; FOV 256×256 mm; 128×128 matrix; 1 average; 60 directions of encoding with b value = 700 s/mm^2 ; and 10 images with b-value = 0 s/mm^2). Head motion was minimized by the use of tightly padded clamps attached to the head coil. Data were processed using the Freesurfer package.

Cortical Thickness Analysis

For cortical thickness measurements, we used a technique of analysis developed in our center by Fischl et al. [42]. This

Table 1. Demographics of Study Participants

Variable	MWA Patients (n = 12)	MWOA Patients (n = 12)	HCs (n = 15)
Age (y), mean (SD)	33.8 (9.1)	35.2 (6.2)	33.2 (8.7)
Female/male	9/3	7/5	11/4
Migraine duration (y), mean (SD)	20.3 (11.2)	19.5 (8.5)	NA
Migraine frequency (per month), mean (SD)	4.1 (3.6)	4.0 (3.6)	NA
Aura frequency (per month), mean (SD)	2.1 (3.6)	NA	NA

NA, not applicable

DOI: 10.1371/journal.pmed.0030402.t001

automated method accurately measures the thickness of the cerebral cortex across the entire brain and generates cross-individual statistics in a coordinate system based on cortical anatomy. The interindividual standard deviation (SD) of the thickness measures is less than 0.5 mm, implying the ability to detect focal atrophy in small populations or even individual participants. The reliability and accuracy of this new method has been assessed by within-participant test-retest studies, as well as by comparison of cross-participant regional thickness measures with published values. This technique has also been validated with histological and with manual [43,44] measurements.

The maps of cortical thickness were created using previously described procedures [42]. Regions of interest on the cortical surface were defined by detection of contiguous regions of statistical significance ($p < 0.05$) in the maps described above. These regions of interest were created on a standard brain and mapped back to each individual using spherical morphing to find homologous regions across participants. Mean thickness scores for areas MT+ and V3A were calculated for each person. These scores were used to perform unpaired t-test and Bonferroni-corrected ANOVAs between groups for each region of interest.

DTI Analysis

DTI has emerged as a powerful method for the investigation of WM architecture. The technique measures the tensor associated with the self-diffusion (Brownian motion) of the endogenous water in brain tissue [45]. It is more sensitive to WM alteration than conventional T1 or T2 imaging. Diffusion anisotropy, qualified with the fractional anisotropy (FA) metric [46], is influenced by several factors, including the degree of myelination, density, diameter distribution, and orientational coherence of axons [47]. Deep WM lesions (seen on T1 or T2 images), including small infarcts, have been described in migraineurs [48], although no exploration of more subtle WM changes has been performed.

The diffusion tensor, associated eigensystem, and FA metric were calculated for each voxel [49,50]. The FA volumes were normalized to MNI (Montreal Neurological Institute) space manually. The MNI normalization was performed by registering the individual T2 volume to the MNI-152 T2 template and then applying the registration transformation to the FA volume. The MNI-normalized FA volumes were then smoothed using a three-dimensional Gaussian kernel with 3mm FWHM to improve anatomic correspondence across volumes. Statistical maps for group differences in FA were then computed, using a two-tailed t-test on a voxel-by-voxel basis.

Results

An increase of cortical thickness was found bilaterally in two areas involved in motion processing, area V3A and MT+, in migraineurs compared with controls. Values are expressed, in millimeters, as mean (SD) V3A: MWA, 2.00 (0.09); MWoA, 2.06 (0.19); HC, 1.86 (0.08). MT+: MWA, 2.11 (0.21); MWoA, 2.10 (0.28); HC, 1.87 (0.17). Unpaired t-tests revealed that both areas were significantly thicker in all migraineurs compared with HCs: V3A, $p = 0.0002$; MT+, $p = 0.002$. One-way ANOVA showed significant differences in V3A and MT+: V3A, $p = 0.0005$; MT+, $p = 0.010$. Bonferroni multiple comparisons test

revealed significant differences between each subgroup of migraineurs and HCs (MWA versus HCs: V3A, $t = 2.99$, $p < 0.05$; MT+, $t = 2.82$, $p < 0.05$; MWoA versus HCs: V3A, $t = 4.12$, $p < 0.001$; MT+, $t = 2.68$, $p < 0.05$) but no significant difference between migraineurs (MWA versus MWoA: V3A, $t = 1.08$, $p > 0.05$; MT+: $t = 0.13$, $p > 0.05$) (Figure 1).

Similarity was found between the localization of cortical thickening in the mean thickness difference map of the 24 migraineurs compared with controls in V3A, and the location of the source of a CSD event in a single individual described in our previous work (Figure 2) [29].

FA values in the white matter subjacent to area V3A revealed significantly lower FA bilaterally in the migraine group relative to HC (right hemisphere, $p = 0.03$; left hemisphere, $p = 0.005$). (See Methods for details of analysis.) WM subjacent to area MT+ was lower bilaterally but reached significance only in the right hemisphere (right hemisphere, $p < 0.001$; left hemisphere, $p = 0.16$) (Figure 3A). There was no significant difference between MWA and MWoA subgroups in either area ($p = 0.5$). The superior colliculus and the left LGN, two subcortical areas involved in visual motion perception, also exhibited a significantly lower FA in migraineurs (superior colliculus, $p = 0.043$; LGN, $p = 0.0035$) (Figure 3B and 3C).

Discussion

This is the first demonstration, to our knowledge, of interictal cortical abnormalities in migraine. Migraine remains an enigmatic disease. The presence of transient neurological signs (aura) in a subgroup of migraineurs has long raised a question that, perhaps surprisingly, still remains controversial: Are MWA and MWoA two separate entities, or are they different manifestations of a similar underlying mechanism? Although the two forms of migraine may be distinct disorders [51,52], similarities between them are remarkable. Pure MWA is comparatively rare, and most

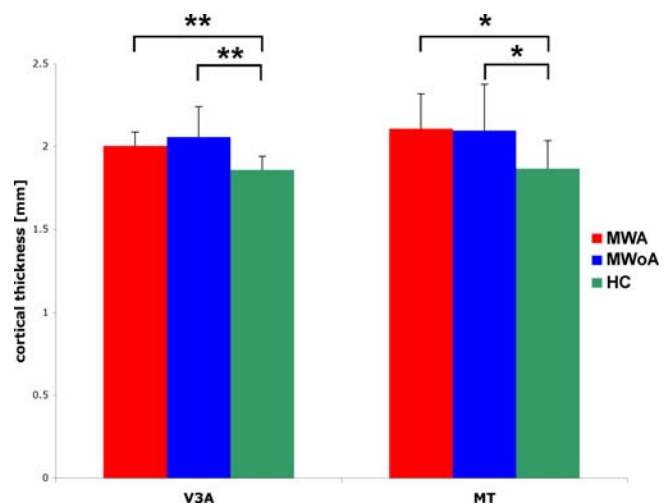


Figure 1. Cortical Thickness Is Increased in Motion-Processing Areas in Migraineurs

Values are presented in mean millimeters (SD). V3A: MWA, 2.00 (0.09); MWoA, 2.06 (0.19); HCs, 1.86 (0.08). MT+: MWA, 2.11 (0.21); MWoA, 2.10 (0.28); HCs, 1.87 (0.17). Asterisks represent p -value summary * $p < 0.05$; ** $p < 0.01$

DOI: 10.1371/journal.pmed.0030402.g001

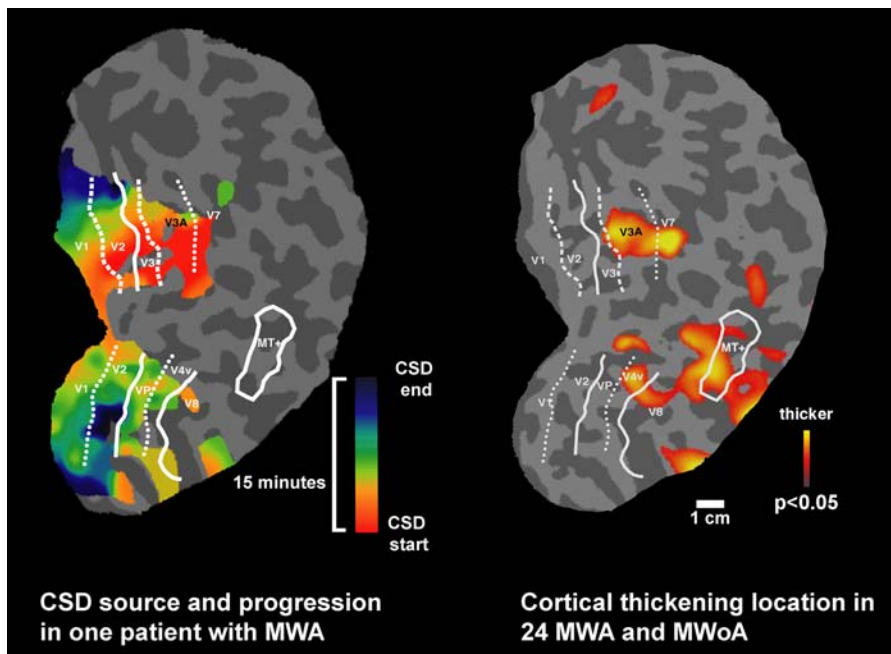


Figure 2. Retinotopic Localization of Cortical Thickness Changes

Flattened maps of the right occipital cortex, gyri, and sulci are indicated as light and dark gray. The borders of retinotopic areas are indicated in white (horizontal meridians, solid lines; upper vertical meridians, dotted lines; lower vertical meridians, dashed lines). The image on the left is taken from our previous data [29] and shows the progression of CSD during a visual aura, starting in area V3A, in a single participant. The image on the right shows the average map of the mean thickness difference of 24 migraineurs compared with 15 matched controls, projected on the same brain, with the superimposed retinotopy for one participant. A clear correspondence can be seen between the area of CSD origin in V3A in the left image and cortical thickness difference in the right image. In addition, areas of thickening can be observed in visual area MT+. DOI: 10.1371/journal.pmed.0030402.g002

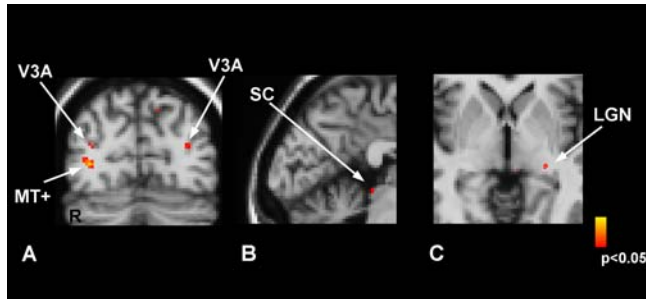


Figure 3. Fractional Anisotropy Differences in Migraineurs Versus Healthy Controls

Coronal (A) and sagittal (B) sections show the areas exhibiting statistically significant lower FA values in migraineurs compared to HCs. Significant differences can be seen in the WM underlying MT+ and V3A areas (A), in the superior colliculus (SC) (B), and in the left LGN (C). DOI: 10.1371/journal.pmed.0030402.g003

MWA patients suffer also from attacks without aura, clearly suggesting a connection between the two forms [53]. MWA and MWoA share a number of characteristics: they both have a strong genetic component; they can be triggered by the same substances (usually serotonin releasers such as reserpin or fenfluramine, NO releasers, or high-tyramine foods); both are at higher risks for WM lesions in the cerebellar region of the posterior circulation [54]; and both share the same clinical picture with regard to the pain and related symptoms during the headache phase. In addition, a number of similarities in the therapeutic approach also suggest that a similar pathophysiological phenomenon underlies both dis-

orders—namely, an altered excitability of the cortex. Preventive treatments for both types that have been validated for efficacy in double-blind, placebo-controlled studies include anticonvulsants (divalproex sodium, topiramate); calcium channel antagonists (flunarizine); antidepressants (amitriptyline); beta-blockers (propranolol); and serotonin blocking agents (pizotifen). The two first classes (anticonvulsants, calcium channel antagonists) are likely to reduce cortical excitability, whereas the mechanism of action of three others (antidepressants, beta-blockers, and serotonin blocking agents) is less clear. However, recent data show that migraine prophylactic agents may act by increasing the CSD threshold [55]. A common pathophysiology remains a valid hypothesis, and several recent functional studies have underlined the importance of neuronal hyperexcitability in both types of migraine [25,38].

Our data show that both MWA and MWoA present anatomical changes in precortical and cortical areas involved in motion perception and confirm that these abnormalities are detectable outside the acute phase.

Reduction of anisotropy can be due to several conditions. In the most commonly referred cases, a loss of myelin (as is the case in MS [56–60], stroke [61–63], or in the cerebral arteriopathy CADASIL [64–66]) is accompanied by a loss of barriers to diffusion, and by an increase in mean diffusivity and a decrease in fractional anisotropy. In these patients, decreased performance is correlated with increased mean diffusivity [64], reflecting damage to specific tracts.

Paradoxically, however, a reduced FA can be due to opposite patterns of myelin fiber conditions: loss of myelin,

as described above, or increased axonal diameter with increased myelin [67]. In healthy individuals, positive correlations have been described between reaction time in a visuospatial task and visual WM pathways [68]. The faster the individuals were, the lower the FA was. In addition, two studies have shown that intensive training results in lower FA values in the motor pathways of piano players [69,70]. Abnormal white matter maturation processes could result in the alteration observed in motion-processing areas and their subjacent WM, as MT+ is an area that undergoes myelination in an early phase during development [71,72]. This hypothesis cannot be excluded for area V3A, for which no specific developmental data are available presently. Supporting evidence for this interpretation is provided by the early visual processing abnormalities observed in migraineurs, and the close association between motion sickness in childhood and later appearance of migraine [18]. FA changes observed in the WM beneath areas V3A and MT+ may correspond to “thicker” and faster axons, a hypothesis that would be corroborated by the psychophysical findings in migraineurs. Prospective studies in migraineurs’ children may help to resolve this question.

An increased thickness of areas V3A and MT+ could be the result of a focal dysplasia leading to exaggerated excitability of neurons in these regions [25,38,73] and to the classical aura percept. In this context, the role of area V3A is particularly intriguing, since it has been suggested as the source of CSD during the aura phase. Our results show that this region is abnormally thickened in both hemispheres in migraine patients, without distinction between subgroups. These findings, as well as the FA abnormalities in V3A supporting white matter, suggest the importance of this area in migraine during the interictal period, as hyperexcitability of the V3A area could contribute to the alteration of motion processing frequently observed in MWA and MWOA.

Most migraine headaches are not preceded by any obvious neurological symptoms, and their origin remains a mystery. Should CSD be of pivotal importance in migraine and aura symptoms reflect a CSD-like phenomenon in the human brain, there is no clear reason that only some migraine patients experience aura. Two imaging studies suggest that MWOA could be the result of a “silent” CSD-like event occurring in the brain: Occipitally originating cortical spreading hypoperfusion was observed by Woods et al. [74] during MWOA; and spreading suppression of neuronal activity in the occipital cortex in MWOA before headache onset was reported by Cao et al. [28]. These data suggest that CSD occurs without being necessarily expressed as aura symptoms and that it could be an underlying phenomenon in both MWA and MWOA.

Alternatively, or in addition, the changes observed may also develop as the consequence of repetitive migraine attacks on the integrity of the cortical layers in V3A and MT+ and the subjacent white matter. The increase in cortical thickness observed in both MWA and MWOA could be due to repeated glial activation following repeated episodes of CSD [75] and/or hypoperfusion [76], known to play a role in migraine pathophysiology [38,77–79].

Neuronal abnormalities in areas MT+ and V3A could explain the common interictal motion-processing deficits observed in both groups (differences in sensitivity to temporal and spatial contrast, color, and orientation; and abnormal visual discom-

fort when viewing striped patterns [7,9–16]. Following this hypothesis, in addition to these chronic symptoms, migraineurs with aura may present acute episodes of CSD originating from these regions that translate into visual scintillations.

A number of recent studies in migraineurs [54,80] show subclinical structural brain changes, going from progressive cellular damage in nociceptive systems to diffuse WM loss, multifocal WM lesions, and ischemic stroke. However, these changes were present in only a small subset of patients. DTI is more sensitive than conventional T1 and T2 imaging, and can detect subtle white matter changes that are not necessarily ischemic. We did not observe any macroscopic lesions in our participants, but did observe significant FA changes common to all individuals in the migraineurs group that were specifically located in the WM subjacent to areas V3A and MT+ as well as in the superior colliculus and in the lateral geniculate nucleus. We cannot conclude from the present data whether these changes are due to a loss of WM, or to an increase in axonal diameter in these functionally organized areas.

In conclusion, we demonstrate that cortical and subcortical structures involved in motion perception differ between migraineurs and persons without migraine. Chronic dysfunction of these areas may explain interictal findings of motion-processing deficits in migraineurs, whereas episodic dysfunction might contribute to the initiation of an attack. The present data indicate that structural changes are present in at least two cortical regions in migraine patients, even outside attacks; that MWA and MWOA share the same abnormalities; and that the changes are present in areas where CSD most probably develops. It seems likely that MWA and MWOA are two phenotypes sharing a common pathophysiological substrate, and that asymptomatic CSD may occur in some patients.

The finding of morphometric changes in the brains of migraineurs may be of fundamental importance because migraine has so far been considered a condition with abnormal brain function but completely normal brain structure. Further characterization of the histological and chemical properties of V3A, MT+, and the subjacent WM, both prospectively and developmentally, will tell us more about the precise nature of and the mechanisms underlying cortical and subcortical changes in migraineurs.

This study presents the limitation inherent to all question-driven reports, as it voluntarily restricted itself to the examination of areas of the brain involved in vision and specifically visual motion processing.

Although our data are experimental and represent the result of a group analysis, the present findings of specific alteration in migraineurs, e.g., cortical thickness increases in specific areas, may open the possibility of a new noninvasive diagnostic tool in migraine.

Supporting Information

Alternative Language Abstract S1. French Translation of the Abstract Found at DOI: 10.1371/journal.pmed.0030402.sd001 (20 KB DOC).

Acknowledgments

We thank Dr. M. Moskowitz for his support and his valuable comments on the manuscript.

Author contributions. NH designed the study. CG, AFMD, JS, and NH analyzed the data. AFMD and NH enrolled patients. CG, AFMD, DST, and NH contributed to writing the paper.

References

- Lipton RB, Stewart WF (1998) Migraine headaches: Epidemiology and comorbidity. *Clin Neurosci* 5: 2–9.
- Roncolato M, Fabbri L, Recchia G, Cavazzuti L, Visona G, et al. (2000) An epidemiological study to assess migraine prevalence in a sample of Italian population presenting to their GPs. *Eur Neurol* 43: 102–106.
- Warshaw LJ, Burton WN (1998) Cutting the costs of migraine: Role of the employee health unit. *J Occup Environ Med* 40: 943–953.
- Stewart WF, Lipton RB, Celentano DD, Reed ML (1992) Prevalence of migraine headache in the United States. Relation to age, income, race, and other sociodemographic factors. *JAMA* 267: 64–69.
- Mulleners WM, Chronicle EP, Palmer JE, Kochler PJ, Vredevelde JW (2001) Visual cortex excitability in migraine with and without aura. *Headache* 41: 565–572.
- Battelli L, Black KR, Wray SH (2002) Transcranial magnetic stimulation of visual area V5 in migraine. *Neurology* 58: 1066–1069.
- McKendrick AM, Badcock DR (2004) Motion processing deficits in migraine. *Cephalalgia* 24: 363–372.
- Ditchfield JA, McKendrick AM, Badcock DR (2006) Processing of global form and motion in migraineurs. *Vision Res* 46: 141–148.
- Khalil NM, Legg NJ, Anderson DJ (2000) Long term decline of P100 amplitude in migraine with aura. *J Neurol Neurosurg Psychiatry* 69: 507–511.
- Coleston DM, Chronicle E, Ruddock KH, Kennard C (1994) Precortical dysfunction of spatial and temporal visual processing in migraine. *J Neurol Neurosurg Psychiatry* 57: 1208–1211.
- Shepherd AJ (2000) Visual contrast processing in migraine. *Cephalalgia* 20: 865–880.
- Marcus DA, Soso MJ (1989) Migraine and stripe-induced visual discomfort. *Arch Neurol* 46: 1129–1132.
- Coleston DM, Kennard C (1995) Responses to temporal visual stimuli in migraine: The critical flicker fusion test. *Cephalalgia* 15: 396–398.
- Shepherd AJ, Palmer JE, Davis G (2002) Increased visual after-effects in migraine following pattern adaptation extend to simultaneous tilt illusion. *Spat Vis* 16: 33–43.
- Shepherd AJ (2001) Increased visual after-effects following pattern adaptation in migraine: A lack of intracortical excitation? *Brain* 124: 2310–2318.
- Palmer JE, Chronicle EP, Rolan P, Mulleners WM (2000) Cortical hyperexcitability is cortical under-inhibition: Evidence from a novel functional test of migraine patients. *Cephalalgia* 20: 525–532.
- Drummond PD (2005) Triggers of motion sickness in migraine sufferers. *Headache* 45: 653–656.
- Jan MM (1998) History of motion sickness is predictive of childhood migraine. *J Paediatr Child Health* 34: 483–484.
- Ungerleider LG, Desimone R, Galkin TW, Mishkin M (1984) Subcortical projections of area MT in the macaque. *J Comp Neurol* 223: 368–386.
- Tootell RB, Mendola JD, Hadjikhani NK, Ledden PJ, Liu AK, et al. (1997) Functional analysis of V3A and related areas in human visual cortex. *J Neurosci* 17: 7060–7078.
- Tootell RBH, Reppas JB, Kwong KK, Malach R, Born RT, et al. (1995) Functional analysis of human MT and related visual cortical areas using magnetic resonance imaging. *J Neuroscience* 15: 3215–3230.
- Annese J, Gazzaniga MS, Toga AW (2005) Localization of the human cortical visual area MT based on computer aided histological analysis. *Cereb Cortex* 15: 1044–1053.
- Aurora SK, Welch KM, Al-Sayed F (2003) The threshold for phosphenes is lower in migraine. *Cephalalgia* 23: 258–263.
- Mulleners WM, Aurora SK, Chronicle EP, Stewart R, Gopal S, et al. (2001) Self-reported photophobic symptoms in migraineurs and controls are reliable and predict diagnostic category accurately. *Headache* 41: 31–39.
- Welch KM (2003) Contemporary concepts of migraine pathogenesis. *Neurology* 61: S2–8.
- Leao AA (1944) Spreading depression of activity in cerebral cortex. *J Neurophysiol* 7: 359–390.
- Fabricius M, Fuhr S, Bhatia R, Boutelle M, Hashemi P, et al. (2005) Cortical spreading depression and peri-infarct depolarization in acutely injured human cerebral cortex. *Brain* 129: 778–790.
- Cao Y, Welch KMA, Aurora S, Vikingstad E (1999) Functional MRI-BOLD of visually triggered headache in patients with migraine. *Arch Neurol* 56: 548–554.
- Hadjikhani N, Sanchez del Rio M, Wu O, Schwartz D, Bakker D, et al. (2001) Mechanisms of migraine aura revealed by functional MRI in human visual cortex. *Proc Natl Acad Sci U S A* 98: 4687–4692.
- Kraig RP, Nicholson C (1978) Extracellular ionic variations during spreading depression. *Neuroscience* 3: 1045–1059.
- Lauritzen M (1987) Cerebral blood flow in migraine and cortical spreading depression. *Acta Neurol Scand Suppl* 113: 1–40.
- Okada YC, Lauritzen M, Nicholson C (1988) Magnetic field associated with spreading depression: A model for the detection of migraine. *Brain Res* 442: 185–190.
- Welch KM, Barkley GL, Ramadan NM, D'Andrea G (1992) NMR spectroscopic and magnetoencephalographic studies in migraine with aura: Support for the spreading depression hypothesis. *Pathol Biol (Paris)* 40: 349–354.
- Lauritzen M (1994) Pathophysiology of the migraine aura. The spreading depression theory. *Brain* 117: 199–210.
- Lauritzen M, Jorgensen MB, Diemer NH, Gjedde A, Hansen AJ (1982) Persistent oligemia of rat cerebral cortex in the wake of spreading depression. *Ann Neurol* 12: 469–474.
- Olesen J, Larsen B, Lauritzen M (1981) Focal hyperemia followed by spreading oligemia and impaired activation of rCBF in classic migraine. *Ann Neurol* 9: 344–352.
- Barkley GL, Tepley N, Simkins R, Moran J, Welch KM (1990) Neuro-magnetic fields in migraine: Preliminary findings. *Cephalalgia* 10: 171–176.
- Welch KM, D'Andrea G, Tepley N, Barkley G, Ramadan NM (1990) The concept of migraine as a state of central neuronal hyperexcitability. *Neurol Clin* 8: 817–828.
- Coppola G, Vandenheede M, Di Clemente L, Ambrosini A, Fumal A, et al. (2005) Somatosensory evoked high-frequency oscillations reflecting thalamo-cortical activity are decreased in migraine patients between attacks. *Brain* 128: 98–103.
- Schoenen J, Ambrosini A, Sandor PS, Maertens de Noordhout A (2003) Evoked potentials and transcranial magnetic stimulation in migraine: Published data and viewpoint on their pathophysiologic significance. *Clin Neurophysiol* 114: 955–972.
- Headache Classification Subcommittee of the International Headache Society (2004) The international classification of headache disorders. 2nd Ed. *Cephalalgia* 24: 9–160.
- Fischl B, Dale AM (2000) Measuring the thickness of the human cerebral cortex from magnetic resonance images. *Proc Natl Acad Sci U S A* 97: 11050–11055.
- Kuperberg GR, Broome MR, McGuire PK, David AS, Eddy M, et al. (2003) Regionally localized thinning of the cerebral cortex in schizophrenia. *Arch Gen Psychiatry* 60: 878–888.
- Rosas HD, Liu AK, Hersch S, Glessner M, Ferrante RJ, et al. (2002) Regional and progressive thinning of the cortical ribbon in Huntington's disease. *Neurology* 58: 695–701.
- Basser PJ, Mattiello JM, LeBihan D (1994) MR diffusion tensor spectroscopy and imaging. *Biophysical J* 66: 259–267.
- Basser PJ (1997) New histological and physiological stains derived from diffusion-tensor MR images. *Ann N Y Acad Sci* 820: 123–138.
- Beaulieu C (2002) The basis of anisotropic water diffusion in the nervous system—A technical review. *NMR Biomed* 15: 435–455.
- Kruit MC, Launer LJ, van Buchem MA, Terwindt GM, Ferrari MD (2005) MRI findings in migraine. *Rev Neurol (Paris)* 161: 661–665.
- Basser PJ, Mattiello J, LeBihan D (1994) Estimation of the effective self-diffusion tensor from the NMR spin echo. *J Magn Reson B* 103: 247–254.
- Pierpaoli C, Basser PJ (1996) Toward a quantitative assessment of diffusion anisotropy. *Magn Reson Med* 36: 893–906.
- Olesen J, Tfelt-Hansen P, Henriksen L, Larsen B (1981) The common migraine attack may not be initiated by cerebral ischaemia. *Lancet* 2: 438–440.
- Russell MB, Ulrich V, Gervil M, Olesen J (2002) Migraine without aura and migraine with aura are distinct disorders. A population-based twin survey. *Headache* 42: 332–336.
- Ranson R, Igarashi H, MacGregor EA, Wilkinson M (1991) The similarities and differences of migraine with aura and migraine without aura: A preliminary study. *Cephalalgia* 11: 189–192.
- Kruit MC, van Buchem MA, Hofman PA, Bakkers JT, Terwindt GM, et al. (2004) Migraine as a risk factor for subclinical brain lesions. *JAMA* 291: 427–434.
- Ayata C, Jin H, Kudo C, Dalkara T, Moskowitz MA (2006) Suppression of cortical spreading depression in migraine prophylaxis. *Ann Neurol* 59: 652–661.
- Filippi M, Cercignani M, Inglese M, Horsfield MA, Comi G (2001) Diffusion tensor magnetic resonance imaging in multiple sclerosis. *Neurology* 56: 304–311.
- Ciccarelli O, Werring DJ, Barker GJ, Griffin CM, Wheeler-Kingshott CA, et al. (2003) A study of the mechanisms of normal-appearing white matter damage in multiple sclerosis using diffusion tensor imaging evidence of wallerian degeneration. *J Neurol* 250: 287–292.
- Le Bihan D, Mangin JF, Poupon C, Clark CA, Pappata S, et al. (2001) Diffusion tensor imaging: Concepts and applications. *J Magn Reson Imaging* 13: 534–546.
- Bammer R, Augustin M, Strasser-Fuchs S, Seifert T, Kapeller P, et al. (2000) Magnetic resonance diffusion tensor imaging for characterizing diffuse and focal white matter abnormalities in multiple sclerosis. *Magn Reson Med* 44: 583–591.
- Wilson M, Tench CR, Morgan PS, Blumhardt LD (2003) Pyramidal tract mapping by diffusion tensor magnetic resonance imaging in multiple sclerosis: Improving correlations with disability. *J Neurol Neurosurg Psychiatry* 74: 203–207.
- Wang C, Stebbins GT, Nyenhuis DL, Detoleto-Morrell L, Freels S, et al. (2005) Longitudinal changes in white matter following ischemic stroke: A three-year follow-up study. *Neurobiol Aging* Nov 23 [epub ahead of print].
- Thomalla G, Glauche V, Weiller J (2005) Time course of wallerian degeneration after ischaemic stroke revealed by diffusion tensor imaging. *J Neurol Neurosurg Psychiatry* 76: 266–268.
- Werring DJ, Toosy AT, Clark CA, Parker GJ, Barker GJ, et al. (2000)

- Diffusion tensor imaging can detect and quantify corticospinal tract degeneration after stroke. *J Neurol Neurosurg Psychiatry* 69: 269–272.
64. O'Sullivan M, Barrick TR, Morris RG, Clark CA, Markus HS (2005) Damage within a network of white matter regions underlies executive dysfunction in CADASIL. *Neurology* 65: 1584–1590.
 65. Holtmannspotter M, Peters N, Opherk C, Martin D, Herzog J, et al. (2005) Diffusion magnetic resonance histograms as a surrogate marker and predictor of disease progression in CADASIL: A two-year follow-up study. *Stroke* 36: 2559–2565.
 66. Chabriat H, Pappata S, Poupon C, Clark CA, Vahedi K, et al. (1999) Clinical severity in CADASIL related to ultrastructural damage in white matter: In vivo study with diffusion tensor MRI. *Stroke* 30: 2637–2643.
 67. Takahashi M, Hackney DB, Zhang G, Wehrli SL, Wright AC, et al. (2002) Magnetic resonance microimaging of intraaxonal water diffusion in live excised lamprey spinal cord. *Proc Natl Acad Sci U S A* 99: 16192–16196.
 68. Tuch DS, Salat DH, Wisco JJ, Zaleta AK, Hevelone ND, et al. (2005) Choice reaction time performance correlates with diffusion anisotropy in white matter pathways supporting visuospatial attention. *Proc Natl Acad Sci U S A* 102: 12212–12217.
 69. Bengtsson SL, Nagy Z, Skare S, Forsman L, Forssberg H, et al. (2005) Extensive piano practicing has regionally specific effects on white matter development. *Nat Neurosci* 8: 1148–1150.
 70. Schmithorst VJ, Wilke M (2002) Differences in white matter architecture between musicians and non-musicians: A diffusion tensor imaging study. *Neurosci Lett* 321: 57–60.
 71. Flechsig P (1920) *Anatomie des menschliches Gehirn Ruckenmark auf mielogenetische Grundlage*. Leipzig: Georg Thieme.
 72. Bourne JA, Rosa MG (2006) Hierarchical development of the primate visual cortex, as revealed by neurofilament immunoreactivity: Early maturation of the middle temporal area (MT). *Cereb Cortex* 16: 405–414.
 73. Avoli M, Louvel J, Pumain R, Kohling R (2005) Cellular and molecular mechanisms of epilepsy in the human brain. *Prog Neurobiol* 77: 166–200.
 74. Woods RP, Iacoboni M, Mazziotta JC (1994) Brief report: Bilateral spreading cerebral hypoperfusion during spontaneous migraine headache. *N Engl J Med* 331: 1689–1692.
 75. Kraig RP, Dong LM, Thisted R, Jaeger CB (1991) Spreading depression increases immunohistochemical staining of glial fibrillary acidic protein. *J Neurosci* 11: 2187–2198.
 76. Petito CK, Morgello S, Felix JC, Lesser ML (1990) The two patterns of reactive astrocytosis in postischemic rat brain. *J Cereb Blood Flow Metab* 10: 850–859.
 77. Lipton RB, Ottman R, Ehrenberg BL, Hauser WA (1994) Comorbidity of migraine: The connection between migraine and epilepsy. *Neurology* 44: S28–32.
 78. Leniger T, von den Driesch S, Isbruch K, Diener HC, Hufnagel A (2003) Clinical characteristics of patients with comorbidity of migraine and epilepsy. *Headache* 43: 672–677.
 79. Ottman R, Lipton RB (1994) Comorbidity of migraine and epilepsy. *Neurology* 44: 2105–2110.
 80. Lipton RB, Pan J (2004) Is migraine a progressive brain disease? *JAMA* 291: 493–494.

Editors' Summary

Background. Migraine is a disabling brain disorder that affects more than one in ten people during their lifetimes. It is characterized by severe, recurrent headaches, often accompanied by nausea, vomiting, and light sensitivity. In some migraineurs (people who have migraines), the headaches are preceded by neurological disturbances known as “aura.” These usually affect vision, causing illusions of flashing lights, zig-zag lines, or blind spots. There are many triggers for migraine attacks—including some foods, stress, and bright lights—and every migraineur has to learn what triggers his or her attacks. There is no cure for migraine, although over-the-counter painkillers can ease the symptoms and doctors can prescribe stronger remedies or drugs to reduce the frequency of attacks. Exactly what causes migraine is unclear but scientists think that, for some reason, the brains of migraineurs are hyperexcitable. That is, some nerve cells in their brains overreact when they receive electrical messages from the body. This triggers a local disturbance of brain function called “cortical spreading depression,” which, in turn, causes aura, headache, and the other symptoms of migraine.

Why Was This Study Done? Researchers need to know more about what causes migraine to find better treatments. One clue comes from the observation that motion perception is abnormal in migraineurs, even between attacks—they can be very sensitive to visually induced motion sickness, for example. Another clue is that aura are usually visual. So could brain regions that process visual information be abnormal in people who have migraines? In this study, the researchers investigated the structure of the motion processing parts of the brain in people who have migraine with aura, in people who have migraine without aura, and in unaffected individuals to see whether there were any differences that might help them understand migraine.

What Did the Researchers Do and Find? The researchers used two forms of magnetic resonance imaging—a noninvasive way to produce pictures of internal organs—to examine the brains of migraineurs (when they weren't having a migraine) and healthy controls. They concentrated on two brain regions involved in motion processing known as the MT+ and V3A areas and first measured the cortical thickness of these areas—the cortex is the wrinkled layer of gray matter on the outside of the brain that processes information sent from the body. They found that the cortical thickness was increased in both of these areas in migraineurs when compared to healthy controls. There was no difference in cortical

thickness between migraineurs who had aura and those who did not, but the area of cortical thickening in V3A corresponded to the source of cortical spreading depression previously identified in a person who had migraine with aura. The researchers also found differences between the white matter (the part of the brain that transfers information between different regions of the gray matter) immediately below the V3A and MT+ areas in the migraineurs and the controls but again not between the two groups of migraineurs.

What Do These Findings Mean? This study provides new information about migraine. First, it identifies structural changes in the brains of people who have migraines. Until now, it has been thought that abnormal brain function causes migraine but that migraineurs have a normal brain structure. The observed structural differences might either account for or be caused by the hyperexcitability that triggers migraines. Because migraine runs in families, examining the brains of children of migraineurs as they grow up might indicate which of these options is correct, although it is possible that abnormalities in brain areas not examined here actually trigger migraines. Second, the study addresses a controversial question about migraine: Is migraine with aura the same as migraine without aura? The similar brain changes in both types of migraine suggest that they are one disorder. Third, the abnormalities in areas MT+ and V3A could help to explain why migraineurs have problems with visual processing even in between attacks. Finally, this study suggests that it might be possible to develop a noninvasive test to help doctors diagnose migraine.

Additional Information. Please access these Web sites via the online version of this summary at <http://dx.doi.org/10.1371/journal.pmed.0030402>.

- The MedlinePlus encyclopedia has several pages on migraine
- The US National Institute of Neurological Disorders and Stroke offers patient information on migraine and other headaches
- The NHS Direct Online contains patient information on migraine from the UK National Health Service
- MAGNUM provides information from The US National Migraine Association
- The Migraine Trust is a UK charity that supports research and provides support for patients
- The Migraine Aura Foundation is a site about aura that includes a section on art and aura