

PERISTALSIS IN REVERSED LOOPS OF BOWEL*

A. O. SINGLETON, JR., M.D. AND E. B. ROWE, M.D.

GALVESTON, TEXAS

FROM THE DEPARTMENT OF SURGERY, UNIVERSITY OF TEXAS MEDICAL BRANCH, GALVESTON, TEXAS

IN RESTORING THE continuity of the intestinal tract after resecting segments of bowel for adhesive peritonitis one may be confronted with a seemingly hopeless maze. At times the operator may find it difficult to determine whether he has oriented a loop of bowel in its normal direction. Is peristalsis limited to the original direction of flow? Does the reversal of the ends of a section of bowel act as an obstruction? In bridging defects with loops of bowel, for example, after oesophagectomy, is it hazardous to attempt to reverse the flow in the gut?

In attempting to settle these questions, experiments were carried out in 20 dogs under intravenous nembutal anesthesia. Segments of small bowel were isolated, ranging from three inches to the entire length of the intestine from duodenum to cecum. Care was taken to preserve the blood supply. The shorter segments were located both in the jejunum and ileum. After dividing the bowel the ends of the loops were reversed and the continuity of the bowel restored. When the bowel was examined at intervals of five days to three months, either at death or on sacrificing the animal, dilatation and hypertrophy of the bowel proximal to the proximal anastomosis and extending several inches past the line of suture were uniformly found (Fig. 1). On observation, peristaltic waves could be seen traveling down the bowel to the

proximal suture line. Peristaltic waves in the reversed loop appeared to travel in the original direction of the bowel and in the opposite direction to peristalsis in the non-rotated portion of the small intestine.

It was noted that three dogs lived as long as three months, with an 18-inch segment reversed. Therefore, the obstruction could not have been complete. Where 24-inch or longer segments were reversed, the animals didn't live longer than five days. Two animals which had had a six-inch loop reversed showed no proximal dilatation at the end of one month; at this time other six-inch loops more distal in the tract were rotated and when sacrificed one month later, the characteristic dilatation was found on both sides of the proximal suture lines of each segment. In no case did rotating of the bowel interfere with the blood supply.

Two animals with reversed segments in the upper jejunum were followed by fluoroscopy and roentgenograms, which confirmed the evidence of partial obstruction at the site of the rotated loop. Barium was injected through a stomach tube, but none was seen to pass through the anastomosis immediately. One animal with a 12-inch segment of rotated intestine had passed all barium into the colon after 20 hours (Fig. 2), but the one with an 18-inch segment still had some retention in the small bowel at this time (Fig. 3). Films taken three days later showed no barium present.

We have also attempted to rotate loops of large bowel in the dog. Here the short

* Presented before the Southern Surgical Association, Hot Springs, Virginia, December 10, 1953.

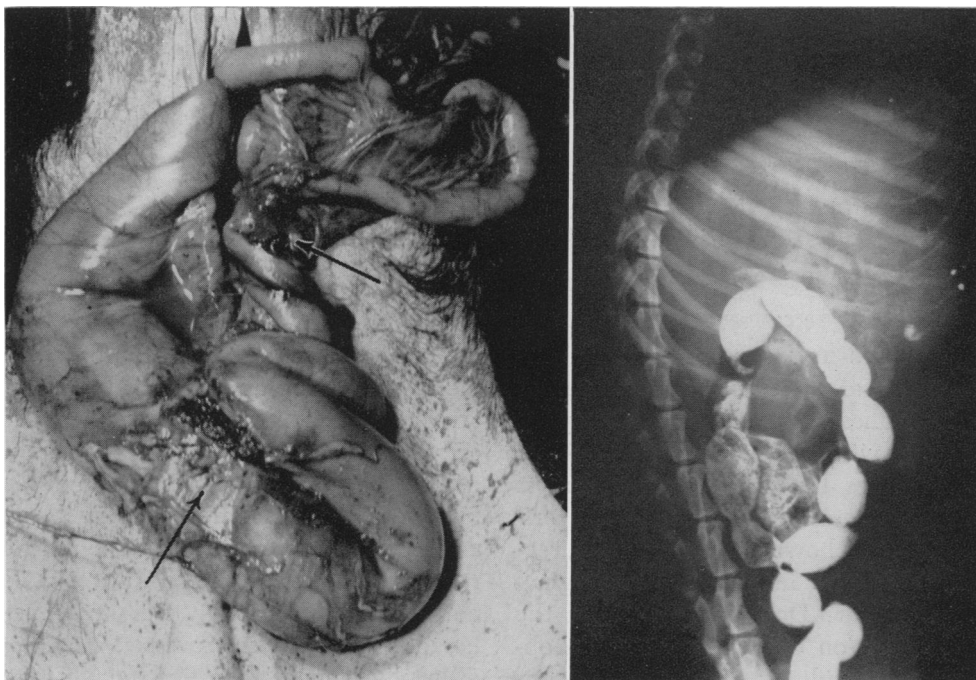


FIG. 1. (Dog #11.) Twelve-inch segment of bowel reversed near ligament of Treitz two months previously. Lower arrow points to proximal suture line, upper arrow to distal. Note dilatation and hypertrophy proximal and for a short distance distal to proximal anastomosis.

FIG. 2. (Dog #11.) Abdominal film taken two weeks after reversing bowel and 20 hours after giving barium by mouth. Note barium has passed into colon.

mesentery and poorer blood supply, together with the other inherent difficulties of colon surgery, resulted in leakage at the anastomosis site, with fatal peritonitis in most cases. Only in animals prepared with intestinal antiseptics and purges were there survivors. The rotated loops average about five inches in length (Fig. 4). When the animals were sacrificed, we found the same picture as in the small bowel, with dilatation above the upper suture line extending up into the terminal ileum as well as for several inches distal to the proximal suture line. With the short colon loops used, the dilatation usually extended to the distal suture line.

Clinically, antiperistaltic loops of colon have been used to bridge defects in the esophagus successfully, as illustrated in the following case report.

T. N., a 37-year-old white female, was admitted to the John Sealy Hospital in March, 1951, with an esophageal bronchial fistula due to lye poisoning. After esophagectomy, the defect had been bridged with a transplanted jejunal loop, but this had failed to survive because of vascular insufficiency. In November, 1952, a loop of transverse colon was used to bridge the gap in the esophagus. The colon was transected just proximal to the middle colic artery and proximal to the left colic artery, and the continuity of the colon was re-established with a two-layer anastomosis. The proximal end of the isolated loop of colon was then anastomosed to the fundus of the stomach, and the distal end brought through the diaphragm along the anterior mediastinal aspect of the left pleural space, into the left side of the neck. About two weeks later the cervical esophagus was joined to the colon segment, the colon bridge being then made in an antiperistaltic fashion (Fig. 5). When last seen in July, 1953, she was still taking liquids and food without any difficulty.

Other similar antiperistaltic colon loop bridges which worked satisfactorily have been described in the literature.²

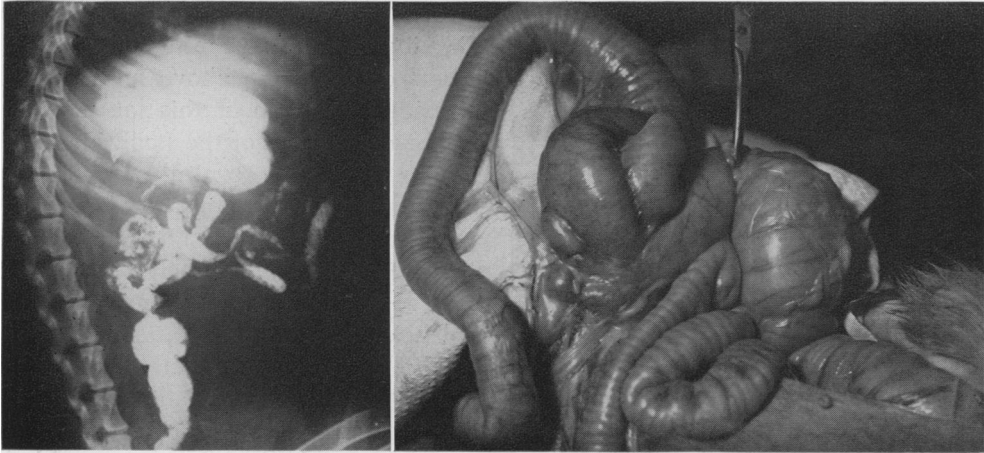


FIG. 3. (Dog #12.) Abdominal film taken 20 hours after barium meal in animal with 18-inch segment of bowel reversed. Note retention of barium in small bowel above anastomosis.

FIG. 4. (Dog #16.) Five-inch loop of colon reversed 3 weeks previously. Instruments point to anastomoses. Note dilatation of loop extending back into terminal ileum. Animal had been eating and was in good health.

DISCUSSION

Two main types of activity in the small bowel have been reported:⁴ one a rhythmic segmental action, and the other a series of peristaltic waves or rushes. The former aids in mixing the bowel content, thus enabling better digestion and absorption of food, while the latter effects the progression of material down the bowel. The peristaltic wave may occur as a slowly advancing contraction (1 to 2 cm. per minute), extending 4 or 5 cm., or as a swift movement called the peristaltic rush, which may extend along the entire bowel. A swaying or pendular motion has also been described. The segmental movements are apparently myogenic in origin, since they occur in the isolated intestine and where the local nerve supply has been paralyzed with drugs. The frequency of contraction varies inversely with the distance from the stomach. There is apparently a metabolic gradient from above downwards, the upper portions having a higher metabolism and a higher rate of spontaneous contractions or rhythmicity than the lower parts.

Bayliss and Starling's classical explanation of peristalsis has been that stimulation

of the gut causes contraction above the point of stimulus and relaxation below. The peristaltic contraction involves the cooperation of Auerbach's plexus, independent of the central nervous system. Alvarez¹ believes that the bowel is polarized so that waves travel more easily in one direction than another, the direction being determined by the metabolic gradient of the intestine. He reasons that the theory of Bayliss and Starling is too simple an explanation for this complicated process, and that actually many mechanisms are at work in controlling peristalsis. It is his opinion that any stimulus which raised the tonus, activity and irritability of a segment of bowel tends to slow the progress of waves and material approaching the segment on the oral side and to hurry the progress of material leaving it on the caudal side.

Mall⁵ and others have reported that if a short length of gut is separated, reversed and re-anastomosed, peristaltic waves started above the area cannot travel down the reversed gut, and dilatation of the proximal bowel occurs. When the reactions of the local nervous system are inhibited with drugs, however, material will pass forward

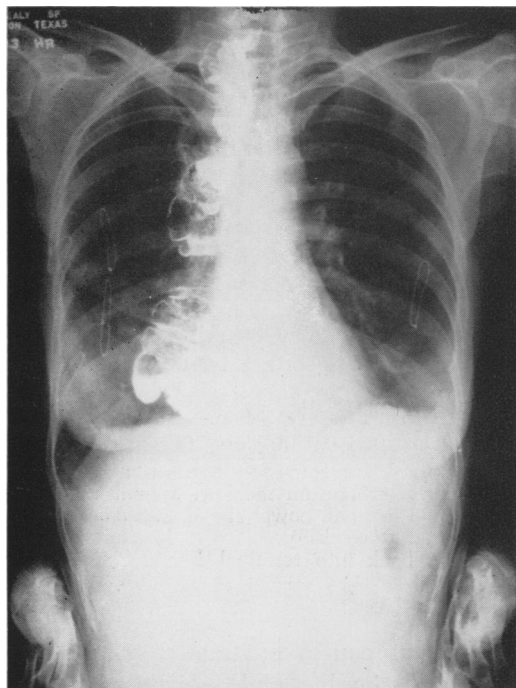


FIG. 5. Antiperistaltic loop of colon used to bridge esophageal defect outlined by barium swallow (case report).

through the segment as local contractions attempting to push food up and down will result in the bowel contents being moved distally against the least resistance.

Mall stated that reversing a segment of intestine was fatal in dogs. Hammer and Dragstedt³ have not found this to be a fatal procedure. Hammer reversed loops of duodenum in attempting to create peptic ulcers in the dog. He found that there was marked dilatation of the duodenum and stomach, with a delay in emptying time up to four days, as compared with a normal of from two to four hours. Alvarez has compared a reversed loop of bowel to a pipe line running up hill where fluids pass through easily, but solids with difficulty. We noted that in our animals, hair and other solid material was often found impacted in the reversed loop.

Rienhoff⁶ has reported using antiperistaltic loops of jejunum in bridging esophageal

defects without any apparent ill effects. Gravity and the intermittent filling of the reversed loop from above may make this procedure feasible at this location.

The movements of the small intestine are also subject to the central nervous system. Stimulation of the vagus has the effect of producing an initial inhibition of the small intestine, followed by increased irritability and contractions, while stimulation of the splanchnics caused relaxation.⁷

The structure of the large bowel varies a great deal in different animals, depending on the feeding habits of each. The colon of carnivora is short and narrow, with little or no cecum. In contrast, herbivora have a well developed, large intestine, with sacculated walls and large cecum. Although the length of the small intestine is relatively the same, the length of the colon varies greatly in different species. Thus, while the cat's bowel is about three times its length, the sheep's intestine is 27 times as long. The large intestine in meat eaters has very little effect on digestion and absorption. In vegetable feeders, the chief parts of digestion may take place in the cecum, where the cellulose walls of their food is broken down by the action of bacteria or by cellulose digestive enzymes in the vegetable cells themselves. Man occupies a somewhat intermediate position between these two classes.

The large intestine shows very little activity as compared with the small bowel. It fills more or less passively by material flowing through the ileocecal valve. The progress of the contents along the large bowel is not a slow, regular one, but occurs as a result of a few rather sudden powerful contractions, known as mass peristalsis, initiated by the taking of food or by defecation. The contents of one portion of the bowel may be entirely moved from cecum to transverse colon to sigmoid in a few minutes. In certain animals, so called antiperistaltic waves take place, moving material

in the opposite direction. The low grade peristaltic activity in large bowel would theoretically make it more desirable than small bowel in antiperistaltic bridges.

SUMMARY

The question is raised as to the importance of maintaining the continuity of the bowel in the original direction when performing anastomoses. Our experiments tend to confirm the experience of others that in dogs, the direction of peristalsis in a loop of bowel remains constant, and suggest that in restoring continuity of bowel, the normal position in regard to direction of flow be maintained for maximum efficiency in the passage of material through the intestinal tract.

BIBLIOGRAPHY

- ¹ Alvarez, W. C.: *An Introduction to Gastro-Enterology*. Paul B. Hoeber, Inc., New York, 1950.
- ² Camara-Lopez, L. H.: The Intrathoracic Use of the Large Bowel After Subtotal Esophagectomy for Carcinoma. *J. Thoracic Surg.*, **25**: 205, 1953.
- ³ Hammer, J. M., Frank Visscher and E. J. Hill: Experimental Gastrojejunal Ulcers Produced by Reversing the Duodenum. *Arch. Surg.*, **67**: 23, 1953.
- ⁴ McLeod, J. J. R.: *Physiology in Modern Medicine*, p. 486-491, 7th Ed. The C. V. Mosby Company, St. Louis, 1935.
- ⁵ Mall, F. P.: Reversal of the Intestine. *Johns Hopkins Hospital Reports*, **1**: 93, 1896.
- ⁶ Reinhoff, W. F.: Intrathoracic Esophagojejunostomy for Lesions of the Upper Third of the Oesophagus. *Southern M. J.*, **39**: 928, 1946.
- ⁷ *Starling's Principles of Human Physiology*, pp. 603-612, 6th Edition, Lea & Febiger, Philadelphia, 1933.