

Intravascular Thrombi and the Intestinal Factor of Irreversible Shock *

ROBERT M. HARDAWAY, COLONEL, MC,** DONALD G. MCKAY, M.D. †

*From the U. S. Army Hospital, Fort Belvoir, Virginia, and the U. S. Army Hospital,
Frankfurt, Germany*

IT has been shown that irreversible shock in dogs is accompanied by autopsy findings of hemorrhagic necrosis and congestion of bowel mucosa.^{12-14, 21} It has also been shown that irreversible shock is accompanied by liver damage.^{5, 6, 14} Attempts have been made to prevent this irreversible shock by protecting the liver.⁵ It is the purpose of this paper to show that this type of irreversible shock can be prevented by preventing the gastro-intestinal lesions, and that these lesions can be caused by intravascular capillary thrombi.

It was shown^{6, 7, 13, 14} that hemorrhagic necrosis of the gastro-intestinal tract and shock could be produced by an episode of intravascular clotting brought on by an intra-aortic injection in the dog of incompatible (human) blood. The intracapillary thrombi caused infarction of the superficial mucosa (Fig. 1-4). This occurred only in dogs which had had a laparotomy and a series of kidney biopsies.^{6, 14} The dogs which had the intra-aortic injection of incompatible (human) blood without laparotomy all survived, while dogs which had the same procedure plus the laparotomy and kidney biopsies all died.

It was theorized that the laparotomy and kidney biopsy caused a certain amount of compensated shock with constriction of

visceral arterioles and capillary dilatation. This caused a marked slowing of blood in the capillary. When to this stagnant blood was added a clotting agent (incompatible blood^{6, 14}) clotting occurred. The present paper reports the results of experiments designed to prevent the intravascular capillary thrombosis and resulting ischemic gangrene of the superficial mucosa of the bowel by protecting the bowel by pinching off the superior mesenteric artery during the intra-aortic injection of incompatible blood, or by heparin.

Materials and Methods

Nineteen mongrel dogs were anesthetized with sodium pentobarbital. A laparotomy was performed and the left kidney freed so that it was attached only by its artery vein and ureter. Both femoral arteries were exposed and a polyethylene catheter was inserted in each until the tip reached the level of the diaphragm. One catheter was used to inject 4 cc. per pound of dog of incompatible (human) blood and the other used to record arterial pressure.⁷ The injection was given. Biopsies of the left kidney were taken at intervals of 15, 30, 60 and 120 minutes after the transfusion. At three hours the left kidney was removed.†† Two variations of the experiment were performed. In Group A (8 dogs) the superior mesenteric artery was not clamped during the injection of incompatible blood (5 to 10 min.). In Group B (11 dogs) it was. A single dog in

* Submitted for publication October 26, 1958.

** Chief General Surgery Service, Martin Army Hospital, Fort Benning, Georgia.

† Of the Research Laboratory, Department of Pathology, Boston Free Hospital for Women, and the Department of Pathology, Harvard Medical School, Boston.

†† Kidney and blood pressure studies are reported in other papers.⁶⁻⁸

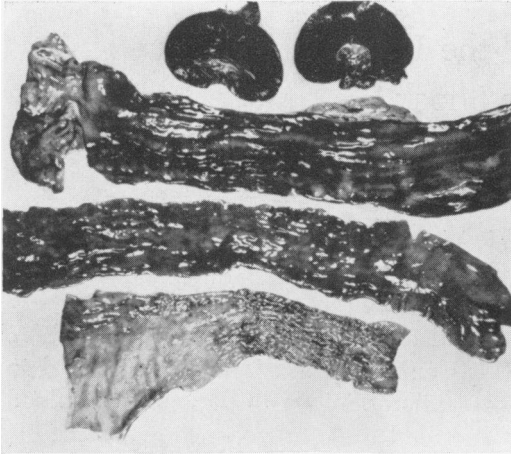


FIG. 1. Kidneys (above), duodenum (second), ileum (third) and colon (below) of a dog given incompatible (human) blood intra-aortically without occlusion of the superior mesenteric artery. Note the hemorrhagic areas are most prominent in the duodenum but also in the ileum. There is minimum hemorrhagic mucosa in the large bowel.

Group A was given 10 mg. per Kg. of heparin IA before the injection of blood.

Results

Group A. Of the eight dogs all, except the heparinized dog, died within 24 hours

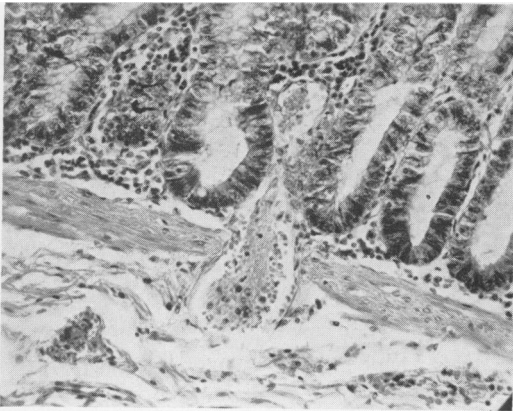


FIG. 2. High-power view of the junction of the mucosa and submucosa of a dog given an intra-aortic injection of incompatible blood without temporary occlusion of the superior mesenteric artery. Note the thrombus in a small vessel which is penetrating the muscularis mucosa. This is the earliest histologic detectable change in the development of the hemorrhagic mucosa. There is as yet no necrosis of the mucosa.

of irreversible shock.¹³ Some had a bloody diarrhea.

At autopsy all seven showed a hemorrhagic necrosis of the gastro-intestinal mucosa, most marked in the duodenum and small bowel but occurring from the stomach to rectum (Fig. 1). The entire bowel was filled with large quantities of a hemorrhagic fluid. Microscopically there were numerous capillary thrombi in the intestinal mucosa with overlying hemorrhagic necrosis of the mucosa with pseudomembrane formation (Fig. 2-4). There were also thrombi in the kidney, liver and lungs. The heparinized dog survived.

Group B. Of the 11 dogs, only one died within 24 hours. Autopsy of the latter showed severe hemorrhagic necrosis of the gastro-intestinal tract primarily in the duodenum (Fig. 5). Of the remaining ten, six died on the fourth or fifth day of uremia^{8, 9} with BUN levels ranging up to 212 mg.%. Autopsy showed only mild red streaks in the intestinal mucosa, primarily in the colon. Two others were sacrificed after a few days of anuria when they started to put out urine. Autopsy showed essentially normal bowel mucosa. Two others survived with few symptoms.

Discussion

The fact that the unheparinized dogs in Group A all died within a few hours with marked gastrointestinal lesions, whereas of the Group B dogs only one died in this situation, points strongly to an association between irreversible shock and the hemorrhagic lesion in the gastro-intestinal mucosa. The bowel mucosa was associated with intracapillary thrombosis in our experiments, and it would seem that the necrosis is secondary to the thrombosis with resultant ischemia. Lillehei¹² demonstrated that hemorrhagic bowel lesions and death from irreversible shock, following bleeding of dogs into a reservoir, could both be prevented by maintaining superior mesenteric artery pressure at normal levels by

blood from donor dogs, while the systemic blood pressure was maintained at 35 mm. Hg for five hours. Results had been uniformly fatal without the superior mesenteric artery perfusion even after return of the entire blood volume.

It is possible that the giving of heparin, 20 mg. per Kg., to donor dogs helped prevent thrombi formation. No mention is made of thrombi in these experiments. However it has been shown that hemorrhagic shock is associated with the formation of intravascular thrombi,^{3, 4} and can be prevented by preventing intravascular thrombi with heparin.^{4, 7} The association of hemorrhagic gastro-intestinal lesions with dramatic, severe and treatment-resistant shock has been recently shown in human cases of pseudomembranous enterocolitis¹⁰ (Fig. 6). The pathologic picture of the bowel in these cases is quite similar to the dog lesions produced in the present experiments.¹³ The association between fatal clinical hypovolemic shock and hemorrhagic intestinal lesions was first reported by Billroth¹ in 1867. After an unsuccessful attempt to remove a large goiter, his patient developed melena and died with multiple duodenal ulcerations. Klemperer *et al.*,¹¹ in describing hemorrhagic gastro-intestinal lesions after fatal shock, attributed them to arteriolar vasospasm causing mucosal necrosis. Others^{2, 19, 20} attributed the intestinal lesions in fatal shock cases to retrograde emboli from thromboses in the omentum.

The mechanism of production of irreversibility and death by the bowel lesions is probably the loss of quantities of hemorrhagic fluid into the lumen of the bowel.¹⁵ In our Group A dogs the intestine at autopsy was filled with large quantities of hemorrhagic fluid and some dogs had had a bloody diarrhea. It has been shown¹⁷ that removal of the small bowel (thus preventing this loss of bloody fluid) will prevent death in these animals. It has also been shown¹⁶ that blood flow to the intestinal tract is markedly and disproportion-

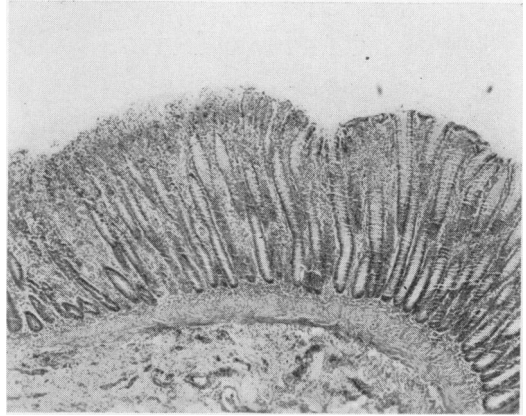


FIG. 3. Section of ileum of a dog dying after an incompatible transfusion into the aorta. On the right, the mucosa is intact. On the left, the mucosa shows a superficial layer of necrosis and hemorrhage. A thrombus is visible in a vessel in the mucosa on the left.

ately reduced during hemorrhagic shock. This is probably due to obstruction of blood flow by thrombi in the liver and bowel.⁷ The obstructive effect of the thrombi is probably greatly increased by associated vascular spasm brought on by serotonin released from clumped platelet thrombi.¹⁸

Reversible shock occurring in dogs after the intra-aortic injection of amniotic fluid may be prevented by heparin which pre-

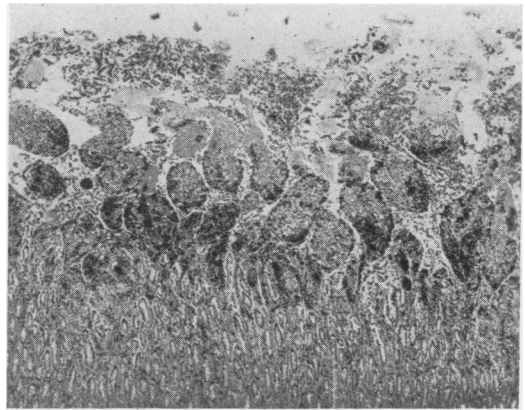


FIG. 4. Fully developed lesion in the jejunum of a dog which died after an intra-aortic injection of incompatible blood. The dark patches are masses of red blood cells. The tips of the villi are necrotic and large masses of fibrin lie free in the lumen surrounded by epithelial cells and leukocytes. Blood and serum are lost freely from this surface.

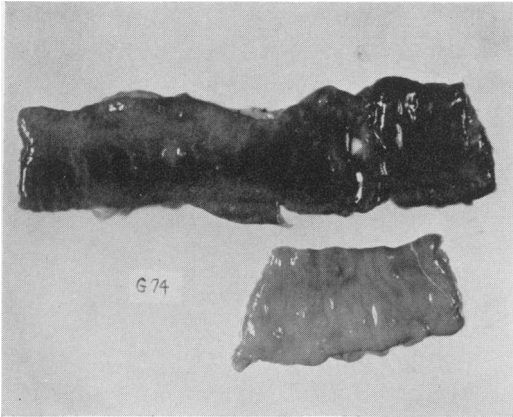


FIG. 5. Duodenum (above), and ileum (below) of the one dog in Group B which died after an intra-aortic transfusion of incompatible blood. During the transfusion, the superior mesenteric artery was occluded. Note that the ileum (below) was almost completely protected from the development of the hemorrhagic necrosis, while the upper duodenum (upper right) showed a severe hemorrhagic necrosis.

vents the formation of lung and hepatic thrombi.⁷ This type of reversible shock³ is apparently caused by a decreased cardiac output secondary to: 1) acute cor pulmonale due to capillary thrombi in the lung and 2) damming of portal venous return by thrombi in the liver. Serotonin, released from platelet thrombi, probably increases the blockage in the lung and liver through its vasoconstrictor action.¹⁸ The finding of thrombi in human autopsy cases is rare, possibly due to the activation of fibrinolysins.

Summary

1. The intra-aortic injection of incompatible (human) blood into dogs with accompanying laparotomy and kidney biopsy consistently causes death in a few hours with hemorrhagic necrosis of the mucosa of the bowel.

2. This hemorrhagic necrosis is apparently due to intravascular thrombi with resulting infarction.

3. These fatal lesions may be prevented by protecting the bowel by occluding the superior mesenteric artery during the intra-aortic injection or by heparin.

Conclusion

There is evidence that both reversible and irreversible shock can be caused by intravascular thrombi in the following manner:

a) Reversible shock may be due to a decreased cardiac output secondary to

1) acute cor pulmonale due to blockage of pulmonary capillaries with thrombi and associated serotonin-produced vascular spasm.

2) damming of blood in the portal system due to thrombi in the liver and associated vascular spasm.

b) Irreversible shock may be due to a loss of blood and serum into the gastrointestinal tract secondary to a hemorrhagic necrosis of the bowel mucosa caused by an episode of intravascular clotting in the bowel mucosa and submucosa.

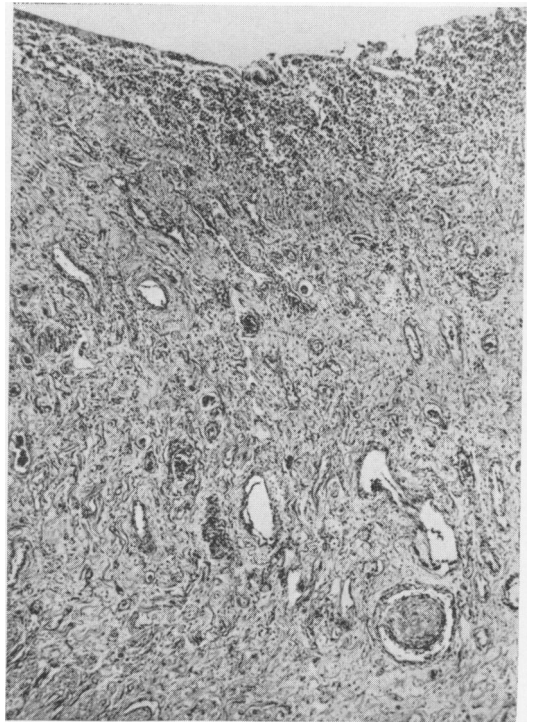


FIG. 6. Ileum of a patient who died suddenly postoperatively after the sudden onset of severe and irreversible shock. Note the complete hemorrhagic necrosis of the mucosa and a large thrombus in the lumen of a vessel in the mucosa. This case is being reported elsewhere.¹⁰

References

1. Billroth, CAT Wien. med. Wchnschr., 17: 705, 1867.
2. Busse, W.: Arch. klin. Chir., 76:122, 1905.
3. Crowell, J. W., *et al.*: The Mechanism of Death After Resuscitation Following Acute Circulatory Failure. Surgery, 38:696, 1955.
4. —, *et al.*: In Vivo Coagulation, a Probable Cause of Irreversible Shock. Am. J. Physiol., 183:565, 1955.
5. Frank, H. A., A. M. Seligman and J. Fine: The Prevention of Irreversibility in Hemorrhagic Shock in *Vivi*-perfusion of the Liver. J. Clin. Invest., 29:826, 1951.
6. Hardaway, R. M., *et al.*: Pathologic Study of Intravascular Coagulation Following Incompatible Transfusion in Dogs. I. Intravenous Injection. Am. Jour. of Surg., 91:24, 1956.
7. — and D. G. McKay: Disseminated Intravascular Coagulation—a Cause of Shock. Ann. Surg., 149:462, 1959.
8. — and D. G. McKay: Changes in the Dog Kidney Produced by Incompatible Blood Transfusion. A. M. A. Arch. of Surg., 78: 565, 1959.
9. — and D. G. McKay: Production of Lower Nephron Nephrosis in Dogs by Means of an Episode of Intravascular Clotting. Surgical Forum, Clinical Congress, American College of Surgeons, Chicago, 1958.
10. — and D. G. McKay: Pseudomembranous Enterocolitis: Are Antibiotics Wholly Responsible? A. M. A. Arch. of Surg., 78:446, 1959.
11. Klemperer, P., *et al.*: The Gastrointestinal Manifestation of Shock. Am. J. Digest. Dis., 7:410, 1940.
12. Lillehei, R. C.: The Intestinal Factor in Irreversible Hemorrhagic Shock. Surgery, 42: 1043, 1957.
13. McKay, D. G., R. M. Hardaway, G. H. Wahle and R. M. Hall: The Experimental Production of Pseudomembranous Enterocolitis by Means of Thrombosis of Intestinal Capillaries. A. M. A. Arch. Intern. Med., 95:779, 1955.
14. —, *et al.*: Pathologic Study of Intravascular Coagulation Following Incompatible Transfusion in Dogs. II. Intra-aortic Injection. Am. Jour. of Surg., 91:32, 1956.
15. McRae, I. M.: The Role of the Small Intestine in Hemorrhagic Shock. Surgical Forum, American College of Surgeons Clinical Congress, Chicago, 1958.
16. Overton, R. C., *et al.*: The Effect of Hemorrhagic Shock on Intestinal Blood Flow. Surgical Forum, American College of Surgeons Clinical Congress, Chicago, 1958.
17. Powers, L. H.: Intestinal Factor in Irreversible Hemorrhagic Shock. Surgical Forum, American College of Surgeons Clinical Congress, Chicago, 1958.
18. Sullenberg, J. W., *et. al.*: A Study of the Pressor Effects of Serotonin and Its Possible Role in Massive Thromboembolism. Surgical Forum, American College of Surgeons Clinical Congress, Chicago, 1958.
19. von Eiselsberg, F.: Arch. klin. Chir., 59:837, 1899.
20. von Winiwarer, J. R.: Arch. klin. Chir., 95: 161, 1911.
21. Wiggers, C. J.: Physiology of Shock. New York, Commonwealth Fund, p. 413, 1950.