

# Giant Choledochal Cyst \*

## Report of a Case Successfully Treated by Roux-en-Y Choledochocyst-jejunostomy

WILLIAM J. FARRELL, M.D.

*From the Department of Surgery, Ellis Hospital, Schenectady, N. Y.*

CONGENITAL dilation of the common bile duct is a rare anomaly seldom encountered in surgical practice. Although it was first noted by Vater in 1723 as quoted in Davis' paper,<sup>8</sup> Todd reported the first case in 1818 (as quoted by Dennison<sup>9</sup>). The first successfully treated case, that of Williams and Smith, was reported in 1929 as quoted by Burgess and Cherry.<sup>5</sup> Since then there have been a number of individual case reports noted in the literature: Davis,<sup>8</sup> Bodart *et al.*,<sup>4</sup> Trnka,<sup>24</sup> Caussade *et al.*,<sup>7</sup> Burgess and Cherry,<sup>5</sup> Ugelli,<sup>25</sup> Hamilton,<sup>11</sup> and Allen.<sup>1</sup> Several reviews of the literature have also appeared: Zinniger and Cash in 1932,<sup>27</sup> Shallow, Eger, and Wagner in 1943<sup>19</sup> and in 1946,<sup>20</sup> Smith in 1942,<sup>22</sup> Altar and Obeid in 1955,<sup>2</sup> and Cantley in 1956.<sup>6</sup> Gross<sup>10</sup> reviewed the results of 52 cases treated in childhood which he collected from the literature, and also summarized results in nine cases treated at the Children's Hospital in Boston. In 1955, Shocket and his associates<sup>21</sup> reported six cases from the Mayo Clinic records. In all 217 cases have been reported prior to the case reported here.

### Etiology

The cause of this anomaly is not known. It is congenital and probably represents an inherent weakness in the wall of the common duct and differs from ductal dilation due to obstruction in that the common duct or some part of it between the liver hilus

and the ampulla is affected only. The intrahepatic biliary ducts and the gall bladder, if present, are not dilated. Once dilation begins, the tension created causes kinking in the ductal outlet producing further obstruction. This creates increased intraluminal pressure and further dilation. Thus a vicious cycle is produced. Other theories have been advanced as to the cause of this anomaly. All are largely speculative. Cantley<sup>6</sup> lists them in his recent review, as does Gross in his text on Surgery in Infancy and Childhood.<sup>10</sup> These cysts vary considerably in size containing from a few hundred cubic centimeters of bile to several liters. The largest which contained 8,000 cubic centimeters was reported by Reel and Burrell in 1922.<sup>16</sup> Our case contained a measured 2,600 cubic centimeters. Despite the secondary obstructive factor, which should cause biliary inspissation and sludging, stones have been reported in but one case, that of Trnka.<sup>24</sup> I know of one unreported case which contained stones, MacMillan.<sup>13</sup> Cholangitis, jaundice, hepatic dysfunction and cirrhosis are common sequelae.

### Diagnosis

Most cases exhibit a triad of a mass, jaundice, and pain. The majority of patients are children or teenagers. Because the triad of symptoms is common to many other affections of the biliary tree which are more common than a choledochal cyst, a correct preoperative diagnosis is seldom made. One must be aware of this condition when it is

\* First submitted for publication October 14, 1957; resubmitted February 18, 1959.

encountered at operation, as the best treatment is some type of biliary shunt rather than excisional treatment.<sup>10</sup> Attempts at excision have usually proven hazardous.

This anomaly has never been demonstrated radiographically by the use of oral or intravenous choledochograms.<sup>6</sup> X-ray studies of Barium swallows may reveal gastric or duodenal displacement depending on the size of the cyst. The diagnosis is usually made at laparotomy when bile is aspirated from the cyst.

### Differential Diagnosis

In the differential, one would consider primarily pancreatic cysts, echinococci cysts and hepatic cysts. Other right sided masses which conceivably could resemble this anomaly would be hepatic tumors, right renal tumors, right retroperitoneal tumors, biliary tumors and duodenal reduplications.

### Treatment

Unless choledochal cysts are operated on, repeated bouts of cholangitis, eventual hepatitis, cirrhosis and death occur. Gross reported nine cases which were not operated upon, and all died.<sup>10</sup> Altar and Obeid reported 22 cases not operated upon, and all died either from biliary peritonitis secondary to rupture of the cyst or from suppurative cholangitis and cirrhosis.<sup>2</sup>

The type of surgical treatment to be carried out is, in the literature, a matter of difference of opinion. It is generally agreed that some type of shunt, rather than excision or external drainage, is the best treatment. Although cyst excision with subsequent reconstruction of the common duct over a T-tube or excision with hepatico-enterostomy has been reported successful by Shallow *et al.*,<sup>19</sup> McLaughlin,<sup>14</sup> McWhorter,<sup>15</sup> Wrightson<sup>26</sup> and Dennison,<sup>9</sup> it is conceded by Gross<sup>10</sup> and by Shackelford<sup>18</sup> that attempts at excision are more hazardous and no more satisfactory than shunting procedures. Excisional attempts have an 80 to 90 per cent mortality rate.

Attempts at trans-abdominal percutaneous aspiration, external drainage, and cyst marsupialization have likewise been dangerous. Forty-two of 50 patients who had external drainage as reported by Altar and Obeid died.<sup>2</sup> All five whose cysts were aspirated likewise expired. In Gross' tabulation of attempts at some type of drainage, 25 of 30 such treated patients died.<sup>10</sup>

Choledochocyst-enterostomy by choledochocyst-duodenostomy or Roux-en-Y choledochocyst-jejunostomy with jejuno-jejunostomy is a disputed point. The latter procedure was successful in our case. Gross has been the main exponent of choledochocyst-duodenostomy. He does not agree that the Roux-en-Y procedure is necessary to prevent intestinal regurgitation into the cyst, but a review of his reported case records would seem to belie this opinion. Of eight cases subjected to a definitive procedure, seven survived. One patient who was 16 years postoperative had experienced repeated bouts of cholangitis and jaundice. In another on whom a postoperative barium swallow was done to determine the amount of postoperative cyst shrinkage by differences of degree in gastroduodenal displacement, barium easily entered the cyst via the choledochocyst-duodenostomy.<sup>10</sup> If barium entered so easily, why not intestinal contents? Pearse and Radakovitch report a 12 per cent incidence of cholangitis with Gross' preferred anastomosis. Possibly, however, cholangitis following choledochocyst-duodenostomy is the result of an obstruction at the anastomosis line thus causing biliary inspissation and cholangitis. I feel, however, that regurgitation of intestinal contents into the cyst could also act as an etiologic agent to cholangitis. The results of reported Roux-en-Y procedures are very good. Shocket *et al.* reported a 3,000 cc. cyst treated by the Roux-en-Y method. Altar and Obeid report nine cases so treated with excellent results.<sup>2</sup> Similar case reports have been recorded by Strohl and Sarver,<sup>23</sup> Rogers and Priestley,<sup>17</sup> Keeley<sup>12</sup> and Arch-

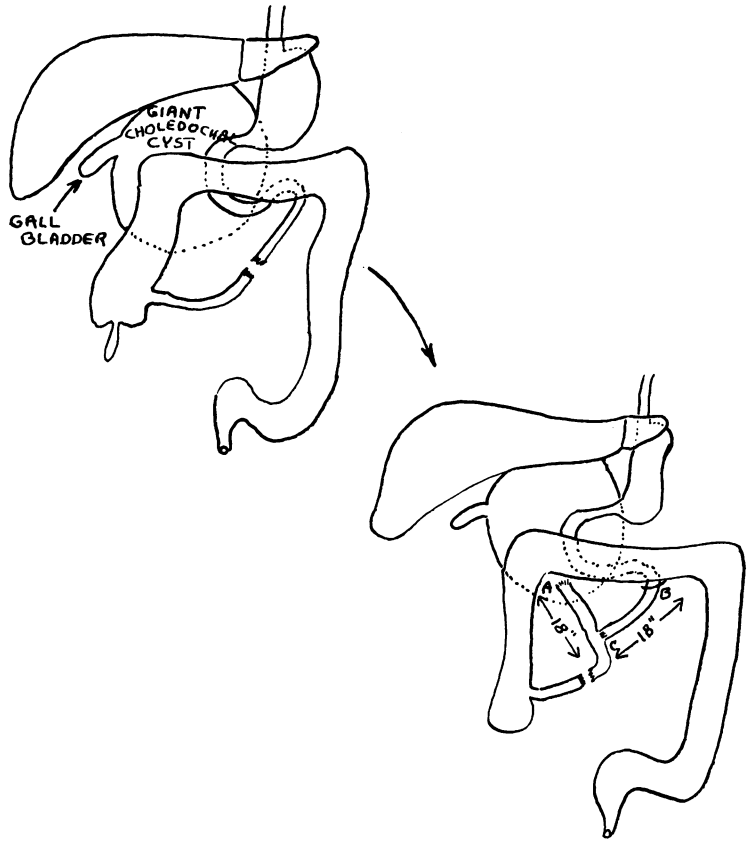


FIG. 1. a. Choledochocyst-jejunostomy, b. Ligament of Treitz, c. Jejunojejunostomy. (Note the long limbs of the Roux-en-Y anastomosis. Each limb is 18 inches long. It is felt that these long limbs will prevent cholangitis.)

ambault *et al.*<sup>3</sup> In the following case report, the Roux-en-Y method of shunting bile from the choledochal cyst to the jejunum was used successfully.

### Case Report

An 18-year-old white female was admitted to Ellis Hospital, June 25, 1956. She was complaining of severe right upper quadrant and right flank pain which began five months prior to admission at the onset of pregnancy. As pregnancy progressed, repeated attacks of right upper quadrant pain were followed by vomiting and later by jaundice. Demerol and morphine had minimal pain relieving effect. In the 4th and 5th months of pregnancy, she had repeated bouts of pain and jaundice. An asymmetrical fullness of her right abdomen was noted. She was advised to have a therapeutic abortion. This was carried out in another hospital two weeks prior to her Ellis Hospital admission. Following abortion, abdominal pain, jaundice, and right-sided abdominal mass continued. Two days prior to admission, she had chills and fever to

102–103° F. In her past she was jaundiced at age 13. This was called catarrhal jaundice.

She was a thin, moderately well nourished young white female with noticeable general and scleral icterus. Her temperature was 100.6° F., pulse 108, respiration 20 and blood pressure, systolic 130/diastolic 90. She was mildly dehydrated. Her chest was clear. Her heart was not enlarged and there were no murmurs. The abdomen was moderately distended with right sided asymmetry. There was a large right sided mass, the size of a basketball, flaring the right costal margin and filling the right upper and lower quadrants. This was thought to be a hugely enlarged liver. The spleen and kidneys were not palpable. There was marked right costovertebral angle tenderness. Rectal examination was negative. The extremities were normal. The various clinical diagnoses entertained included choledocholithiasis with cholangitis, hepatitis, hepatic abscess, subdiaphragmatic abscess, and hepatoma.

The following laboratory data was accumulated: Packed red blood cell volume 39%, hemoglobin 11.9 Gm., white blood cell count 10,300, segmented

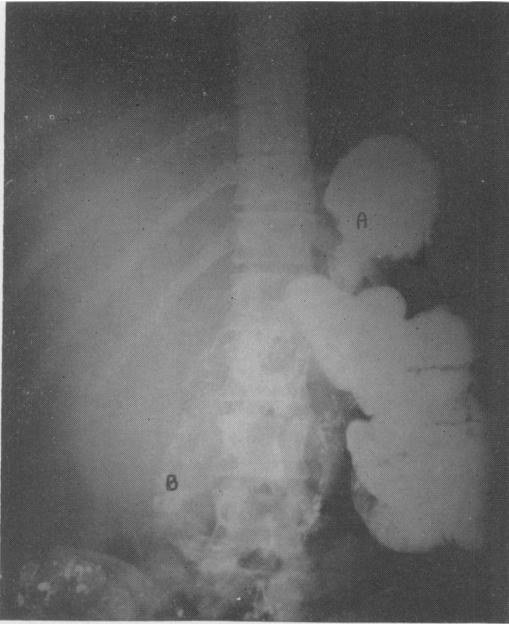


FIG. 2. Preoperative gastro-intestinal series (P-A view). Note the diffuse haziness throughout the entire right side of the abdomen with displacement of the viscera to the left of the spinal column. Note (A) the stomach and (B) the displacement of the duodenal loop towards the midline and towards the pelvis.

neutrophils 71%, stabs 2%, lymphocytes 22%, monocytes 3%, eosinophils 2%, reticulocytes 1.9%. Fasting blood sugar was 99 mg.%, blood urea nitrogen 9 mg.%, quantitative serum bilirubin 1.9 mg.%, cholesterol 168 mg.%, cholesterol esters 118 mg.%, serum alkaline phosphatase 84 King and Armstrong units, total proteins 4.3 Gm.%, with a 2.5 Gm.% albumin and 1.8 Gm.% globulin. The blood serology was negative. Prothrombin time 17.1 seconds with a control of 15 seconds. Cephalin flocculation was 1 + in 48 hours. Thymol turbidity was negative. Bromsulphathalein retention was 25.8%. In summary, a mild anemia, marked hypoproteinemia, and obstructive jaundice were present.

The following x-ray studies were obtained: An abdominal flat plate revealed a large soft tissue right sided mass. Intravenous pyelogram was normal. A gastro-intestinal series demonstrated that the previously noted mass displaced the gastric antrum, pylorus and duodenum toward the left, the descending duodenal loop was displaced anteriorly and to the left almost to the anterior abdominal wall. The gall bladder failed to visualize (Fig. 2, 3). Radiographically, this was interpreted as a large right upper quadrant mass, part of which

was in the right retroperitoneal position, suggesting a pancreatic cyst or an enlarged liver.

### Preoperative Preparation

The hypoproteinemia and depleted blood volume were corrected by administering a total of 2,000 milliliters of whole blood and 400 milliliters of serum albumin over a four-day period.

### Operation

On June 30, 1956, laparotomy was carried out. A hugely dilated congenital dilation of the common bile duct, so-called choledochal cyst was found. 2,600 cubic centimeters of bile were obtained from the cyst by trocar aspiration. No hepatic ducts existed as such. No cystic duct was noted. The gall bladder was a small "finger-like" pseudopod on the right antero-lateral aspect of the cyst (Fig. 1). At the point of trocar insertion into the

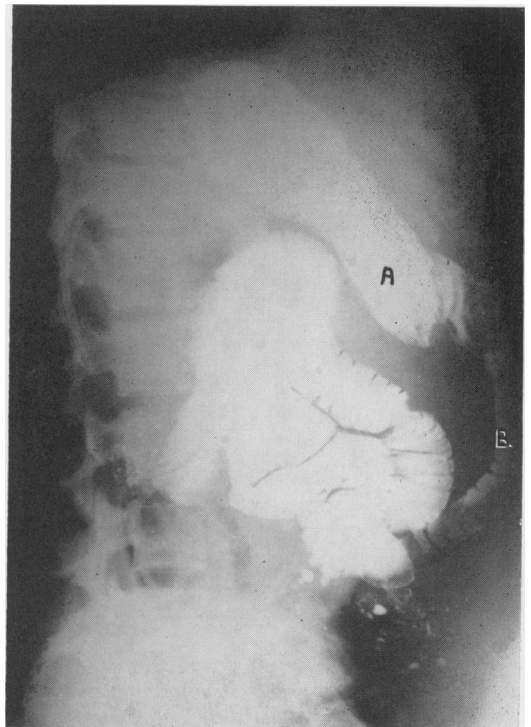


FIG. 3. Preoperative gastro-intestinal series (lateral view). Note the displacement of (A) the gastric antrum anteriorly and (B) the marked anterior displacement of the duodenal loop which is in contact with the anterior abdominal wall.

cyst for aspiration, a circular segment of the cyst wall was excised. Microscopically this was fibromuscular tissue lined by columnar epithelium consistent with biliary tract origin. A Roux-en-Y cyst jejunostomy was carried out. The limbs of the Roux-en-Y were each a measured 18 inches long. It was believed that such relatively long limbs would prevent a reflux of alimentary contents into the cyst. Whether this point would subsequently be important, remains theoretical; however, I believe it is important. An incidental appendectomy was also accomplished (Fig. 1). Her postoperative course was uneventful. Nine days postoperatively liver function tests were done and compared with preoperative values. Serum bilirubin had dropped from 1.9 mg.% to 0.7 mg.%. The total protein had risen from 4.3

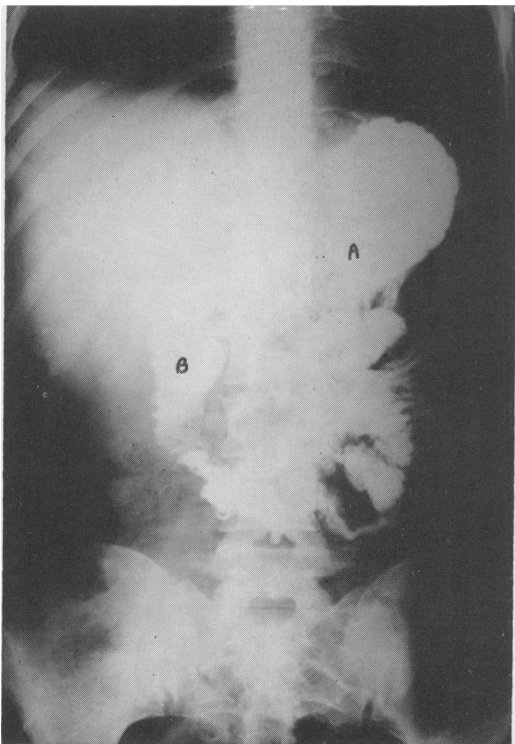


FIG. 4. Two weeks post-operative gastro-intestinal series (P-A view). Note (B) the second portion of the duodenum returning towards its normal habitat in the right upper quadrant. Compare this film with the preoperative P-A view. This was interpreted radiographically as consistent with choledochal cyst shrinkage.

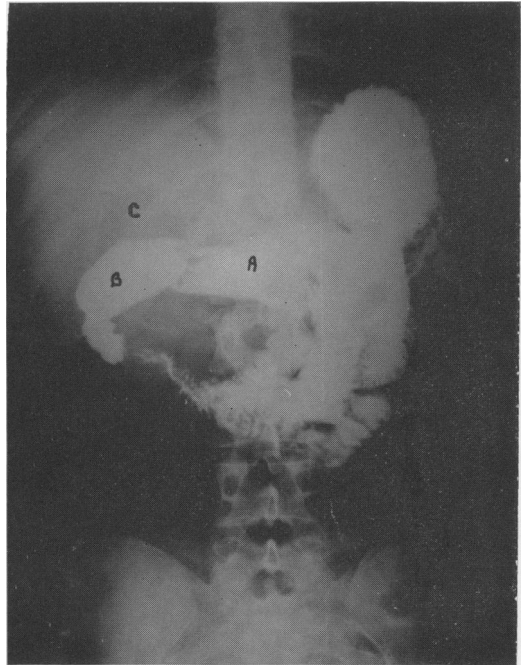


FIG. 5. Eight months postoperative gastro-intestinal series (P-A view). Note (A) the gastric antrum now at the midline, (B) the first portion of the duodenum located in its normal right upper quadrant position, and (C) a faint radiolucent shadow which was interpreted radiographically as representing air in the choledochal cyst, which probably ascended via the Roux-en-Y anastomosis. Though air entered, barium did not ascend.

Gm.% to 5.9 Gm.%. The albumin had risen from 2.5 Gm.% to 3.6 Gm.%. Globulin had risen from 1.8 Gm.% to 2.3 Gm.%. Serum alkaline phosphatase had dropped from 88 King and Armstrong units to 16 King and Armstrong units. Thirteen days postoperatively a gastro-intestinal series revealed the cyst to be smaller in that the former displacement of the gastric antrum, pylorus and duodenum were much less. This was interpreted radiographically as evidence of cyst shrinkage (Fig. 4). She was discharged from the hospital 19 days postoperatively ambulatory, afebrile and with no evidence of an abdominal mass. When discharged from the hospital she weighed 103 pounds.

#### Follow up

The patient has been seen five weeks, nine weeks, and five, six, nine, and 15

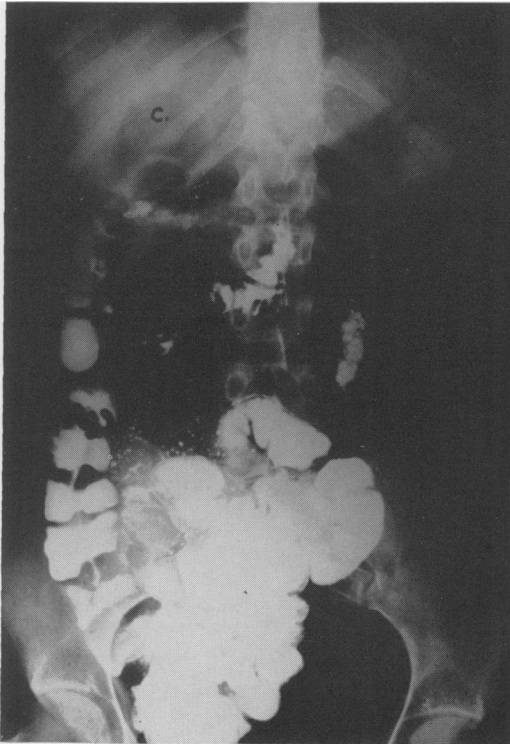

FIG. 6. Eight months postoperative gastro-intestinal series three hours after the ingestion of barium (P-A view). Note (C) the persistent right upper quadrant radiolucent shadow, representing air in the cyst which in eight months had shrunk to such a degree as to allow both stomach and duodenum to resume their more normal positions without any clinical evidence of cholangitis.

months postoperatively. She has done well. In nine months she gained 23 pounds and had no pain, fever or jaundice. Eight months postoperatively an attempt at biliary tract radiographic visualization was unsuccessful. A gastro-intestinal series revealed further evidence of cyst shrinkage (Fig. 5, 6). The patient delivered a seven pound boy with no complications on September 11, 1957, approximately 15 months after the surgery had been performed. At present the patient is two and one-half years postoperative and remains well in all respects.

### Bibliography

1. Allen, J.: Personal communication to Cantley. *Ann. Surg.*, 143:608, 1956.

2. Altar, S. and S. Obeid: Congenital Cyst of the Common Duct. A Review of the Literature and a Report of 2 Cases. *Ann. Surg.*, 142:289, 1955.
3. Archambault, H., R. Archambault and G. W. Lasker: Choledochal Cyst: A Case Treated by Roux-en-Y Type Anastomosis of Jejunum to the Cyst. *Ann. Surg.*, 132:1144, 1950.
4. Bodart, A., N. Neimann, J. Lesure and M. Pierson: Giant Cyst of the Choledochus. *Revue Medicale de Nancy*, 78:368, 1953.
5. Burgess, C. M. and J. W. Cherry: Idiopathic Dilatation of the Common Bile Duct. *Arch. Surg.*, 67:771, 1953.
6. Cantley, W. C.: Congenital Cystic Dilatation of the Common Bile Duct. *Ann. Surg.*, 143:5, 608, 1956.
7. Cussade, L., A. Bodart, N. Neimann, L. Lesure and M. Pierson: Idiopathic Cyst of the Choledochus. *Revue Medicale de Nancy*, 79:131, 1954.
8. Davis, C. E., Jr.: Choledochus Cyst: Case Report with Brief Comment. *Ann. Surg.*, 128:240, 1948.
9. Dennison, W. M.: Choledochus Cyst in Childhood. *J. Internat. Coll. Surgeons*, 21:113, 1954.
10. Gross, R. E.: *The Surgery of Infancy and Childhood, Its Principles and Techniques.* Philadelphia, W. B. Saunders and Co., 1953.
11. Hamilton, I.: Congenital Cystic Dilatation of the Common Bile Duct. *Med. J. Australia*, 1:800, 1939.
12. Keeley, J. L.: Congenital Cystic Dilatation of the Common Bile Duct: Report of a Case. *Arch. Surg.*, 56:508, 1948.
13. MacMillan, S. F.: Personal communication.
14. McLaughlin, E. F.: Choledochus Cyst. *Ann. Surg.*, 123:1047, 1946.
15. McWhorter, G. L.: Congenital Cystic Dilatation of the Bile and Pancreatic Ducts, Necropsy Thirteen Years After Hepaticoduodenostomy. *Arch. Surg.*, 38:397, 1939.
16. Reel, P. J. and N. E. Burrell: Cystic Dilatation of the Common Bile Duct. *Ann. Surg.*, 75:191, 1922.
17. Rogers, J. D. and J. T. Priestley: Cystic Dilatation of the Common Bile Duct: Report of Case. *Proc. Staff Meet. Mayo Clinic*, 24:568, 1949.
18. Shackelford, R. T.: *Surgery of the Alimentary Tract, Vol. I.* Philadelphia, W. B. Saunders and Co., 1955.
19. Shallow, T. A., S. A. Eger and F. B. Wagner, Jr.: Congenital Cystic Dilatation of the Com-

- mon Bile Duct: Case Report and Review of the Literature. *Ann. Surg.*, **117**:355, 1943.
20. Shallow, T. A., *et al.*: Congenital Cystic Dilatation of the Common Bile Duct. *Ann. Surg.*, **123**:119, 1946.
  21. Shocket, E., G. A. Hallenbeck and A. B. Hayles: Choledochal Cyst: Case Reports. *Proc. Staff Meet. Mayo Clinic*, **83**: March 9, 1955.
  22. Smith, B. C.: Cyst of the Common Duct. *Arch. Surg.*, **44**:963, 1942.
  23. Strohl, E. L. and F. E. Sarver: Cystic Dilatation of the Common Duct. *Arch. Surg.*, **62**: 597, 1951.
  24. Trnka, I. A.: Case of Congenital Cyst of Bile Ducts. *Medical Education in Czechoslovakia (Translation from Russian)*, **19**:523, 1953.
  25. Ugelli, L.: The Congenital Cystic Dilatation of the Choledochus. *Il Policlinico (Seyione Chirurgica)*, **40**:343, 1953.
  26. Wrightson, P.: Congenital Cystic Dilatation of the Common Bile Duct. *Australian and New Zealand J. of Surg.*, **23**:110, 1953.
  27. Zinniger, M. M. and J. R. Cash: Congenital Cystic Dilatation of the Common Bile Duct: Report of a Case with a Review of the Literature. *Arch. Surg.*, **24**:77, 1932.