

# Retrograde Intussusception at the Gastrojejunal Stoma \*

MOHAMMED H. SALEM, M.B.Ch.B., SELBY E. COFFMAN, M.D.,\*\*  
R. W. POSTLETHWAIT, M.D.

*From the Department of Surgery and Radiology of Duke Medical Center and  
Veterans Hospital, Durham, North Carolina*

RETROGRADE intussusception after gastroenterostomy is a surgical entity which is seen infrequently, being one of the least common complications following gastric surgery. This complication has been observed, either after simple gastroenterostomy or after partial resection of the stomach with gastrojejunostomy. It has been suggested that the condition probably occurs more often but is not recognized because of a general lack of knowledge of the possibility of such a complication.<sup>14</sup>

Most cases of this condition have been recorded in the European literature, only 26 instances having been reported in this country up to the present time. Three of these reports were from abroad, namely Foster's<sup>13</sup> two cases from West Africa and De Andrade's<sup>10</sup> case from Brazil. Most authors report one or two cases.<sup>7, 13, 25</sup> Although the first gastroenterostomy was performed in 1881, it was not until 1917 that the first complication of this type was recorded by Steker.<sup>34</sup> Iron's case<sup>17</sup> in 1955 was believed to be the one hundredth reported case in the world medical literature. This analysis is based on 26 cases in the American literature and an additional case of our own.

## Classification

According to Shackman,<sup>29</sup> three types of jejuno-gastric intussusception may occur as complication of the anastomosis:

Type I. The afferent loop alone may intussuscept through into the stomach. This is called descending intussusception and is quite uncommon, making up about 16 per cent of this group.

Type II. The efferent loop may undergo retrograde intussusception and either stop short of or pass through the gastroenterostomy stoma. This is referred to as retrograde or ascending intussusception. This type constituted 74 per cent of Aleman's series.<sup>2</sup> Irons<sup>17</sup> pointed out that the intussusception occurring in Classes I and II is usually jejunojejunal intussusception, which in turn intussuscepts into the gastric lumen.

Type III. Both afferent and efferent loops together may intussuscept into the stomach, called combined intussusception. This rare variety comprises about 10 per cent of the cases.

These three types of intussusception are noted to occur in simple gastrojejunostomy. Prohaska<sup>27</sup> in a recent review stated that contrary to the assumption in the literature, the invagination of the afferent or of the combined afferent and efferent segments of jejunum into the gastric pouch has never been observed, and that the only type of intussusception ever noted following subtotal gastric resection is the invagination of the efferent jejunal segment.

This condition has also been classified according to the clinical picture as acute fulminating and chronic or recurrent jejuno-gastric intussusception. It is also recorded as early and late, based on the time interval from the initial operation.

\* Submitted for publication December 29, 1958.

\*\* Present address: Greenville, N. C.

### Etiology and Mechanism of Intussusception

The etiology of retrograde jejuno gastric intussusception is unknown. In contrast to other types of intussusception in adults, elsewhere in the gastro-intestinal tract, there is not a single case in which some anatomicopathologic change found in the intussusception itself, such as tumor or ulcer, could account for the genesis of the invagination. Neither marginal ulcers nor polyps appear to be present to be incriminated as the predisposing factors. The much higher incidence of the condition in simple gastroenterostomy compared with that following gastric resection (five cases of gastrectomy in 27 instances) has led Aleman<sup>2</sup> to assume that hydrochloric acid irritation of the anastomosed jejunal loop, producing spasm and violent peristalsis, is a definite etiologic factor. This powerful antiperistaltic activity of the jejunum is secondary to the presence of acid gastric contents. According to Oselladore,<sup>24</sup> who reproduced in dogs retrograde gastrogastric invagination by injection of weak isotonic silver nitrate solution into the wall of the stomach, the edema of the anastomosis "may cause active gastric peristalsis directed toward emptying itself more rapidly and this peristalsis may throw the gastric mucosa on the anastomosis initiating the invagination." In retrocolic anastomosis (posterior gastrojejunostomy) the hypothesis<sup>2</sup> that intussusception proceeds in retrograde manner because of the tendency for a mobile segment like the efferent limb of the jejunum to invaginate into the gastric stump should be considered.

Mechanical causes<sup>17</sup> have also been suggested, and among them are shortening of the mesentery of the jejunal loop, pressure from a short mesocolon, adhesions to the mesocolon, a sucking action of the stomach where the stoma is narrow, too large a stoma, jejunal stenosis with obstruction

facilitating antiperistalsis, unduly long afferent loop and other technical imperfection.

Once the process has been started, however, its dynamics are easily understood. The point of initial invagination may be at, proximal to or distal to the gastroenterostomy stoma. As peristalsis (afferent loop) or antiperistalsis (efferent loop) continues, more jejunum is pushed into the stomach.

In the recurrent type of intussusception the neck is probably loose, the circulation of the bowel is not compromised, and little, if any, edema develops in the wall of the bowel. The intussusception may change in size by varying the jejunal segment at either the neck or the apex of the intussusceptum. In chronic cases spontaneous reduction is the rule.

It appears, then, that like most of the more familiar ileoileal and ileocolic intussusception of childhood, definite predisposing and precipitating causes have not been recognized, and the reason for the infrequent occurrence of intussusception after gastroenterostomy remains unsolved.

### Clinical Features

Clinically, this mechanical accident occurs in two typical patterns, either as an acute and fulminating process or as a chronic and intermittently recurrent one that is much less critical and much more difficult to recognize. Chamberlin<sup>8</sup> and Caudell<sup>7</sup> divided these cases into two clinical groups:

1. **Acute Fulminating Jejuno gastric Intussusception.** This sequela may occur many years (up to 26 years<sup>21</sup>) after the initial operation and may have fatal results unless diagnosed early. Here, there is increasing edema with fixity of stoma, progression of intussusception and embarrassment of circulation. The involved segment of jejunum may become gangrenous and shock may ensue with high mortality, up to 100 per cent in the cases reported up to 1950 when surgical exploration was not at-

tempted.<sup>13</sup> The clinical picture is characterized by epigastric pain, moderate to severe colicky in type, followed shortly by vomiting first of food, then of bile and finally blood. An epigastric mass may be palpated above and to the left of the umbilicus. Visible peristalsis and upper abdominal rigidity are often present. The usual preoperative diagnosis has been high intestinal obstruction, a ruptured viscus or an acute surgical abdomen. In this group the prognosis is grave and surgical intervention should be immediate.

**2. Chronic Recurrent Jejunogastric Intussusception.** This condition in its chronic recurrent form is reported more common than the acute type, though frequently unrecognized. Patients have maintained a state of chronic invalidism following gastric surgery. The characteristic symptoms are epigastric recurrent discomfort or pain, frequently associated with ingestion of food, and usually subsiding within an hour. These repeated episodes are usually accompanied with nausea and vomiting but no hematemesis unless obstruction of the stoma is complete. These symptoms are quite distressing to the patient, confusing to the surgeon and have been called "postgastrectomy symptoms" or atypical dumping syndrome. Radiographic examination with barium and gastrocopy aid in establishing the diagnosis.

A review of the American literature (Table 1) of retrograde jejunal intussusception following gastroenterostomy, simple or with gastric resection, showed that in 27 cases reported, 19 were male and eight were female. There were 24 white and three colored patients, with extremes of age being 28 and 70 years. The condition has been reported 20 times after gastrojejunostomy (mostly posterior for ulcer) and six after partial gastrectomy for ulcer (except one, which was for carcinoma of stomach). The

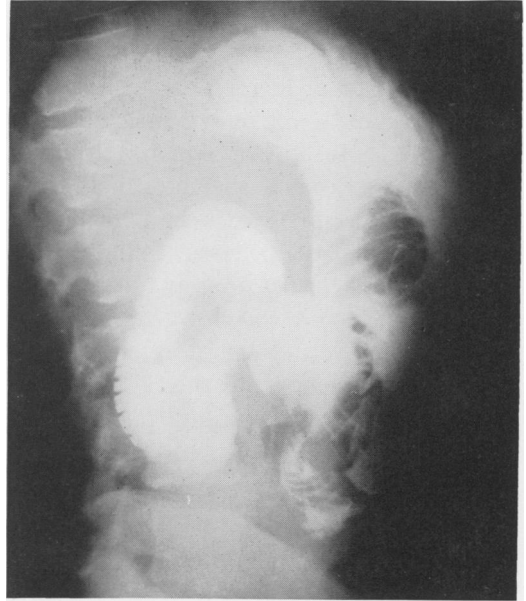

FIGURE 1A.

occurrence of this complication varied in time from three days to 26 years.

Abdominal pain was the first and most striking symptom in 25 patients while shock was present in only nine cases. Vomiting occurred in 22 instances and was persistent.

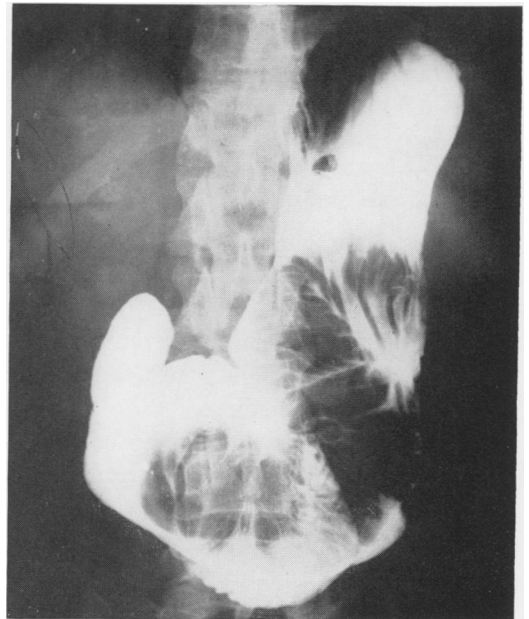


FIGURE 1B.

TABLE 1

Author and Date	Age and Sex*	Type of Previous Surgery	Interval Since Surgery	Symptoms				X-Ray Confirmation	Gastroscopy	Operative Treatment	Delay Before Operation	Reduction and Length of Loop	Resection	Result
				Shock	Mass	Hematemesis	Pain							
1 Lewisohn, 1922	53M	Postgastroenterostomy	6 days	-	-	-	+	-	+	2 days	+ ? length	-	Died	
2 White, 1928	38M	Gastroenterostomy	1½ years	+	-	+	+	-	-	-	-	-	Died	
3 Shearer, 1928	41F	-	2 years	-	+	+	+	-	+	2 days	+30 cm.	-	Good	
4 Summer, 1929	28M	Postgastroenterostomy	12 days	-	-	-	+	-	+	12 days	+At stoma	+		
5 Schilling, 1932	35F	-	7 years	+	-	-	+	-	+	hours	+ 5 feet	-	Died	
6 Bettman, 1933	47M	Gastroenterostomy	12 years	+	-	+	+	-	-	-	-	-	Good	
7 Sibley, 1934	70F	-	8 years	-	-	+	+	+	-	-	-	-	Died	
8 Gotterman, 1936	43M	Postgastroenterostomy	2 years	-	+	+	+	-	-	-	-	-	Good	
9 Ducey, 1937	57M	Gastroenterostomy	15 years	+	-	+	+	-	-	-	-	-	Died	
10 Chamberlin, 1940	39F	Postgastroenterostomy	7 years	-	?	-	+	+	+	7 days	+ ? length	-	Good	
11 McNamara, 1944	50M	Polya gastrectomy	3 weeks	+	-	+	+	-	-	-	-	-	Good	
12 Grimes, 1949	55M	Partial gastrectomy	2½ years	+	?	+	+	-	Enterostomy	-	-	-	Died	
13 Watson, 1950	60M	Postgastroenterostomy	5 weeks	-	+	+	+	+	+	3 days	+50 cm.	-	Good	
14 Lawson, 1950	55M	Gastroenterostomy	5½ years	+	-	+	+	-	-	-	-	-	Died	
15 Lavadia, 1953	64M	Partial gastrectomy	8 years	-	-	+	+	-	+	4 days	+15"	-	Good	
16 Bansmer, 1954	54M	Excision of ulcer and duodenoplasty	20 years	+	+	+	+	-	+	10 hours	+36" then	+	Good	
17 Palmer: 1, 1954	48M	Partial gastrectomy	13 months	-	-	+	+	+	-	-	-	-	Satisfactory with Urocholine	
2, 1954	32M	-	5 weeks	-	-	-	+	-	-	-	-	-	Satisfactory without treatment	
18 Caudell: 1, 1955	49F	Postgastroenterostomy	5 years	-	-	+	+	+	+	-	+	-	Good	
2, 1955	53M	Gastroenterostomy	14 years	-	-	+	+	+	+	3 days	+20 cm.	+		
19 Irons, 1955	69M	Postgastroenterostomy	3 days	-	-	-	+	-	+	18 days	-	+		
20 Andrade (Brazil), 1955	53F	Gastroenterostomy and vagotomy	7 years	-	-	-	+	+	+	?	-	+	Good	
21 Foster (West Africa): 1, 1956	60F	Postgastroenterostomy	14 years	+	-	+	+	-	+	24 hours	+ ? length	-	Good	
2, 1956	30F	-	18 months	-	+	+	+	-	+	5 hours	+30 cm.	-		
22 Madding, 1956	60M	Postgastroenterostomy and pyloroplasty	26 years	-	-	+	+	+	+	24 hours	-	+		
23 Prohaska, 1957	56M	Partial gastrectomy	2 years	-	-	+	+	-	+	?	+ ? length	-	Good	
24 Salem, 1958	53M	Postgastroenterostomy	12 years	-	+	+	+	-	+	3½ days	+10"	-		

\* Patients in Cases 15 and 21 were colored; all other patients white.

In 16 patients the vomitus was bloody. A tumor mass in the upper part of the abdomen was palpable in six cases. Gastros-copy was done in only two cases with verification of diagnosis. Plain x-ray films of the abdomen usually show nothing abnormal. However, as emphasized by Aleman,<sup>2</sup> an upper gastro-intestinal series is very helpful. The oval or round filling defect in the stomach with its base at the site of the gastroenterostomy stoma and a uniform pattern of curved lines suggestive of jejunal mucosa is quite pathognomonic of jejuno-gastric intussusception (Fig. 1). The size of the defect varies from a slight bulge at the site of the stoma to a large mass of jejunum filling the entire stomach. The correct diagnosis was made before operation in nine cases (Palmer's two cases needed no operation).

Operations for this complication were performed on eighteen patients with two deaths and 16 recoveries, i.e. 11 per cent operative mortality. However, the overall mortality was 26 per cent. Four of the 18 patients operated upon were treated with resection, one had enterostomy and the remaining 13 had reduction of intussusception. The base of the intussusception was at gastrojejunos-tomy stoma in one case, and the distance of intussusceptum varied from 20 cm. to five feet. The length of time from the onset of symptoms to the time of operation varied from five hours to 18 days.

Foster<sup>13</sup> in a recent review mentioned the following reasons which make the diagnosis quite difficult: (1) Only one or two cases have been seen by any one author, and the condition is so rare that it is not even considered. (2) In practically all cases the previous history of ulcer associated with hematemesis strongly suggests the recurrence of a peptic ulcer or the development of a marginal ulcer. (3) Because of the desire to let a bleeding, vomiting patient alone as much as possible for the first few days, deep palpation of the abdomen and x-ray

examination may be deferred, and the tumor mass may not be recognized. (4) The combination of hematemesis with high intestinal obstruction is rare and misleading. (5) The chronic intermittent type of intussusception is often spontaneously reduced before the diagnosis is made.

However, sudden epigastric pain in a patient with previous gastric surgery, either gastroenterostomy or resection, vomiting of food, then of bile and later of blood, together with a palpable epigastric mass constitute a classical triad suggesting the diagnosis, and barium meal confirms the condition.

Recurrent peptic ulcer with hemorrhage or perforation; high intestinal obstruction from adhesion, tumor or internal hernia should be distinguished by careful consideration of every case from acute jejuno-gastric intussusception.

### Treatment

In all types of acute jejuno-gastric intussusception immediate surgical treatment is necessary. Reduction by gentle traction, with or without opening the stomach, should always be attempted. If there is gangrenous bowel, resection will be mandatory. If the patient's condition is good and he has had recurrent ulcer symptoms following simple gastroenterostomy, resection may be justified. Additional procedures to prevent recurrence of intussusception, such as fixing the jejunal loops together or to the colon or mesocolon with or without enterostomy, are not warranted since the chance of recurrence is slight. Bettman<sup>5</sup> found only two recurrences among all the reported cases.

The high mortality (32% reported in American literature) associated with this condition is usually owing to the poor pre-operative condition of the patient, the failure to recognize this complication and delay in prompt surgical exploration.

### Case Report

J. C. was a 53-year-old, white, married man who was admitted on January 4, 1958, because of massive hematemesis and right upper quadrant and epigastric colicky pain of four hours' duration. The patient gave a history of having had a gastroenterostomy some 15 years previously for a bleeding ulcer. The patient had been relatively asymptomatic since that procedure, with the exception of daily emesis, usually at breakfast time. Two years ago he was found to have chronic myelogenous leukemia with myelofibrosis and hepatosplenomegaly. Barium meal at that time showed no evidence of spasm, tenderness or ulceration about the stoma. The patient had been treated with Myleran® and had been followed at regular intervals in the Hematology Clinic. He had also been treated for hypertension.

Four hours prior to admission, the patient was awakened about midnight by severe sharp and colicky pain in the right upper quadrant and radiating to the chest. This was very shortly followed by vomiting a large amount of dark blood. The patient vomited three times on the way to the hospital.

On physical examination, the patient appeared chronically ill. The blood pressure was 130/75, pulse 60, temperature 36.5° C. and respiration 16. The skin was pale and the head and face had a greyish pallor. There was no lymphadenopathy. The lungs were clear. The heart was slightly enlarged to the left, had a regular rhythm, and a Grade II systolic murmur was heard along the left sternal border. The abdomen showed an upper transverse scar with exquisite tenderness in the right upper quadrant and epigastrium, but minimal rebound tenderness. Muscle spasm of the right upper quadrant, but no actual rigidity was noted. The liver and spleen were not palpable, and the rectal and neurologic examinations were not remarkable.

The hemoglobin was 9.5 grams, and the white blood count 8,000. Platelet count on the next day after admission was 14,500 platelets with markedly reduced differential. Various blood chemical studies were essentially normal. Electrocardiogram was abnormal due to bradycardia and probably digitalis effect.

Nasogastric suction was started and intravenous fluids and blood given. A gastro-intestinal series was attempted on the second day, but this was not successful because of the inability of the patient to cooperate. At that time, however, there were noted to be large filling defects in the stomach. The patient continued to drain large amounts of guaiac positive gastric contents, up to five liters per day,

and treatment was continued with fresh whole blood transfusions. On the third hospital day, palpation of the abdomen showed fullness in the epigastrium with ill-defined, tender, somewhat movable mass. Roentgen re-examination of the stomach on the same day showed a large almost completely atonic stomach with a number of dilated jejunal loops within the lumen of the stomach (Fig. 1). No gross defect of the duodenum was noted. His general condition had deteriorated and it was then elected to proceed with an exploratory laparotomy.

Three and a half days after the onset, operation was carried out. The spleen and liver were moderately enlarged and smooth. A soft mass was palpated inside the stomach. On retracting the transverse colon upward, the posterior gastrojejunostomy was found to be markedly swollen, ecchymotic, bluish and admitted two fingers easily. Attempts to reduce the intussusception without opening the stomach were not completely successful, and so the anterior wall of the antrum was opened. Inside the stomach the efferent loop, measuring about ten inches, was found invaginated as the intussusceptum; this was markedly swollen, bluish and hemorrhagic. Using very gentle traction and milking the jejunum, reduction was completed, and the reduced loop was covered with a warm abdominal pad for 15 minutes. The mesentery of the intussuscepted loop was infiltrated with 20 cc. of 1 per cent Xylocaine in an effort to relieve the spasm of its vessels. Inspection and palpation of the lumen of the stomach and duodenum showed no ulceration, bleeding or abnormality of the mucosa of the pylorus or of the cardia. The anterior gastrotomy opening was closed. The color of the efferent jejunal loop had improved, pulsation had returned to the mesenteric vessels and viability appeared assured. It was felt that no more definitive surgery should be done to the gastrojejunostomy opening because of the poor condition of the patient and the local swelling and ecchymosis in that area. The patient received a total of 500 cc. of whole blood during operation, bringing the total to 2,500 cc. of blood since admission to the hospital.

Postoperatively, the patient continued to drain moderate amounts of dark blood through his nasogastric tube. His temperature remained elevated to 38° C. for the first three postoperative days and then dropped gradually within normal range. His platelets continued to rise postoperatively. He was discharged on the twenty-third postoperative day. Repeat barium meal three months after operation revealed no defect or ulceration and good passage of barium through stoma. There was no evidence of recurrent intussusception (Fig. 2).

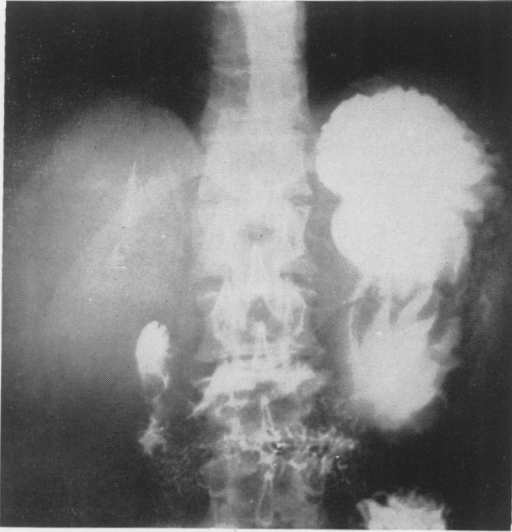


FIGURE 2A.

### Summary

Review of American literature revealed 26 cases of retrograde jejuno-gastric intussusception. These cases were analyzed and another case was added. The classification, etiology, mechanism and clinical features of this infrequent and rare complication following gastric surgery were discussed.

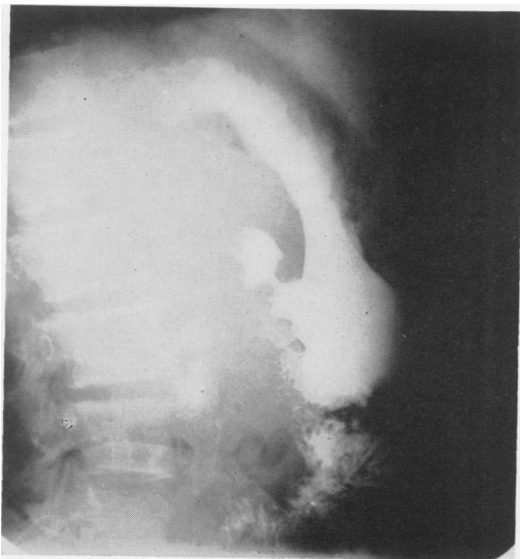

FIGURE 2B.

### References

1. Adams, A. W.: Retrograde Jejuno-Gastric Intussusception, Acute and Chronic. *Brit. Med. J.*, 1:248, 1935.
2. Aleman, S.: Jejuno-gastric Intussusception, a Rare Complication of the Operated Stomach. *ACTA Radiol.*, 29:383, 1948.
3. Bansmer, G.: Retrograde Intussusception of a Gastroenterostomy Stoma. *A. M. A. Arch. Surg.*, 68:624, 1954.
4. Becker, B. J. P.: Retrograde Intussusception of the Jejunum Following Gastro-Enterostomy. *South African Med. J.*, 10:489, 1936.
5. Bettman, R. B. and R. S. Baldwin: Retrograde Intussusception of Jejunum: A Complication of Gastro-Enterostomy. *J. A. M. A.*, 100:1228, 1933.
6. Cameron, J. A. M. and W. D. Macfarlane: Intussusception of Jejunum into Stomach Through a Gastro-Enterostomy Stoma. *Brit. J. Surg.*, 23:275, 1935.
7. Caudell, W. S. and L. Marshall, Jr.: Acute and Chronic Jejuno-gastric Intussusception. *New England J. Med.*, 253:635, 1955.
8. Chamberlin, G. W.: Chronic Recurrent Jejuno-gastric Intussusception Through a Gastro-enterostomy Stoma. *Am. J. Surg.*, 49:510, 1940.
9. Davey, W. W.: Retrograde Intussusception Following Roux-loop Anastomosis in Total Gastrectomy. *Brit. J. Surg.*, 42:102, 1954.
10. DeAndrade, M. A. and C. A. D. A. Coelho: Jejuno-gastric Intussusception Associated with a Strange Postoperative Complication (Gastroenterostomy). *Surgery*, 37:653, 1955.
11. Ducey, E. F. and W. L. McNamara: Retrograde Jejuno-gastric Intussusception Through a Gastro-Enterostomy Stoma. *Ann. Surg.*, 105:461, 1937.
12. Dudko, M. O.: Retrograde Invagination of Small Intestine in Stomach Following Posterior Gastro-enterostomy. *Rad. Med.*, 5:67, 1940.
13. Foster, D. G.: Retrograde Jejuno-gastric Intussusception. A Rare Cause of Hematemesis. Review of the Literature and Report of Two Cases. *A. M. A. Arch. Surg.*, 73:1009, 1956.
14. Gotterman, J.: Intussusception of Jejunum Following Gastro-enterostomy. *J. A. M. A.*, 106:1895, 1936.
15. Grimes, A. E.: Retrograde Intra-gastric Intussusception of the Jejunum Following Subtotal Gastrectomy; Report of a Case, Apparently the Second Such in the Literature. *Ann. Surg.*, 129:404, 1949.

16. Groper, M. J.: Retrograde Enteric Intussusception. *Ann. Surg.*, **112**:344, 1940.
17. Irons, H. S., Jr. and R. J. Lipin: Jejuno-gastric Intussusception Following Gastro-enterostomy and Vagotomy. *Ann. Surg.*, **141**:541, 1955.
18. Lavadia, P., Jr., B. W. Haynes, Jr. and M. E. DeBakey: Retrograde Jejuno-gastric Intussusception; Review of Literature and Report of a Case. *Am. Surgeon*, **19**:507, 1953.
19. Lawson, E. H. and D. L. Whitener: Retrograde Jejuno-gastric Intussusception: Report of a Case. *Arch. Surg.*, **60**:242, 1950.
20. Lewisohn, R.: Intussusception of Stoma Following Gastroenterostomy. *Ann. Surg.*, **76**:543, 1922.
21. Madding, G. F., B. F. McLaughlin and R. DeRiemer: Jejunojejuno-gastric Intussusception. *Am. Jr. Surg.*, **92**:636, 1956.
22. Maisel, B. and S. Weintraub: Prolapsing Gastric Mucosa Through Gastrojejunostomy Simulating Cancer of the Stomach. *Surgery*, **29**:777, 1951.
23. McNamara, W. L.: Retrograde Jejuno-gastric Intussusception through a Subtotal Gastrectomy Stoma. *Ann. Surg.*, **120**:207, 1944.
24. Osellodore, G.: *Arch. ital. di. chir.*, **53**:357, 1938.
25. Palmer, E. D.: Retrograde Intussusception at the Gastrojejunal Stoma: Two Cases and a Bibliography. *Am. J. Digest Dis.*, **21**:309, 1954.
26. Peterson, D. R. and J. Bieman: Jejuno-duodenogastric Intussusception Following Gastrojejunostomy. *Northwest. Med. S.*, **1**:38, 1952.
27. Prohaske, I. V., M. C. Govostis, H. P. Harms and S. O. Evans: Jejuno-gastric Intussusception Following Subtotal Gastrectomy. *Am. J. Surg.*, **94**:776, 1957.
28. Schilling, N.: Intussusception Through Gastroenterostomy Stoma. *Ann. Surg.*, **95**:958, 1932.
29. Shackman, R.: Jejuno-gastric Intussusception. *Brit. J. Surg.*, **27**:475, 1935.
30. Shearer, J. P. and E. M. Pickford: Intussusception of Small Intestine into Stomach Through Gastroenterostomy Stoma. *Ann. Surg.*, **87**:574, 1928.
31. Sibley, W. L.: Chronic Intermittent Intussusception Through the Stoma of a Previous Gastro-Enterostomy. *Proc. Staff. Meet. Mayo*, **9**:364, 1934.
32. Smith, I.: Retrograde Jejuno-gastric Intussusception Following Gastrectomy. *Brit. J. Surg.*, **42**:654, 1955.
33. Stammers, F. A. F.: Remarks on Fifteen Cases of Small Bowel Obstruction Following Antecolic Partial Gastrectomy and One Case Following Retrocolic Partial Gastrectomy. *Brit. J. Surg.*, **42**:34, 1954.
34. Steber: *München. med. Wschnschr.*, **64**:648, 1917.
35. Summers, J. E.: Acute Complete Obstruction of Duodenum Following Gastrojejunostomy; Cure by Degastroenterostomy. *Arch. Surg.*, **19**:292, 1929.
36. Warren, R.: Retrograde Intussusception of Jejunum Through Stoma of Gastrojejunostomy. *Lancet*, **2**:615, 1919.
37. Watson, T. R., Jr. and W. B. Grandell: Acute Jejuno-gastric Intussusception: Report of Case. *Surgery*, **28**:116, 1950.
38. White, F. W. and I. R. Jankeison: Late Intussusception of Bowel into Stomach After Gastroenterostomy. *New England J. Med.*, **199**:1189, 1928.