

Hepatic Hemodynamics in Experimental Ascites *

THEODORE DRAPANAS, M.D., WORTHINGTON G. SCHENK, JR., M.D.,
EUGENE L. POLLACK, M.D., JOHN D. STEWART, M.D.

*From the Department of Surgery, University of Buffalo School of Medicine and the
Edward J. Meyer Memorial Hospital, Buffalo, New York*

IN THE experimental animal, constriction of the supradiaphragmatic vena cava has been a time-honored method for the production of chronic ascites. The hepatic venous outflow block produced results in marked venous congestion of the liver and ascites similar to that seen in humans with thrombosis of the hepatic veins (Budd-Chiari syndrome), tricuspid insufficiency and constrictive pericarditis.¹²

Although it appears that alterations in hepatic lymph flow with transudation through the liver capsule and lymphatics play an important role in the formation of ascites of this nature, the hemodynamic alterations involving the hepatic vasculature remain obscure. The concept of chronic hepatic vein and hepatic sinusoidal hypertension with resultant alterations of hepatic blood flow is frequently mentioned as a possible phenomenon accompanying this ascites. To this extent, it would appear to simulate the mechanism operating in ascites due to portal cirrhosis where outflow obstruction at the hepatic sinusoidal level has been suggested.^{5-7, 11, 12}

In the present study, direct measurement of some of the alterations in hemodynamics involving the liver following production of chronic ascites in the experimental animal was performed in an attempt to clarify some of these concepts.

* Presented before the American Surgical Association, White Sulphur Springs, West Virginia, April 4-6, 1960.

Supported in part by a grant-in-aid (A-2937) from the United States Public Health Service.

Methods

Twenty-four adult mongrel dogs were studied. Partial constriction by a silk ligature of the supradiaphragmatic inferior vena cava was produced in ten dogs through a short right intercostal incision under intravenous thiopental (30 mg./kg.) and endotracheal ether anesthesia. Sixty to 75 per cent constriction of the lumen of the vena cava was produced. Complete obstruction of the supradiaphragmatic vena cava was produced in six other dogs in two stages three to six weeks apart in order to obtain maximum ascites. All animals were fed a standard kennel diet without salt restriction and were weighed periodically.

At varying periods after the development of ascites, the animals were anesthetized lightly with intravenous pentobarbital (15 to 20 mg./kg.). Laparotomy was performed through a midline incision, and all ascitic fluid was measured. Inspection of the viscera and the portal and caval venous systems was carried out noting the extent of venous collateral development. In some animals catheterization of the hepatic lymphatics was performed with a fine polyethylene catheter, and hepatic lymph collected. After dissection of the portal vein, hepatic artery and abdominal vena cava above the renal veins, mean blood flow, pulsatile blood flow and directional flow measurements were performed on these vessels utilizing the noncannulating square-wave electromagnetic flowmeter.

Polyethylene catheters were then in-

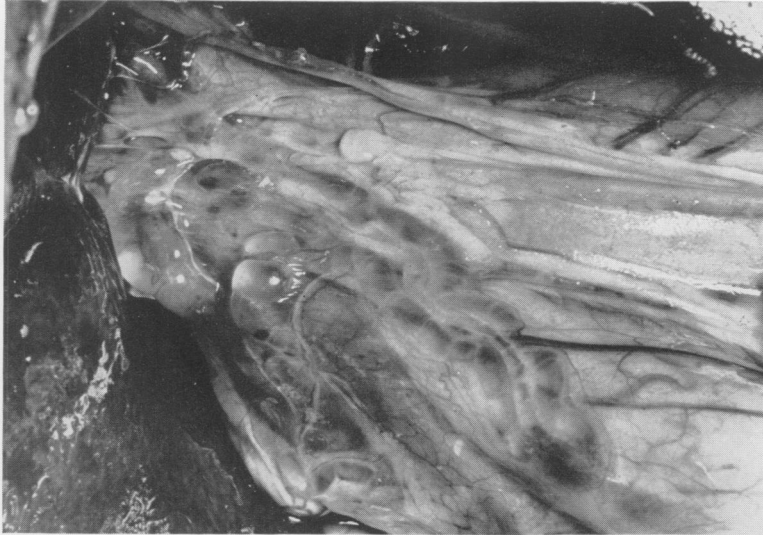

FIG. 1. Liver Hilum: Note enlarged tortuous lymphatics distended with lymph coursing along portal vein and hepatic artery in duodenohepatic mesentery. Marked venous engorgement of the liver is present and weeping of lymph from the liver capsule is noted. Ascitic fluid of 3,600 cc. was present in this dog.

served into the portal vein through the splenic vein; the abdominal vena cava through the femoral vein; and the lower aorta through the femoral artery. Venous pressures were measured by a U-tube water manometer relating all measurements to the level of the right auricle as a standard reference point. Pressure in the vena cava at the level of the liver was determined before and after occlusion with a sling ligature between the liver and the renal veins. Pressure below the sling ligature occlusion was also measured. Arterial pressures were measured with a U-tube mercury manometer.

Radiographic visualization of the portal bed and the inferior vena cava was obtained by injection of 50 per cent Hypaque through the appropriate polyethylene catheters. Liver biopsies were performed at the termination of the studies following which all animals were sacrificed, and further examined for evidence of venous collateral development.

Concentration of the total plasma protein and plasma albumin was repeatedly determined before and after the development of ascites. Protein concentration was also measured in the hepatic lymph and ascitic fluid. As a control study, comparable flow

and pressure measurements were performed in eight normal dogs.

Results

Clinically apparent ascites developed in all dogs as early as eight days following partial constriction of the supradiaphragmatic vena cava. Spontaneous regression of ascites was noted in one dog at seven weeks and only minimal constriction of the vena cava was present at autopsy. Venous collaterals became evident on the abdominal wall as abdominal distention and ascites progressed.

At laparotomy, all ascitic dogs exhibited a large engorged liver occupying most of the upper abdomen. Many large distended lymphatic channels containing lymph under pressure were present at the hilum of the liver (Fig. 1) and weeping of lymph was noted from the liver capsule. When cut, these channels continued to pour out large quantities of lymph. The amount of ascites was variable, but generally increased with time. A mean volume of 2,400 cc. of ascitic fluid was present in dogs with partial constriction and 3,300 cc. in dogs with complete occlusion of the supradiaphragmatic vena cava.

The protein concentrations in plasma, hepatic lymph, and ascitic fluid from four typical experiments are shown in Table 1. Lymph protein values approached the plasma values with very little difference in albumin concentration. The high protein concentration in lymph and ascitic fluid was similar in all dogs studied.

Many large collateral venous channels were present from the tense enlarged vena cava to the retroperitoneal region, abdominal wall, and diaphragm. In contrast, the portal vein was soft and of normal size with no evident collateral development in the portal bed. Hypaque injection of the vena cava confirmed the presence of marked collateral development (Fig. 2A). Portal venograms through the distal splenic vein revealed a normal venous pattern with rapid transit of dye into the liver (Fig. 2B). No abnormal collateral veins were noted.

Liver biopsies (Fig. 3) uniformly revealed marked congestion of the central lobular region with disruption of liver cords and distention of sinusoids with blood. Numerous enlarged distended lymphatic channels were present in the periportal spaces. No fibrosis was seen.

Hepatic blood flow measurements in eight normal dogs are shown in Figure 4. There was a flow range of 30 to 47 cc./kg./min. with a mean total flow of 39 cc./kg. of body weight/min. in this group. A portal vein/hepatic artery flow ratio of 2:1 was present in all dogs except two (experiments 63 and 65) where the hepatic artery contributed 50 per cent of the total hepatic blood flow. Directional blood flow in all instances was toward the liver.

Figure 5 shows the flow measurements in ten ascitic dogs, obtained eight to 60 days following partial constriction of the supradiaphragmatic vena cava. Mean total hepatic blood flow was 39 cc./kg./ body weight/min. with a range of 31 to 45 cc./kg./min. This was identical to the values found in the control dogs. Similarly, a portal vein/hepatic artery flow ratio of

TABLE 1. Protein Concentrations in Plasma, Lymph and Ascitic Fluid. Hepatic lymph protein values are approximately 80% of the plasma levels. Albumin levels in plasma and hepatic lymph show little difference indicating rapid filtration of albumin from plasma to lymph.

		Total Protein Gm. %	Albumin Gm. %	Globulin Gm. %
Dog 31	Plasma	6.9	1.7	5.2
	Lymph	6.0	1.6	4.4
	Ascitic fluid	4.8	1.4	3.4
Dog 34	Plasma	5.3	1.7	3.6
	Lymph	4.2	1.4	2.8
	Ascitic fluid	3.6	1.3	2.3
Dog 10	Plasma	5.4	2.0	3.4
	Lymph	4.5	1.7	2.8
	Ascitic fluid	3.6	1.8	1.8
Dog 21	Plasma	5.1	2.1	3.0
	Lymph	4.5	1.9	2.6
	Ascitic fluid	4.0	1.7	2.3

2:1 was noted, except in two animals (experiments 4 and 17) where approximately equal flow was present in each vessel.

Flow measurements in the six dogs with complete obstruction of the supradiaphragmatic vena cava are shown in Figure 6. These dogs appeared sicker, required less anesthesia and had more ascites. Their livers appeared tense and many enlarged lymphatic channels leaving the liver were present. Despite this, mean total hepatic blood flow measured up to two months following the development of ascites was 32 cc./kg./min. with a range of 27 to 41 cc./kg./min. This was not statistically different from the mean flow present in the normal dogs. In four dogs, a normal portal vein/hepatic artery flow ratio approximating 2:1 was present. In two dogs, the hepatic artery contributed 55 per cent (experiment 37), and 75 per cent (experiment 41) of the hepatic blood flow. Portal vein blood flowed toward the liver in every ascitic dog studied. In no instance was portal flow away from the liver.

The flow patterns obtained in normal dogs are shown from a typical experiment

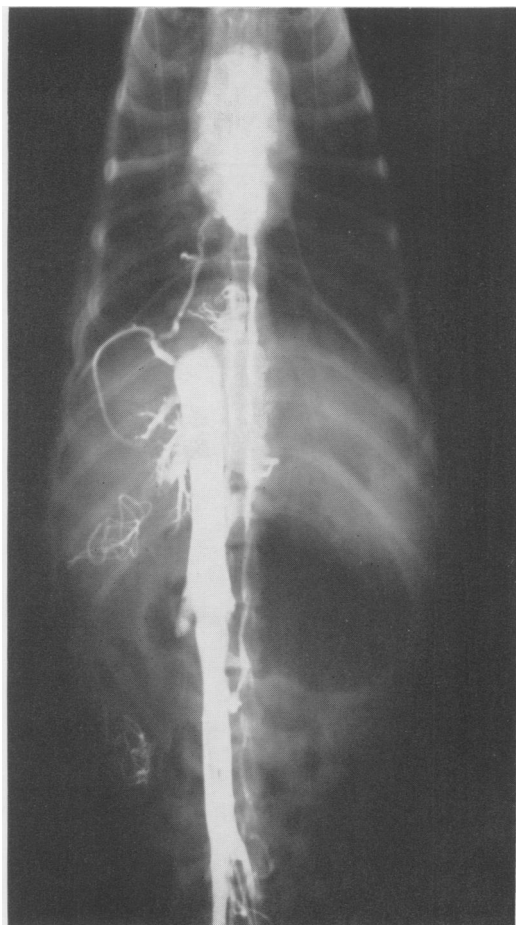


FIG. 2A. Venogram of Inferior Vena Cava: Catheter threaded into the vena cava to level of the liver through the femoral vein and 30 cc. of 50 per cent Hypaque injected. Retrograde flow of dye in the vena cava is noted from point of obstruction above the liver into collaterals with visualization of vertebral veins, epigastric veins and azygos system.

(Fig. 7). The characteristic pulsatile hepatic arterial flow reveals no reverse component in diastole and the zero flow point indicates all flow toward the liver since by convention, flow tracings are mounted so that forward flow appears above the zero flow line. Portal vein flow typically showed respiratory variation. Vena cava flow measured between the liver and the renal veins was cephalad as shown by the zero line.

Figure 8 shows the patterns in a typical ascitic dog. Pulsatile hepatic arterial flow

and portal vein flow appeared normal and directed toward the liver. Vena caval flow was in a retrograde direction away from the liver indicating reversal of flow toward the collaterals.

Pressure measurements in the portal vein and the vena cava at the liver are shown from each experiment (Fig. 9). Portal vein pressures in ascitic dogs, when compared to normal dogs, reveal no significant differences although in a few animals slightly higher readings were present. No elevation in portal pressure above 165 mm. of water occurred in any ascitic dog and all pressures remained well within the normal range.

Hepatic vena cava pressures, on the other hand, revealed consistent elevation

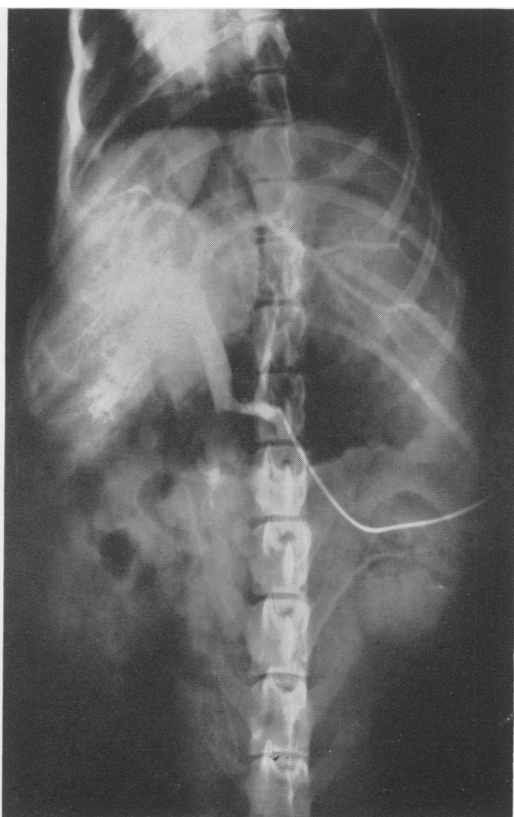
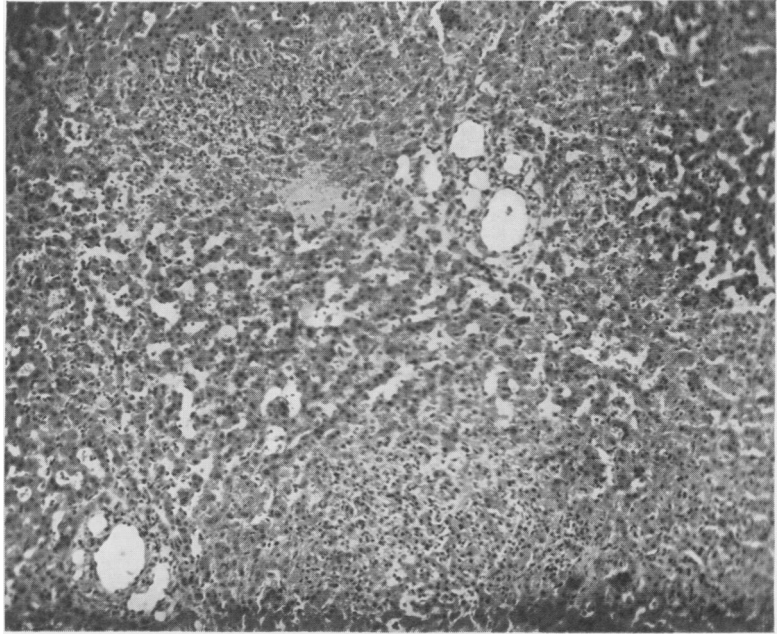


FIG. 2B. Portal Venogram: Following injection of Hypaque into the splenic vein, rapid egress of dye into the liver is noted. No evidence of any enlargement of collaterals in the portal bed is present.

FIG. 3. Photomicrograph of Liver (from $\times 120$): Six weeks following constriction of supra-diaphragmatic vena cava, marked congestion of hepatic sinusoids and disruption of cords in hepatic vein centro-lobular region is present. Enlargement of hepatic lymphatics in periportal spaces is prominent.

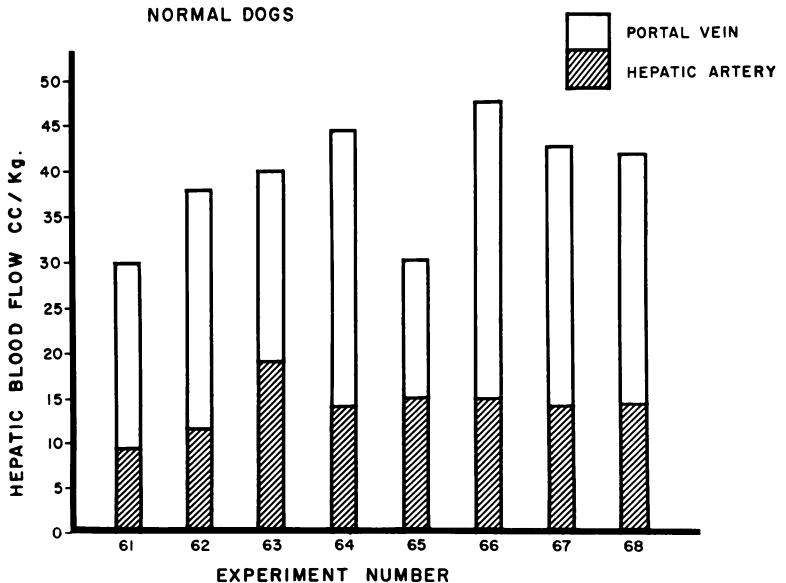


above the normal ranges. Pressures appeared highest immediately following constriction and slowly fell as reversal of flow became evident with the development of collaterals.

A diagrammatic representation of the typical flow and pressure measurements

obtained in each group of dogs studied is shown in Figure 10. Table 2 summarizes the complete data from eight normal dogs; Table 3, the data from the ten dogs with partial constriction of the supra-diaphragmatic vena cava; and Table 4, the data from six dogs with complete constriction.

FIG. 4. Hepatic Blood Flow in Normal Dogs: Total and differential portal vein and hepatic artery blood flows are shown from eight experiments. Mean hepatic blood flow in this group is 39 cc./kg./min.



PARTIAL OBSTRUCTION THORACIC INFERIOR VENA CAVA

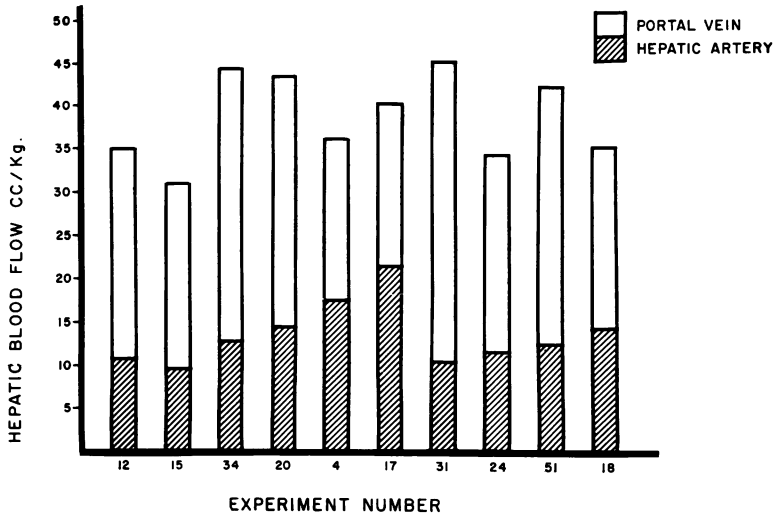


FIG. 5. Hepatic Blood Flow in Ascitic Dogs: Partial obstruction of thoracic inferior vena cava is present. Total and differential portal vein and hepatic artery blood flows are shown from ten experiments. Mean hepatic blood flow in this group is 39 cc./kg./min.

COMPLETE OBSTRUCTION THORACIC INFERIOR VENA CAVA

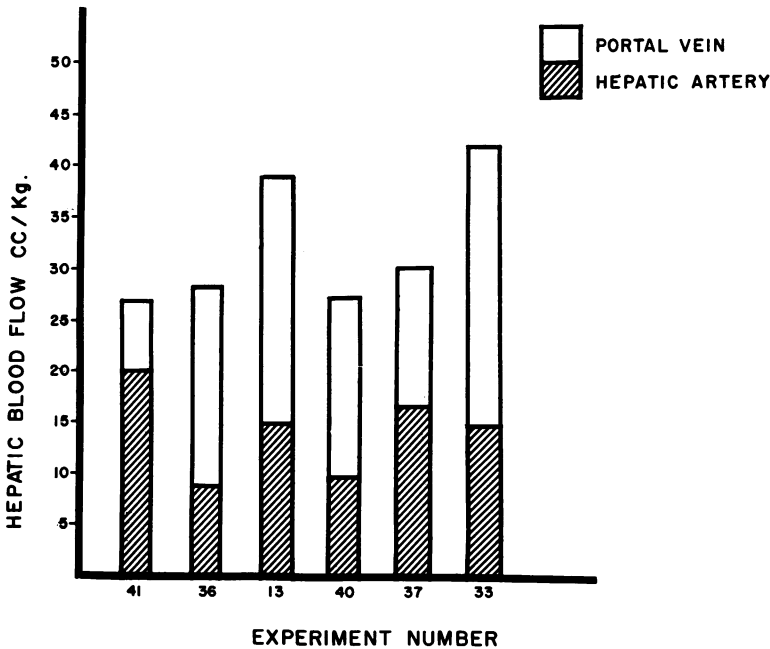
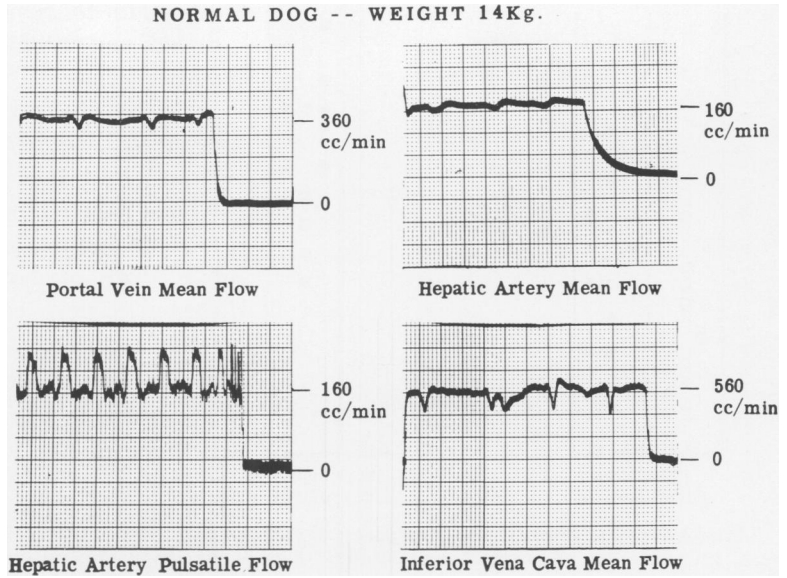


FIG. 6. Hepatic Blood Flow in Ascitic Dogs: Complete obstruction of thoracic inferior vena cava is present. Total and differential portal vein and hepatic artery blood flows are shown from six experiments. Mean hepatic blood flow in this group is 32 cc./kg./min.

FIG. 7. Blood Flow Patterns in Normal Dog: Portal vein and hepatic artery mean flows at top. Typical respiratory variation in flow is shown in the portal vein. Zero line is obtained by momentary occlusion of each vessel. In all flow pattern tracings, flow above the zero line is indicated as forward flow. Total hepatic blood flow is obtained by summation of portal vein and hepatic artery flow and is 37 cc./kg./min. in this animal. Pulsatile hepatic artery flow and vena cava flow measured below the liver is shown at bottom. Note, also, the typical respiratory variation present in the vena cava flow tracing.

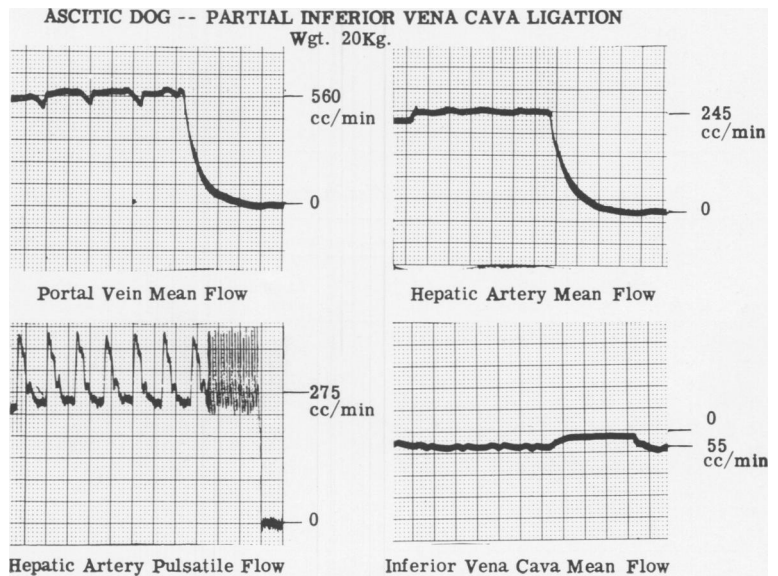


Discussion

Although many endocrine and electrolyte alterations have been shown to accompany experimental ascites produced in this fashion,^{2, 8} they are probably secondary to ascitic fluid production and sequestration in the peritoneal cavity. The initiating defect appears to be the marked rise in venous outflow pressure of the liver. This,

in turn, produces congestion and an increased effective filtration pressure at the intrahepatic capillary or sinusoidal level resulting in the formation and extravasation of large quantities of lymph.³ The development of large lymphatic channels containing lymph under increased pressure appears to confirm this concept. It is also probable that the lymph channels are in-

FIG. 8. Blood Flow Patterns in Ascitic Dogs: Portal vein and hepatic artery mean flows are shown in the top tracings. Total hepatic blood flow in this dog is 41 cc./kg./min. Hepatic artery pulsatile flow pattern is normal. In the inferior vena cava flow tracing, however, flow (55 cc./min.) falls below the zero line indicating reversal of direction.



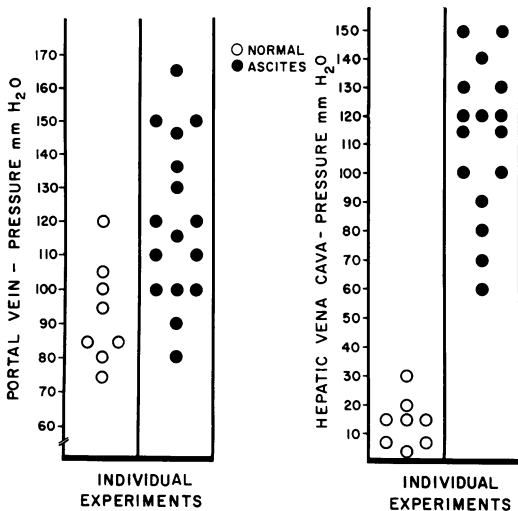


FIG. 9. Venous Pressure Measurements: Portal vein pressures in all normal and ascitic dogs studied are shown on the left. Although a wider range of portal pressures is present in ascitic dogs, no significant elevations are noted. Vena cava pressures measured at the level of the liver, however, show a marked increase over normal pressures.

adequate to remove all the lymph produced, and weeping from the liver surface occurs. Cain *et al.*¹ have shown that hepatic lymph flow in experimental ascites is greatly augmented and may exceed by twenty-fold the rate of normal hepatic lymph flow. This lymph having a high protein content approaching plasma protein levels produces further fluid loss into the peritoneal cavity when extravasated into this space.⁴

The lack of development of portal hypertension in our animals is not surprising in light of the fact that complete staged occlusion of the portal vein does not result in sustained portal pressure increases in dogs. Volwiler *et al.*¹⁰ have also shown that portal hypertension is not essential to the formation of ascites in the dog, and that obstruction of the vena cava above the

TABLE 2. Hemodynamic Studies in Normal Dogs

Experiment Number	Blood Flow cc./kg./min.				Venous Pressure mm. H ₂ O		Mean Blood Pressure mm. Hg
	Total Hepatic	Portal Vein	Hepatic Artery	Abdominal Vena Cava	Portal Vein	Abdominal Vena Cava	
61	30	21	9	36	80	20	140
62	37	26	11	40	85	5	150
63	40	21	19	19	95	5	130
64	44	30	14	23	100	15	120
65	30	15	15	21	105	2	120
66	47	32	15	41	85	15	130
67	43	29	14	18	75	30	140
68	42	28	14	28	120	15	150

TABLE 3. Hemodynamic Studies in Ascitic Dogs-Partial Constriction Thoracic Vena Cava

Exp. No.	Days	Ascites cc.	Blood Flow cc./kg./min.				Venous Pressure mm. H ₂ O				Mean Blood Pressure mm. Hg
			Total Hepatic	Portal Vein	Hepatic Artery	Abdominal Vena Cava	Portal Vein	Hepatic Vena Cava	Occluded Hepatic Vena Cava	Occluded Peripheral Vena Cava	
4	8	660	36	19	17	16 ↑	120	100	60	200	120
12	9	1,800	35	24	11	12 ↑	90	150	115	220	125
24	16	2,300	34	23	11	14 ↓	100	80	110	40	140
31	21	4,200	45	35	10	8 ↓	110	140	150	120	120
15	22	3,000	31	22	9	2.3 ↓	100	70	85	20	110
34	23	1,800	44	32	12	9 ↓	80	60	80	50	85
17	33	1,200	40	19	21	17 ↓	120	115	170	100	95
51	46	4,000	42	29	13	3 ↓	145	120	120	120	120
20	54	Regressed	44	29	15	3.2 ↓	150	90	20	130	120
18	60	2,300	35	21	14	2.2 ↓	100	100	140	50	115

The arrow in the abdominal vena cava column indicates direction of flow toward ↑ or away ↓ from the liver. Occluded hepatic vena cava and occluded peripheral vena cava measurements refer to pressures above and below the level of temporary occlusion of the inferior vena cava between the liver and the renal veins respectively.

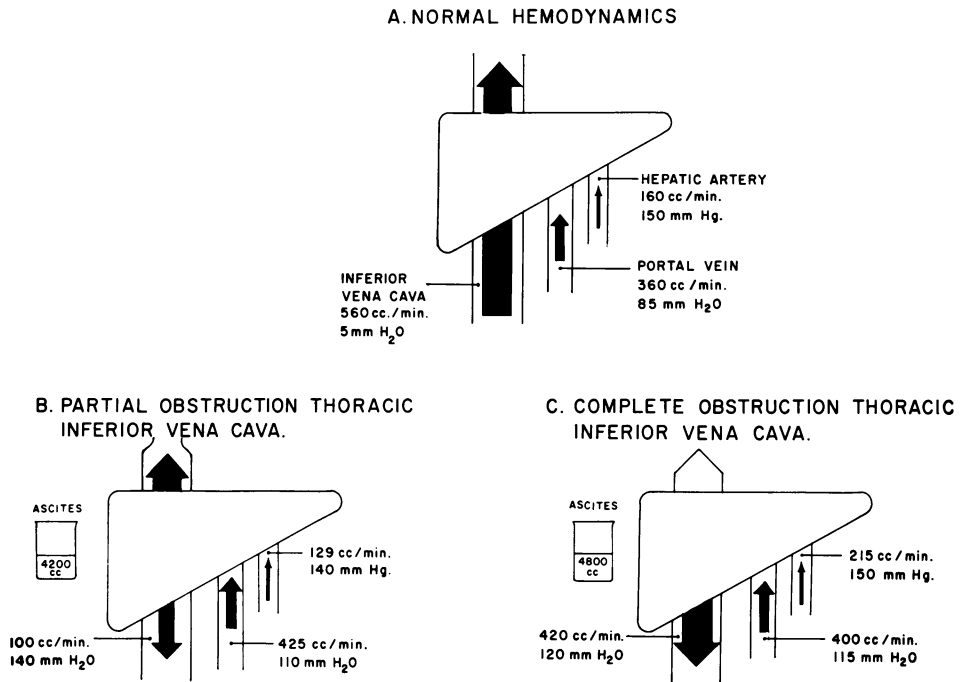


FIG. 10. Diagram of Hepatic Hemodynamics: In A are shown pressure and flow measurements in a typical normal dog, indicating the point at which flow and pressure measurements were made. Direction of blood flow is shown in the inferior vena cava, portal vein and hepatic artery. In B, marked elevation of inferior vena cava pressure with reversal of flow below the liver is shown. Normal hepatic artery and portal vein flow and pressure are present. In C, following complete obstruction of the vena cava above the liver, all vena cava flow is reversed with marked pressure elevation. Hepatic artery flow, portal vein flow, and pressure remain normal.

liver frequently does not alter the portal pressures.

It might be postulated that normal portal pressures exist at the expense of diminished portal flow by diversion of blood through rapidly developing collateral channels. The evidence from our experiments makes this hypothesis untenable. Total hepatic blood flow and differential portal vein and hepatic arterial flow remained normal in all ascitic animals studied. The absence of any demonstrable collaterals in the portal bed further confirmed the findings of lack of stagnation of portal blood flow.

It would appear, therefore, that although the formation of lymph by the liver is greatly accelerated in the presence of the venous outflow obstruction produced in these experiments, obstruction sufficient to alter portal flow was not present. The ex-

planation that portal flow and pressure remain normal because of the rapid formation of lymph acting as a "bleed-off" mechanism does not seem plausible if one compares the normal hepatic blood flow (measured on an average as 24 liters/hour in a 10-kg. dog) to the lymph flow. The possibility exists, however, that the period of study of up to two months in these animals was not of sufficient duration to produce the anatomical alterations within the liver necessary to alter blood flow.

To what extent studies of experimental ascites in the dog with an admittedly different portal and hepatic circulation may be related to clinical studies of hepatic hemodynamics in humans is difficult to establish at the present time. The implication exists, however, that the presence of ascites due to outflow obstruction of the

TABLE 4. *Hemodynamic Studies in Ascitic Dogs—Complete Ligation Thoracic Vena Cava*
Reversal of abdominal vena cava flow is shown in each animal.

Exp. No.	Days	Ascites cc.	Blood Flow cc./kg./min.				Venous Pressure mm. H ₂ O				Mean Blood Pressure mm. Hg
			Total Hepatic	Portal Vein	Hepatic Artery	Abdominal Vena Cava	Portal Vein	Hepatic Vena Cava	Occluded Hepatic Vena Cava	Occluded Peripheral Vena Cava	
41	29	1,800	27	7	20	25 ↓	110	150	250	110	110
37	37	4,500	30	14	16	22 ↓	135	115	145	60	100
36	41	3,200	28	20	8	20 ↓	165	130	150	70	140
13	42	4,500	39	24	15	20 ↓	150	120	150	60	100
40	43	800	27	18	9	23 ↓	130	130	250	50	110
33	60	4,800	41	27	14	27 ↓	115	120	170	65	115

liver may not be accompanied by portal hypertension or diminished or reversed portal flow. Studies of portal pressure, while helpful, may be misleading for normal portal pressures can exist with diminished or normal portal flow. It has been established experimentally in our laboratory that portal volume flow is more labile than portal pressure.⁹ Large increases or decreases in portal volume flow were accompanied by little or no change in portal pressure. Preliminary studies also show that portal vein flow and hepatic arterial flow are inter-dependent, for a marked increase in hepatic arterial flow can occur in the experimental animal or in humans following temporary occlusion of the portal vein or after porta-caval shunt.

In light of these experiments it is evident that more thorough studies of hepatic hemodynamics, including volume flow, would be indicated in the search for adequate treatment of the clinical ascites of liver disease.

Summary and Conclusions

1. Chronic ascites and persistent venous congestion of the liver were produced in the dog by partial and complete ligation of the supradiaphragmatic vena cava.

2. Dilatation of the hepatic lymphatics and marked increases in lymph flow and pressure were present. Weeping of lymph from the hepatic capsule was also noted. Studies of hepatic lymph revealed a high concentration of protein, approaching plasma levels.

3. Flow measurements with the square-wave electromagnetic flowmeter revealed a mean total hepatic blood flow in normal dogs of 39 cc./kg./min. with a portal vein/hepatic artery flow ratio of 2:1. In an occasional animal equal flows from each vessel or reversal of this ratio was present.

4. In ascitic dogs studied at periods up to two months following the development of ascites, mean total hepatic blood flow was 39 cc./kg./min. (partial constriction) and 32 cc./kg./min. (complete ligation). Portal vein/hepatic artery flow ratios remained normal in all animals. No changes in flow or pulsatile patterns were noted.

5. Many collaterals developed in the inferior vena below the point of obstruction with reversal of blood flow and persistent elevation of caval pressures. Portal vein pressures remained normal and no collateral formation was noted in the portal bed.

Bibliography

1. Cain, J. C., J. H. Grindlay, J. L. Bollman, E. V. Flock and F. C. Mann: Lymph From the Liver and Thoracic Duct: An Experimental Study. *Surg., Gynec. & Obst.*, **85**:559, 1947.
2. Davis, J. O., M. J. Goodkind, M. M. Pechet and W. C. Ball: Increased Excretion of Aldosterone in Urine From Dogs with Right-Sided Congestive Heart Failure and From Dogs with Thoracic Inferior Vena Cava Constriction. *Am. J. Physiol.*, **187**:45, 1956.
3. Grindlay, J. H., E. V. Flock and J. L. Bollman: Hepatic Lymph and Ascitic Fluid Following Experimental Chronic Obstruc-

- tion of the Inferior Vena Cava. *Fed. Proc.*, 7:45, 1948.
4. Hyatt, R. E., G. H. Lawrence and J. R. Smith: Observations on the Origin of Ascites from Experimental Hepatic Congestion. *J. Lab. and Clin. Med.*, 45:274, 1955.
 5. Longmire, W. P., Jr., D. G. Mulder, P. S. Mahoney and S. W. Mellinkoff: Side-to-Side Portacaval Anastomosis for Portal Hypertension. *Ann. Surg.*, 147:881, 1958.
 6. Madden, J. L., J. M. Lore, Jr., F. P. Gerold and J. M. Ravid: The Pathogenesis of Ascites and a Consideration of Its Treatment. *Surg., Gynec. & Obst.*, 99:385, 1954.
 7. McIndoe, A. H.: Vascular Lesions of Portal Cirrhosis. *Arch. Path.*, 5:23, 1928.
 8. Schilling, J. A., A. B. McCoord, S. W. Clausen, S. G. Troup and F. W. McKee: Experimental Ascites. Studies in Electrolyte Balance in Dogs With Partial and Complete Occlusion of the Portal Vein and the Vena Cava Above and Below the Liver. *Jour. Clin. Invest.*, 31:702, 1952.
 9. Stewart, J. D., J. G. Stephens, M. B. Leslie, B. A. Portin, and W. G. Schenk, Jr.: Portal Hemodynamics Under Varying Experimental Conditions. *Ann. Surg.*, 147:868, 1958.
 10. Volwiler, W., J. H. Grindlay, and J. L. Bollman: The Relation of Portal Vein Pressure to the Formation of Ascites, An Experimental Study. *Gastroent.*, 14:40, 1950.
 11. Warren, W. D. and W. H. Muller, Jr.: A Clarification of Some Hemodynamic Changes in Cirrhosis and Their Surgical Significance. *Ann. Surg.*, 150:413, 1959.
 12. Welch, C. S., H. F. Welch, and J. H. Carter: The Treatment of Ascites by Side-to-Side Portacaval Shunt. *Ann. Surg.*, 150:428, 1959.

DISCUSSION

DR. JOHN STEWART: The preparation used in these experiments was employed by Starling as long ago as 1895, in his classic researches on the forces controlling the movement of water and solutes through the capillary wall. We recognize that this preparation results in venous stasis in the adrenal cortex and in the kidney as well as in the liver. The anatomical and physiological data reported by Dr. Drapanas suggests, however, that the ascites can best be explained on the basis of Starling's theory.

Transudation of albumin-rich fluid must occur from the sinusoids of the swollen liver which is receiving a normal flow of hepatic and portal blood but which is drained against a high venous pressure. Whether there is any proper analogy with cirrhosis and ascites is doubtful, though if pressure could be measured in the sinusoids of the cirrhotic liver the question might be answered.

Presumably the ascites which may be seen in the chiari syndrome and in chronic constrictive pericarditis offers a closer parallel to the experimental ascites of this study.

The data presented illustrate the importance of instrumentation in present day medical research. Until recently it has not been possible to quantitate blood flow in intact vessels and particularly in small veins.

I would like to take the occasion to express my appreciation for the fine paper that Dr. Cannon presented to you on the measurement of blood flow using the electromagnetic flowmeter.

It would seem that the solution of the clinical problems of portal hypertension may depend on precise measurements of hepatic artery and caval flow. These parameters undoubtedly vary at different stages of the disease. Certainly, direction and volume of flow is a more critical factor than pressure in selecting the proper surgical operation for a given case.

DR. WORTHINGTON G. SCHENK, JR.: Since the initiation of the studies reported by Dr. Drapanas, we have had one opportunity to make flow measurements in a patient undergoing operation for treatment of chronic intractable ascites due to hepatic cirrhosis.

(Slide) This slide summarizes the flow data. I would make four points in relation to it. The first is that the hepatic artery to portal vein flow ratio is normal. The second is that the total hepatic blood flow is somewhat low, being 20 cc./kg./body weight/min. The third is that the direction of portal vein flow is all toward the liver; that is, the portal vein is not an outflow tract in this particular patient. Finally, the hepatic artery flow more than doubled following the creation of a shunt.

It is apparent, I think, that we must make many more such studies before any conclusions can be drawn in relation to patients.

DR. WILLIAM V. McDERMOTT: I would like to point out what a very elegant and precise study this was, again, like Dr. Cannon's paper, employing electronic technics in the measurement of flow