

# SARCOIDOSIS PRODUCING PORTAL HYPERTENSION\*

TREATMENT BY SPLENECTOMY AND SPLENORENAL SHUNT

ROBERT A. MINO, M.D., ARTHUR I. MURPHY, JR., M.D.

WILMINGTON, DEL.

AND

ROBERT G. LIVINGSTONE, M.D.

CAMBRIDGE, MASS.

FROM THE SURGICAL SERVICE OF DR. JAMES G. SPACKMAN, MEMORIAL HOSPITAL,  
WILMINGTON, DEL.

MUCH ATTENTION HAS BEEN GIVEN to veno-venous shunts in the operative treatment of portal hypertension since Blakemore and Lord perfected the nonsuture, Vitallium tube technic of blood vessel anastomosis. The recent publications of Blakemore, Whipple, Blalock, Welch, and Linton and their colleagues afford an excellent summary of the currently established indications, technics, and immediate clinical results of these procedures.

The etiologic aspects of portal hypertension have also been reviewed in these reports. Sarcoidosis of the liver, a subject which has been omitted from consideration, has apparently not been encountered as a cause of this condition.

The present communication is an account of our experience with splenectomy and splenorenal venous anastomosis in the treatment of the incapacitating symptoms of portal hypertension caused by sarcoidosis of the liver.

## CASE REPORT

Mrs. E. C. (M. H. 62, 286), a Negro housewife 26 years old, was admitted to the Memorial Hospital on November 24, 1947, because of marked dyspnea and ascites. These symptoms were related to sarcoid infiltration of the liver and the spleen.

Her first admission to this hospital had occurred on November 12, 1943, three weeks after the onset of multiple joint pains, shortness of breath on slight exertion, and weakness of both legs. The details of her family history and past history were irrelevant. Her arms and legs were covered with discrete, indurated areas of pigmentation which also involved the trunk. Many shot-like lymph nodes, the largest 1 and 2 cm. in diameter, were encountered in the axillary, epitrochlear, inguinal, and femoral regions. The liver edge was palpable 8 cm. below the costal margin, and the spleen was enlarged to the level of the umbilicus. Routine examinations of the blood and of the urine disclosed no abnormalities. A chest film showed extensive, patchy lesions in the peribronchial areas, especially in both lower lobes. There were no roentgenographic changes in the bones of either hand. The presumptive diagnosis of sarcoidosis was established by histopathologic study of an excised cervical lymph node.

Trial of a variety of therapeutic measures in the out-patient department failed to prevent a gradual increase in the severity of the symptoms. Ascites was demonstrable after 18 months of treatment, and on two occasions hospitalization was required because

---

\* Submitted for publication November, 1948. Grateful acknowledgment is made to Dr. John F. Hynes, Director of the Carpenter Memorial Tumor Clinic; to Dr. John W. Hooker, Pathologist; and to Dr. Robert W. Frelick, former Resident in Medicine, for their valuable assistance and suggestions in the treatment of this patient.

of the progressive disability which followed. Thorough clinical and laboratory studies, throughout the period of illness, indicated that the only active foci of disease were present in the spleen and liver and possibly in the spinal cord. A state of total invalidism was believed to be at hand when accentuated symptoms led to the present readmission.

*Physical examination.* The patient at this time was a thin young Negro woman with a strikingly enlarged, protuberant abdomen. Her weight was 135 pounds, and at the level of the umbilicus the circumference of her abdomen was 36 inches. A definite cyanosis of the nail beds was observed, and a slight degree of dyspnea was evident at rest. There were no apparent changes in the lesions of the skin or in the groups of enlarged lymph nodes which had previously been noted. The blood pressure was 110/72; the pulse rate was 88. The heart and lungs were normal. The liver edge extended to the umbilicus. The limits of the spleen were at the midline and at the left anterior superior iliac spine. There was moderate ascites. The knee and ankle jerks were absent. There was marked weakness of the extensor muscles of the thighs and lower legs, and there was moderate weakness of the other muscle groups. No peripheral edema was apparent.

*Laboratory findings.* The red cell count was 3,400,000, the hemoglobin level 12.5 Gm., and the white cell count, 5,000. A differential count of 71 per cent neutrophils, 23 per cent lymphocytes, 2 per cent monocytes, and 4 per cent eosinophils was noted. The coagulation time was 3½ minutes; the bleeding time was 2½ minutes. The platelet count was normal. The prothrombin time was 52 per cent of the control. The plasma protein level was 6.61 Gm. per 100 cc., representing 2.75 Gm. per 100 cc. of albumin and 3.86 Gm. per 100 cc. of globulin. With the bromsulfalein test there was 10 per cent retention in 30 minutes and 5 per cent retention in 1 hour. The cephalin cholesterol flocculation was 4 plus. The Congo red and galactose tolerance tests were negative. The concentration of the blood urea nitrogen was 20 mg. per 100 cc. The urea clearance was 113 per 100 cc. The phenolsulfonphthalein test was normal.

A complete examination of the cerebrospinal fluid revealed no abnormalities. A chest film also indicated that there had been no changes in the peribronchial lesions.

*Operation.* Splenectomy, with the creation of a veno-venous shunt, was recommended as the only therapeutic measure thought to offer any prospect of relief. Preliminary treatment by transfusions and by the administration of a diet low in fat and high in carbohydrate and in protein constituents was therefore instituted.

The operation was performed on December 11, 1947, (R. A. M.) with the patient under spinal and supplemental intravenous anesthesia. There was a moderate amount of clear ascitic fluid in the abdominal cavity. The visible serosal surfaces were smooth and glistening. The spleen was smooth, dark gray, and very firm to touch; it extended to the midline and to the level of the left anterior superior iliac spine. The liver was somewhat hob-nailed in appearance and also very firm to touch; its edge was at the level of the umbilicus. There were numerous retroperitoneal lymph nodes, the largest almost 3 cm. in diameter. An accessory spleen was found which was about 6 cm. in diameter. The uterus and ovaries were extremely atrophic. Moderately enlarged veins were observed in the gastrohepatic omentum and elsewhere in the portal area. The left renal vein was about 1.5 cm. in diameter, the splenic vein about 10 mm. in diameter.

The pressures in the coronary and middle colic veins were found to be equivalent to 175 mm. of saline solution.

No unusual difficulty was experienced in the removal of the spleen. The pressure in the splenic vein was subsequently found to be equivalent to 180 mm. of saline solution. In view of the appearance of the liver, the increased venous pressures were interpreted as evidence that the portal hypertension was of intrahepatic origin.

An end-to-side anastomosis of the splenic and renal veins, with preservation of the kidney, was therefore created, the presence of enlarged lymph nodes and plexuses of small blood vessels having been considered as a contraindication to the formation of a

portacaval shunt. The axial placement of a rubber-covered "McWhorter delicate model gallbladder forceps"\* on the renal vein in the course of this procedure was found to be a very satisfactory method for securing partial occlusion of this vessel. The parallel closing of its very narrow blades assures an even grasp upon the vessel wall, and the flexibility of their structure results in minimal trauma to the intimal surfaces. Subsequent palpation of the anastomotic site indicated that the stoma was almost 1 cm. in diameter.

Additional determinations of the pressures were then made in various tributaries of the portal vein before the abdomen was closed. The lowest reading taken was found to be equivalent to 90 mm. of saline solution, but the accuracy of these results was considered questionable since no appreciable fluctuations of the column were associated with the respiratory movements.

The patient tolerated this procedure very well. During the operative period of approximately eight hours she received a total of 5,500 cc. of fresh citrated blood and 1,000 cc. of 5 per cent glucose in normal saline solution. She was returned to her bed with a blood pressure of 100/70 and a regular pulse rate of 110.

*Postoperative course.* A variety of complications developed in the postoperative period. Additional heparin was given to maintain a carefully controlled, prolonged coagulation time, but gross hematuria was noted ten hours after operation, in association with a rapidly falling blood pressure and a diminishing red cell count. The heparin was discontinued, and a total of 2,000 cc. of freshly withdrawn blood was given in the following five hours. The blood pressure was restored to normal levels by this treatment, and the subsidence of the hematuria was shortly afterwards observed. Abdominal distention in this period also made continuous gastric suction necessary. Dyspnea and cyanosis became evident 24 hours after operation. A bronchoscopic examination demonstrated an obstructing edema of the mucosa of the left lower bronchus which was attributed to the aspiration of gastric content during anesthesia. An oxygen tent afforded some relief from these symptoms. Considerable difficulty was then experienced in the management of the electrolyte balance, but with the administration of parenteral solutions a gradual return to normal was eventually observed.

A normal temperature was attained on the tenth postoperative day, and a soft solid diet, rich in protein constituents, was tolerated at this time. Fever reappeared a few days later, and in spite of massive doses of penicillin and streptomycin a subdiaphragmatic abscess developed on the left. An intravenous pyelogram demonstrated normal function and appearance of both kidneys. The abscess was incised and drained on January 17, 1948, with the patient again under spinal anesthesia. The cultures revealed strains of *Staphylococcus aureus* and *Bacillus coli* which were markedly resistant to the antibiotic agents. A superficial infection of the primary wound required drainage somewhat later, and a large decubitus ulcer finally appeared over the sacral area. This ulcer was excised on February 25, 1948, and the resulting wound was closed with a sliding flap of skin and subcutaneous tissue.

An uneventful convalescence then occurred. Healing progressed rapidly, the dyspnea and ascites disappeared, and the patient soon exhibited a ravenous appetite. The red cell count was 3,830,000, the hemoglobin level 12.5 Gm., and the white cell count 18,000. The prothrombin time was 100 per cent of the control. The plasma protein level was 6.39 Gm. per 100 cc. representing 2.45 Gm. per 100 cc. of albumin and 3.94 Gm. per 100 cc. of globulin. The cephalin cholesterol flocculation was 3 plus. With the bromsulfalein test there was 4 per cent retention in 30 minutes and no retention in 1 hour. Discharge from the hospital was granted on March 20, 1948, approximately 3½ months after operation.

*Pathologic examination.* The operative specimens included several retroperitoneal

---

\* This instrument is supplied by V. Mueller and Company, Chicago.

lymph nodes, a wedge of tissue from the left lobe of the liver, the spleen, an accessory spleen, and a portion of the tail of the pancreas.

The spleen measured 28 by 18.5 by 12 cm. and weighed 2,250 Gm. (Fig. 1). There were scattered fibrinous adhesions and focal areas of hyalocapsulitis on the diaphragmatic surface of its capsule. It was abnormally firm. On section it was rusty brown in color, rubbery, and uniformly sprinkled with minute, somewhat reddish areas (Fig. 2).

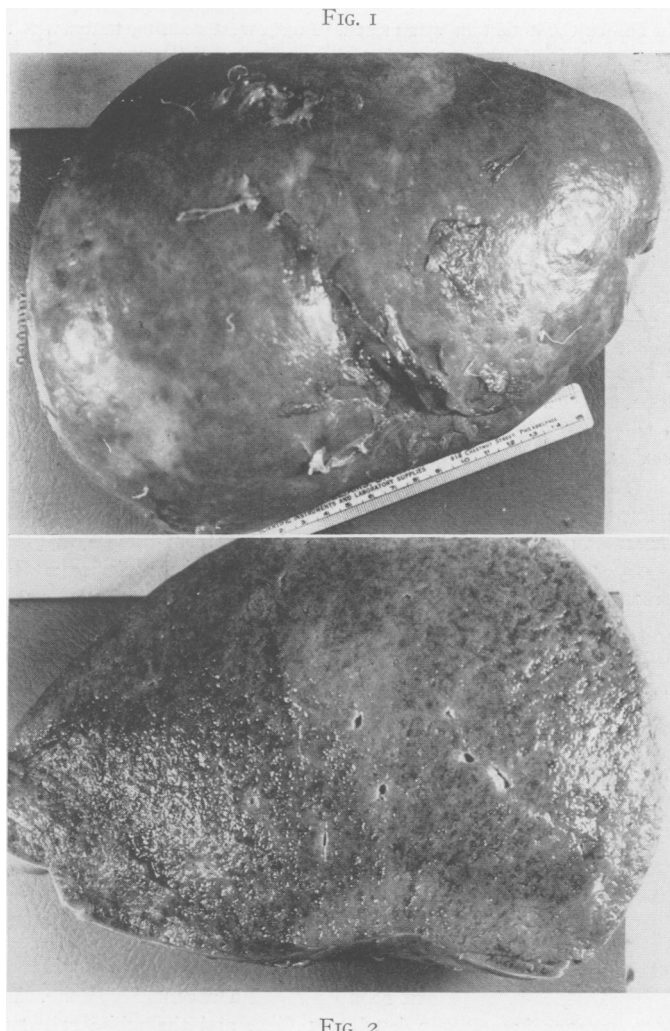

FIG. 1.—The appearance of the spleen (weight 2,250 Gm.) immediately after its removal.

FIG. 2.—A cut section of the spleen.

Similar characteristics were shown by the accessory spleen.

The lesions of Boeck's sarcoid were beautifully demonstrated in the sections of the lymph nodes (Figs. 3 and 4). Definite groups of epithelioid cells were present without evidence of giant cells or of caseation necrosis.

There were also definite and extensive sarcoid lesions in the spleen (Fig. 5). Giant

cells of the Langhan's type were present, and "asteroid" inclusion bodies were occasionally noted. A fibrinoid necrosis was displayed in the central areas of many of the lesions, and in these instances a circumferential zone of partially necrotic, partially hyalinized and regenerating fibrous connective tissue was observed. There was no involvement of the intima of the veins.

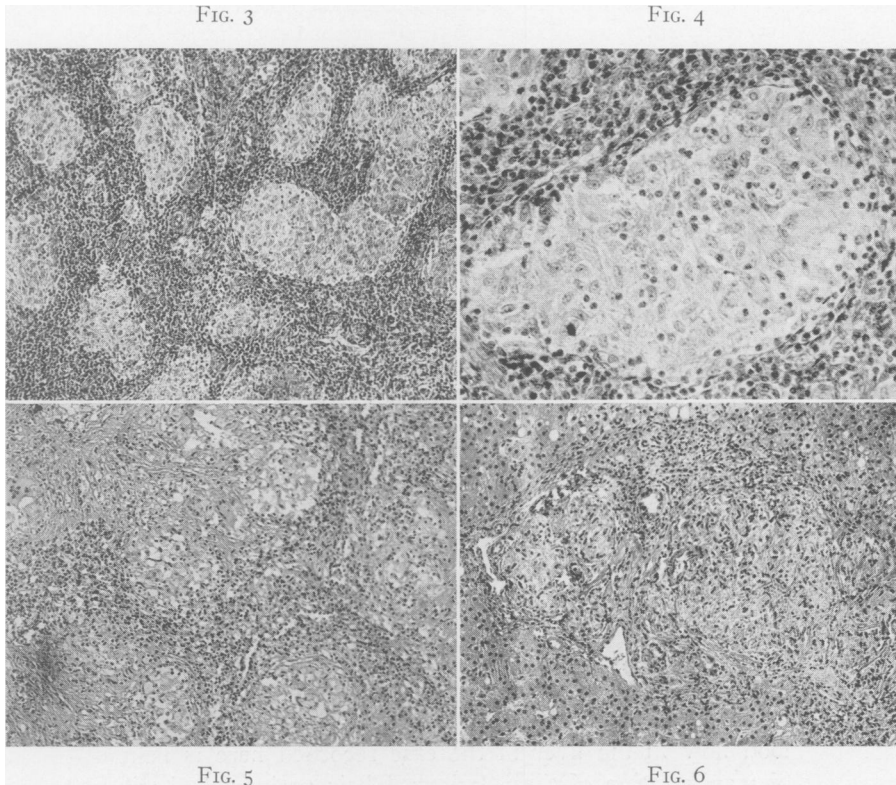


FIG. 3.—Sarcooid lesions in a retroperitoneal lymph node. The typical clusters of broad epithelioid cells show no evidence of giant cells or of caseation necrosis. (x 60)

FIG. 4.—Detailed view of a sarcooid lesion in a retroperitoneal lymph node. (x 175)

FIG. 5.—Sarcooid lesions in the spleen. The parenchyma is shown to be extensively involved. (x 60)

FIG. 6.—Sarcooid lesions in the liver. There is a coalescence of the lesions about the portal triad shown in the center of the field. (x 60)

The lesions in the tissue from the liver were found primarily about the tributaries of the portal vein in many of the portal triads (Fig. 6). There was occasional involvement also of the central lobular veins. A striking infiltration of the walls of several of the larger, apparently sublobular veins was evident in other sections (Fig. 7). No focal hemorrhages had occurred, although the lesions had encroached upon the intimal surfaces. A comparable infiltration has already been described by James and Wilson in the walls of the smaller splenic veins, but its occurrence in the walls of the hepatic veins is not known to have been previously reported. These findings serve to explain the mechanism of the portal hypertension in this case of sarcooidosis.

Special stains of all these tissues revealed no acidfast bacilli.

*Subsequent course.* The patient has exhibited a very gratifying clinical response since her discharge from the hospital. She resumed her lighter household duties a few months postoperatively. As her ravenous appetite continued, her weight soon increased to 144 pounds, but the persistence of the weakness of her legs led her to accept a somewhat restricted diet. One year after operation the red cell count was 3,500,000, the hemoglobin level 14.5 Gm., and the white cell count 14,400. The plasma protein concentration was 7.10 Gm. per 100 cc. representing 3.00 Gm. per 100 cc. albumin and 4.10 Gm. per 100 cc. globulin.

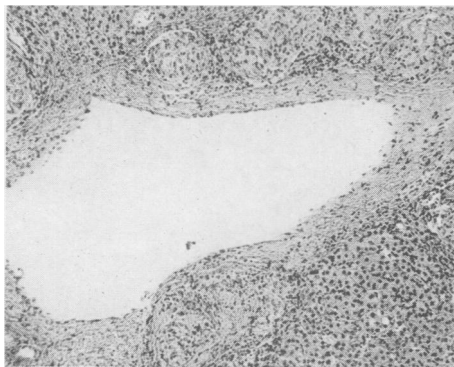

FIG. 7.—Sarcoid infiltration of the wall of a large hepatic vein. (x 60)

The cephalin cholesterol flocculation was 4 plus. With the bromsulfalein test there was 8 per cent retention in 30 minutes and 8 per cent retention in 1 hour. A chest plate showed slight clearing of the peribronchial lesions.

At the most recent visit, 18 months postoperatively, the patient weighed 130 pounds. The circumference of her abdomen was 24 inches. There was no evidence of ascites, dyspnea, or edema. The liver edge was palpable approximately 6 cm. above the umbilicus. The weakness of her legs had not been changed. The patient was noticeably alert, active, and cheerful.

#### COMMENT

The extensive infiltration of the spleen and liver is of special interest in this case. Nickerson, Harrell, Longcope, and Reisner have observed that involvement of these organs frequently occurs in sarcoidosis, and Nickerson and Longcope have reported that splenectomy has been performed in certain instances of this disease in the erroneous belief that the preoperative signs and symptoms were evidence of Banti's syndrome. The serious obstruction of the venous blood flow in the liver in the case recorded here is believed to be an unusual manifestation of these lesions. Their periportal distribution was undoubtedly a most important factor in the production of the ascites. The spleen is also thought to be the largest yet described in sarcoidosis.

It is evident that ascites has rarely been encountered as a complication of this disease. Reisner has described a peritoneal effusion in one case in his series, but he has attributed this finding to sarcoid infiltration of the serous membranes.

The indication for operative intervention in the case reported here was the presence of the progressive, incapacitating ascites. It is realized that sarcoidosis is a generalized disease in which the clinical manifestations vary in accord with the extent and distribution of the lesions, and it is also recognized that the occurrence of spontaneous remissions or exacerbations makes the prognosis difficult in the individual case. The patient in this instance was observed, however, for a period of four years, and, except for its progression in the spleen and liver and possibly in the spinal cord, the disease in her case was believed to have become quiescent. She was obviously being reduced to a state of invalidism, and operative treatment was thought to offer

her the only possibility of relief. The venous shunting operations are not advised in sarcoidosis unless the primary disease has become stationary and incapacitating ascites or bleeding from esophageal varices has occurred. The prognosis should be guarded in spite of operation.

#### SUMMARY

A case of portal hypertension which was caused by sarcoidosis of the liver is reported, and a histopathologic explanation of the mechanism of this syndrome in sarcoidosis is presented.

Treatment by splenectomy and splenorenal venous anastomosis is advised in this condition when the primary disease has entered a quiescent phase and when evidence of bleeding or of incapacitating ascites has occurred. A satisfactory result has been obtained in the case reported here 18 months postoperatively.

#### BIBLIOGRAPHY

- <sup>1</sup> Blakemore, A. H.: Indications for Portacaval Anastomosis—Analysis of Cases. *Surg., Gynec. & Obst.*, **84**: 645, 1947.
- <sup>2</sup> —————: Portacaval Anastomosis. *Surg., Gynec. & Obst.*, **87**: 270, 1948.
- <sup>3</sup> —————: The Portacaval Shunt in the Surgical Treatment of Portal Hypertension. *Ann. Surg.*, **128**: 825, 1948.
- <sup>4</sup> Blakemore, A. H., and J. W. Lord, Jr.: A Nonsuture Method of Blood Vessel Anastomosis. *Ann. Surg.*, **121**: 435, 1945.
- <sup>5</sup> —————: Technique of Using Vitallium Tubes in Establishing Portacaval Shunts for Portal Hypertension. *Ann. Surg.*, **122**: 476, 1945.
- <sup>6</sup> Blalock, A.: The Use of Shunt or By-pass Operations in the Treatment of Certain Circulatory Disorders, including Portal Hypertension and Pulmonic Stenosis. *Ann. Surg.*, **125**: 129, 1947.
- <sup>7</sup> Harrell, G. T.: Generalized Sarcoidosis of Boeck. *Arch. Int. Med.*, **65**: 1003, 1940.
- <sup>8</sup> James I., and A. J. Wilson: Spontaneous Rupture of the Spleen in Sarcoidosis. *Brit. J. Surg.*, **33**: 280, 1945-1946.
- <sup>9</sup> Linton, R. R.: Portacaval Shunts in the Treatment of Portal Hypertension. *New England J. Med.*, **238**: 723, 1948.
- <sup>10</sup> Linton, R. R., I. B. Hardy, Jr., and W. Volwiler: Portacaval Shunts in the Treatment of Portal Hypertension. *Surg., Gynec. & Obst.*, **87**: 129, 1948.
- <sup>11</sup> Linton, R. R., C. M. Jones and W. Volwiler: Portal Hypertension. Treatment by Splenectomy and Spleno-renal Anastomosis with Preservation of the Kidney. *Surg. Clin. N. America*, **27**: 1162, 1947.
- <sup>12</sup> Longcope, W. T.: Sarcoidosis, or Besnier-Boeck-Schaumann Disease. *J. A. M. A.*, **117**: 1321, 1941.
- <sup>13</sup> Nickerson, S. A.: Boeck's Sarcoid: Report of Six Cases in which Autopsies Were Done. *Arch. Path.*, **24**: 19, 1937.
- <sup>14</sup> Reisner, D.: Boeck's Sarcoid and Systemic Sarcoidosis. *Am. Rev. Tuberculosis*, **49**: 289 and 437, 1944.
- <sup>15</sup> Welch, C. S.: A Technique for Portacaval Anastomosis (Eck fistula). *Surg., Gynec. & Obst.*, **85**: 492, 1947.
- <sup>16</sup> Whipple, A. O.: The Problem of Portal Hypertension in Relation to Hepatosplenopathies. *Ann. Surg.*, **122**: 449, 1945.