

CONGENITAL ANEURYSM OF SUPERIOR VENA CAVA*

REPORT OF ONE CASE WITH OPERATIVE CORRECTION

OSLER A. ABBOTT, M.D.

ATLANTA, GEORGIA

FROM THE DEPARTMENT OF SURGERY (THORACIC), EMORY UNIVERSITY SCHOOL OF MEDICINE

PRIMARY ANEURYSMS of venous structures are a considerable rarity. The discovery of a large, probably congenital aneurysm of the superior vena cava, with apparent operative correction is felt to be sufficiently unusual to justify a case report. The author has not been able to find a report of a similar case either in life, or upon autopsy examination.

The patient, Mr. H. S., a 19-year-old white male college student, was seen in consultation on February 17, 1948. The only reason for consultation was the discovery of a large mass in the region of the superior mediastinum, on the right. The family history was not unusual. There was no history of antecedent serious illness, and no history of previous injury to the thoracic cage. He was born at full term without any difficulties associated with the labor, and his mother had experienced no unusual diseases during the period of pregnancy. The patient had never been known to show evidence of cyanosis; hemoptysis was denied, and there were no unusual sensations in the thorax, and there had been no dyspnea. He had been able to take part in strenuous physical exercise without difficulty. He had no knowledge of any thoracic abnormality until a 70 mm. screening roentgen ray film was taken in January, 1948. An unusual superior mediastinal shadow was noted, and therefore the patient was recalled and a complete roentgen ray study carried out.

It was of interest to discover that this patient had a similar 70 mm. roentgen ray film taken November 22, 1946, and this showed the lesion to be present at that time, but apparently smaller in size. No previous roentgen ray examination of the patient had been performed.

The findings on the roentgen ray studies are presented in Figures 1 and 2. Figure 1 shows the inspiration chest roentgen ray taken November 22, 1946, while Figure 2 shows the P. A. view roentgenogram taken on full expiration. The patient was subjected to a very intensive roentgen ray investigation. Fluoroscopy and film studies were carried out February 18, 1948, by Dr. T. F. Leigh. His notes, made at that time, read as follows: "Fluoroscopy and films of the chest demonstrated a unilateral enlargement of the superior mediastinum on its right side. This mass appeared to lie anteriorly, was sharply outlined laterally, but could not be seen on its medial border. The mass markedly changed shape when visualized in deep inspiration and deep expiration. A further change of shape from the standing to the horizontal position was noted. It was of homogeneous density and contained no calcium. There was no displacement of the trachea or the esophagus by the described mass. It appeared to move paradoxically in relation to the aortic pulsations. It could not be determined whether its movements were due to intrinsic or transmitted pulsations. The lungs otherwise appeared normal. The heart was normal in size."

On February 26, 1948, angiocardiographic studies were carried out by Doctor Leigh (See Figs. 3 and 4). The description of his findings at that time read as follows: "Films of the heart and great vessels were made in the right posterior oblique position after the injection of 70 per cent Diodrast into the right antecubital vein. The contrast media appears to show a fusiform dilatation of the superior vena cava. A part of this dilatation probably also includes the right innominate vein. The vena cava has a trans-

* Submitted for publication April, 1949.

FIG 1

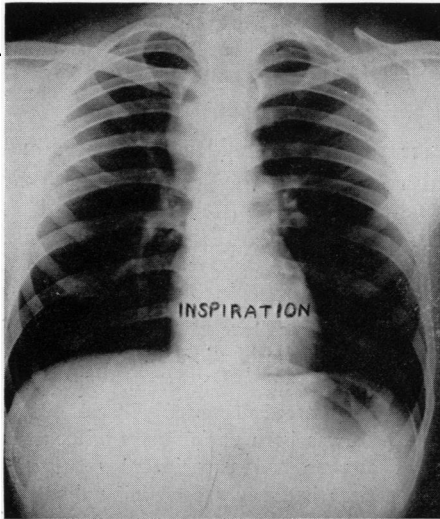


FIG. 2

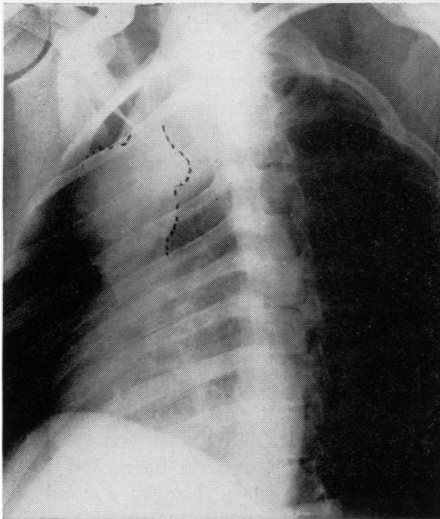
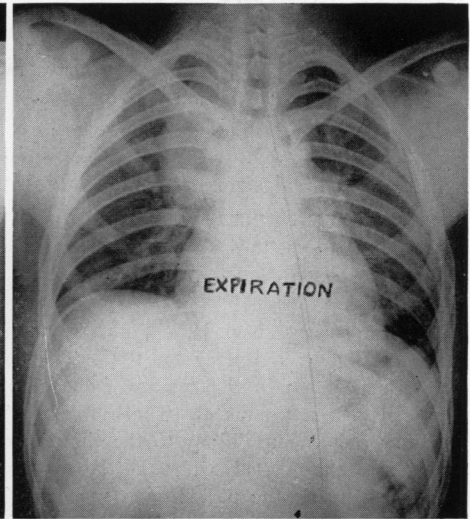


FIG. 3

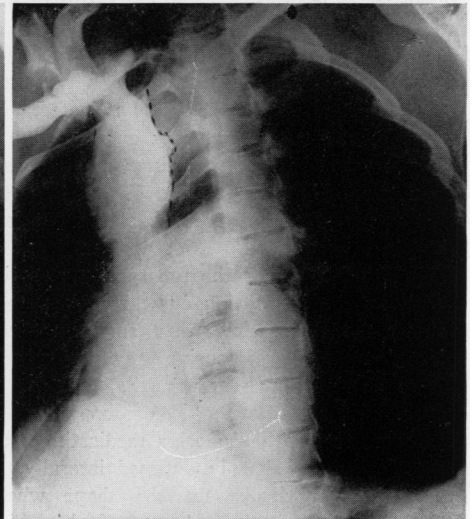


FIG. 4

FIG. 1.—Postero-anterior roentgen ray projection February, 1948. Note the right paramediastinal shadow demonstrates considerable translucency.

FIG. 2.—Postero-anterior roentgen ray projection February, 1948. Compare this film taken on full expiration with the inspiration film shown in Figure 1.

FIGS. 3 and 4.—Figure 3 demonstrates the findings noted on the primary positioning film taken in the right oblique. This position was found to give maximal visualization of the lesion. Figure 4 denotes the filling of the aneurysmal area in the right innominate vein and superior vena cava. Note irregularity on postero-medial surface, which is too far posterior to be a part of the left innominate vein.

verse diameter of 5 cm. It contracts down to apparent normal size just before entry into the heart. The borders of the mass can be seen extending approximately 1 cm. beyond the border of the opaque column in some areas. This would indicate that the vena cava has either a thick wall or that there is a compression of the vena cava causing its dilatation through broadening and flattening by an extra-vascular mass. There is no apparent obstruction to the passage of the opaque media. The examination discloses no other abnormal findings in relation to the cardiac chambers, pulmonary vascular bed, or first portion of the aorta."

On physical examination the patient appeared to be a very healthy individual. There were no definable abnormal physical findings. The blood pressure in the right arm was 110/80, in the left arm was 120/80, and in the right leg was 132/85. The venous pressure readings were determined in both arms: Right arm 130 mm. blood, left arm 109 mm.

The patient was studied by the method of cardiac catheterization, but these studies appeared somewhat to confuse the issue. The pressure readings within the superior vena cava, right auricle and right ventricle were within normal limits. There appeared to be a one volume per 100 increase in the oxygen content of the blood obtained from the superior vena caval area in contrast to those obtained from the right auricle and right ventricle. With the catheter in the superior vena cava, Diodrast was injected and failed to show the dilatation noted on the previous angiocardiographic studies. These studies seemed to indicate that the superior vena cava itself was not enlarged, but distorted by a nearby mediastinal tumor. The variance in the oxygen content of the blood in the superior vena cava in contrast to that within the cardiac chambers suggested the possibility of an arterio-venous communication.

In view of the unknown nature of the mass plus evidence of enlargement of the mass in the roentgen ray studies over a two-year period, it was felt advisable to recommend exploratory thoracotomy. On July 23, 1948, exploratory thoracotomy was carried out under endo-tracheal gas-oxygen-ether anesthesia. The antero-lateral approach was used with subperiosteal resection of the anterior two-thirds of the right third rib. On entering the pleural cavity some dense adhesions were noted between the posterior and medial surfaces of the right upper lobe, and the adjoining chest wall and mediastinum. Palpation revealed an irregular ovoid firm mass in the superior mediastinum with nodular enlargements on the medial and posterior surface. The upper lobe was dissected free from the mediastinum, and a large mass in the region of the superior vena cava and right innominate veins was seen. The two nodular areas described appeared to be daughter aneurysms.

Multiple grape-sized, small aneurysms were found to be present on the antero-medial surface of the large aneurysmal area in the superior vena cava, and this aneurysmal enlargement was also found to involve the proximal 2 cm of the major azygos vein as it entered into the superior vena cava. The right phrenic nerve was found to be firmly adherent to the aneurysm, and was carefully dissected away. The aneurysmal wall appeared to be very thin except in the region of the two daughter aneurysms which apparently contained clots. The one on the posterior surface had the appearance of a false sac. The entire superior vena cava and right and left innominate veins were carefully dissected free and surrounded by a double sheet of polythene cellophane which had been prepared by boiling. The cellophane was sutured in place by means of a No. 4-0 deknotel silk to nearby structures, and the aneurysm completely surrounded, including the proximal 4 cm. of the right innominate vein, and the proximal 3 cm. of the azygos major vein. The point of entry of the left innominate vein into the aneurysm was protected by non-reactive cellophane. A long free graft of pleura was then obtained from the posterior chest wall and used to surround the phrenic nerve throughout the area in which it would lie over the region of the aneurysm surrounded by polythene cellophane. The chest wall was closed in layers in the usual manner. The patient

withstood the procedure well. The postoperative course was remarkably smooth, and he was discharged on the sixteenth postoperative day. There was no visible evidence of increased venous pressure in the upper extremities at the time of discharge and the venous pressure readings at that time were almost exactly the same as those prior to operation.

The patient's physical activities were moderately restricted for the first three months following operation, and he was not allowed to indulge in strenuous exercise until six months after surgery. He was studied frequently by means of fluoroscopy and roentgen ray examination. During the postoperative period there seemed to be some slight increase in the size of the mass during the first two months following operation (See Fig. 5). On January 21, 1949, six months after the operative procedure, the patient was again subjected to angiocardigraphic studies (See Fig. 6). Doctor Leigh's

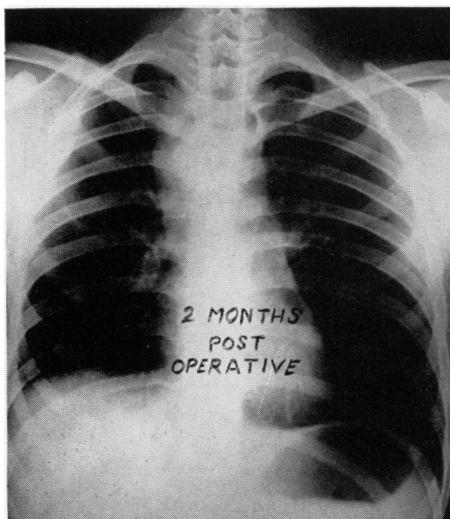


FIG. 5

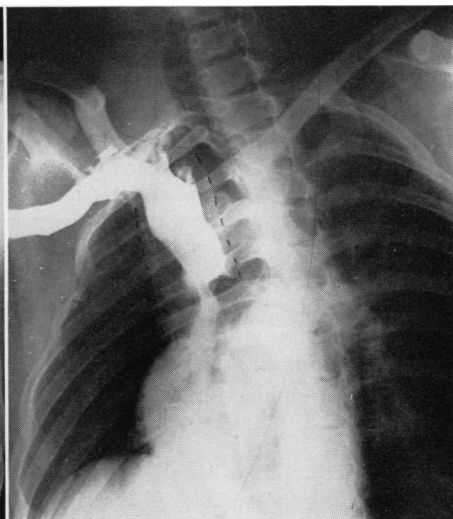


FIG. 6

FIG. 5.—Postero-anterior roentgen ray projection taken September, 1948. Note evidence of moderate enlargement of the paramediastinal shadow which is expected during the first three months after Polythene cellophane application.

FIG. 6.—Angiocardiographic study performed January, 1949. This shows definite decrease in the size of the lumen of the aneurysmal area and definite thickening of the aneurysmal wall.

report reads as follows: "Repeat angiocardigraphic studies of the right innominate vein and superior vena cava reveal a moderate reduction in the size of the aneurysm in these vessels. Just distal to the aneurysm there is a mild narrowing of the vena cava, but this does not appear to be obstructing the flow of the contrast media into the heart. Opinion: Reduction in size of aneurysm postoperatively of the right innominate and superior vena cava veins. Moderate constriction of the superior vena cava just distal to the aneurysm."

Patient has had repeated studies of venous pressure during the intervening months, and there has been no alteration in these findings. Examination of venous pressure on February 3, 1949, revealed the venous pressure in the right arm to be 128 mm. of blood, and that in the left arm to be 122 mm. of blood. There has been no evidence of abnormal collateral venous circulation appearing over the thorax or upper extremities. Patient has been totally asymptomatic, and has been able to continue a full schedule in the University.

SUMMARY AND CONCLUSIONS

The roentgen ray and clinical findings of a patient having a congenital aneurysm of the superior vena cava and right innominate veins has been described. The diagnostic measures utilized, the roentgen ray findings, and the findings at the time of operation have been described in detail because of the apparent unique character of this lesion. It is noted that the aneurysm of the superior vena cava showed changes in size and shape with inspiration and expiration comparable to other thin-walled cysts of the mediastinum. The angiocardiographic studies performed by means of injection of 70 per cent Diodrast into the antecubital vein proved to be of considerably more value than did the study carried out with a ureteral catheter within the lumen of the aneurysmal structure. The cardiac catheter studies were not thought to be of value in this patient, but actually appeared to confuse the issue. It is also believed, after direct visualization of the extremely thin wall of the lesion at the operating table, that the catheter could constitute an extremely dangerous procedure, and in fact, might even have been responsible for the false saccular aneurysm on the posterior surface of the lesion. It is felt that the character of the wall of the aneurysm would not have allowed any attempt at plication methods, and that the only satisfactory method of attack was by means of the use of polythene cellophane. It is also considered to be extremely important that this material not be prepared by soaking in alcohol. The alcohol may dissolve the di-acetyl phosphate contained in the substance which is necessary for the production of the marked fibroblastic reaction. The patient has been observed over a period of seven months following the operative procedure, and it is not felt that further obliteration of the lumen of the vena cava should occur due to the surrounding polythene cellophane. Comparison of pre- and post-operative angiocardiographic visualization of the aneurysmal structure has shown a very definite improvement in the size of the lesion, with marked thickening of the aneurysmal wall.