

TRANSMETATARSAL AMPUTATION FOR INFECTION OR GANGRENE IN PATIENTS WITH DIABETES MELLITUS*

LELAND S. MCKITTRICK, M.D., JOHN B. MCKITTRICK, M.D.
AND THOMAS S. RISLEY, M.D.

BOSTON, MASSACHUSETTS

FROM THE NEW ENGLAND DEACONESS HOSPITAL.

This might be considered a report of progress in the surgical management of lesions of the lower extremities in patients with diabetes mellitus. Fifteen years ago in a paper before this Association, one of us¹ in analyzing the deaths following amputations for gangrene, pointed out that the mortality rate was 13.7 per cent; that about 10 per cent of these patients died as the result of uncontrolled sepsis; that if and when some mechanism other than surgery was developed for the control of infection, we might anticipate a mortality following major amputation of about 5 per cent.

Chemotherapeutic agents and the antibiotics have made it possible to control invasive infection, and the mortality rate has fallen as anticipated (Table I). This is of particular significance in the management of these patients with diabetes mellitus, because this control of invasive infection invited a different approach to a selected group of cases. With the danger of ascending infection and septicemia eliminated, it might now be practical to consider each foot on the basis of its arterial supply. In selected cases, amputation might now be performed at a more distal level with safety and a reasonable chance of success. There was reason to believe that if all or part of the toe was gangrenous, amputation through the foot just proximal to the heads of the metatarsals would be more likely to succeed than removal of the toe alone. Such an amputation would, in addition, offer the patient protection against subsequent involvement of the remaining toes, and would give him a useful foot.

In 1944 we did our first transmetatarsal amputation for gangrene of a toe in a diabetic patient. The lesion in this patient was one for which we had previously considered amputation through or above the mid-lower leg as the operation of choice. The operative wound healed promptly. There have been 215 such amputations done at the New England Deaconess Hospital up to January, 1949,† and sufficient time has elapsed to permit a study of these cases in an attempt more clearly to delineate the indications and the technic, and to review the early and late results.

* Read before the American Surgical Association, St. Louis, Mo., April 22, 1949.

† We are indebted to Drs. T. C. Pratt and C. C. Franseen for permission to include patients operated upon by them and for their cooperation in obtaining follow-up data on their patients.

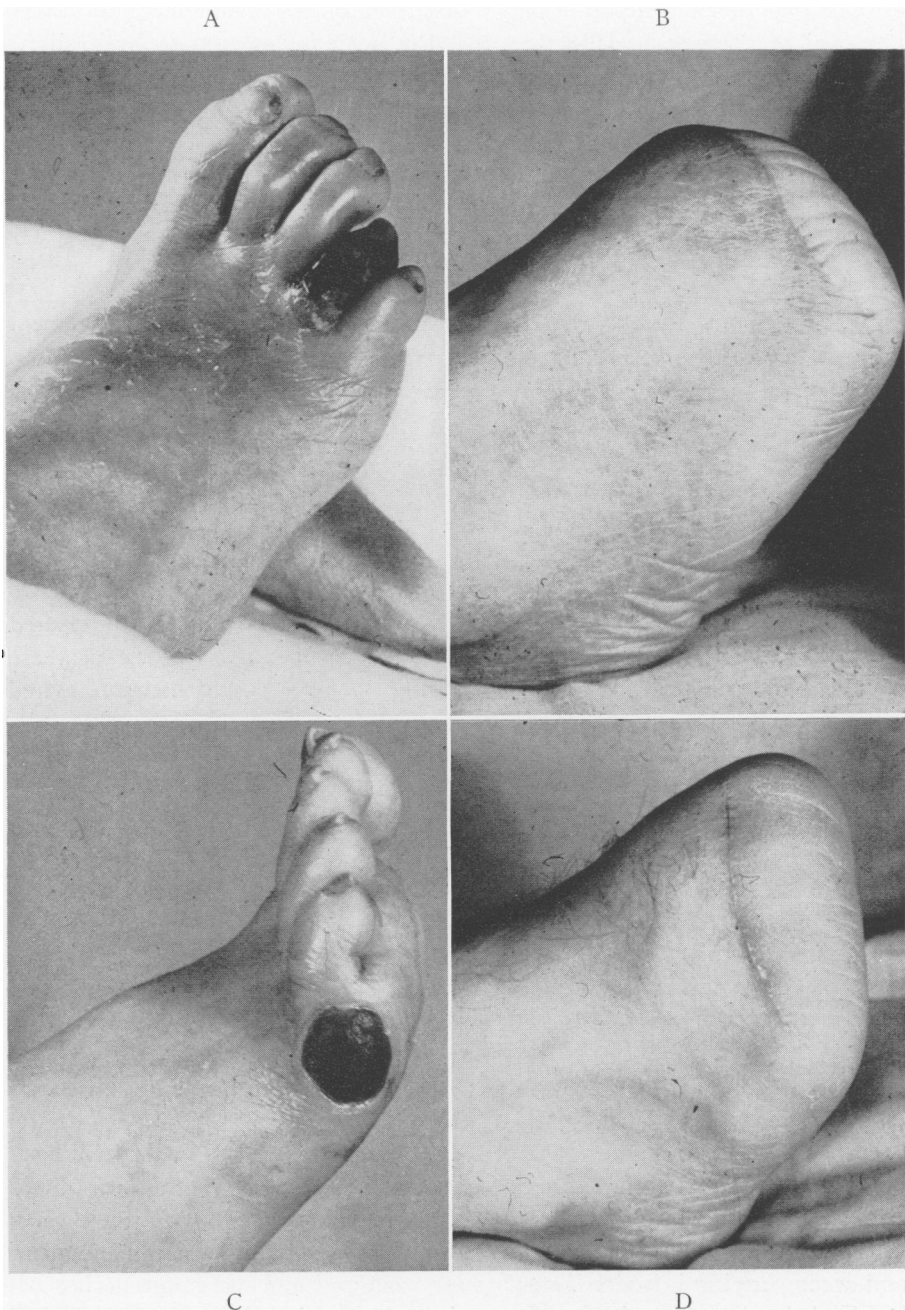


FIG 1.—Gangrene of toe (A) and lateral aspect of base of fifth toe (C). Successful transmetatarsal amputation in these two patients (B & D)

INDICATION

Our experience will permit only a discussion of the anatomical indications. Removal of a toe, especially the great toe, with its metatarsal head, alters weight bearing and increases the vulnerability of the remaining toes; therefore, we prefer the relative security of the transmetatarsal amputation. Factual

TABLE I.—Mortality Following Major Amputations 1923-1949, New England Deaconess Hospital

Period	No. Cases	No. Deaths	Mortality (%)
1923-1941	680	93	13.7
1941-1949	358	20	5.5

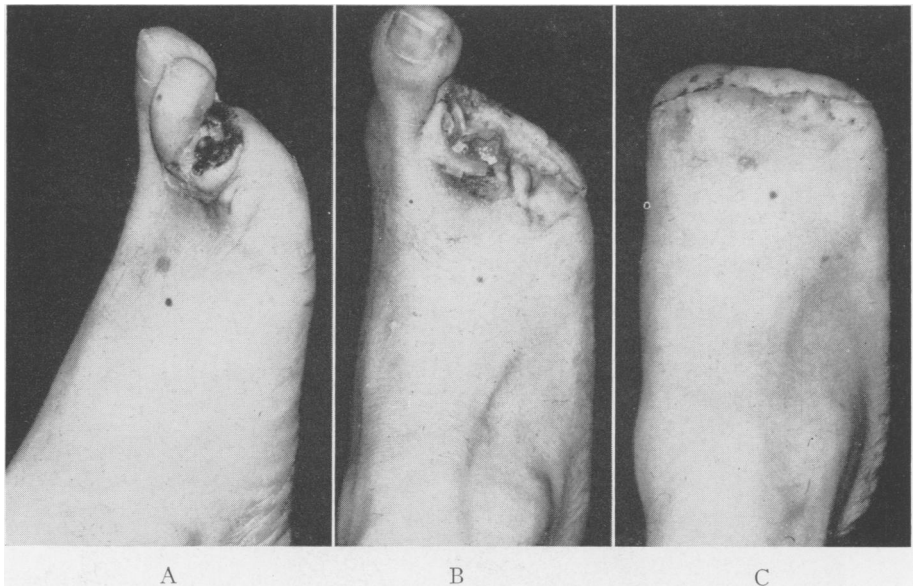


FIG. 2.—Exemplifying total excision of open wound and primary closure of transmetatarsal amputation: (A) Initial lesion; (B) local excision of initial lesion and drainage of soft tissue infection; (C) hospital result 18 days post transmetatarsal amputation.

evidence to support this preference is not at hand but, with this thought in mind, we have advised this procedure for the following indications:

1. Gangrene of all or part of one or more toes, providing that the gangrene and accompanying infection *have become stabilized* and the gangrene has not involved the dorsal or plantar aspect of the foot (Fig. 1).

2. A stabilized infection or open wound involving the distal portion of the foot, when total excision of the infected area with primary or delayed closure can be accomplished (Fig. 2).

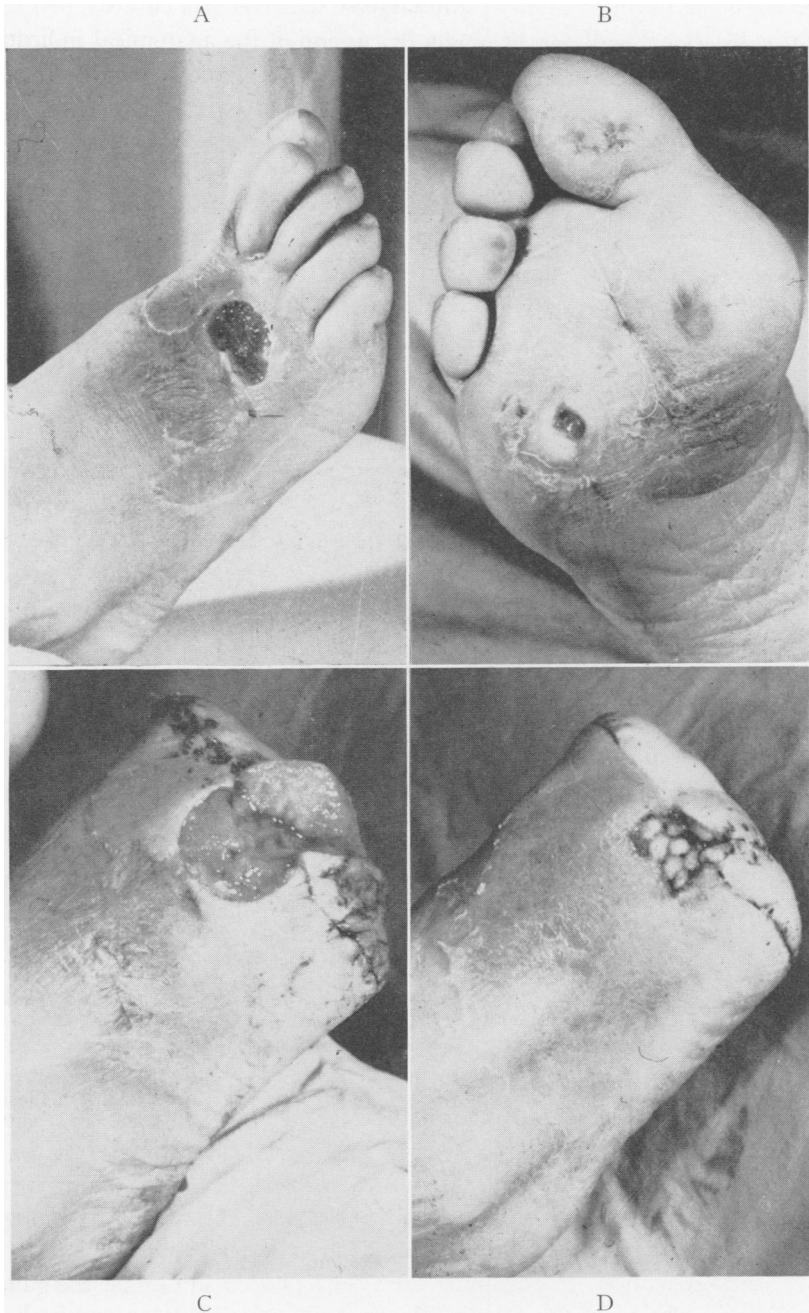


FIG. 3.—Neurogenic foot with destruction of third and fourth metatarsophalangeal joints. Partially closed amputation with subsequent secondary closure of plantar flap and pinch grafts to dorsum. Area of anesthesia totally excised: (A) and (B) presenting lesion; (C) transmetatarsal amputation; area of local infection left open; (D) delayed suture of plantar defect and pinch grafts to dorsal granulating wound nine days post-amputation.

3. An open, infected lesion in a neurogenic foot (a) as a curative procedure when the entire area of anesthesia can be excised (Fig. 3), or (b) as a delaying procedure when the area of infection can be excised but the line of incision is through the area of anesthesia (Fig. 4).

GANGRENE

We know of no way to determine accurately that a transmetatarsal amputation will be successful in a foot whose arterial blood supply is deficient. If the process is stabilized, and if gangrene and infection are well demarcated, there is a borderline group where only trial and error will give the final

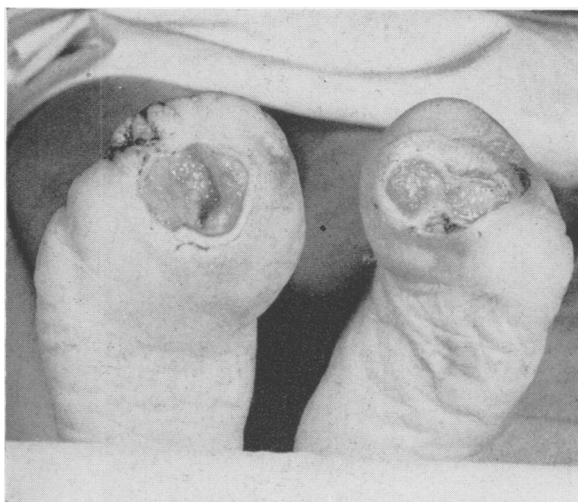

FIG. 4.—Recurrent ulceration on amputation stumps in anesthetic plantar flap. Good circulation and diabetic neuropathy.

answer. With experience we become increasingly accurate in the estimation of the potentialities of the circulation of a given foot, but we are not able always to foretell the outcome with accuracy. We are sometimes pleasantly surprised to obtain early and prompt healing (Fig. 5), just as we are occasionally disappointed to find necrosis and delayed healing or failure to heal (Fig. 6). If the gangrene has extended onto the dorsal or plantar aspect of the foot, only rarely will this procedure be successful. Occasionally an area of gangrene may extend slightly onto the medial or lateral aspect of the foot and can be excised without jeopardizing the result (Fig. 1). On the other hand, when the circulation in the foot is adequate, infection may extend well onto the foot and not contraindicate the operation (Fig. 3).

Excision of area of infection. One of the most satisfactory by-products of this operation for gangrene has been its adaptation to a group of patients where the circulation in the foot has been reasonably good, but where the pre-

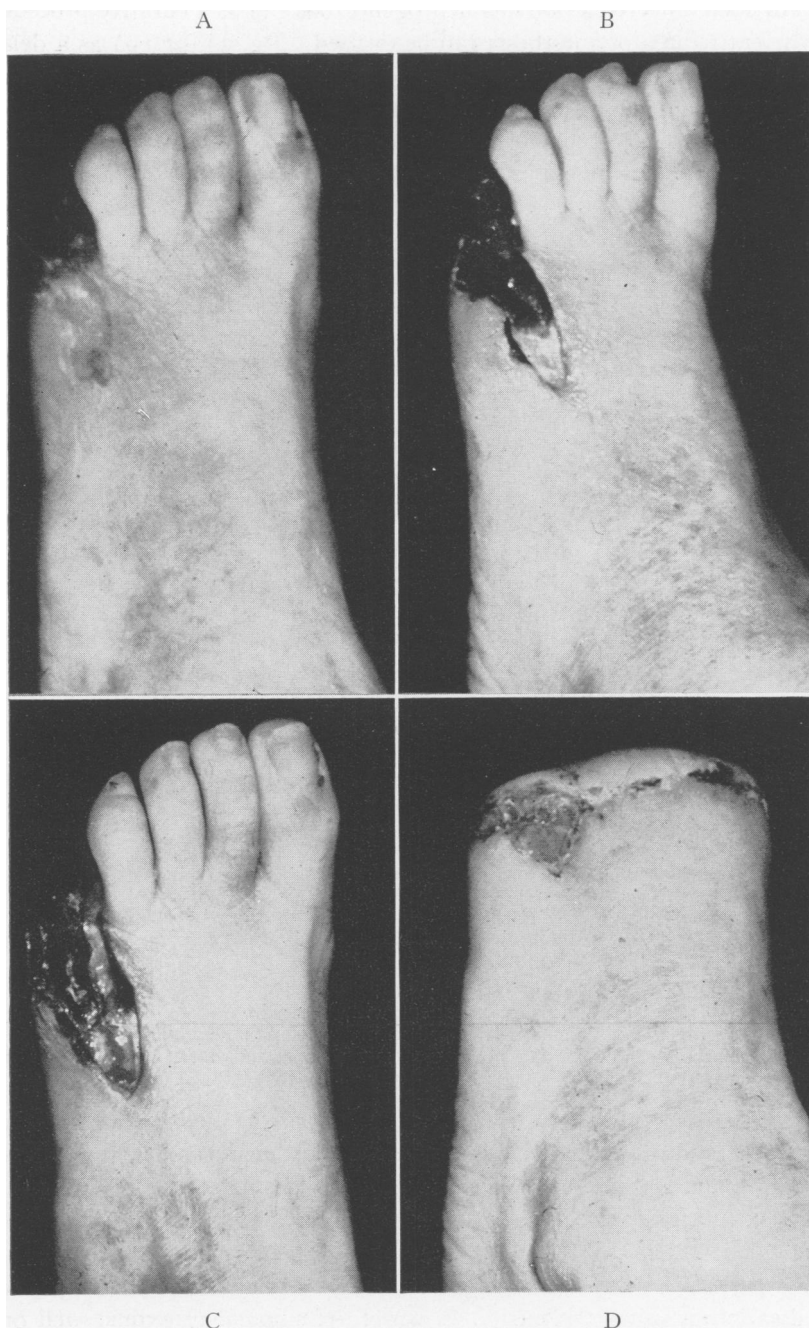

FIG. 5.—Successful transmetatarsal on an extremity with very poor circulation. A failure was anticipated. (A) presenting lesion showing gangrene of the fifth toe, ulceration onto dorsum with diffuse, surrounding cellular reaction; (B) and (C) progressive localization and demarcation; (D) hospital result 21 days post-amputation. The defect on the dorsum is not yet healed.

dominant factor has been infection. We have now had a modest number of patients who entered the hospital with severe local infection, usually involving one of the metatarsophalangeal joints and not infrequently the web space. Initial drainage with or without amputation of one or more toes has been carried out in order to control the infection. After the process has become stabilized it has been possible to do a transmetatarsal amputation, excising the entire granulating area. The edges of the newly made wound are carefully approximated with steel wire (Fig. 2). In a few of these cases a small segment of the wound has been packed loosely with gauze and allowed to heal by secondary intention. In others, a granulating area on the dorsum of the foot has then been covered with pinch grafts removed from the amputated segment (Fig. 7).

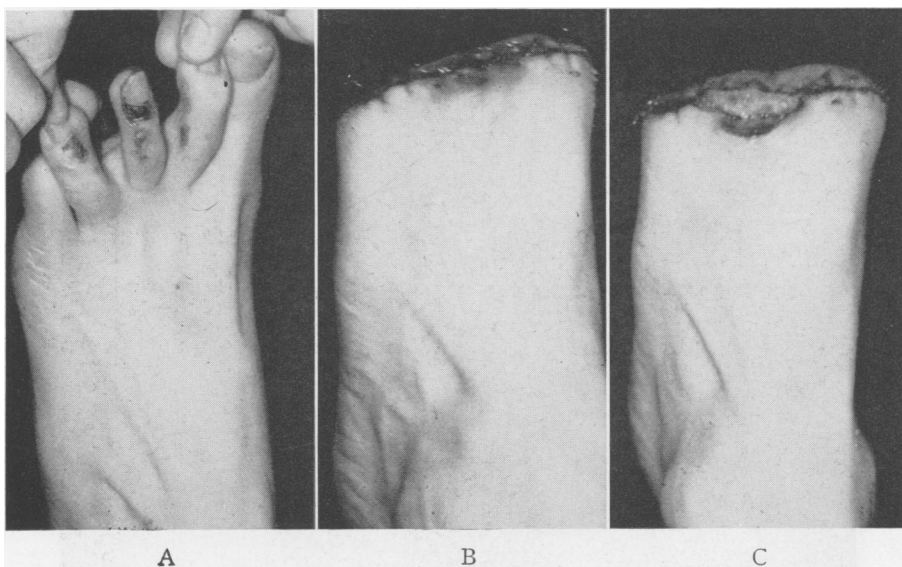


FIG. 6.—Immediate failure in a patient with poor circulation but in whom a successful result was anticipated. (A) presenting lesion; (B) and (C) progressive dorsal necrosis within 12 days postoperatively. Supracondylar amputation done three days after (C).

Neurogenic lesion. These lesions are the most disturbing and baffling of all of the lesions that we see in this group of patients. In most instances there is an open, infected area on the plantar aspect of the foot, surrounded by an area of thick callus, and frequently leading into a metatarsophalangeal joint. There is partial or complete anesthesia to pin prick in the involved area. The arterial supply is usually adequate. A variety of surgical procedures has been utilized for this condition and healing is usually prompt. In almost all instances, however, there will be recurrence in spite of any precaution we have been able to take, unless all of the anesthetic area on the plantar aspect of the foot can be excised. If the incision on the plantar aspect is through skin

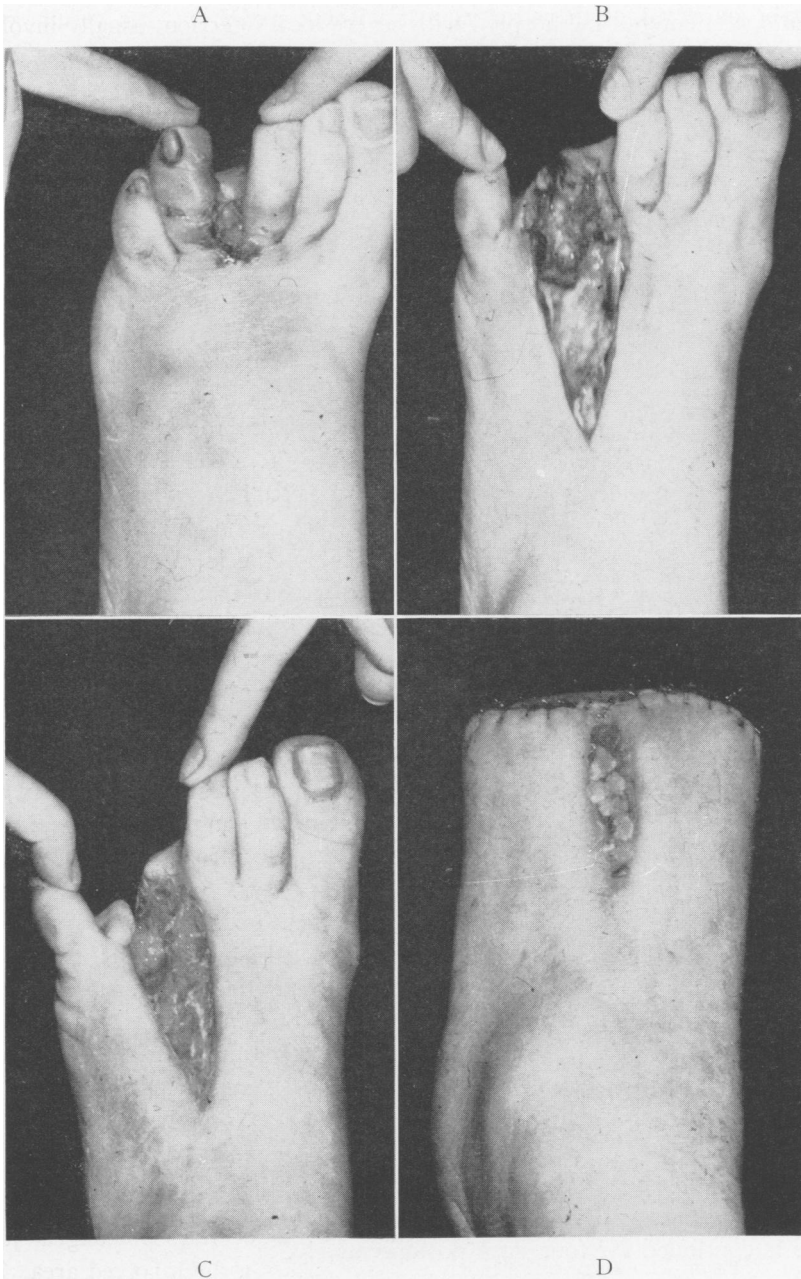


FIG. 7.—An example of preliminary drainage of infection followed in 23 days by closed transmetatarsal amputation. The pinch grafts were taken from the amputated forefoot. (A) presenting lesion; (B) preliminary drainage; (C) stabilized, open wound immediately pre-amputation; (D) hospital result 10 days post-amputation.

with normal sensation, not only will healing be complete, but a good result may be expected. Otherwise, almost without exception, the result will be merely a delaying one (Figs. 3 and 4).

PREPARATION FOR OPERATION

Probably the most important single factor favoring a successful outcome in a patient with borderline circulation is selection of the proper time for operation. Just when this is we are not certain; but every effort should be made to

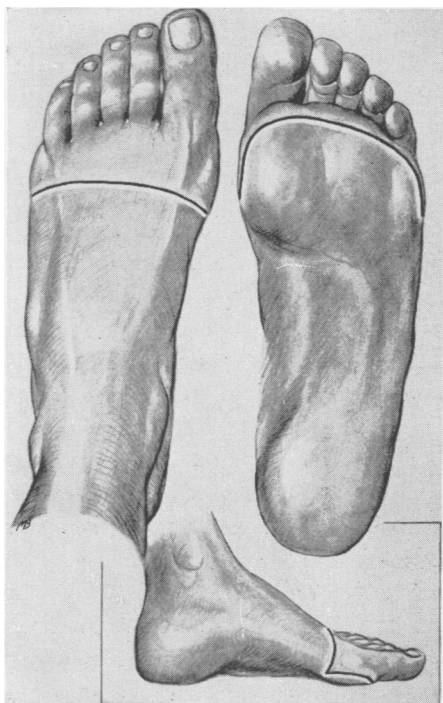


FIG. 8.—Illustration showing line of incision. Note long plantar flap.

do the operation after the gangrene and infection have demarcated. We know from past experience that patients entering the hospital with severe pain will continue to benefit from the hospital routine for a period of two to three weeks. We have, therefore, taken approximately three weeks as the period during which adjustment of the local circulation may be expected to take place. Maximum improvement should then be evident and the patient ready for operation. Patients are given penicillin, usually a preparation of procaine penicillin G, 300,000 units once or twice daily if infection is present in association with the area of gangrene. When infection has been controlled, usually in five to seven days, penicillin is stopped. Buerger exercises are started and continued for approximately two weeks. Patients with more favorable circulation may be operated upon at an earlier time. During this period of

preparation the general condition of the patient is supported; transfusions of blood are given to obtain a hemoglobin of 13 Gm. or more; the diabetes is adjusted and every effort is made to have both the patient and the local area in the best possible condition for operation. During the 24 hours before the time of operation, the patient is given 600,000 units of the procaine penicillin G. This is continued for four days postoperatively.

TECHNIC OF OPERATION

A low spinal anesthesia has been used for all of these operations. The lines of incision are shown in Figure 8. The long plantar flap is important because experience has shown that the blood supply to this flap is much better

than that to the dorsal flap. Great care is taken to make the incisions decisive, using a sharp knife which is changed after the skin incision has been made. There is no undermining or dissection of the dorsal flap, but the incision is carried directly down to the bone. Dissection of the plantar flap is kept close to the underlying bone. Each metatarsal is divided just proximal to its head with bone forceps. All sesamoid bones are removed. No special attention is given to the tendons. Careful hemostasis with a minimum of trauma is essential. Closure is carried out in one layer using a serum proof suture material to approximate the skin edges. Fine (No. 38) stainless steel wire has proved the most satisfactory in our hands. Closure of the wound is started from each end, to insure accurate approximation at these two vulnerable areas. There must be no tension to the suture line, nor should the flaps be redundant. The wound is not drained.

POSTOPERATIVE CARE

An important feature of the postoperative, as well as the preoperative care is the position of the patient in bed. In order that the extremity not be blanched and the veins remain full, the head of the bed is elevated so that the heart is always at a slightly higher level than the most distal portion of the feet. This dependency may be accomplished either by placing shock blocks under the head of the bed or by cranking the head of the bed up to the desired level.

Patients are kept on bed rest in the above fashion for a period of two to two and a half weeks after amputation. One half the stitches are removed about the ninth day, and the remainder between the twelfth and fourteenth day. In preparation for ambulation Buerger exercises are started ten to 15 days postoperatively. Mobilization is begun gradually, starting with one minute three times a day, Buerger exercises are continued, and the amount of walking permitted is gradually increased. Usually the patient is ready for discharge from the hospital three to four weeks after operation. The average postoperative stay for the entire group has been 30 days.

HOSPITAL RESULTS

A total of 215 patients have been operated upon up to January 1, 1949, (Table II). There were two hospital deaths, a mortality of 0.9 per cent. Healing was complete in 155 patients at the time of discharge. Sixty patients failed to heal, and of this group, re-amputation was done at a higher level in 27 patients, with prompt healing in all but one. This latter patient represents one of the fatalities. Thirty-three patients left the hospital with wounds not completely healed.

Fatal Cases. Both patients died of coronary thrombosis. One was a 77-year-old diabetic of 12 years' duration who died on his 48th hospital day, ten days after his transmetatarsal amputation. Preceding the amputation a prostatectomy had been done for urinary retention. The second, a 71-year-old

woman, who had diabetes for 24 years, died on the 24th hospital day. An unsuccessful transmetatarsal amputation had been followed by a supracondylar amputation ten days before death.

Failures. Supracondylar amputation had been advised for five of this group of 27 patients. All of these patients developed early progressive necrosis along the suture line. Most of them had severe local pain in association with the necrosis.

TABLE II.—Hospital Results Following Transmetatarsal Amputation

Indication for Operation	Cases	Healed	Unhealed	Re-amputation	Died
Gangrene.....	145	94	25	26	2
Excision of Infection (neuropathy)	55	46	8	1	0
Excision of Infection.....	15	15	0	0	0
Total.....	215	155	33	27	2

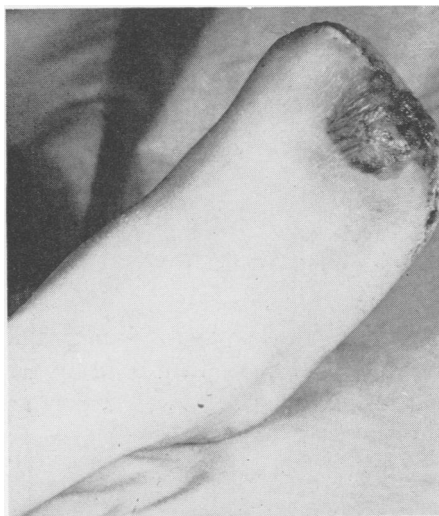

FIG. 9.—Typical dorsal flap necrosis. Subsequent surgical revision was done three and one-half months later with primary healing.

Careful review of the available data does not indicate how a more accurate decision might have been reached. In each case failure was apparently due to arterial insufficiency. A possible exception was a patient with excellent collateral circulation but with no pulsations noted below the level of the femoral artery. This patient was sensitive to penicillin, and is the only patient in the entire series who was operated upon without the protection which this would have afforded. He is also the only patient in this series who developed invasive infection. It was our belief that penicillin would have permitted healing per primum. Rest pain was present in 47.5 per cent of these patients in contrast to 18.1 per cent of the remaining 188. When rest pain

does not entirely disappear during the period of preparation, the prognosis is very poor.

Local Complications. Fifty-three patients in addition to those already discussed, did not heal per primum. Twenty of these were healed at the time of discharge from the hospital. Eight of these patients had a minor separation of skin edges. In the remaining 12 patients, partial primary closure of the wound was followed by secondary suture, skin grafting, or healing by second intention.

The most important local complication in this group of patients was the development of a triangular area of discoloration on the dorsal flap (Fig. 9) which occurs within 10 or 12 days after operation. In many instances this was transient and did not interfere with primary healing. In 33 patients, the discoloration progressed to necrosis of a segment of the dorsal flap, which involved the skin and subcutaneous fat, and which had not healed at the time of discharge from the hospital. If this necrosis is not too extensive, and if it demarcates early, there will be gradual separation of the necrotic tissue. This may take many months, during which time the patient is up and about. In selected cases, after complete separation of the slough, the defect may be closed by excision of the open area, shortening of the underlying metatarsal shaft or shafts, and careful approximation of the skin edges.

LATE RESULTS

Anatomical. One hundred and fifty-five patients left the hospital with their stumps completely healed. We have been unable to learn the present condition

TABLE III.—*Late Results Following Transmetatarsal Amputation; Stumps Healed at Time of Discharge*

Indication	Cases	Recurrent	
		Ulceration	Re-amputation
Gangrene.....	88	10	6
Excision of infection (neuropathy).....	43	14	1
Excision of infection.....	15	0	0
Total.....	146	24	7

of nine of these patients. Twenty-four, or 16 per cent of the remaining 146, have had subsequent trouble (Table III). In ten of these patients the amputation had been done for gangrene. Three of these have developed a small area of necrosis at the medial or lateral corner of the scar. A fourth has a painful fissure of the heel. Six patients have survived successful amputation at a higher level necessitated by further gangrene. These six patients all had useful limbs for a minimum of one year (average 18.7 months). In the neuro-pathic group 14 patients have recurrent ulcerations at a weight-bearing point. One developed a callus and ulceration underlying a bony spur which developed at the transected end of the second metatarsal. This patient was well three months after excision of the spur. Re-amputation was necessary in one patient in this group, a 31-year-old diabetic with excellent circulation. He remained well for one year, then recurrent ulceration and intractable infection resulted in higher amputation.

Thirty-three patients left the hospital with the stump unhealed. Four of these healed in from two to ten months, but their present condition is unknown. Of the remaining 29 patients (Table IV) 13 have subsequently

healed. Five of these had a successful revision of their stump (original amputation for gangrene) and in eight, healing has taken place by secondary intention. In six of the ten patients who remain unhealed the appearance of the local lesion would suggest that ultimate healing and a satisfactory result should occur. In the six patients who have been re-admitted to the hospital and survived amputation at a higher level the intervals between the two amputations have varied from two to ten months. At no time did healing take place in this group.

Functional Results. We can only report upon the function of the transmetatarsal stump as it pertains to this elderly group of people (average age 61.5 years) whose physical activities are of necessity somewhat limited. No patient considered his or her activities to be limited because of the loss of the distal portion of the foot. There is a lack of forward balance. Some patients report that in walking at a rapid pace the foot tires more easily than formerly. All patients walk without a limp. Those with bilateral transmetatarsal stumps (19 patients) use a shortened stride. In all cases this stump has fully met the daily requirements of this group of patients and we feel justified in classifying the functional results as "excellent."

TABLE IV.—*Late Results Following Transmetatarsal Amputations, Stumps Unhealed at Time of Discharge*

Indication	Cases	Healed	Unhealed	Re-amputation
Gangrene.....	22	8	8	6
Excision of infection (neuropathy).....	7	5	2	0
Excision of infection.....	0	0	0	0
Total.....	29	13	10	6

Prosthesis. With but few exceptions these patients have been discharged from the hospital without any special type of shoe. The toe of the shoe of the amputated foot has been filled with lamb's wool to lessen the tendency of the shortened foot to slip forward.

Three patients with unilateral transmetatarsal amputations have had special inner soles made and report that they are very satisfactory. This inner sole consists of a flexible steel plate with the space which the forefoot would have occupied filled with rubber foam. This inner sole is not unlike that described by Bates.² It has given comfort to the end of the amputation and has stiffened the sole, both of which are important features. From this very limited experience it would seem to us that perhaps this may be the simplest and most satisfactory appliance.

Five other patients with unilateral amputations have had a short, narrow, flexible steel plate inserted between the outer and inner sole of the regular shoe. This steel plate extends to the level of the transected metatarsals, and minimizes the annoyance resulting from the flail-like action of the distal,

empty portion of the shoe. This seems a more expensive way to handle the problem and probably no more satisfactory than a well-constructed inner sole. One ingenious patient with a unilateral amputation, a retired cobbler, simply had a cobbler friend do what amounted to a transmetatarsal amputation of his old shoe. This, he says, has been perfectly satisfactory.

All of the patients with bilateral amputations use custom-made short shoes. None of this group has used a shoe of the old size with specially constructed inner soles as described above. It is possible that such a solution would be satisfactory, and if so, the expense of having special shoes made each time a new pair is required would be eliminated. We are impressed that so few of these patients have felt the need for custom-made shoes.

TABLE V.—*Summary of Results*

	Cases	% Total	Follow-up (Months)		
			Av.	Max.	Min.
Satisfactory*.....	135	67	28.5	57	7
Unsatisfactory†.....	32	16	20.8	56	4
Failures‡.....	35	17
Total.....	202	100

*Nineteen patients died at intervals of 8 to 54 months after discharge from the hospital of conditions not related to the amputation.

†Four patients died at intervals of 14 to 35 months after discharge from the hospital of conditions not related to the amputation.

‡Includes the 2 operative deaths.

Summary of Results. If healing has been complete and the amputation stump does not limit the patient's activities, we have classified the result as "satisfactory." If complete healing has not taken place, or if there has been recurrent trouble in relation to the stump but the patient is ambulatory, we have considered the result "unsatisfactory." If healing did not occur, and the open area has progressed resulting in amputation at a higher level, we have called this result a "failure."

The present condition of 202 patients is known (Table V). Thirty-five, or 17 per cent, of these (including the two who died) are failures. Thirty-two (16 per cent) have had one or more of a variety of local symptoms, but still retain limited use of their extremities. These we have considered as unsatisfactory. We feel that the remaining 135 patients, or 67 per cent of the entire group whose present condition is known, have had satisfactory results following their transmetatarsal amputations.

SUMMARY

I. Two hundred and fifteen transmetatarsal amputations have been done from July, 1944, to January 1, 1949, with two hospital deaths, both due to coronary thrombosis.

2. Thirty-three of these failed to heal, and came to amputation at a higher level.

3. The present condition of the remaining 174 patients who left the hospital with a transmetatarsal amputation is known. One hundred and thirty-five of these are completely satisfactory. In 32 patients the end result is still undetermined and is regarded as unsatisfactory. Seven patients have come to higher amputation after complete healing for a minimum of one year.

4. The functional result has been excellent in all successful cases. Most patients with unilateral amputations use lamb's wool in the toe of their own shoe. Three patients use an inner sole insert with a rubber toe, which is probably the best, and five patients use a flexible steel bar between the outer and inner sole.

5. Custom-made short shoes are used by all patients with bilateral amputations, and this is regarded as a satisfactory solution.

6. We consider the results very gratifying, and believe amputation at this level to be a major contribution to the management of this group of patients.

BIBLIOGRAPHY

¹ McKittrick, L. S., and T. C. Pratt: *Ann. Surg.*, **120**: 531, 1944.

² Bates, R. R.: *Surg., Gynec. & Obst.*, **83**: 243, 1946.

DISCUSSION.—DR. LOUIS G. HERRMANN, Cincinnati, Ohio: At the Cincinnati General Hospital we have employed, since 1934, the various conservative amputations through the foot for gangrene of the toes due either to arterial disease or to infection. We agree with Doctor McKittrick and his associates that many lives and many limbs can be saved by such procedures, but we differ with them slightly on certain technical aspects of the operation. It has been our experience that the transmetatarsal amputation gives the most serviceable stump of any of the amputations through the foot. We have allowed the end of the stump to remain open until a healthy granulation tissue base developed, then secondarily closed it by split thickness skin grafts, rather than make large skin flaps and close the stump at the primary operation. In patients without arterial insufficiency, the primary closure of the stump can usually be done safely.

Doctor Furste and I published the end-results of transmetatarsal amputations in 91 patients who were subjected to this procedure between 1934 and 1947. Of these patients, 37 per cent obtained an excellent or good result and a useful weight-bearing foot.

The antibiotics and chemotherapeutic agents have enabled us to control local infection so our future series should present an even higher percentage of useful weight-bearing feet after transmetatarsal amputations. Doctor McKittrick has demonstrated the value of conservative amputation in the diabetic patient and we are in agreement that these operations should be performed more frequently in patients with localized gangrene of the toes

DR. MICHAEL E. DEBAKEY, Houston, Texas: I should like first to express my grateful appreciation to Doctor McKittrick and his associates for directing our attention to this valuable procedure. There are two facts that are particularly impressive in emphasizing the value of this procedure; first is the salvage of functioning extremities, and second is the strikingly low mortality. Those of us who have long been interested in peripheral vascular disease can fully appreciate the great improvement in both mortality