

Percutaneous Transhepatic Cholangiography

BJORN THORBJARNARSON, M.D., ZUHEIR MUJAHED, M.D.,
FRANK GLENN, M.D.

From the Departments of Surgery and Radiology, The New York Hospital-Cornell Medical Center, New York, New York

PERCUTANEOUS transhepatic cholangiography has been in use at The New York Hospital-Cornell Medical Center for 7 years. Some of our earlier experience with this method has been reported previously.^{1,3} This paper deals with our total experience to date, a matter of 130 percutaneous transhepatic cholangiograms.

Selection of Patients

The method reported earlier for cholangiography has been found satisfactory and no major changes have been instituted. Basically, the method consists of introducing a 6-inch, 20-21 gauge needle into the liver parenchyma. The procedure is done under local anesthesia and television monitoring is used to direct the needle and detect filling of the bile ducts by the contrast material. The patients selected are all suffering from jaundice, and evaluation in the hospital has either indicated extrahepatic obstruction to the biliary tree or else the differential diagnosis between extrahepatic obstruction versus parenchymatous liver disease cannot be made without resorting to laparotomy. The patients are thus essentially all candidates for operation at the time the cholangiogram is performed.

Material

Of the 130 patients there were 40 females and 90 males. The age of the patients ranged from 2 to over 80 years. The youngest was a child with biliary atresia, the old-

est a man with pancreatic carcinoma. The diagnosis and number of patients are shown in Table 1. In the same table there is indicated the rate of success of the procedure.

Complications

The complications possibly related to the procedure of percutaneous transhepatic cholangiography are listed in Table 2. Subphrenic abscesses occurred in two patients, one of whom died. Whether the infection was caused by the cholangiogram or not cannot be proved since subphrenic abscesses are not uncommon as complications following biliary tract operations in general. The complications of intra-abdominal bleeding are directly related to the performance of the cholangiogram. The one patient who died later was found at laparotomy to have brisk bleeding from the site of puncture of the liver. Eventually, but only with difficulty, this appeared to be controlled with transfusion sutures. Postoperatively this patient received several transfusions and at autopsy large amounts of blood were found in the peritoneal cavity. The source of the bleeding could not be ascertained at postmortem examination but we assumed that recurrent bleeding from the puncture site was responsible.

The source of bleeding in a second patient was found at laparotomy to be a small blood vessel overlying the common duct. This bleeding was easily controlled and the patient made an uneventful recovery.

A biliary fistula occurred in one patient on whom a cholecystojejunostomy was per-

TABLE 1. *Percutaneous Transhepatic Cholangiograms. The New York Hospital-Cornell Medical Center, 1958-1965*

Diagnosis	Successful	Unsuccessful
<i>Extrahepatic Obstruction</i>		
Carcinoma head of the pancreas	35	7
Cholelithiasis	16	8
Common duct injury	8	2
Carcinoma of gallbladder	5	3
Sclerosing cholangitis	2	1
Carcinoma of bile duct	8	1
Carcinoma of ampulla of Vater	8	0
Chronic pancreatitis	0	1
Metastases to the pancreas	1	0
<i>Intrahepatic Obstruction</i>		
Hepatitis	4	4
Biliary cirrhosis	1	1
Leukemia hepatitis	0	1
Liver metastases	9	4

formed for unresectable carcinoma of the pancreas. The fistula was not complete but apparently arose from the puncture wound of the liver. The cholecystojejunostomy seemed to function adequately and we do not know the reason for the continued leakage. It may be surmised though that a bile duct partly occluded by a metastasis was penetrated by the cholangiogram needle and that drainage to the outside was easier than into the main ductal system. In this context it is of interest that bile fistulas did not occur more often since in a fair proportion of the patients with advanced cancer, we were unable to create a bypass to relieve the obstructive jaundice.

Range of Success. The range of success in visualizing the ductal system varies widely. Visualization was obtained in 75% of the patients. Among patients with extrahepatic obstruction it was 78% and among those with predominantly intrahepatic disease it was 58%. These results are somewhat better than reported elsewhere without the use of television monitoring.² Better results have been reported by other authors. Their series, however, are smaller.^{4, 5}

There are several possible reasons for failure. The most common one is normal or subnormal size of the intrahepatic ducts as in the case of hepatitis, sclerosing cholangitis, or parenchymal disease of the liver. Here it may be impossible to find a duct large enough to allow filling through the needle despite repeated efforts, and this is the main reason for differences in results in intrahepatic versus extrahepatic obstruction. Most patients with extrahepatic obstruction have dilated intrahepatic bile ducts and should be suitable for this examination with an anticipated high degree of accuracy.

The reasons for failure in those with extrahepatic obstruction are sometimes based on the patient's inability to tolerate the procedure. There is almost always some pain or discomfort associated. The pain usually is due to puncture of the liver capsule and trial injections of the contrast material into the liver parenchyma. The pain may be particularly severe when the injection is in the immediate subcapsular area.

TABLE 2. *Percutaneous Transhepatic Cholangiograms. The New York Hospital-Cornell Medical Center 1958-1965*

Subphrenic abscess	Cholelithiasis	Cholecystectomy Common duct exploration	Patient died following drainage
Subphrenic abscess	Carcinoma pancreas	Cholecystojejunostomy	Patient recovered
Intra-abdominal bleeding	Carcinoma pancreas with liver metastases	Cholecystojejunostomy	Patient died after operation
Intra-abdominal bleeding	Cholelithiasis	Cholecystectomy Common duct exploration	Bleeding found at operation to come from hepatoduodenal ligament and was controlled. Patient did well
Biliary fistula	Carcinoma pancreas	Cholecystojejunostomy	Small fistula persisted

When repeated efforts are made it sometimes becomes difficult for the patient to tolerate the procedure and it has to be abandoned before it has been given an adequate trial since it is not safe to continue with an apprehensive and restless patient who moves about on the examining table.

Another common reason for failure is accumulation of contrast material in the area of confluence of bile ducts. This problem arises when several attempts have been made at injection into the liver parenchyma. The opaque material is in the tissues for up to 15 minutes or longer depending on the ease of absorption and eventually it becomes impossible to observe the early filling of the duct that is necessary for success. Extravasation of contrast material in the subcapsular area of the porta hepatis is particularly apt to produce pooling and when it occurs early in the course of the test it may completely obliterate the critical area of injection and force abandonment of the procedure.

Value of the Procedure. A frequent criticism of percutaneous transhepatic cho-

langiography is that often it is not necessary, since most patients have to be operated upon anyway. It is true that most of the patients involved are subjected to an operation immediately following the cholangiogram. A small number, however, are saved from the operation, that is, those with parenchymal liver disease or hepatitis. In our series four of eight patients with hepatitis have normal biliary tracts and were thus not subjected to laparotomy. Here the value of the test is therefore beyond dispute. Other patients with postoperative stricture of the bile duct also would appear to benefit considerably. A successful cholangiogram demonstrates the level of the stricture, whether a stump of common bile duct suitable for anastomosis remains, or whether the stricture involves individual hepatic ducts in the hilum of the liver. Armed with this information the surgeon can approach the repair much more directly and time is saved from laborious dissection to identify the exact location of the stricture and relation to structures in the hepato-duodenal ligament.

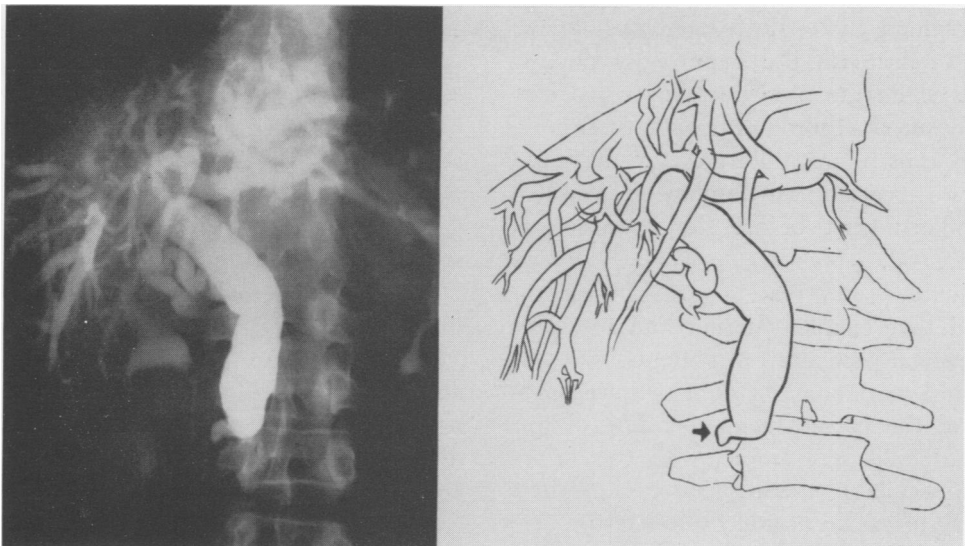


FIG. 1. A 66-year-old man with abdominal pain, diarrhea and signs of obstructive jaundice. Percutaneous transhepatic cholangiogram shows narrowed tapering obstruction typical of carcinoma of pancreas. Ampullary carcinoma was found and a pancreaticoduodenectomy was carried out.

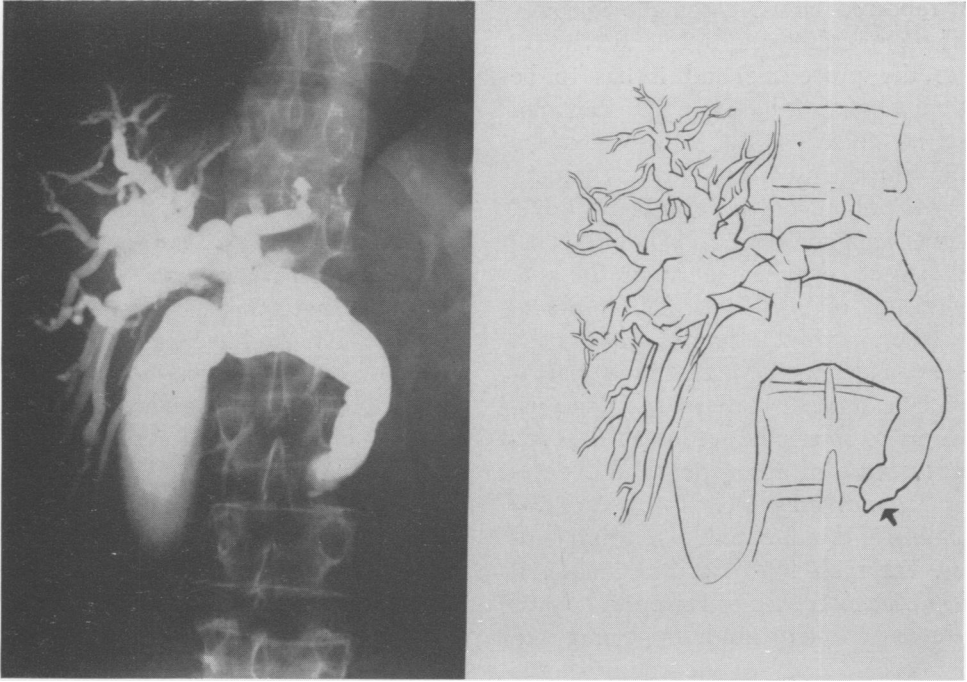


FIG. 2. A 67-year-old woman was admitted because of jaundice of 4-week duration. Examination revealed an enlarged liver and laboratory examinations indicated obstructive jaundice. Percutaneous transhepatic cholangiogram shows dilatation of entire biliary system. Distal end has a small nipple-like deformity with a concave filling defect. Cholangiogram is somewhat suggestive of an ampullary carcinoma, but at surgery a carcinoma of the pancreas was found and a cholecystojejunostomy was performed.

The quality of x-rays obtained by this method is usually much better than can be obtained by operative cholangiograms since facilities in the main x-ray department, where the procedure is carried out, greatly surpass those in the operating room. It may thus be possible to demonstrate the accurate location and number of stones in the biliary tract before the operation is commenced.

Valuable information is frequently gained that enables the surgeon to select the optimal procedure in patients with unresectable carcinoma by demonstrating patency of the cystic duct and filling of the gallbladder. For example, with this information available the surgeon can proceed directly to create a cholecystoenterostomy, knowing that relief of jaundice is assured whereas demonstration of cystic duct patency may be difficult and time-consuming at the time of operation.

Pitfalls in Diagnosis. Whether percutaneous transhepatic cholangiography can differentiate between types of carcinoma obstructing the biliary tract remains to be seen and has not been satisfactorily proved to date. Certainly the narrow tapering obstruction at the lower end of the common duct usually indicates carcinoma of the pancreas and the ragged irregular but sometimes abrupt ending commonly denotes carcinoma of the ampulla of Vater but there are notable exceptions (Fig. 1, 2). The possible similar radiologic appearances of pancreatic and ampullary carcinomas are to be kept in mind at the time of operation and the definitive diagnosis confirmed by inspection and palpation since the surgical approach may be different for the two lesions.

We mentioned earlier the value of percutaneous transhepatic cholangiography when dealing with postoperative strictures

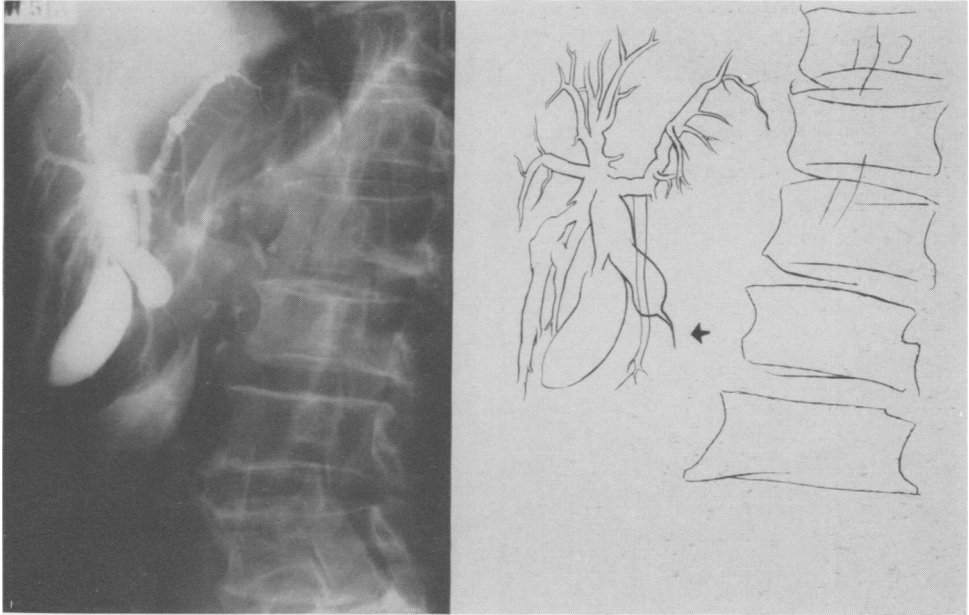


FIG. 3. A 76-year-old man had jaundice and abdominal pain for 2 weeks. Liver was enlarged and tip of the spleen could be palpated. Laboratory tests indicated obstructive jaundice. No history of prior surgery. Percutaneous transhepatic cholangiogram reveals a smooth tapering obstruction in common bile duct. Obstruction seems to be incomplete with a narrow channel or fistula from dilated duct. Carcinoma of the pancreas extending into hepatoduodenal ligament was discovered.

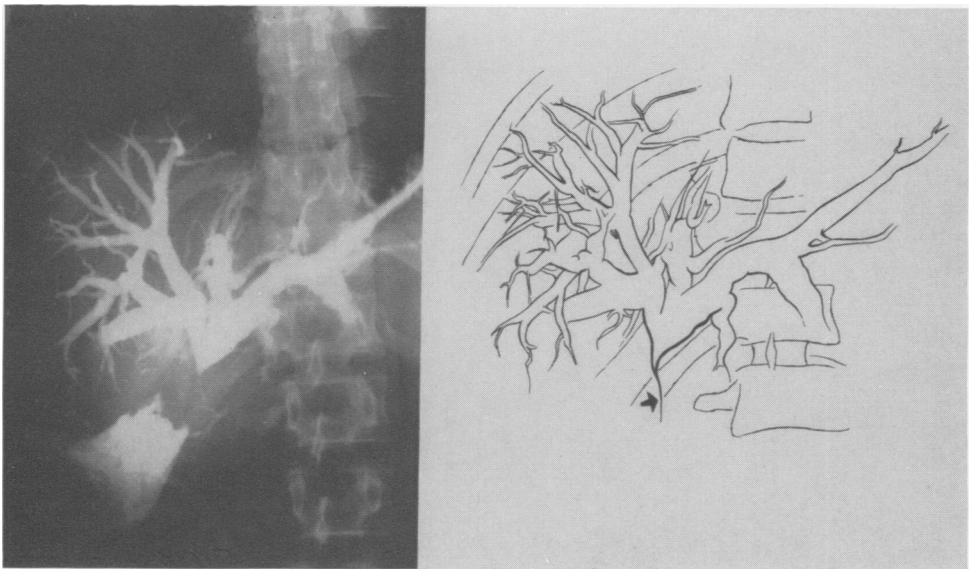


FIG. 4. A 46-year-old man, admitted because of jaundice and biliary fistula following cholecystectomy. There was a sinus in RUQ draining small amounts of bile. Stools were clay colored and laboratory tests revealed evidence of obstructive jaundice. Percutaneous transhepatic cholangiogram shows dilatation of intrahepatic ducts with a narrowing and tapering of the ducts at their confluence. Margins are smooth and a fistula may be seen from occluded end. Picture here is quite similar to Figure 3 but the history indicates this to be a postoperative stricture as was proved at operation.

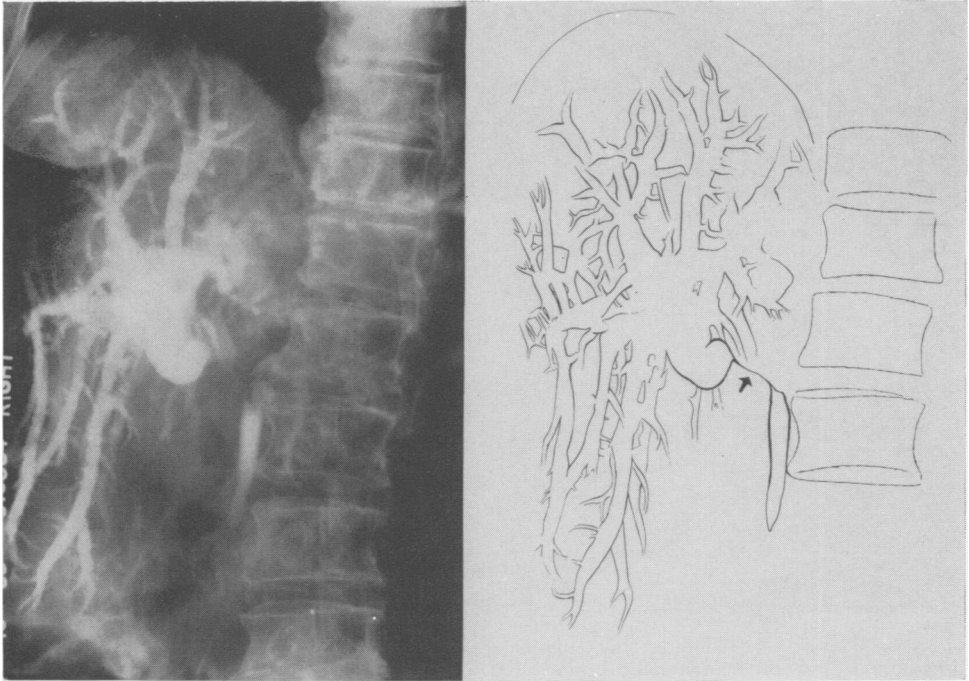


FIG. 5. A 75-year-old woman with RUQ pain and evidence of obstructive jaundice. Percutaneous transhepatic cholangiogram shows dilatation of the intrahepatic ducts and the hepatic duct. There is a narrowed segment at the junction of the hepatic and common bile ducts and common bile duct distally is normal in caliber. This was found to be carcinoma of the gallbladder invading and compressing bile duct.

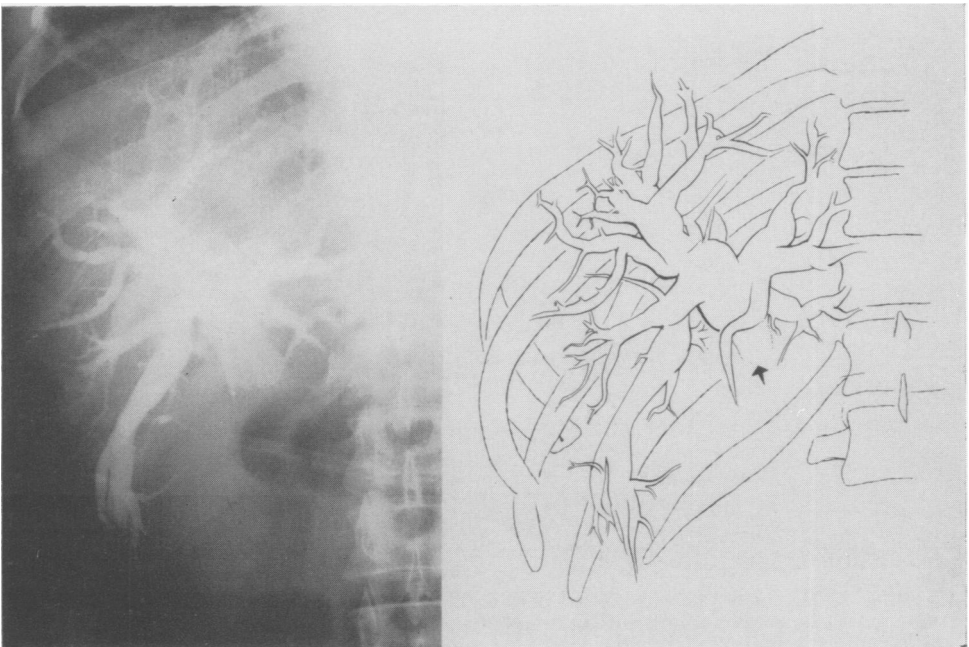


FIG. 6. A 56-year-old man with painless jaundice of 2-week duration. Laboratory tests indicate the jaundice to be obstructive in nature. Percutaneous transhepatic cholangiogram shows dilatation of hepatic and intrahepatic ducts. Obstruction was found to be caused by lymph node metastases comprising the bile duct. Metastases were from a previously treated carcinoma of the lung.

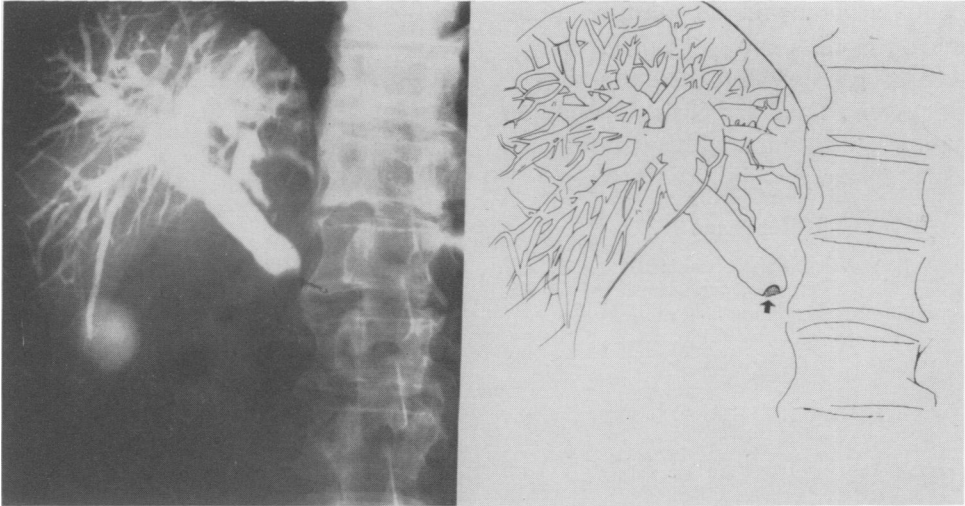


FIG. 7. A 67-year-old man with epigastric pain, steatorrhea, weight loss and jaundice of 3-week duration. Percutaneous transhepatic cholangiogram shows dilated bile duct and meniscus-like deformity at distal end of duct, consistent with impacted calculus. Carcinoma of the head of pancreas was found but no stone; cholecystojejunostomy was performed.

of the common bile duct. Figure 3 shows a carcinoma of the pancreas that extended into the hepatoduodenal ligament and caused compression of the bile duct giving it an appearance very much like that of a postoperative stricture shown in Figure 4. The differential diagnosis may be suggested by the typical history following common duct injury but remains to be confirmed by the findings at operation.

Carcinoma of the common bile duct or segmental stricture of the duct following operative injury may produce the picture in Figure 5. Actually this is a carcinoma of the gallbladder involving the ampullary portion and invading and compressing the adjacent bile duct.

Primary carcinoma of the biliary system is the most common cause of obstruction high in the porta hepatis (Fig. 6). This obstructive lesion was, however, found to be caused by lymph node metastasis from a carcinoma primary elsewhere such as carcinoma of the lung. Finally, carcinoma of the pancreas may on rare occasions look deceptively similar to an obstructing stone at the lower end of the common duct as in Figure 7.

The foregoing has emphasized some pitfalls in the diagnosis of anatomical and pathological lesions by percutaneous transhepatic cholangiography. These pitfalls are few but serve to emphasize that the method is only an adjunct in making a diagnosis; final analysis upon which treatment is determined must be made from all the known factors including history, clinical evaluation and sometimes operative findings. When percutaneous transhepatic cholangiography is used in this context it is a valuable method and supplies information not available at present by any other means.

Summary

Percutaneous transhepatic cholangiography is a valuable adjunct in the diagnosis of jaundice and obstructive lesions of the biliary tract. It is not free of complications and failure of visualization must not be an indication to avoid operation since this may occur in 20% of patients with obstructive lesions. The procedure should therefore be followed by operation both where obstruction has been demonstrated and where there has been failure to visualize the ductal system. The procedure has a high

degree of accuracy in demonstrating the anatomical location and pathological nature of obstructing lesions but there are notable exceptions and final diagnosis depends on evaluation of all factors known in each particular instance.

References

1. Evans, J. A., Glenn, F., Thorbjarnarson, B. and Mujahed, Z.: Percutaneous Transhepatic Cholangiography. *Radiology*, **78**:363, 1962.
2. George, P., Young, W. B., Walker, J. G. and Sherlock, S.: The Value of Percutaneous Cholangiography. *Brit. J. Surg.*, **52**:770, 1965.
3. Glenn, F., Evans, J. A., Mujahed, Z. and Thorbjarnarson, B.: Percutaneous Transhepatic Cholangiography. *Ann. Surg.*, **156**:451, 1962.
4. Kaplan, A. A., Traitz, J. J., Mitchel, S. D. and Block, A. L.: Percutaneous Transhepatic Cholangiography. *Ann. Intern. Med.*, **54**:856, 1961.
5. Wiechel, K.-L.: Percutaneous Transhepatic Cholangiography. *Acta Chir. Scand. Supplement*, **330**, 1964.

Erratum

In Caswell, H. Taylor, Robbins, Robert R., and Rosemond, G. P.: Definitive Treatment of 536 Cases of Hyperthyroidism with I-131 or Surgery, *Ann. Surg.*, **164**:593, 1966, the following should be corrected:

In Tables 1 and 2 on p. 594, "Hypothyroidism without Goiter" should have appeared as "HYPERthyroidism without Goiter."