

CONDYLOMATA ACUMINATA

TWO HUNDRED CASES TREATED WITH PODOPHYLLIN

MAJ. O. S. CULP, M.C., AND CAPT. I. W. KAPLAN, M.C.

STATION HOSPITAL

CAMP BOWIE, TEXAS

CONDYLOMATA ACUMINATA not only are pathologic "nuisances" but occasionally they reach proportions which constitute serious clinical problems. Reliable statistics regarding their incidence are not available but it is generally agreed that they are extremely common. The fact that 180 individuals with typical lesions were seen by us during the past nine months adds proof to this contention. The great variety of therapeutic measures which have been recommended illustrates the inadequacy of most methods of treatment. The purpose of this report is to present the dramatic results which we have obtained with podophyllin. There is reason to believe that this drug may be a "specific" for condylomata acuminata.

The etiology of these growths remains unknown. They present raspberry, cauliflower or cockscomb masses, which are soft, red or cyanotic, often friable, and may be sessile, pedunculated or attached by a broad base. They must be differentiated from carcinoma and condylomata lata of syphilis, but this usually is not difficult. Mixed lesions may occur and complicate the clinical picture.

Condylomata acuminata have been described in many locations, usually on or near the genitalia, and have been given the misnomer "venereal warts." In the present series, they were found on the penis, the labia, the fourchette, lining the vagina, at the urethral meatus, around the anus, on the perineum and on the scrotum (Table I). They had been present for one day to eight months, with the average duration three months. All of these patients were less than 36 years of age, and 90 per cent were white.

Podophyllin is a powder which varies in color from light brown to greenish-yellow, and turns darker when subjected to heat or light. It is an irritant and active purgative and is the basis of several proprietary "liver pills." Various strengths of podophyllin have been tried in the treatment of condylomata acuminata but a 25 per cent suspension in mineral oil has proved most efficacious and has been used in the 200 cases which comprise this report.

The podophyllin in oil is applied with a cotton swab to the surface of the lesions. This is a painless procedure and there is no immediate reaction. Anesthesia is not required, because of the viscosity of the oil and close approximation of normal tissues (*e.g.*, redundant prepuce) it is impossible to keep the podophyllin confined to the condylomata, but in most instances this does not alter the therapeutic effect of the drug. Within

a few hours the growths become blanched, and 24 to 48 hours later they appear necrotic. The condylomata begin to slough on the second or third day and promptly disappear. No ulceration or scarring is left at the bases. The adjoining normal tissue usually is unaffected even though it has been exposed to the same medication. Most patients experience no discomfort during the entire process and only rarely is sedation necessary. There have been no systemic reactions to any of the 249 treatments employed in this group of 200 patients. This type of therapy is so simple and the clinical courses so uneventful that it is performed in the clinic or office and hospitalization is unnecessary. The minimum loss of time to the patient has made it especially valuable among military personnel.

No satisfactory explanation of the more or less specific action of podophyllin on the condylomata is possible at this time. The most logical assumption is that the irritating power of the drug produces spasm of the small vessels, which in turn causes ischemia, necrosis and sloughing. The blood supply of the condylomata apparently is more susceptible to the 25 per cent suspension than that of the more viable, adjoining, normal tissues. The podophyllin also seems to dehydrate the condylomatous masses. Irrespective of the exact physiology involved, the dramatic results obtained in these cases indicate that podophyllin is of tremendous value in the treatment of condylomata acuminata.

All of the 200 patients in this study were cured regardless of the number, size, location or duration of the growths. Only one application of podophyllin was needed for 81.5 per cent, while an additional 14.5 per cent were cured by a second treatment. No one required more than four applications of the drug. In 72.5 per cent of the cases, complete recovery occurred within four days, while only 6.5 per cent required more than eight days for disappearance of the growths. No discomfort was experienced by 83.5 per cent of the patients and only 2 per cent required any sedation (Table I).

Because of the movements of military organizations, complete follow-ups have been impossible. There have been nine known recurrences of the condylomata (4.5 per cent) but others may have occurred. In each of these nine cases, response was prompt to additional similar treatment with podophyllin. Inasmuch, as the etiology of the initial lesions is unknown, there is reason to anticipate recurrences or new growths after *any* type of therapy. The causative factors no doubt continue to exist in many cases despite prompt disappearance of the original growths. Initial and recurrent lesions respond equally well to podophyllin, and this appears to be the treatment of choice for all condylomata acuminata.

The minor variation in clinical courses with lesions in different locations are demonstrated by the following group analyses (Table I):

Penis.—A total of 168 patients had condylomata acuminata on the penis. The only instances of associated venereal diseases were in this group. Nine patients had acute gonococcal urethritis and five had chancres. These were

CONDYLOMATA ACUMINATA

treated by accepted methods and did not influence the course of the condylomata or result in recurrence.

The number of growths in each case varied from single lesions to clusters of as many as 25 pedunculated tumors with the average six. These varied in size from 2 Mm. in diameter to conglomerate masses covering the glands or filling the coronal sulcus. Most of the discrete lesions were 0.5 to 1.0 cm. in diameter.

TABLE I
ANALYSIS OF 200 CASES OF CONDYLOMATA ACUMINATA TREATED WITH PODOPHYLLIN

Location	Total Cases	No. of Treatments				Days Until Cured			Pain		V. D.			Recurrence
		1	2	3	4	2-4	5-8	More	None	Req. Mild	Sed. Lues	GC.		
Penis.....	168	148	16	2	2	134	30	4	150	18	0	5	9	8
		88.1%	9.5%			79.8%	17.8%		89.3%	10.7%				
Female														
genitalia...	15	9	6	0	0	7	4	4	2	9	4	0	0	0
		60%	40%			46.6%	26.7%		13.3%	60%				
Urethra.....	10	2	5	2	1	2	5	3	10	0	0	0	0	1
		20%	50%			20%	50%		100%					
Anus.....	4	3	0	0	1	1	2	1	2	2	0	0	0	0
		75%				25%	50%		50%	50%				
Male														
perineum..	2	1	1	0	0	1	0	1	2	0	0	0	0	0
		50%	50%			50%		50%	100%					
Scrotum....	1	0	1	0	0	0	1	0	1	0	0	0	0	0
			100%				100%		100%					
Total...	200	163	29	4	4	145	42	13	167	29	4	5	9	9
		81.5%	14.5%	2%	2%	72.5%	21%	6.5%	83.5%	14.5%	2%	2.5%	4.5%	4.5%

MARBLE BIOL. LAB.

The condylomata were found most frequently in the coronal sulcus or at the frenulum but occurred at any point along the shaft or mucous membrane of the redundant prepuce (Fig. 1). Four patients had been circumcised prior to the onset of the lesions, thus dispelling any claims that circumcision alone is adequate prophylaxis. Twenty patients had been treated previously with escharotics without complete disappearance of the growths.

Only one application of podophyllin was necessary to produce complete disappearance of all lesions in 88.1 per cent of these patients (Fig. 2). Only four patients required more than two treatments. An interval of four to six days was employed between applications in these cases.

The condylomata had entirely disappeared and the sites appeared normal within four days in 79.8 per cent of the patients (Fig. 2). An additional 17.8 per cent were well in five to eight days. Those patients who required repeated treatment automatically had longer intervals until cured.

No discomfort of any kind was noted by 89.3 per cent of the patients. The remaining 10.7 per cent had only mild burning. None of these required sedatives. The same patients (total of 18) had some degree of chemical balanoposthitis. All had very long prepuces. The balanoposthitis was mild and subsided quickly in all but three cases. The tissue reaction was severe in these three instances and, because of marked prepuccial edema, dorsal slit was done. This may not have been absolutely necessary. In each of

these three cases complete disappearance of the condylomata was found at operation and the balanoposthitis subsided promptly after surgical exposure of the glans. No balanoposthitis or edema has been observed since the patients have been advised to wash off the podophyllin 24 hours after its application.

Eight of our nine known recurrences were in this group. These appeared

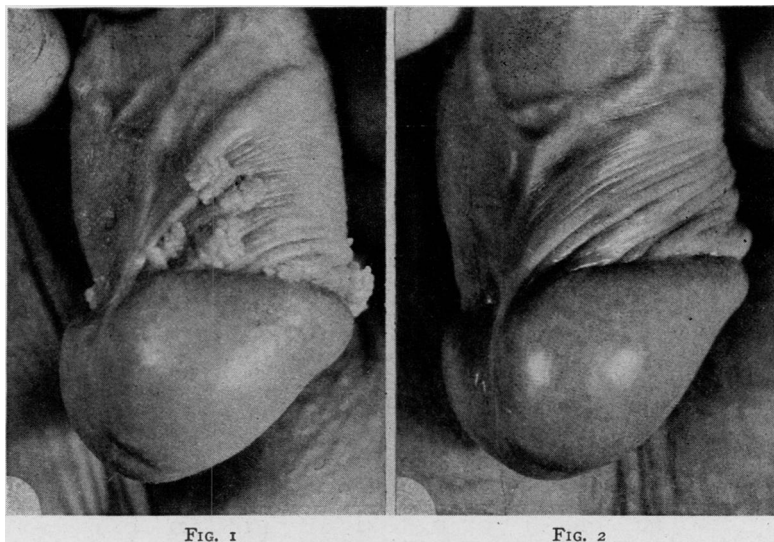


FIG. 1.—Multiple condylomata in coronal sulcus and along mucous membrane of prepuce.
(Photograph by U. S. Army Signal Corps)
FIG. 2.—Same patient four days after single application of podophyllin in oil.
(Photograph by U. S. Army Signal Corps)

from one to six months later and in each case, one additional treatment caused disappearance of the lesions. Several patients have been followed nine months without recurrence or new growths.

Hospitalization was necessary only for the three patients who were subjected to dorsal slits.

Female Genitalia.—Fifteen women had condylomata acuminata on the genitalia. Eight of these were pregnant. The growths have been known to fill the vagina and require cesarean section. This promised to be true in at least one of this group.

The lesions were confined to the labia in nine cases, to the fourchette in two patients and were scattered throughout the vagina in the remaining four. They varied in size from 0.5 cm. in diameter to a condylomatous mass which filled the vagina of one patient who was eight months pregnant. In most instances four or five growths were present.

No patient in this group required more than two applications of podophyllin and 69.3 per cent were cured within eight days. The remaining four patients had disappearance of the condylomata in 9 to 14 days.

These patients experienced more pain than any other group. The four with diffuse vaginal involvement required codeine or morphine. Only two

patients, with lesions limited to the labia, had no discomfort. Sedation was necessary for only 12 to 24 hours.

No recurrences have been noted. Treatment of the condylomata did not disturb any of the eight pregnancies.

Urethra.—Ten males had single lesions just inside the urethral meatus. These were 0.2 to 0.6 cm. in diameter. Only two were cured by one treatment. Urination caused premature removal of the podophyllin from the condylomata, thereby, necessitating repeated applications of the drug. Five patients were well after two treatments. Two patients required three applications and another needed four. An interval of four days was used between treatments.

Because of the prolonged therapy, only two patients were cured within four days. Five were well in five to eight days and the remaining three patients had disappearance of the growths in 9, 14, and 21 days, respectively. None of these ten patients had any pain.

One patient, whose condyloma disappeared after a single treatment, had a recurrence two months later. This disappeared after two treatments.

Anus.—Four males had clusters of condylomata surrounding the anus at the mucocutaneous margin. Three were cured within one week after a single application of podophyllin. The fourth patient required four treatments, and was well in 16 days.

Two patients had no discomfort but the other two had mild burning pain for 24 hours. No recurrences have been observed in this group.

Perineum.—Two patients had condylomata on the perineum, midway between the anus and the base of the scrotum. Three pedunculated growths, each 1 cm. in diameter, were present in one case, while the other presented two such lesions.

One patient was cured four days after one application of the drug and the other was well in ten days but required two treatments. No pain was experienced in either case. No recurrence has been observed in four months.

Scrotum.—One patient had 25 discrete condylomata, each about 0.5 cm. in diameter, scattered over the left side of the scrotum. Two treatments (with an interval of four days) caused complete disappearance of all lesions in one week without discomfort. There has been no recurrence in three months.

COMMENT.—Tomskey, Vickery and Getzoff have reported excellent results in the treatment of granuloma inguinale with podophyllin. Two such cases which failed to respond to other therapy at this hospital were cured promptly with 25 per cent podophyllin in oil.

The oil suspension and powdered drug have been used by us in removing excessive granulation tissue from surgical wounds with dramatic success. It appears to be far superior to the conventional silver nitrate in this respect.

Podophyllin has been of no value, however, in the treatment of typical, horny verrucae, of condylomata lata of syphilis or of benign rectal polypi.

This drug appears to be most efficacious in removing soft granulomatous tissues, and its clinical applications may not be exhausted. Further studies pertaining to additional therapeutic values of podophyllin are being conducted but as yet are inconclusive.

SUMMARY

Podophyllin has been found to be unusually successful in producing prompt and complete disappearance of condylomata acuminata regardless of size, number, location or duration of the growths. The drug is best applied as a 25 per cent suspension in mineral oil. Anesthesia and hospitalization are not necessary. There is minimal time lost from any type of physical activity.

Most lesions disappear within four days after a single application of the drug. Growths within the urethra usually require two or more treatments. None of our patients required more than four topical applications.

No ulceration or scarring results and the surrounding normal tissue usually is unaffected by the drug. In isolated cases of extensive application under long prepuces some balanoposthitis may develop but thorough washing 24 hours after treatment promises to prevent this and not interfere with the end-result.

The convalescence is usually entirely painless but some patients, especially those with extensive involvement of the vagina, may require sedation.

Recurrences or new growths are to be expected since the etiology of condylomata acuminata remains unknown, but these, likewise, respond quickly and completely to the same treatment.

Podophyllin appears to be capable of destroying most types of granulosomatous tissue and additional clinical applicability probably will be forthcoming.

The dramatic results obtained in this series of 200 patients with condylomata acuminata on the penis, female genitalia, perineum, scrotum, urethra and anus, and the simplicity of the treatment with podophyllin, prompt us to recommend more general adoption of this type of therapy.

REFERENCES

- Cook, E. F., and LaWall, C. H.: Remington's Practice of Pharmacy. Philadelphia and London, J. B. Lippincott Co., 468, 1936.
- Culp, O. S., Magid, M. A., and Kaplan, I. W.: Podophyllin Treatment of Condylomata Acuminata. *J. Urol.* In press.
- Kaplan, I. W.: Condylomata Acuminata. *New Orleans Med. and Surg. J.*, 94, 388, 1942.
- Tomskey, G. C., Vickery, G. W., and Getzoff, P. L.: The Successful Treatment of Granuloma Inguinale: With Special Reference to the Use of Podophyllin. *J. Urol.*, 48, 401, 1942.

EDITORIAL ADDRESS

Original typed manuscripts and illustrations submitted to this Journal should be forwarded prepaid, at the author's risk, to the Chairman of the Editorial Board of the ANNALS OF SURGERY

Walter Estell Lee, M.D.
1833 Pine Street, Philadelphia, Pa.

Contributions in a foreign language when accepted will be translated and published in English.

Exchanges and Books for Review should be sent to James T. Pilcher, M.D., Managing Editor, 121 Gates Avenue, Brooklyn, N. Y.

Subscriptions, advertising and all business communications should be addressed

ANNALS OF SURGERY
East Washington Square, Philadelphia, Pa.