THE MANAGEMENT OF WAR INJURIES OF THE EXTRAPERITONEAL RECTUM

MAJOR EDMUND J. CROCE, M.C., A.U.S.,
LT. COL. VANSEL S. JOHNSON, M.C., A.U.S.,
AND
MAJOR THOMAS B. WIPER, M.C., A.U.S.
FROM THE SURGICAL SERVICE, HALLORAN GENERAL HOSPITAL, STATEN ISLAND, N. Y.

INJURIES OF THE RECTUM present many problems which are peculiar to it alone. These problems arise largely from its physiologic and anatomic properties. As the organ of temporary storage and evacuation of the solid wastes of the intestinal tract, its contents teem with organisms, many of them potential pathogens, both aerobic and anaerobic. Anatomically, it is for the most part unprotected by infection-resisting peritoneum. It traverses a tissue which is highly vulnerable to infection, and it is difficult of surgical access. In order to understand more fully the implications of the anatomic problems, let us examine some of the essential details of the relationships of the rectum.

The rectum, the terminus of the large bowel, is arbitrarily said to begin at the level of the third sacral vertebra and end in the anal canal (Fig. 1). Its average length is 12 cm. The lateral and anterior surfaces of the proximal portion, 5 cm. in the male, 7 cm. in the female, are invested with peritoneum. The posterior surface of this proximal portion is retroperitoneal, the distal portion is infraperitoneal. The rectum ending below at the level of the internal sphincter to become the anal canal, is approximately 2 cm. long and is circumvested by the external sphincter. The internal structure of the pelvic floor, through which the rectum passes, may be likened to a trough, the sides of which are formed by the levators ani and coccygei, flat, sling-like muscles originating from the internal surfaces of the pelvis on either side, from the pubic tubercle in front to the coccyx behind, to join in a median raphe below. The triangular anterior wall is formed by the urogenital triangle, while the triangular posterior wall is formed by the sacrum and coccyx. Through this trough-like space descend the rectum posteriorly and the urogenital tract anteriorly. Over this trough-like space and its viscera, the peritoneum is loosely draped as a cover. Actually, this space is more potential than real, since it is filled with a cellular areolar tissue. This space is, therefore, bounded laterally by the levators, inferiorly by their raphe, anteriorly by the urogenital triangle, posteriorly by the sacrum and coccyx and superiorly by the peritoneum, and will be referred to as the infraperitoneal space. When this space is distended by pus or blood, its expansion is found to be definitely limited in certain directions, relatively unlimited in others. Rigid fascial planes prevent extension in any direction except superiorly. Laterally, these fascial planes are formed by the medial investment of the levators, the superior levator fasciae. These layers join inferiorly over the raphe, and become continuous at the rectal and urogenital outlet with a similar layer of fascia loosely investing these viscera, the endopelvic fascia. Anteriorly, the superior levator fascia

fuses with the deep layers of the urogenital triangle, and posteriorly, with the periosteal layer of the sacrococcygeal fascia. Expansion of the infraperitoneal space is, therefore, limited inferiorly, laterally, anteriorly and posteriorly by fascial planes, but is relatively uninhibited superiorly by the loose peritoneal roof. Even this, however, is rather firmly adherent laterally along the line of origin of the levators, at the so-called "white line" where levator fascia fuses with the obturator fascia above. Since the peritoneum is most loosely attached over the sacral promontory on either side of the rectum, it is

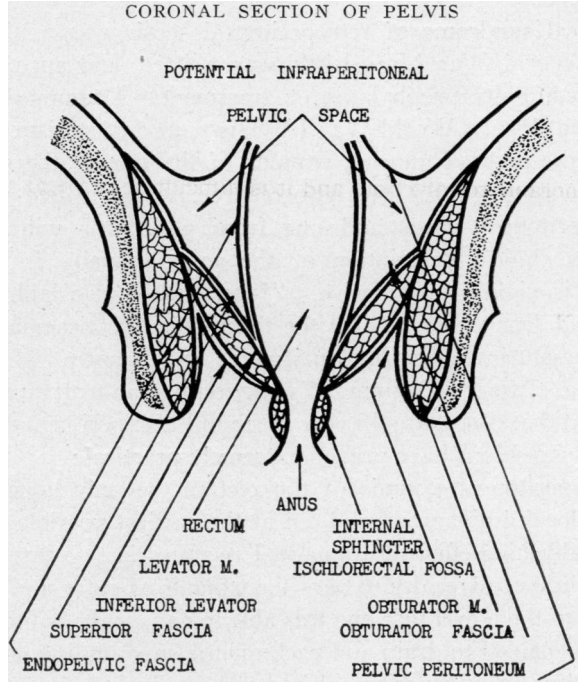

FIG. 1.—Diagram of coronal section of pelvis demonstrating the infraperitoneal space.

here that the infraperitoneal space readily communicates with the retroperitoneal space. When the infraperitoneal space becomes distended with pus or blood, it, therefore, spills through this escape route into the retroperitoneal space. This has been demonstrated experimentally in the cadaver by the serial roentgenologic studies of progressive injection with sodium iodide solution into the infraperitoneal space (Figs. 2 and 3). It is also well illustrated in one of the cases presented below (Case 1).

While perforation of the infraperitoneal portions of the rectum and bladder cause infection of the infraperitoneal and eventually of the retroperitoneal space, perforation of the anal canal causes infection of the ischiorectal fossae on either side. These are symmetrical pyramidal spaces, one on each side beneath the pelvic floor. The medial wall of each space is formed above by the levator and its investing fascia, the inferior levator fascia, and below by

the anal canal. The lateral wall of each is formed by obturator internus and its investing fascia, and the base by the superficial fascia and skin alone (Fig. 1). Expansion of these spaces is limited on all sides except at the base, so that the ischiorectal abscess points at the skin. Again, serial roentgenologic studies of progressive injection with sodium iodide solution of the ischiorectal space in the cadaver illustrates the barriers formed by the pelvic floor between these spaces and the infraperitoneal space (Fig. 4). Extension of infection does not occur from one to the other except by trauma to the levator and to investing fasciae.

The clinical syndrome of retroperitoneal sepsis was a nightmare to the surgeons of World War I.[1, 2] Little was written, and apparently little was known, regarding its prophylaxis or treatment. Drummond reviewed the problem at the close of World War I.[3] His mortality statistics are discouraging: "From the table of gunshot wounds of the rectum there were fourteen deaths out of sixteen cases with two recoveries; seven died from shock, six from retroperitoneal sepsis and one from peritonitis with retroperitoneal sepsis." His clinical description of the acute casualty is borrowed from Fraser[4] and is vividly imaginative. "John Fraser also laid great stress on retroperitoneal sepsis, and applied the term 'colon septicaemia' to a group of symptoms present in cases of colon wounds with a spread of infection to the retroperitoneal tissue." Drummond's suggestions as to treatment reveal that the problem at that time was still very much in the experimental stage, although some of his suggestions have proved extremely practical:

"In extraperitoneal wounds of the rectum the only hope of success lies in very free local drainage carried out at the earliest possible moment. With a view to establishing efficient drainage, I removed in two cases, the uninjured coccyx in addition to free drainage of the wounds of entry and exit, and found by stripping up the bowel that one was able to expose the wound in the rectum and was thus enabled to drain and pack off the surrounding parts and prevent further tracking by retroperitoneal hemorrhage."

During the past two years, we have been fortunate enough to administer definitive treatment to a moderate number of patients returning from the battlefields in various stages of convalescence from war wounds of the rectum. In addition, we have been able to evaluate the treatment of many others who have not remained under our care. From these observations, we feel that progress has been made during this war in the management of extraperitoneal injuries of the rectum. We feel that sufficient progress has been made to warrant crystallization of the surgical management. We wish to emphasize here the part played by surgical prophylaxis in contrast to the supportive measures of blood, plasma, and chemotherapeutic agents. Invaluable as they are, when applied alone, without surgery, they may influence the early mortality rate in assisting recovery from shock, but not appreciably the morbidity or late mortality rate from chronic sepsis. These measures have been proved to be merely adjuvants and not in any way substitutes for early and properly executed surgery.

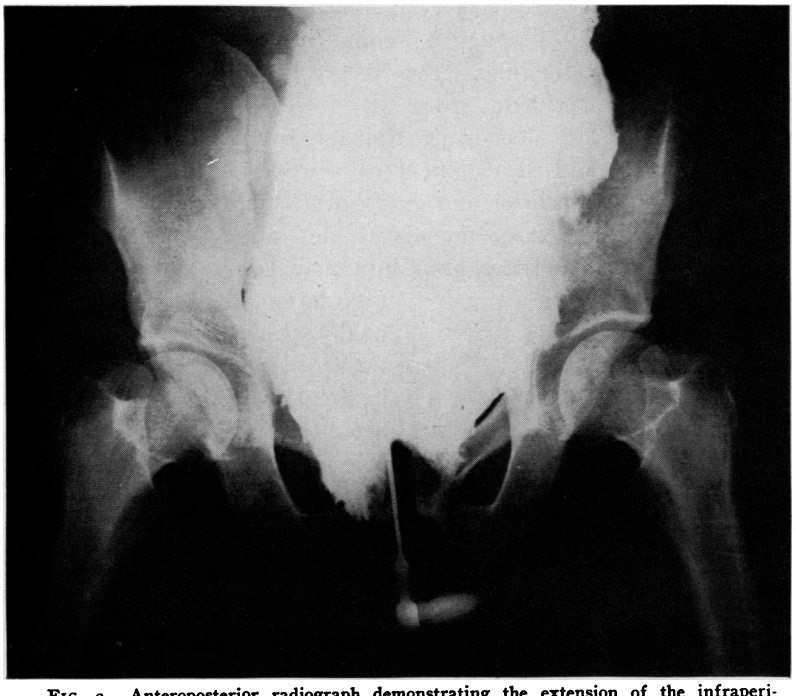

FIG. 2.—Anteroposterior radiograph demonstrating the extension of the infraperitoneal into the retroperitoneal space by injection of sodium iodide solution into the former space in the cadaver.

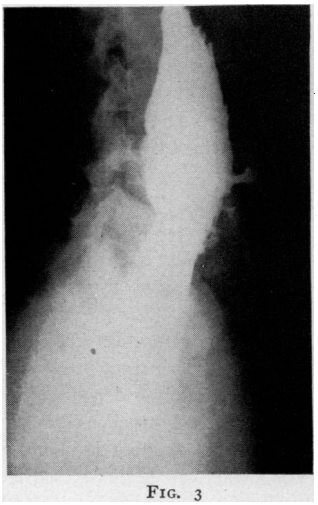

FIG. 3

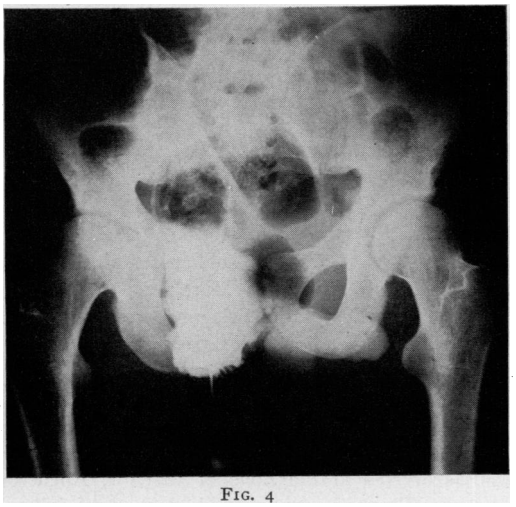

FIG. 4

FIG. 3.—Lateral radiograph as in Figure 2.

FIG. 4.—Anteroposterior radiograph demonstrating the confines of the right ischiorectal fossa after injection with sodium iodide solution in the cadaver.

What, then, is properly executed surgery? Examination of the anatomy of the pelvic floor reveals that a very simple approach to the infraperitoneal space lies posteriorly. Through a midline incision, one may easily expose and excise the coccyx, then incise the precoccygeal fascia and thus expose the areolar tissue of the perirectal space. By loosely packing this space one has provided very adequate dependent drainage well calculated to prevent the spread of infection and development of retroperitoneal sepsis. Moreover, the exposure of the posterior and lateral walls of the lower rectum permits exploration for laceration of the viscus, and an opportunity to suture it. Failure to perform the latter procedure may result in chronic sepsis and retardation of wound healing, and, finally, the establishment of a chronic fistula, even in the presence of a proximal colostomy. However, it is recognized that this ideal may not be attainable at the primary procedure because of the precarious condition of the patient or the pressure of other life-saving measures. Furthermore, even when the patient's condition and other circumstances permit, this ideal may still be unattainable because in many instances the laceration will be inaccessible, in others, it will not be detectable because of hemorrhage in the rectal wall, while in still others, perforation will appear as a result of infarction only several days after trauma.

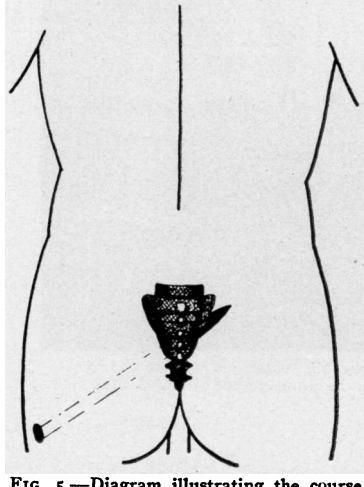

FIG. 5.—Diagram illustrating the course of the bullet. (Posterior view)

We have selected for presentation a number of clinical cases from which we have evolved a rationale of management, and we shall present them below *pari passu* with our observations regarding their contributions to the final plan of management.

CASE REPORTS

Case 1.—A 23-year-old soldier sustained a penetrating gunshot wound of the left buttock in North Africa on March 27, 1943. The bullet perforated the rectum and lodged in the bodies of the first and second sacral vertebrae (Fig. 5). Celiotomy was performed through a lower left rectus incision the following morning. Apparently, no intraperitoneal lesion was found and the wound was closed without drainage and without colostomy. The celiotomy wound became infected, and was widely opened (Fig. 6). Fecal drainage appeared from the wound of entrance in the left buttock. The patient became acutely ill and rapidly malnourished, despite vigorous supportive measures. When he arrived at the Zone of Interior, April 30, 1943, he was severely septic and emaciated. The celiotomy wound was superficially epithelized, with wide musculofascial defect. There was a deep-lying tender mass in the right lower quadrant against the right inguinal ligament. There was frank fecal drainage from the wound of entrance in the lateral aspect of the left buttock, which communicated with a fecal abscess underlying the gluteal muscles. There was a large decubitus ulcer over the sacral region.

On admission, the R. B. C. was 3.29 million per cu. mm., W. B. C., 7,400 cu. mm.; hemoglobin, 12.6 Gm. per cent; uranalysis and Kahn were negative. Roentgenograms revealed a bullet lodged near the right sacro-iliac joint. On May 6, 1943, an attempt was made to improve the drainage of the fecal abscess of the gluteal region. On May 11, 1943, the mass in the right lower quadrant of the abdomen was incised and found to be a fecal abscess. Lipiodol injection of the incision in the right inguinal region revealed a communication with the infraperitoneal space (Figs. 7 and 8). Despite vigorous supportive measures with plasma, blood and sulfonamides, the sepsis and emaciation increased. A barium meal revealed no evidence of an internal fistula involving small bowel or cecum. All the evidence indicated that the fecal abscess in the right inguinal region was an overflow from the infraperitoneal space which was being filled by an infraperitoneal perforation of the rectum (Fig. 9). Therefore, on June 10, 1943, a sigmoid colostomy was performed to divert the fecal stream. There

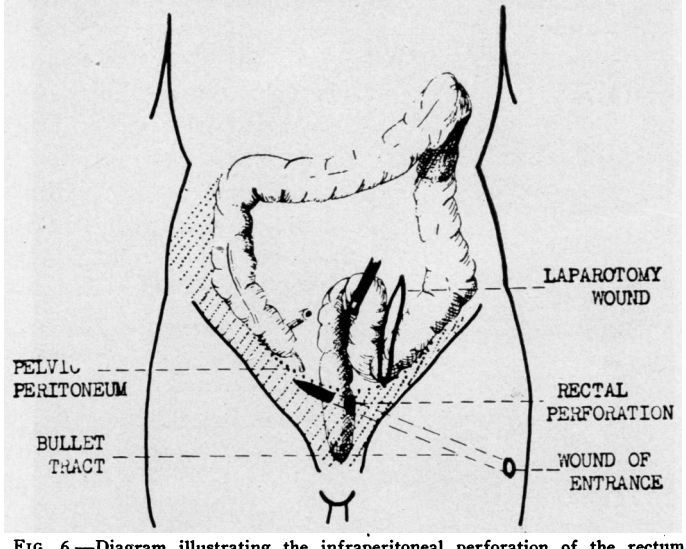

FIG. 6.—Diagram illustrating the infraperitoneal perforation of the rectum and the celiotomy wound. (Anterior view)

was some improvement for a while, but large amounts of malodorous pus continued to discharge from the left buttock and through the right inguinal incision. On August 2, 1943, the discharge from the right inguinal incision again became feculent and it was presumed that an internal fistula had developed with the cecum or ascending colon. Barium studies failed to reveal this internal fistula. On August 9, 1943, the discharge from the right inguinal incision became blood-tinged. The prothrombin time was normal. On August 10, 1943, rather profuse hemorrhage appeared from the right inguinal incision, distal sigmoid colostomy orifice, the rectum and left buttock incisions, and the patient died despite attempts to pack off the vessels through the wound in the right inguinal region, and the use of multiple transfusions.

Autopsy revealed marked emaciation. The peritoneal floor of the pelvic cavity had been raised by the underlying necrotizing infection of the infraperitoneal space. This infection was not only posterior, about the rectum, but had extended anteriorly about the bladder. It communicated with the abscess underlying the left gluteal muscles through the bullet tract in the left levator muscle. There was a perforation of the rectum in its posterior wall about 8 cm. above the anal orifice. The bullet lay embedded in a crumbled mass of cancellous bone of the first and second sacral vertebrae near the sacro-iliac joint just above the peritoneal reflexion. Thence, the fecal abscess had

extended retroperitoneally to the right iliac fossa where it continued to burrow upward along the posterolateral wall of the ascending colon almost to the liver. About midway in the ascending colon, a secondary wide communication had become established with the retroperitoneal space (Fig. 10).

COMMENT: It seems very unlikely that this internal fistula could have been traumatic in origin. In fact, if it had been present prior to establishing the sigmoid colostomy on June 10, 1943, the external fecal fistula in the left gluteal region and the right inguinal region would not have lost their

FIG. 7.—Anteroposterior radiograph after lipiodol injection of right inguinal incision showing upward extension along right iliac fossa and downward to the perirectal space.

fecal characteristics after sigmoid colostomy. It was not until August 2, 1943, that the discharge from these again became feculent and it was then that this secondary communication proximal to the colostomy must have become established. There was a septic erosion of the outer walls of many visceral branches of the pelvic vessels but the exact origin of the hemorrhage could not be located.

This represents a casualty which probably would not have survived more than a few hours were it not for the excellent supportive therapy our soldiers have been receiving at the front—blood, plasma and chemotherapeutic agents. We do not know what the findings were at the time of initial celiotomy except that no intraperitoneal visceral lesion was found. Soon after operation the patient became very ill, and fecal drainage appeared from the wound of entrance. Had a sigmoid colostomy been established at

that time and the infraperitoneal space widely saucerized through coccygectomy, the subsequent course might have been modified. Upon arrival here, the patient was in such poor condition that a major operation did not, at that time, seem feasible. Even diagnostic procedures were exhausting to the patient. From the light of subsequent events, and our observations of similar cases, thereafter, a coccygectomy with widespread saucerization of the infraperitoneal space should have been performed as soon after arrival as possible,

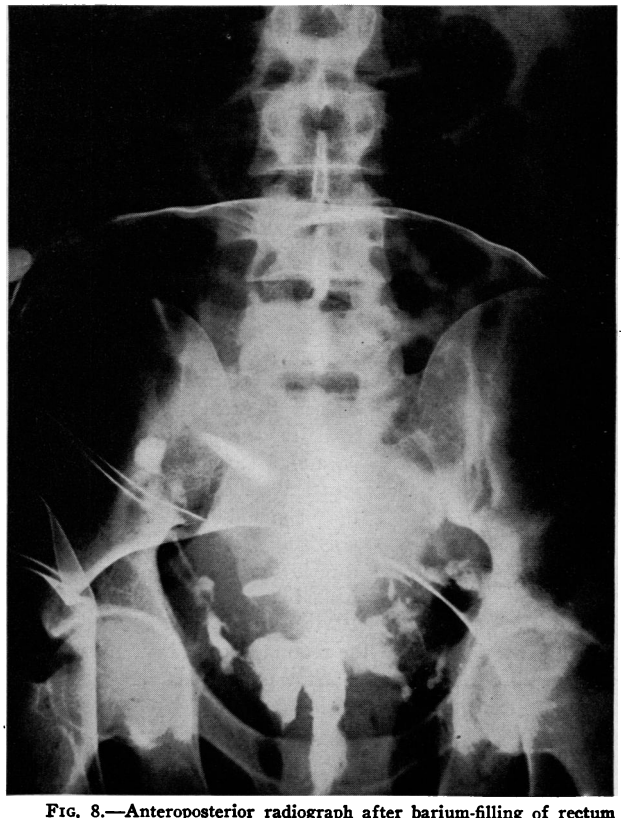

FIG. 8.—Anteroposterior radiograph after barium-filling of rectum showing the extension of barium into the infraperitoneal space and upward toward the right iliac fossa.

together with a sigmoid colostomy. Whether he would have survived such a procedure is problematical, but it would have given him his only chance. Of course, if the internal retroperitoneal fistula into the ascending colon had already been established, even this would have failed, as nothing short of an ileostomy would have diverted the fecal stream, but the evidence indicates that this secondary fistula had not become established until later.

This case, therefore, well illustrates (1) a pathway of spread of infection from the infraperitoneal to the retroperitoneal space. (2) The importance of early surgery for infraperitoneal perforations of the rectum. (3) The futility of supportive treatment in the absence of early surgery. (4) The profound malnutrition resulting from infection of the areolar tissue of the

infra- and retroperitoneal tissues, in the absence of early and adequate drainage.

Case 2.—While in action on the Italian front at 1400 hours on April 3, 1944, a 25-year-old soldier sustained multiple shell fragment wounds of the left lower extremity, the right thigh, the left buttock, and the left forearm. The latter caused paralysis of the radial and ulnar nerves and a compound fracture of the radius. At 0230 hours, the following morning operation was performed under open-drop ether anesthesia. All wounds were débrided. Foreign bodies were removed from the left thigh, left buttock, left arm, left foot and right thigh. The left forearm was immobilized in plaster. Through a lower left paramedian incision, the abdomen was explored. A massive extraperitoneal hemorrhage was found in the pelvis. The peritoneum was reflected, a large shell fragment was removed from the right lateral pelvic wall, and two Penrose drains were inserted extraperitoneally to this site from the lower end of the wound. The surgeon was not cognizant of any rectal perforation at this time and colostomy was not performed. On April 8, 1944, after an enema, feces returned through the wound of the left buttock for the first time, indicating to the surgeon that a contused area in the rectum had sloughed away. A sigmoid colostomy, through a left gridiron incision, was performed without delay, and opened on April 13, 1944. The patient continued to be moderately ill and, April 23, 1944, a left para-anal incision was made through the ischiorectal fossa into the infraperitoneal space, and the sigmoid colostomy completely divided. On May 15, 1944, examination revealed that the lower 6 cm. of the midline celiotomy wound were unhealed and draining pus. Rectal examination revealed a perforation, 3.5 cm. in diameter, in the posterior wall of the rectum, 5 cm. above the anus, communicating with a large perirectal abscess (Fig. 11). It was draining inadequately through a left para-anal incision, so this incision was enlarged. The granulating wounds of the left lower extremity and right thigh were excised and sutured. The patient had had a nonspecific epididymitis which was gradually subsiding. He was evacuated to the Zone of Interior on July 3, 1944.

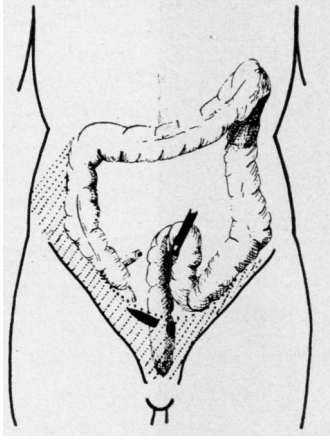

FIG. 9.—Diagram illustrating the extension of the infraperitoneal abscess upward along the right iliac fossa. (Anterior view)

On arrival here, the R. B. C. was 4.7 million per cu. mm.; W. B. C., 6,600 per cu. mm.; hemoglobin, 15 mg. per cent. Uranalysis was negative. Serum protein was 5.7 Gm. per cent. N. P. N., 26 mg. per cent. Despite continued supportive treatment of high caloric diet, vitamins, administration of blood and plasma and later penicillin, the clinical picture remained one of chronic sepsis and its attendant malnutrition. Lipiodol injection of the orifice at the lower end of the celiotomy wound revealed a fistula extending laterally along the right wall of the pelvis, puddling about the lower end of the rectum and finally into the rectum and also out through the left para-anal incision (Fig. 12).

On September 25, 1944, through a midline coccygeal incision the coccyx was resected. On incising the precoccygeal fascia a large perirectal abscess was encountered filled with necrotic and suppurative débris. A large perforation, 3 cm. in diameter, was found in the posterior wall of the rectum. The abscess extended anteriorly on both sides of the rectum, on the right further than could be reached by the finger. The perforation of the rectum was sutured, a cigarette drain placed into each anterior

extension of the infraperitoneal space and the cavity loosely packed. Postoperatively, parenteral penicillin 200,000 units daily was administered.

The patient improved to some extent following this procedure. The suture line closing the perforation of the rectum was soon digested in the infectious process. The cigarette drains in the anterolateral extensions were removed in eight days. The left anterolateral extensions closed completely. The right, which was larger, and was suspected of communication with the caudal end of the abdominal wound by way of the lateral wall of the pelvis, seemed at first to be closing but soon began to drain large quantities of pus. The patient began to complain of pressure pain deep in the perineum. On October 31, 1944, a catheter was introduced into this extension and it was filled with lipiodol and roentgenograms taken (Fig. 13). These films revealed a wide sinus extending along the right anterolateral wall of the pelvis almost to the symphysis pubis.

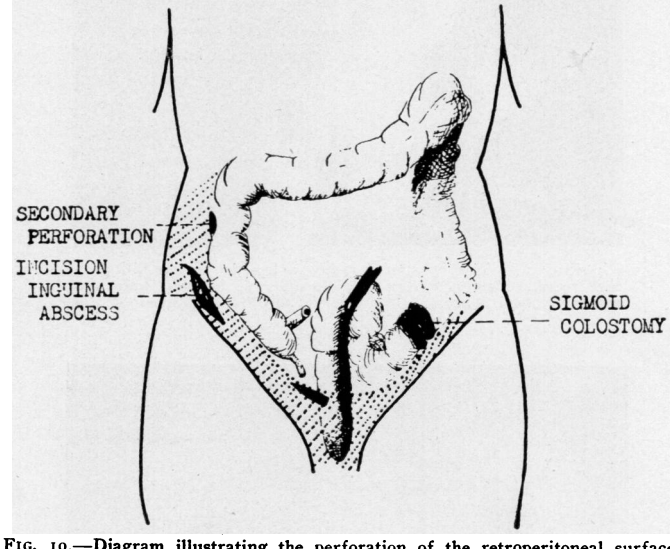

FIG. 10.—Diagram illustrating the perforation of the retroperitoneal surface of the ascending colon proximal to the sigmoid colostomy.

Within this sinus there seemed to be a sequestrum apparently detached from the ascending ramus of the ischium. On November 1, 1944, under intravenous pentothal anesthesia, the sinus was opened widely and the sequestrum removed. No attempt was made to resuture the perforation of the rectum because of the presence of infection. Following this procedure, the infection gradually subsided and the patient's general condition gradually improved.

Once the infection of the infraperitoneal space has been completely controlled, an attempt will be made again to close the perforation of the rectal wall. If this is successful and the posterior wound heals, the colostomy may be closed to reëstablish intestinal continuity.

COMMENT: The ultimate result of this case is expected to be a successful one, but not without great danger and long and serious morbidity. This case differs from Case 1, first, in that colostomy was established as soon as it became clear that an extraperitoneal perforation of the rectum was present, and, secondly, in that some type of drainage of the infraperitoneal space was established immediately after injury, thus, preventing spread in undesirable locations difficult to recognize, and more difficult to reach. However, it

illustrates the inadequacy of draining the infraperitoneal space upward on the anterior surface of the lower abdomen. It, likewise, illustrates the inadequacy of drainage of the infraperitoneal space by a lateral incision

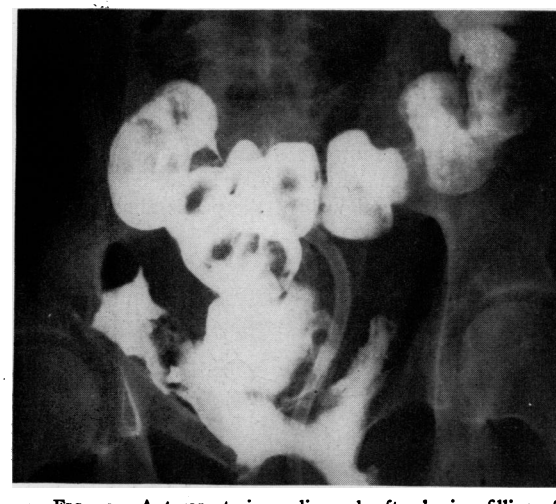

FIG. 11.—Anteroposterior radiograph after barium-filling of the rectum demonstrating the escape of barium into the infraperitoneal space.

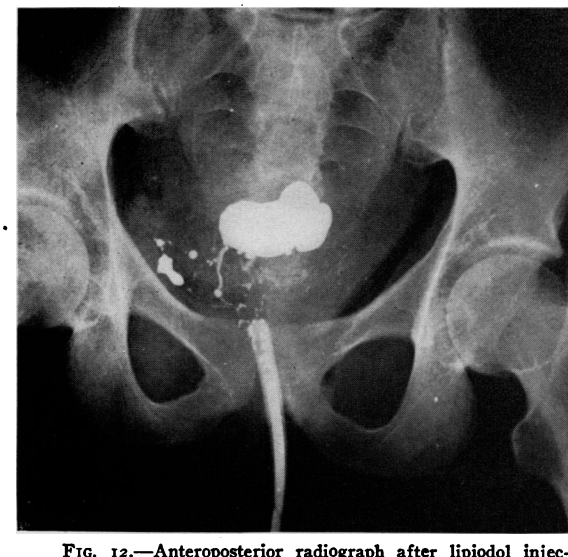

FIG. 12.—Anteroposterior radiograph after lipiodol injection of the suprapubic sinus. Note the communication along the right side of the pelvis with the large space anterior to the lower end of the sacrum. The top of the catheter lies in the suprapubic sinus.

extending through the levator (or coccygeus) and its fasciae. The incision twice failed over a long period of time to provide adequate drainage of the infection of the infraperitoneal space and to permit healing of the sinus

extending to the lower abdominal wound. These objectives, however, were readily obtained after coccygectomy.

Case 3.—A 22-year-old soldier sustained a bullet wound of the upper outer quadrant of the right buttock on the Italian front, September 24, 1943. A celiotomy was performed within six hours, but only an infraperitoneal pelvic hematoma was found, and the abdomen was closed without colostomy. The immediate postoperative course was moderately stormy and he soon began to drain feces through the wound of entrance. On October 23, 1943, a sigmoid colostomy was performed to divert the fecal stream. The patient continued, however, to drain a moderate amount of pus from the right buttock

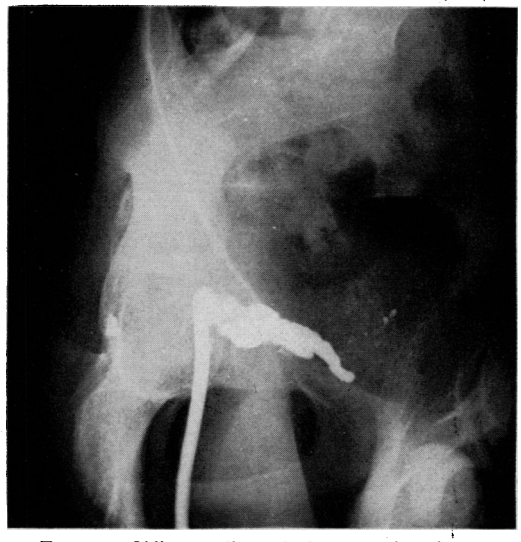

FIG. 13.—Oblique radiograph demonstrating the extension of the lipiodol-filled sinus anteriorly around the rectum on the right toward the symphysis pubis. The tip of the catheter lies in the posterior wound.

and he was returned to the Zone of Interior. On arrival here, the patient was moderately septic and somewhat malnourished. There was loculation of pus in the right buttock near the wound of entrance. The celiotomy wound was well-healed and the sigmoid colostomy was functioning well. Barium enema revealed no abnormality. Proctoscopic examination revealed a deep dimpled granulation three inches above the anal orifice at three o'clock (Fig. 14). The bullet could be felt in the deep tissues of the para-anal region at nine o'clock (Fig. 15).

R. B. C. was 4.2 million per cu. mm.; W. B. C. 7,750 per cu. mm.; hemoglobin 13.5 Gm. per cent; uranalysis was normal; N. P. N. 28 mg. per cent; sugar 99 mg. per cent; plasma protein 7.39 Gm. per cent. Lipiodol injection of the wound of entrance revealed extensive ramifying fistulae in the retrorectal space (Fig. 16). On December 15, 1943, the lower rectum was exposed by coccygectomy, the perforation was closed, the fistulae were widely opened, the bullet removed from the para-anal region, and the entire retrorectal space loosely packed. This wound healed slowly but cleanly. Meanwhile, pus continued to drain from the wound of entrance in the right buttock and finally several spicules of bone appeared. Roentgenologic studies revealed osteomyelitis, with sequestration of the lower aspect of the right sacro-iliac joint. On January 19, 1944, the upper half of the bullet tract was saucerized and sequestrectomy performed. This wound healed slowly but uneventfully until May 26, 1944, when a plastic secondary closure was performed. On July 18, 1944, the posterior wounds having healed, the sigmoid colostomy

was closed. A protective cecostomy was simultaneously established because a nasal deformity precluded passing a Miller-Abbott tube. Both wounds healed uneventfully, and normal bowel habits were restored. The soldier gained in weight and strength and was returned to full duty.

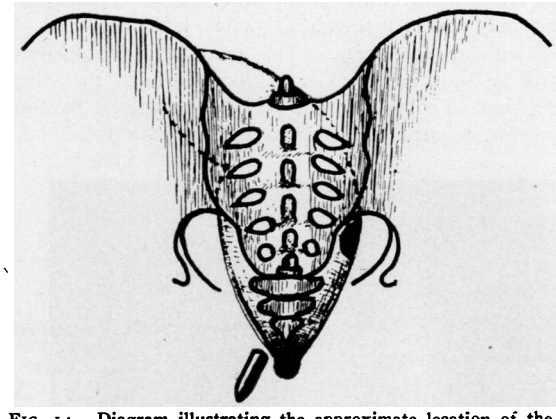

FIG. 14.—Diagram illustrating the approximate location of the perforation of the rectum. (Posterior view)

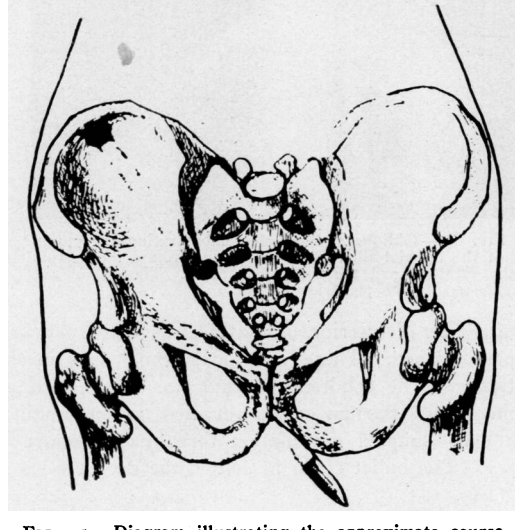

FIG. 15.—Diagram illustrating the approximate course of the bullet. (Anterior view)

COMMENT: This case had a successful outcome, but, likewise, a long and serious morbidity. It is not clear from the records how soon after trauma the perforation of the rectum became manifest by the appearance of fecal drainage from the wound, but it is probable that only a contusion of the rectal wall was present until infection of the bullet tract caused a secondary perforation. This may have saved the patient from death or more serious morbidity since the fecal contents drained into a prepared and partially walled-off fistulous tract. Because the pressure from its direct communication with the bowel was not relieved it soon honeycombed through the little resist-

ing tissues of the infraperitoneal space. Sigmoid colostomy was established one month after the injury, but the damage was already done and the honeycombed labyrinthine fistulae continued to be infected from the communication with bowel. Saucerization of the perirectal space through coccygectomy together with closure of the perforation was necessary to ablate these fistulae. The proximal intramuscular portion of the bullet tract was ignored in our first operation, and it may have been expected to heal were it not for the fact that osteomyelitis of the lower end of the sacro-iliac joint with sequestration, had developed. Once sequestrectomy was performed healing of this portion of the tract developed uneventfully.

FIG. 16

FIG. 17

FIG. 16.—Oblique radiograph after lipiodol-filling of fistula through the wound of entrance and barium-filling of colon, both proximal and distal to colostomy.

FIG. 17.—Lateral radiogram after lipiodol injection of the external fistulous tract in the right buttock revealing its entrance into the rectum.

Case 4.—A 30-year-old officer sustained a through-and-through gunshot wound of both buttocks while on the Italian front on July 16, 1943. He was taken prisoner but subsequently retaken by Allied troops. Meanwhile, a fecal fistula had developed in both wounds of entrance and exit and a sigmoid colostomy was, therefore, established on July 24, 1943. The wounds continued to drain pus and feculent material, and, August 16, 1943, he was returned to the Zone of Interior.

On arrival here, September 22, 1943, his general condition had improved. He was still 26 pounds below his maximal weight. The gunshot wounds had healed and his colostomy was functioning well. Proctoscopic examination failed to reveal any lesion of the lower bowel and barium studies of bowel both proximal and distal to the colostomy were essentially normal. Accordingly, October 4, 1943, the sigmoid colostomy was closed. The immediate postoperative convalescence was essentially normal. On October 19, 1943, the wound in the right buttock reopened and began to drain at first serosanguineous, then purulent material. Lipiodol was injected into its orifice and was found on roentgenologic examination to enter the rectum (Fig. 17). Later, methylene blue, likewise, injected, was observed entering the rectal ampulla in the middle of the

posterior wall 6.5 cm. above the anal orifice but the internal orifice of the fistula was hidden behind a rectal valve. It was decided to treat the fistula conservatively, and by November 22, 1943, the external orifice had healed completely. On January 12, 1944, this wound reopened and discharged feces. Rectal examination now revealed a palpable granuloma in the previously observed location of the internal orifice of the fistula. On January 24, 1944, the fistulous tract was excised, employing a T-shaped incision and exposing the rectum by coccygectomy. The rectal mucosa at the site of perforation was found everted and embedded into an osteoperiosteal scar in the lower segment of the sacrum in such a manner that it could never have healed. After freeing the edges of the defect in the rectum they were inverted by two purse-string sutures, the osseous defect

FIG. 18.—Posteroanterior radiograph showing lipiodol entering the rectum after injection of the external fistulous orifice. The fistula itself appears as a faint line extending to the left. Note fracture of descending ramus of right pelvis.

was curetted and the wound lightly packed and left unsutured. A transverse colostomy was established. Healing was uneventful. Penicillin was administered parenterally. On March 28, 1944, the cleanly granulating posterior wound was revised and secondary suture performed.

On May 25, 1944, the transverse colostomy was closed. Healing again was uneventful. The patient had gained in weight and strength, bowels were functioning normally, and all wounds had been completely healed for several months when the patient was returned to duty on August 12, 1944.

COMMENT: The lessons to be learned from a study of this case are invaluable. Here, again, despite the failure to establish early sigmoid colostomy and adequately drain the infraperitoneal space by coccygectomy, this patient, fortunately, developed merely a fecal fistula rather than a spreading infraperitoneal infection. The reasons for the development of a rapidly spreading infraperitoneal sepsis in some cases and a mere fecal fistula in others is unknown to us. It may be, as already suggested above, that these cases which develop fecal fistula represent late secondary perforations of a contused area of rectum into an already prepared missile tract. However, such an outcome is unpredictable and where there is presumptive evidence of rectal

injury a proximal colostomy should be established immediately as a life-saving procedure. Once a sigmoid colostomy was established, and the intraluminal pressures and gross contamination of functioning bowel removed, the fecal fistula seemed to heal. In the light of subsequent events, it appears that the external orifice and most of the fistulous tract may heal, only to reopen again if the internal orifice at the mucous membrane remains open, and the intraluminal pressure and gross contamination of normally functioning bowel is restored by closure of colostomy. The internal orifice of this fistula would never have healed because the everted edges were embedded in the scarred defect in the sacrum. This scar was not readily discovered because it lay hidden just proximal to one of the rectal valves. This case, likewise, illustrates the unreliability of demonstration of these defects with barium. Above all, it illustrates the importance of closure of the internal orifice of these rectal fistulae, with wide saucerization of the adjoining bowel surface.

Case 5.—A 25-year-old soldier sustained shell fragment wounds of the right buttock and left thigh March 29, 1943, in the North African campaign. He was admitted to a Surgical Hospital where the wound of the right buttock was débrided and found to communicate with the rectum. He was transferred to an Evacuation Hospital where a laceration, 3 cm. in diameter, 7 cm. above the anal orifice, was discovered. On April 2, 1943, a loop-colostomy of the sigmoid was established and opened on April 4, 1943. On April 6, 1943, a large metallic foreign body was removed from the wound of the medial aspect of the upper left thigh. The soldier escaped injury to the neurovascular structures of the left lower extremity. Both wounds healed rather slowly and a chronic fistulous tract developed in the wound of the right buttock communicating with the rectum. The patient was returned to the Zone of Interior. On arrival here, his general condition was fair. He was still some 35 pounds below maximal weight. There was a well-healed, long, lower left rectus abdominal scar through the lower end of which presented the loop-colostomy of the sigmoid. There was a clean granulating wound of the lower aspect of the right buttock about 6 cm. lateral to the anus. Near its center was the external orifice of the fistulous tract. There was a healing wound on the anteromedial aspect of the upper left thigh. Roentgenologic studies of the pelvis revealed a healing fracture of the descending ramus of the right pubis. After cleansing the rectum, proctoscopy revealed the granulating internal orifice of the fistula on the right posterolateral wall of the rectum about 7 cm. above the anal orifice. On May 13, 1943, the fistula was visualized by lipiodol injection (Fig. 18). The lipiodol readily entered the rectal ampulla. On May 30, 1943, the fistula was excised by radial incision overlying its entire extent. The sphincters were spared. The induration margins about the mucous membrane of the internal orifice were trimmed and the fresh margins inverted with fine catgut suture. The wound was then lightly packed open. It healed very cleanly by secondary union. On June 18, 1943, anoscopic examination revealed that the internal orifice was well-healed with a slightly raised margin. On July 8, 1943, the wound of the left thigh was completely healed. The operative wound of the buttock was healed except for a ribbon of clean granulation tissue at the skin level. Accordingly, July 9, 1943, the sigmoid colostomy was closed with delayed closure of extrafascial layers. Bowels functioned spontaneously and normally. Sphincter action was good. All wounds were completely healed by August 20, 1943. The patient regained his weight and was discharged to duty September 27, 1943.

COMMENT: This case is very similar to Case 4, except that the fistulous tract did not close at all, despite the sigmoid colostomy. After demonstrating

the fistulous tract and its internal orifice, the former was excised and the latter properly sutured. This was one of our earlier experiences and because the tract and perforation were low, a lateral approach directly over the fistula and through the levator was employed, without coccygectomy. Suture of the perforation was technically difficult and, in the light of our subsequent experiences, a coccygectomy would have facilitated the repair of the internal fistula and made healing more certain, because of better exposure and wider drainage.

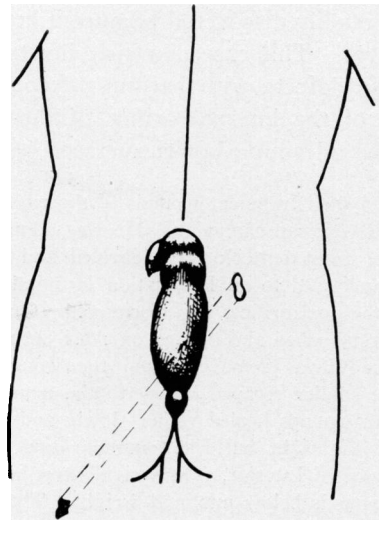

FIG. 19

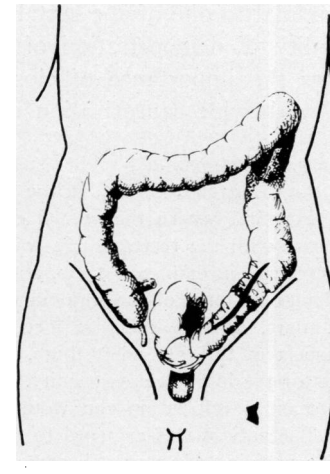

FIG. 20

FIG. 19.—Diagram illustrating the perforations of the rectal wall. (Posterior view)

FIG. 20.—Diagram illustrating the closure of the sigmoid colostomy.

Case 6.—A 36-year-old soldier sustained a mortar shell fragment wound of the right buttock, while in the process of "digging in" during the Sicilian campaign on August 7, 1943, at 1300 hours. He walked to an Aid Station three miles back where the wound was dressed, and then proceeded another ten miles on foot to an Ambulance Station where the wound was redressed. He was then transferred to an Evacuation Hospital, arriving on 1600 hours, August 8, 1943, 27 hours after the injury. At this hospital proctoscopy revealed a perforation of the rectum (Fig. 19), and sigmoid colostomy was established at once without exploratory celiotomy. His convalescence was essentially uneventful. He was transferred to the Zone of Interior. On arrival here, September 25, 1943, the general physical condition was noted to be good. A double-barrel spur colostomy presented through a well-healed left gridiron incision. There was a well-healed scar, 5 cm. long, in the upper medial quadrant of the right buttock. After cleansing the rectum, digital examination revealed a tender pit-like depression at three o'clock and another at eight o'clock, 4 cm. above the anal orifice. These areas were examined on proctoscopy and were seen to be healed wounds. Barium studies of the large bowel, both proximal and distal to the colostomy, revealed no abnormalities. On October 1, 1943, the colostomy was closed by end-to-end anastomosis intraperitoneally. The spur was not reduced in the usual manner because a large artery was readily palpable within its walls. The wound was closed, leaving a Penrose drain to the site of anasto-

mosis (Fig. 20). Convalescence was uneventful. The wound healed *per primam*, and normal bowel function was restored. The patient was discharged to a Reconditioning Center on November 12, 1943.

COMMENT: This case differs from the foregoing cases in that a perforation of the rectum was discovered very shortly after injury and a sigmoid colostomy established. Neither drainage of the infraperitoneal space nor closure of the perforation were performed, and yet the wound perforating the rectum healed uneventfully after early colostomy. This, however, does not justify the omission of these procedures. Fortunately, both the wounds of entrance and exit in the bowel wall were small and clean-cut perforations, without eversion of the mucous membrane into the wound of exit. This cannot be determined at the time of injury, however, without exploration of the bowel wall surgically.

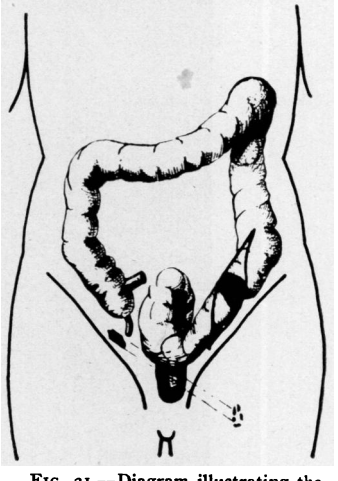

FIG. 21.—Diagram illustrating the course of the missile, the position of the foreign body, and the sigmoid colostomy. (Anterior view)

Case 7.—A 35-year-old soldier sustained a shell fragment wound of the right buttock while lying in a slit trench, on August 7, 1943, in the Sicilian campaign. Several hours later, August 8, 1943, an exploratory celiotomy through a lower right rectus incision was performed at a nearby Evacuation Hospital. No intraperitoneal lesion was found, but there was an extensive infraperitoneal pelvic hematoma. The wound was closed without drainage and without colostomy. On August 13, 1943, he was transferred to another Evacuation Hospital, and a laceration of the rectum was found on proctoscopic examination, accordingly, a sigmoid colostomy was established through a left gridiron incision (Fig. 21). He was returned to the Zone of Interior. On arrival here, September 22, 1943, his general condition was fair except for moderate weight loss. The lower right rectus scar was firmly healed. A single stoma of the sigmoid colostomy presented through a well-healed left gridiron incision. The septum was palpable just below the surface. There was a healed wound, 2 cm. long, in the right buttock, and another, 4 cm. long, in the left. After cleansing the rectum, proctoscopic examination failed to reveal any evidence of any unhealed lesion nor was any scar of a healed lesion recognized. Roentgenograms of the pelvis revealed a metallic foreign body, 1.5 x 1 x 0.7 cm., lying in the pelvis anterior to the upper margin of the sacrum on the right. Another foreign body, 3 mm. in diameter, appeared to lie medial to the right acetabulum. Barium visualization of large bowel proximal and distal to the colostomy failed to reveal any abnormality (Fig. 22).

Accordingly, September 28, 1943, closure of the loop-colostomy was performed under spinal anesthesia, with delayed closure of the extrafascial layers of the abdominal wound. A Penrose drain was placed down to the site of suture. Postoperative convalescence was uneventful. Skin sutures were tied on the fourth postoperative day. The wound was completely healed by October 27, 1943 (Fig. 23). The patient had regained most of his weight but little of his strength. His bowels were functioning normally and spontaneously. On November 12, 1943, he was discharged to a Reconditioning Center.

COMMENT: This is the only case in this series in which evidence of a healed fistula could not be ascertained. This does not, however, discredit the early observation of the presence of a laceration of the rectum, although the position of the lesion was not described. On the contrary, this case illustrates the wisdom of establishing colostomy even on reasonable suspicion of the presence of a perforation of the infraperitoneal rectum. We may go one step further and state that the presence of an infraperitoneal hematoma

FIG. 22.—Anteroposterior radiograph after barium-filling of the rectum. Note the foreign bodies in the pelvis.

from a missile traversing the infraperitoneal space, is presumptive evidence either of laceration of the rectum, contusion of its wall, or infarction from injury to its blood supply, and should be treated by prophylactic sigmoid colostomy. The danger of perforation, with its spreading infection, is thus averted or mitigated at little cost in morbidity. We may go even one step further to state that this procedure should be followed by coccygectomy with drainage of the infraperitoneal space and closure of the perforation of the rectum if one should be found. This additional procedure adds little to the operative shock and may save the patient's life or shorten his convalescence. Drainage of a potentially infected hematoma may prevent actual spreading infection, and even secondary perforation of the rectum.

Case 8.—A 19-year-old soldier sustained multiple shell fragment wounds on the Italian front on July 17, 1944, at 1000 hours. Fragments penetrated the scalp, neck, left forearm, left hemithorax posteriorly, both buttocks, and left leg. The last fragment caused a compound fracture of the left fibula, while one of the wounds of the left buttock perforated the rectum (Fig. 24). On July 18, 1944, several hours after the injuries, at an Evacuation Hospital, all these wounds were extensively débrided and foreign bodies were removed from scalp, neck and leg. A coccygectomy was performed and the infraperitoneal space adequately drained, but it is not known whether the rectal perforation was sutured. A celiotomy was performed under ether anesthesia, and a large retroperitoneal pelvic hematoma but no intraperitoneal injury was found. A sigmoid colostomy was performed. On August 1, 1944, secondary suture of wounds was performed and a skin graft was applied three days later to a wound of the elbow. The patient's convalescence was essentially uneventful. All his wounds healed rapidly and cleanly except the coccygectomy wound. This wound healed slowly and continued to drain pus and mucus. The patient was returned to the Zone of Interior. He arrived here on October 3, 1944.

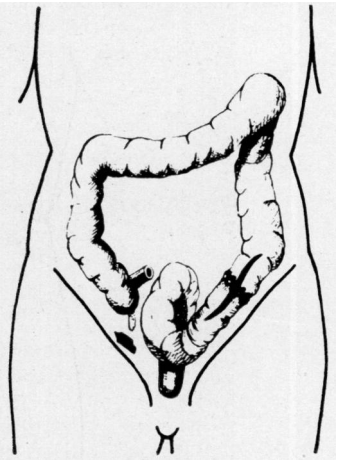

FIG. 23.—Diagram illustrating the closure of sigmoid colostomy. (Anterior view)

On arrival, the patient was somewhat malnourished, since he was still some 40 pounds below his best weight. He was ambulatory and comfortable. His wounds were all healed except for a suspected fistula in the coccygectomy wound already noted. The presence of mucus aroused suspicion of a communication with the rectum. There was a residual paralysis of the left ulnar nerve. The sigmoid colostomy was functioning well. R. B. C., 5.0 million per cu. mm.; W. B. C., 6,500 per cu. mm.; hemoglobin, 15.5 Gm. per cent; N. P. N., 39 mg. per cent.

Proctoscopic examination revealed a small granulating internal orifice of the fecal fistula almost directly posterior, 8.75 cm. above the anal orifice, and its communication with the external orifice in the coccygectomy scar was demonstrated both by lipiodol, and methylene blue injection (Fig. 25). Roentgenograms further revealed residual foreign bodies in the neck and chest.

On October 26, 1944, a resection of the fecal fistula was performed through the original wound. The internal orifice of the fistula was closed with two rows of No. 0000 chromic catgut. The wound was loosely packed, without closure, and has healed uneventfully, but slowly by secondary intention. The patient is now ready for closure of the colostomy to reëstablish the normal channels.

COMMENT: This patient received almost ideal treatment. The surgeon recognized the presence of a perforation of the rectum and established adequate drainage of the infraperitoneal space by partial coccygectomy, then provided a sigmoid colostomy. It seems unlikely that the surgeon sutured the perforation of the rectum, if indeed he found it, since it lay in a position difficult of access on the left lateral wall of the rectum and the remainder of the coccyx had to be removed before it could be reached. This case illustrates, however, that wide saucerization of the infraperitoneal space, with exposure of the rectum, whether or not the perforation is sutured, is adequate

prophylaxis against the death-dealing infraperitoneal sepsis. Failure to suture the perforation of the rectum, however, resulted in this case in the development of a chronic fistula. The presence of such a fistula, if it is short and thick-walled, is not incompatible with a fairly good state of health. Such fistulae once well-established, rarely heal spontaneously and require excision or at least closure of the internal orifice in the bowel wall.

Case 9.—A 30-year-old soldier sustained multiple shell fragment wounds on the Italian front at 1200 hours on May 23, 1944. These fragments penetrated the coccygeal region and the right buttock and perforated the left knee. At 1820 hours, under gas-

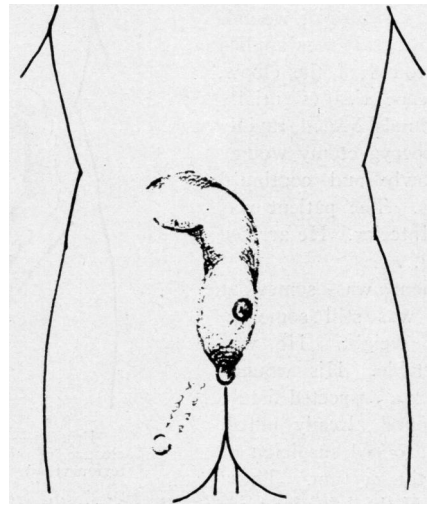

FIG. 24.—Diagram illustrating the perforation of the rectal wall. (Posterior view)

oxygen-ether anesthesia, operation was performed. On abdominal exploration through a lower midline incision, six small perforations of the ileum and one of the bladder were sutured, a sigmoid colostomy and suprapubic cystostomy were established. The abdominal wound was closed about a suprapubic catheter, leaving a rubber tissue drain in the space of Retzius. Coccygectomy was performed, the rectum exposed, the perforation was found and sutured, and the infraperitoneal space loosely packed. The other wounds were débrided and a foreign body removed from the wound of the left knee.

Convalescence was essentially uneventful. The suprapubic catheter was removed on June 12, 1944. A urethral catheter was introduced on June 16, 1944, and removed on June 23, 1944. Since then the bladder has functioned quite normally.

Before the coccygectomy wound had healed, an artery forceps was applied to crush the spur of the sigmoid colostomy but, fortunately, this was rather ineffectual, since little fecal material has passed into the rectum. Meanwhile, the coccygectomy wound failed to heal completely and a sinus developed which drained mucus and pus. The patient was returned to the Zone of Interior.

On arrival here, October 3, 1944, the patient appeared well-nourished, ambulatory and comfortable. His wounds were completely healed except for the coccygectomy wound, in the center of which there was a granulating orifice, 0.5 cm. in diameter, draining a moderate amount of mucopus.

R. B. C., 4.37 million per cu. mm.; W. B. C., 5,700 per cu. mm.; hemoglobin, 12.5

Gm. per cent. Proctoscopic examination revealed a small granulating perforation, the internal orifice of the suspected fecal fistula, 7.5 cm. above the anal orifice, directly posterior. That this was the internal orifice of the fecal fistula whose external orifice was present in the coccygectomy scar, could not be demonstrated either by lipiodol or methylene blue injection, but was finally demonstrated by the passage of a urethral catheter into the lumen of the rectum.

On October 13, 1944, the fistulous tract was excised. The internal orifice was sutured, the investing fascia approximated and the wound lightly packed. Early in the postoperative course, the suture line closing the perforation in the rectal wall, partly reopened. The mucous membrane did not become everted and, with conservative treatment, healing occurred. The wound was allowed to heal by secondary intention. The patient is now ready for closure of the colostomy.

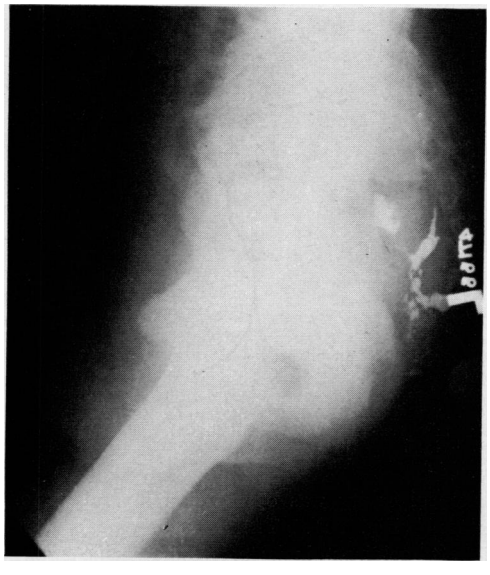

FIG. 25.—Lateral radiograph after lipiodol injection of external fistulous orifice.

COMMENT: This patient received ideal treatment; not only was a sigmoid colostomy established and the infraperitoneal space properly drained, but the perforation of the rectal wall was found and sutured. Unfortunately, this first closure did not hold and the perforation became reëstablished. As in the last case, this merely increased the morbidity without endangering the patient's life. The success of the second closure was threatened. This case illustrates the importance of freeing the mucous membrane about the edges of the defect, trimming away indurated margins and properly inverting the edges with a fine suture. If this is done the break-down of the fascial suture line will probably not jeopardize the closure of the perforation by eversion of the mucous membrane through the reopened fascial defect.

This case, likewise, illustrates the difficulty in demonstrating the entire fistulous tract by employing any one method. In this case, three separate methods were used before success was achieved.

Case 10.—A 32-year-old soldier sustained a mortar shell fragment wound of the left buttock on the Italian front, April 8, 1944, at 1830 hours, while at the latrine in his company area. He tried to walk back to his quarters, but collapsed. He was transported to a nearby Clearing Station, and thence to a Field Hospital where operation was performed a few hours later on April 9, 1944. Under endotracheal ether anesthesia, the wound of the buttock was débrided and perforation of the rectum discovered. Through a midline coccygeal incision, the coccyx was resected, the rectum exposed, the perforation closed and the infraperitoneal space loosely packed. Through a lower left

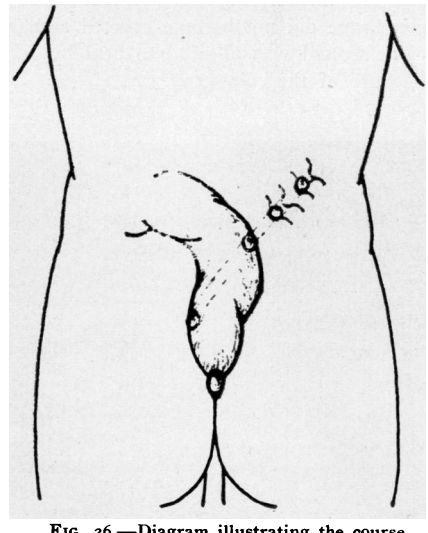

FIG. 26.—Diagram illustrating the course of the missile and perforations of rectum and two loops of small bowel. (Posterior view)

rectus incision, the peritoneal cavity was opened and several perforations of the ileum were discovered and closed (Fig. 26). Then a spur-type of sigmoid colostomy was performed through a left gridiron incision. Sulfadiazine was administered postoperatively. The postoperative course was very satisfactory, and the patient became neither septic nor malnourished. There was some delay in the healing of the transcoccygeal wound due to a sequestrating osteomyelitis of remaining coccyx. The sequestrum was removed, May 9, 1944, and thereafter the wound healed uneventfully. The patient was transferred to the Zone of Interior on July 23, 1944. On admission, the patient's general condition was good. The sigmoid colostomy was functioning well, the wounds were healed, and he had no complaints. Barium studies of the large bowel and proctoscopy failed to reveal an unhealed internal fistulous orifice. R. B. C., 4.4 million per cu. mm.; W. B. C., 8,700 per cu. mm.; hemoglobin, 14.5 Gm. per cent. Uranalysis was negative. N. P. N. was 34. mg. per cent; chlorides, 495 mg. per cent; plasma protein, 7.2 Gm. per cent. After a satisfactory period of observation and recuperation, the sigmoid colostomy was closed extraperitoneally on October 13, 1944. The postoperative convalescence was again uneventful. Rectal evacuations were normal and spontaneous, and he has gained weight. He was transferred to Reconditioning Center on December 8, 1944.

COMMENT: This case illustrates the acme of the current ideal management of infraperitoneal perforation of the rectum. Besides establishing a sigmoid colostomy and saucerizing the infraperitoneal portion of the rectum

the perforation was found and closed. It remained closed and healing occurred quite uneventfully.

All the cases presented above received excellent and early supportive treatment of plasma, blood and chemotherapeutic agents. The difference in their subsequent clinical courses, as we have already indicated, was primarily dependent on the type of surgery and the time of its application. It is probable that many who did not receive early and adequate surgery did not survive to return to the Zone of Interior. The effectiveness of early and adequate surgery in influencing the mortality and morbidity in infraperitoneal rectal wounds is so obvious that it cannot be overemphasized. We have reached the following conclusions as a result of our observations:

CONCLUSIONS

1. Perforation of the infraperitoneal portion of the rectum results in fecal contamination of the cellular tissue of the infraperitoneal space. This space communicates with the retroperitoneal space posteriorly over the sacrum and may, thus, result in fulminating and widespread retroperitoneal sepsis.

2. Even if the perforation cannot be located, but there is a presumptive evidence of its presence or potential development from contusion or infarct of the rectum as judged from the course of the missile and the presence of a large hematoma in the infraperitoneal space, an effective sigmoid colostomy should be established at once.

3. A sigmoid colostomy alone will not prevent infection of the infraperitoneal space, although the infection is likely to be less widespread and fulminating once contact with the normal intraluminal pressure and gross contamination of normally functioning bowel is severed. In addition, the infraperitoneal perirectal space must be saucerized by coccygectomy and loosely packed.

4. Mere saucerization of the perirectal space, while life-saving and prophylactic against spreading retroperitoneal sepsis, is not, however, complete ideal treatment. Unless the perforation is located and closed, a persistent fistula may develop.

The authors wish to acknowledge their appreciation of the contributions made by Major Hazen L. Hauman and Major Joseph M. Miller in the clinical management of the cases presented, and Major A. Bradford Soule in the radiologic studies and photographic reproductions.

REFERENCES

[1] Gordon-Taylor, G.: Diagnosis and Treatment of Injuries of Intestines. Brit. M. J., **2**, 639, October 22, 1921.

[2] Gordon-Taylor, G.: Abdominal Injuries of Warfare. Brit. M. J., **2**, 181, July 22, 1939; *idem:* 235, July 29, 1939.

[3] Drummond, H.: Gunshot Wounds of Large Intestine and Rectum. Proc. Roy. Soc. Med. (Sect. Surg.), **13**, 24, December, 1919.

[4] Frazer, J.: Wounds of Abdomen. Brit. M. J., **1**, 321, March 10, 1917.