

**CLOSURE OF COLONIC STOMA:
IMPROVED RESULTS WITH COMBINED
SUCCINYLSULFATHIAZOLE AND SULFATHIAZOLE THERAPY***

CLAUDE F. DIXON, M.D.,

DIVISION OF SURGERY

AND

RAYMOND E. BENSON, M.D.

FIRST ASSISTANT IN SURGERY, MAYO CLINIC

ROCHESTER, MINN.

THE RESULTS OF CLOSURE of colonic stomas always have been unsatisfactory in a rather high percentage of cases. This procedure necessarily has to be carried out in a field that is contaminated with many bacteria. In the past, wound infection frequently has followed closure of a colonic stoma. In many cases, extensive abscesses have formed in the subcutaneous tissues; the edges of the skin have become undermined, and multiple draining sinuses have made the patient a semi-invalid for weeks or months. Even more distressing than these complications, in some cases, has been the resumption of fecal drainage from the wound. Since we have been using a combination of succinylsulfathiazole and sulfathiazole in the treatment of persons subjected to surgical closure of colonic stomas, the incidence of these complications has been lowered remarkably.

MATERIAL

This paper is based primarily on 102 consecutive cases (Group 1) in which succinylsulfathiazole and sulfathiazole were employed while the patients were hospitalized for closure of colonic stomas. In order to obtain an unbiased evaluation of the results of this treatment, three other groups of cases have been considered. In each of these three groups of cases the patients were hospitalized for closure of colonic stomas and, with the exception of the administration of the sulfonamides, the treatment was the same as that employed in Group 1. Group 2 includes 102 consecutive cases in which no sulfonamide drug was used. Group 3 includes 40 cases in which only sulfanilamide was employed. Group 4 embraces 30 cases in which only sulfathiazole was administered.

TREATMENT EMPLOYED IN CASES OF GROUP 1

After the spur of the colonic stoma had been eradicated by application of clamps, and sufficient time had elapsed to allow all edema and induration at the site of the stoma and in the surrounding tissues to subside, the stoma was considered ready for closure.

Preoperative Treatment.—The patients routinely were hospitalized for three full days (72 hours) before the stoma was closed. As soon as they had been admitted to the hospital a nonresidue, high carbohydrate diet was prescribed and the oral administration of succinylsulfathiazole was started. We have standardized the dose of this drug even though there is good evidence that the effect of the drug varies considerably among different patients. In the

* Read before the American Surgical Association, May 3-4, 1944, Chicago, Ill.

CLOSURE OF COLONIC STOMA

case of an adult, 4 Gm. of the drug was administered as soon as the patient had been admitted to the hospital. This dose was repeated every four hours until six doses (24 Gm.) had been given. Thereafter, a dose of 2 Gm. was administered every four hours (12 Gm. in 24 hours); the last dose was given approximately six hours before the operation was performed.

The proximal and distal loops of colon were irrigated daily with warm tap water for three days before the operation. The irrigating was done through the colonic stoma and through the rectum. The final irrigation was done 24 hours before the operation was performed. During the 24 hours before the

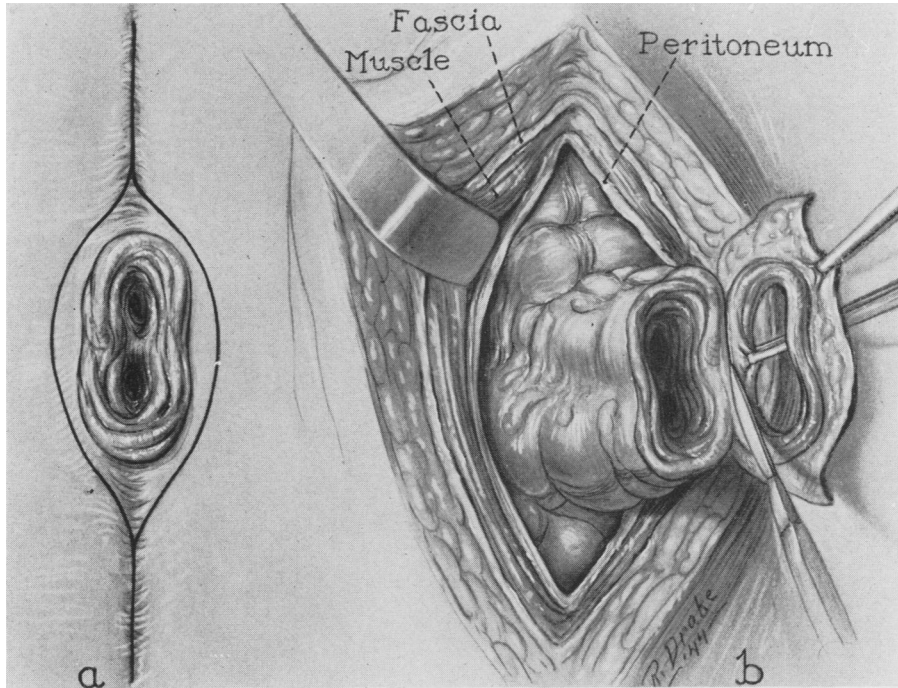


FIG. 1.—Closure of colonic stoma. *a.* Incision in skin encircling the stoma. *b.* The fascial, muscular and peritoneal layers have been incised and the proximal and distal limbs of colon are mobilized. The previously encircled layer of skin and subcutaneous tissue is being excised from the wall of the bowel. The edges of the colonic stoma are freshened by excising a narrow margin of it.

operation, two drachms (8 cc.) of camphorated tincture of opium were administered every four hours, and any fluid that had been retained in the proximal or distal segments of the colon was removed by aspirating through the colonic stoma and through the rectum with a large bulb syringe. The last dose of camphorated tincture of opium was administered approximately eight hours before the operation. The last aspiration also was performed about the same time.

Surgical Treatment.—An incision was made on each side of the stoma passing through the scar produced by the previous operation. These incisions were joined so as to encircle the stoma. Then the colon was freed from the anterior abdominal wall at the site of the stoma (Fig. 1). The deep fascia was

next cleansed of fat and scar tissue sufficiently to form a definite layer which subsequently could be approximated to restore the strength of the abdominal wall. This fascia then was incised. In all cases the peritoneum was then opened and the two limbs of colon mobilized sufficiently to allow accurate approximation (Fig. 1). Immediately adjacent to the peritoneum, one frequently encounters a thin layer of adhesions which have "walled-off" the site of the stoma from the main peritoneal cavity. When these adhesions were

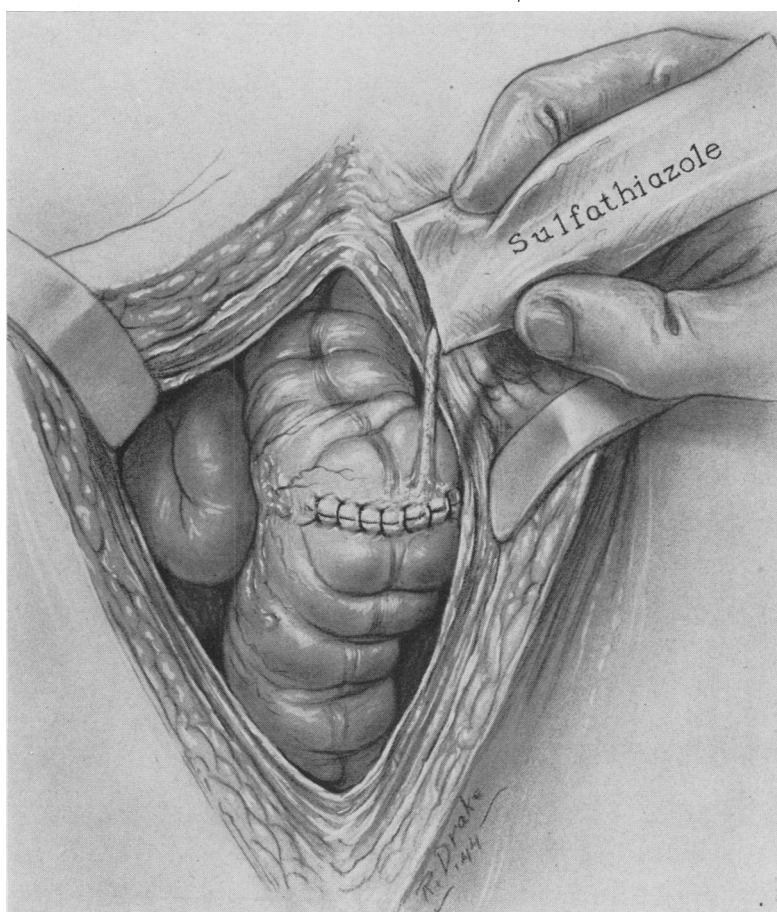


FIG. 2.—The stoma has been closed transversely to the long axis of the bowel. The completed anastomosis is dropped back inside the peritoneal cavity and 5 Gm. of sulfathiazole inserted.

encountered, they were not disturbed unnecessarily. The previously encircled cuff of skin and subcutaneous tissue then was excised from about the stoma. The edges of the stoma were freshened by excising a narrow margin and the colonic opening was closed transversely to the long axis of the bowel with two layers of running chromic catgut sutures. Additional interrupted catgut sutures were inserted in some cases. In a few cases, the mesial edges of the intestine had not united to form the usual colonic spur; consequently, the spur could

not be crushed preoperatively and it was necessary to separate the proximal and distal loops of the colon and perform a complete end-to-end anastomosis. The anastomosis being completed, the colon was dropped back into its normal position within the peritoneal cavity (Fig. 2).

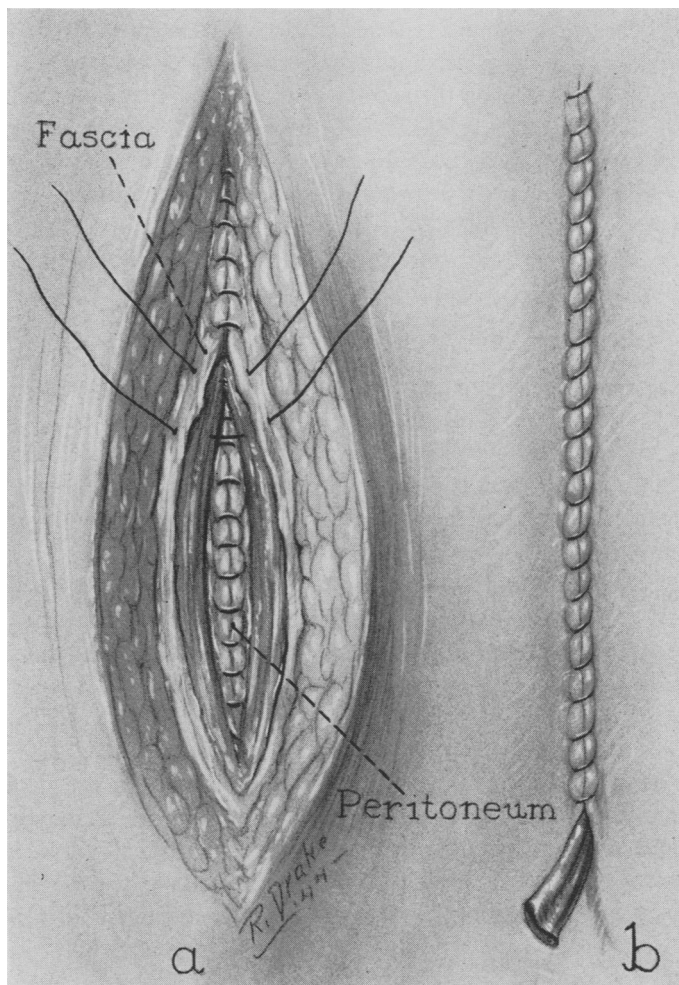


FIG. 3.—*a*. The peritoneal, muscular and fascial layers are closed with a running suture. *b*. A Penrose drain and a few grains of sulfathiazole are placed in the subcutaneous layer. The skin is closed.

Sulfathiazole powder was dusted intraperitoneally around the site of closure. Five grams were so administered routinely, but in occasional instances in which the subperitoneal space about the site of closure was small, lesser amounts, that is as little as 2.5 Gm., were used.

The peritoneal, muscular and fascial layers, which had previously been dissected free, were then closed tightly with surgical gut sutures (Fig. 3). Fifteen to 30 grains (1 to 2 Gm.) of sulfathiazole were dusted into the super-

ficial fatty layer. In most cases a small Penrose drain was inserted subcutaneously. The skin was closed snugly with a running suture of plain catgut. If the subcutaneous fatty layer was thick, a few retention sutures of braided silk were inserted to obliterate any potential dead space.

Postoperative Treatment.—Sulfonamide therapy was not employed postoperatively. Only small amounts of water, that is 15 to 30 cc. every four hours, were administered orally until flatus was passed freely from the rectum. In the average case, this was on the second or third day after operation. The diet then was increased gradually until the fifth or sixth day after operation, when a full diet was permitted. A large lubricated rubber tube was inserted into the rectum periodically in order to prevent pressure by retention of gas or feces. The operative wound received no special care except the routine application of dressings. The Penrose drain was removed on the fourth or fifth day after the operation.

TREATMENT EMPLOYED IN CASES OF GROUPS 2, 3 AND 4

In these groups there was no preoperative use of sulfonamides. In Group 2 (102 cases), as has been said, sulfonamides were not used at all. In Group 3 (40 cases) sulfanilamide, and in Group 4 (30 cases) sulfathiazole was dusted about the site of closure at operation. In other respects, including the preoperative treatment, the surgical technic and the postoperative regimen, treatment in these groups was the same as in Group 1.

Usually the quantity of sulfanilamide or of sulfathiazole applied locally, respectively, in Groups 3 and 4, was 5 Gm. In an occasional case, however, in which the subperitoneal space about the anastomosis was small, a lesser amount, as little as 2.5 Gm. of the powder under consideration, was employed.

RESULTS

In the cases in Group 1, namely, the 102 cases in which a combination of succinylsulfathiazole and sulfathiazole was employed, the incidence of wound infection and of recurrence of fecal drainage was remarkably low. In the majority of cases the wounds healed by primary intention. An extensive subcutaneous abscess did not occur in any case, and a resumption of fecal drainage from the wound occurred in only two cases (Table I). The postoperative febrile reaction was slight or minimal and in most of the cases the average time that was required for the intestine to resume its normal function was shorter than it was in the cases in Group 2, that is, in the 102 cases in which no sulfonamide drug was employed. In the usual case, as has been said, the patient was able to expel flatus freely from the rectum on the second or third day after the operation and normal bowel movements were resumed on the third or fourth day. In general, convalescence was remarkably easy and free of complications.

In marked contrast with the good results obtained in Group 1 are the distressing sequelae that frequently occurred in Group 2 (Table I). Spontaneous fecal drainage from the wound following surgical closure occurred in 31 cases,

CLOSURE OF COLONIC STOMA

or 30 per cent of the cases in this group. It occurred in only two of the 102 cases in Group 1. In some cases these postoperative fecal fistulae closed spontaneously, but in others they had to be closed by a secondary operation. In all cases in which a fecal fistula occurred it was a distressing complication which delayed complete recovery for weeks or months. Extensive wound infections were common before the advent of the sulfonamides. Moderate or severe infection of the wound occurred in 86 (84 per cent) of the cases in Group 2 in which no sulfonamides were used. In the cases of Group 1, however, wound infection developed in only 13, or 13 per cent of cases, and in only one case did extensive subcutaneous abscesses and undermining of the skin occur. In 82, or 80 per cent of the cases in Group 1, the wound had healed firmly by the fourteenth postoperative day; healing in a similar period was observed in only eight (8 per cent) of the cases in Group 2. The better results obtained in the cases in Group 1 must be attributed to the use of succinylsulfathiazole and sulfathiazole, as the treatment in the two groups of cases was the same in all other respects.

Sulfanilamide, as has been explained, was applied locally in the 40 cases in Group 3. Although the results were slightly better than those obtained in Group 2, namely, the 102 cases in which no sulfonamide drug was employed, they still were poor (Table I). Spontaneous fecal drainage from the wound

TABLE I
CLOSURE OF COLONIC STOMAS
COMPARISON OF RESULTS WITH VARIOUS FORMS OF TREATMENT

Group	Treatment	Total Cases	Infected Wounds, Per Cent	Resumption of Fecal Drainage, Per Cent	Wound Healed by 14th Postoperative Day, Per Cent
1	Succinylsulfathiazole and sulfathiazole.....	102	13	2	80
2	No sulfonamides.....	102	84	30	8
3	Sulfanilamide locally.....	40	77	25	10
4	Sulfathiazole locally.....	30	63	17	20

occurred in ten (25 per cent) of the 40 cases. Healing of the wound by the fourteenth day was observed in only four, or 10 per cent, of the cases. Wound infection occurred in 31 (77 per cent) of the cases.

Again, as has been related, sulfathiazole was applied locally in the 30 cases in Group 4. The results obtained in this group were somewhat better than those secured in Group 3, but they did not approach those that ensued in Group 1, that is, in the 102 cases in which a combination of succinylsulfathiazole and sulfathiazole was used. Spontaneous fecal drainage from the wound occurred in five, or 17 per cent, of the 30 cases. In six, or 20 per cent, of the cases the wounds had healed by the fourteenth postoperative day. Wound infection remained common and occurred in 19, or 63 per cent, of the cases.

In the 102 cases in Group 1 no deaths occurred in the hospital. In the 102 cases in Group 2, there were three postoperative deaths. Two were attributed to pulmonary embolism; the third resulted from peritonitis and pulmonary embolism. In the 40 cases of Group 3 there was one death in the hospital and

that was due to gangrenous cholecystitis. In the 30 cases of Group 4, one patient died from postoperative intestinal obstruction and peritonitis.

It is, thus, apparent that the results in the cases (Group 1) in which a combination of succinylsulfathiazole and sulfathiazole was used not only were better than those obtained in the cases (Group 2) in which no sulfonamide drug was employed but also were better than the results obtained in the cases (Groups 3 and 4) in which sulfanilamide or sulfathiazole was applied locally.

COMMENT.—Succinylsulfathiazole is the succinyl salt of sulfathiazole. Chemically, it is 2-(N₄-succinyl-sulfanilamido)-thiazole. It contains, in addition to the succinyl radical, a free carboxyl group^{1, 2, 3, 4}. When it is administered orally it is absorbed from the bowel in only very small amounts. Poth and Knotts^{4, 5} found that, on an average, only five per cent of the ingested drug was excreted by the kidneys. The majority is retained in the lumen of the intestine where it markedly reduces the number of coliform bacteria in the intestinal content. Sulfathiazole, on the other hand, is absorbed rapidly from the gastro-intestinal tract and while it has some effect on the intestinal bacterial flora this action is not pronounced.⁵ When placed locally in wounds, it exerts a powerful bacteriostatic effect without apparent injury to the surrounding tissues. The favorable results obtained with these two drugs in the cases in Group 1 apparently has been due to their ability to inhibit the growth of the many infectious organisms found in the large intestine.

In vitro, succinylsulfathiazole has little or no activity against strains of *Escherichia coli*. When the drug enters the intestinal tract and comes in contact with the intestinal mucosa, however, it evidently becomes a highly effective bacteriostatic agent. It has been shown that succinylsulfathiazole when administered orally may cause the number of coliform bacteria to become negligible. Thus it has been shown⁶ that specimens of stools obtained from various human beings, and which contained 10⁶ to 10¹⁰ organisms per gram of wet stool before the administration of succinylsulfathiazole was started, contained 0 to 500 or 700 organisms per gram of wet stool after therapy with this drug. How this drug, which is ineffective in the test tube, exerts such a profound influence *in vivo* has not been well established. Poth and Knotts⁶ have speculated that "succinylsulfathiazole must * * * be converted into a more active compound, probably sulfathiazole. The addition of the succinyl radical to sulfathiazole renders it poorly absorbable from the bowel. The free carboxyl group gives succinylsulfathiazole relatively strong acid properties and by salt formation maintains a high ionic concentration of the drug admixed with the intestinal contents. Succinylsulfathiazole, therefore, may be strongly absorbed or adsorbed by bacterial cells and may be hydrolyzed to give a high local concentration of a reactive, excited form of nascent sulfathiazole in intimate contact with the organism."

Concomitant with the reduction in the bacterial content of the stools there is a change in their physical characteristics. The stools become lighter in color, practically odorless, reduced in quantity and of a semiliquid consistency. Such

changes have been noted in some cases in which we had an opportunity to examine the intestinal contents shortly before, or in the course of, closure of a colonic stoma, when the drug had had time to exert its maximal effect.

If the oral administration of succinylsulfathiazole sterilized the stools completely, one would expect to obtain favorable results without the local application of sulfathiazole in cases in which operation is performed to close a colonic stoma. Such is not the case, however. The oral administration of large doses of succinylsulfathiazole for five to seven days occasionally will reduce the number of coliform bacteria in the stools to such an extent that they cannot be found by bacteriologic examination. In the majority of cases, however, some organisms remain in the stools even after prolonged therapy with this drug. In many cases in which the drug is administered for a relatively short time, as it was in the cases in Group I, an appreciable number of coliform bacteria must remain in the intestinal contents. The colon contains other bacteria, that is *Streptococcus faecalis*, typhoid and paratyphoid organisms and *Proteus vulgaris*, which apparently are not affected by succinylsulfathiazole. We, therefore, consider it advisable to apply sulfathiazole to the operative wound to control any infectious organisms which are not affected by succinylsulfathiazole and which inadvertently may be carried into the wound.

Recurrence of fecal drainage from the wound after closure of a colonic stoma may be due to various causes. If the colostomy spur has not been crushed adequately, the intestinal lumen may be encroached on and recurrence of fecal drainage may result. If one attempts to close the stoma too soon after it has been established, that is when the edges of the intestinal wall and the tissues about the stoma are edematous and indurated, the suture line may separate and fecal drainage recur. By far the most frequent cause of recurrence of fecal drainage from the wound following surgical closure is infection. The recurrence of fecal drainage often is preceded by obvious evidence of severe infection in the superficial layer of the wound. Subsequently, in all probability, a subfascial abscess forms which ruptures into the bowel through the suture line and externally to form a fecal fistula. That infection plays an important rôle in the formation of such fistulae is evidenced by the results of this study. In those cases in which infection was largely controlled through the use of combined succinylsulfathiazole and sulfathiazole therapy resumption of fecal drainage from the wound occurred in only two cases out of 102.*

Reports concerning the sensitivity of patients to succinylsulfathiazole are rare. It seldom produces an untoward reaction and it is one of the most innocuous of the sulfonamide drugs. In cases in which the drug is administered as it was in the cases in Group I, 5 to 15 Gm. of the drug probably was present in the intestine at the time of operation. Part of this is absorbed into the blood stream as sulfathiazole. In addition to this amount of succinylsulfathiazole, the tissues also contain the 5 Gm. of sulfathiazole that was applied locally. In cases

* In one of these cases unsuspected phlegmonous induration and edema were encountered at operation. The intestinal sutures did not hold and a fecal fistula resulted. The second failure is unexplained.

in which the patients are sensitive to sulfathiazole, one might expect a toxic reaction under these circumstances. These drugs are absorbed into the blood stream very slowly from their respective sites. In 15 of the cases in Group I the concentration of sulfathiazole in the blood was determined repeatedly for the first seven days after operation. In only one instance was the concentration of the drug greater than 1.5 mg. per 100 cc. of blood. In one case a value for sulfathiazole of 5.2 mg. per 100 cc. of blood was obtained 48 hours postoperatively.

A toxic reaction occurred in only two of the 50 cases in Group I. In both of these cases the reaction occurred on the fifth day after operation. In each instance, the reaction consisted of an erythematous, urticaria-like eruption on the face, hands and lower part of the legs, edema of the affected parts, puffiness of the eyelids, severe pruritus, and increase of the temperature to 101° F. The skin lesions, pruritus and fever subsided completely by the thirteenth day after operation. The blood count was not altered in either case and no other toxic manifestations were observed. It is impossible to say whether these reactions were due to sulfathiazole or to succinylsulfathiazole.

Certain parts of the preoperative treatment previously described deserve further consideration. It would seem unwise to discontinue the administration of succinylsulfathiazole for any appreciable time before operation is performed. After the administration of the drug is discontinued, the number of bacteria in the intestine rapidly returns to its previously high level; therefore, in the cases in Group I, the administration of this drug was continued up to four or six hours before the scheduled surgical intervention in order to obtain the maximal effect of the drug at the time of operation. If it were essential for the number of coliform bacteria to be at an absolute minimum at the time of operation, it would be necessary to alter this program. Considerable variation apparently exists in the response of different patients to succinylsulfathiazole.⁶ Thus, in some cases it is necessary to administer the drug in large doses for from five to seven days before the maximal effect on bacterial growth in the colon is obtained. Ideally, then, one probably should culture the stools daily and defer operation until such time as the results of bacteriologic tests would indicate. At the present, however, such a procedure has not seemed advisable to us and for practical purposes the plan herein outlined, in which the drug is given for three full days and its administration continued up to within six hours of the time of operation, would appear to be satisfactory.

The combined use of succinylsulfathiazole and sulfathiazole does not eliminate the necessity of exercising good surgical judgment in selecting the time for closure of the stoma. If the spur has not been adequately crushed or is thick and edematous and surrounded by a phlegmonous induration, the results still are likely to be unsatisfactory regardless of how intensively the sulfonamide drugs are used.

Finally, the adjunctive treatment would seem to be important. Irrigations to free the bowel of impacted fecal material are always used. After the bowel is emptied satisfactorily the irrigations are discontinued so that, for at least 24

hours before operation, the intestine is put at rest and all fecal material which comes down to the stoma is well mixed with succinylsulfathiazole. Probably all of the following play important parts: (1) The nonresidue diet, which reduces the bulk of the stool and in itself alters the bacterial flora favorably; (2) aspiration to empty the intestine as much as possible; and (3) administration of camphorated tincture of opium to decrease peristaltic activity during the operative procedure.

SUMMARY

The oral administration of succinylsulfathiazole and the local application of sulfathiazole to the operative wound have greatly improved the results which we have obtained in closure of colonic stomas. Infection of the operative wounds occurred in 84 per cent and a fecal fistula developed in 30 per cent of a series of 102 cases in which no sulfonamide drug was employed, whereas, infection of the wounds occurred in only 13 per cent and a fecal fistula occurred in only two per cent of 102 cases in which a combination of succinylsulfathiazole and sulfathiazole was administered. These improvements in the results are, in a large part, attributable to the new chemotherapeutic agent succinylsulfathiazole and they indicate in general the usefulness of this drug in the management of surgical diseases of the lower intestinal tract.

For their not inconsiderable part in working out this program and help in carrying out the many details, we wish to express our appreciation to Doctor Bergen, and his associates, in the Division of Medicine at the Mayo Clinic.

REFERENCES

- ¹ Miller, Ellis, Rock, H. J., and Moore, M. L.: Substituted Sulfanilamides: I. N⁴-acyl Derivatives. *J. Am. Chem. Soc.*, **61**, 1198-1200, May, 1939.
- ² Moore, M. L., and Miller C. S.: Dicarboxylic Acid Derivatives of Sulfonamides. *J. Am. Chem. Soc.*, **64**, 1572-1576, July, 1942.
- ³ Moore, M. L., Miller, C. S., and Miller, E.: Substituted Sulfanilamides: N⁴-acyl-N¹-hydroxy Derivatives. *J. Am. Chem. Soc.*, **62**, 2097-2099, August, 1940.
- ⁴ Poth, E. J., and Knotts, F. L.: Clinical Use of Succinylsulfathiazole. *Arch. Surg.*, **44**, 208-222, February, 1942.
- ⁵ Poth, E. J., Knotts, F. L., Lee, J. T., and Inui, Frank: Bacteriostatic Properties of Sulfanilamide and some of its Derivatives. I. Succinylsulfathiazole: A New Chemotherapeutic Agent Locally Active in the Gastro-intestinal Tract. *Arch. Surg.*, **44**, 187-207, February, 1942.
- ⁶ Welch, A. D., Mattis, P. A., and Latven, A. R.: A Toxicological Study of Succinyl Sulfathiazole. *J. Pharmacol. & Exper. Therap.*, **75**, 231-246, July, 1942.