

Diagnosis of subclinical rickets

JOHN M PETTIFOR, JOY M ISDALE, JACQUES SAHAKIAN, AND JOHN D L HANSEN

Metabolic and Nutrition Research Unit, Department of Paediatrics, and Department of Radiology, University of the Witwatersrand, Johannesburg

SUMMARY 44 randomly selected infants under age one year with suspected lower respiratory infections were investigated for the presence of subclinical rickets. Seven infants had metaphyseal changes at the wrist compatible with a diagnosis of rickets and all of these infants had 25-hydroxy-vitamin D (25-OHD) concentrations <12 ng/ml. Serum calcium and phosphorus concentrations were normal in all 44 children. Alkaline phosphatase concentrations did not correlate with the presence of metaphyseal changes. The clinical presence of craniotabes or splaying and loss of definition of the anterior ends of the ribs on x-rays did not correlate with metaphyseal changes at the wrist or with 25-OHD concentrations. An x-ray of the wrist is essential to confirm the presence of subclinical rickets and the at-risk infant can be detected by measuring serum 25-OHD concentrations.

Subclinical vitamin D deficiency rickets is often difficult to diagnose.¹ A raised alkaline phosphatase concentration (a frequently used biochemical indicator)¹⁻² is not necessarily diagnostic.³⁻⁴ Radiological changes are often difficult to detect;⁵ nevertheless the criterion used by Richards *et al.*⁵ for the diagnosis of minimal active rickets is a loss of definition of metaphyseal lines of the radius and ulna. More recently, serum 25-hydroxy-vitamin D (25-OHD) concentrations were used to assess the vitamin D status of a patient.⁶ The present study was undertaken to assess the various methods of detecting subclinical rickets.

Methods

44 randomly selected infants under age one year, referred from the outpatient department for chest x-rays because of suspected lower respiratory tract infections, were studied. X-rays of the chest (antero-posterior and lateral views) and of both wrists were obtained. Serum calcium, phosphorus, alkaline phosphatase, and 25-OHD concentrations⁷ were measured in each infant, who was also examined for clinical evidence of rickets. Informed consent was obtained from the parents of the children before the study was undertaken.

The x-rays of the chest and wrist were assessed by one of us (J M I) for the presence of rickets when the study had been completed, without knowing the results of the clinical examination or those of the biochemical investigations. The anterior ribs were assessed for the presence of splaying and cupping,⁸ the distal metaphyses of the radius and ulna for loss

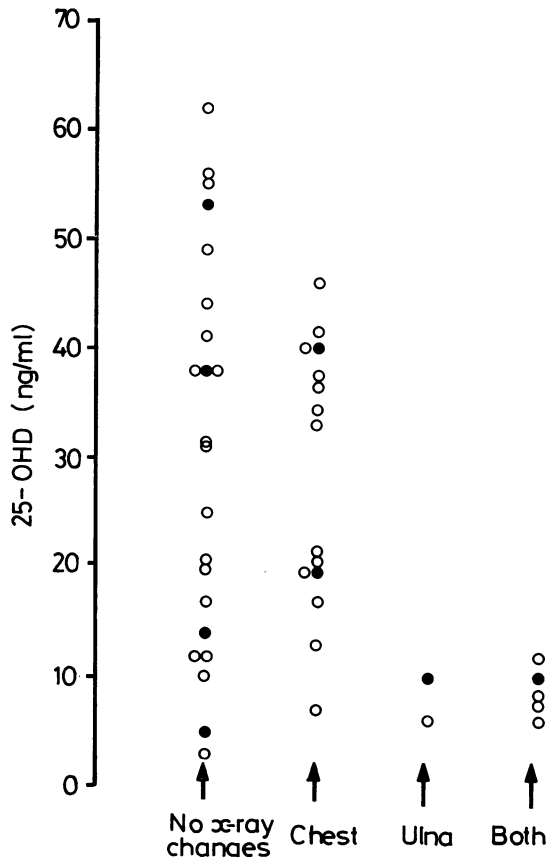


Fig. 1 Correlation between x-ray changes and 25-hydroxy-vitamin D concentrations. ● Infants with craniotabes. 'Both' refers to those infants with both ulna and rib changes suggestive of rickets. Conversion: traditional units to SI—serum 25-OHD: 1 ng/ml \approx 2.5 nmol/l.

of metaphyseal definition,⁵ and the scapula for signs of rickets.⁹

Results

44 infants (15 girls, 29 boys) were examined during a 10-month period between July 1977 and April 1978. The mean age was $7.0 \pm \text{SD } 2.8$ months. Clinically none of the infants had gross signs of rickets, although 8 had mild craniotabes. Seven of these 8 children were less than age 6 months.

Radiologically (Fig. 1), 7 infants had mild metaphyseal changes at the wrist compatible with the diagnosis of rickets. Five of these infants also had apparent splaying and loss of definition of the anterior ends of the ribs. 15 children had changes only at the ends of the ribs, while 22 infants had normal chest and wrist *x*-rays (Fig. 1). Scapular

changes were not found. There was no correlation between the presence of craniotabes and abnormal *x*-ray signs ($\chi^2 = 0.39$, $P > 0.50$). Six of the 7 infants with wrist changes presented during the winter and spring months of July to November (Fig. 2), but no seasonal variation was noted in the prevalence of radiological rib abnormalities.

Serum calcium and phosphorus concentrations were normal in all infants: calcium 9.90 ± 0.49 mg/100 ml (mean \pm SD) (2.48 ± 0.12 mmol/l), phosphorus 5.77 ± 0.74 mg/100 ml (1.90 ± 0.24 mmol/l). The 7 infants with *x*-ray changes at the wrist had mean serum calcium and phosphorus concentrations (9.74 mg/100 ml; 2.44 mmol/l and 5.59 mg/100 ml; 1.84 mmol/l) which did not differ significantly from the means for the whole group. Seven of the 44 children had serum alkaline phosphatase concentrations >300 IU/l, however only two of these had wrist changes.

25-OHD concentrations were noted to have a striking seasonal variation (Fig. 2). The mean value for the summer and early autumn period December to April was 36.2 ± 14.3 ng/ml (90.5 ± 35.75 nmol/l) and was more than twice that for the winter and spring months July to November, 14.6 ± 9.9 ng/ml (36.5 ± 24.75 nmol/l) ($t = 5.72$, $P < 0.0005$). There was no correlation between 25-OHD concentrations and serum calcium ($r = 0.03$) or alkaline phosphatase values ($r = 0.03$). The mean 25-OHD concentration was significantly lower in those children with *x*-ray changes at the wrist (8.4 ng/ml; 21.0 nmol/l), than in either those with changes only at the ends of the ribs (28.5 ng/ml; 71.25 nmol/l) ($t = 4.24$, $P = < 0.0005$) or those with no *x*-ray abnormalities (30.6 ng/ml; 76.5 nmol/l) ($t = 3.18$, $P < 0.0025$). All infants with wrist changes had serum 25-OHD concentrations of 12 ng/ml or less. The presence of craniotabes did not correlate with the vitamin D status of the child, or with radiographical abnormalities.

Discussion

Seven of the 44 infants who were examined radiologically had changes at the distal ulna metaphyses compatible with the diagnosis of rickets.⁸ It could be argued that these changes were not due to rickets as biochemically these infants did not differ from children with normal *x*-rays. Other evidence however supports the diagnosis of rickets. Firstly, 6 of the 7 infants were seen in the winter and early spring months, when exposure to sunlight is likely to be minimal as the temperature is low. Secondly, those infants with wrist changes had significantly lower 25-OHD concentrations than the infants with no

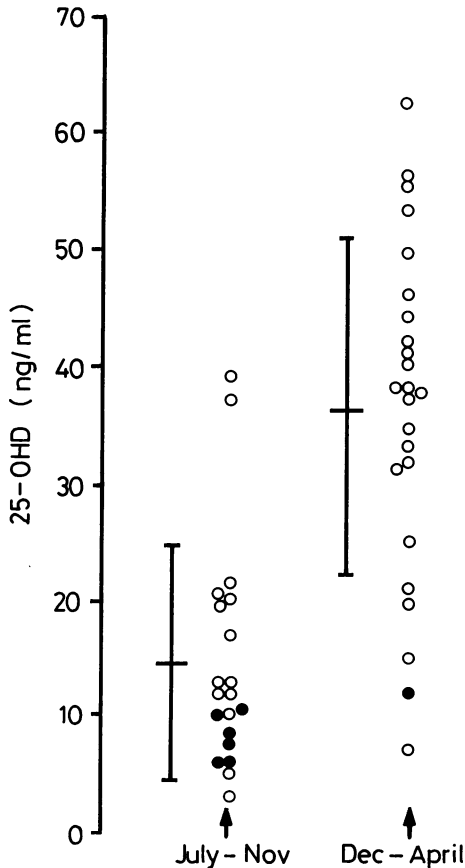


Fig. 2 Seasonal variation in 25-hydroxy-vitamin D concentrations. Mean and SD are drawn for each period. ● Infants with ulna alone or ulna and rib changes.

x-ray abnormalities. Both of these facts are strong evidence for the assumption that the x-ray changes at the wrist are due to vitamin D deficiency. A correlation between metaphyseal changes and 25-OHD concentrations has previously been documented by Goel *et al.*³ who also showed that the loss of definition at the metaphysis could be corrected by treatment with vitamin D. This latter finding could not be confirmed in our group of patients as we were unable to reassess the infants after a period of treatment with vitamin D.

It is apparent from this study that the estimation of serum calcium, phosphorus, and alkaline phosphatase concentrations is of little value in the diagnosis of subclinical rickets in infants, thus confirming earlier reports.¹⁻² Radiographically, splaying of the end of the ribs also does not appear to be a useful sign, as infants with rib abnormalities alone had similar 25-OHD concentrations as those with no x-ray changes. The only useful x-ray sign is the loss of definition of the ulna metaphysis at the wrist⁵ and this correlates well with the vitamin D status of the infant as assessed by serum 25-OHD concentrations.³ Although no particular value of 25-OHD concentration can be equated with the presence of rickets, a low 25-OHD concentration is indicative of vitamin D deficiency and thus of the infant at risk from developing subclinical and then clinical rickets.

Of interest is the lack of correlation between the presence of craniotabes and any other sign of subclinical rickets. Park¹⁰ suggested that craniotabes is the earliest sign to develop in infantile rickets, however he did state that it is not pathognomonic. The results of the current study indicate that minor radiographical changes occur at the wrist before craniotabes develops, and that craniotabes occurs in a number of infants with no x-ray evidence of rickets and normal serum 25-OHD concentrations.

In conclusion, therefore, the results of this study indicate that the estimation of serum calcium, phosphorus, and alkaline phosphatase concentra-

tions is of little value in the screening of infants for subclinical rickets, and that splaying or cupping of the anterior ribs on x-rays of the chest is not diagnostic. An x-ray of the wrist is essential to confirm the presence of subclinical rickets, while the at-risk infant can be detected by measuring serum 25-OHD concentrations.

We thank Dr R Drubin, superintendent of the Transvaal Memorial Hospital for Children, for permission to publish details of these cases, and the Medical Research Council of South Africa, and the Atomic Energy Board for financial assistance.

References

- 1 Editorial: Diagnosis of nutritional rickets. *Lancet* 1971; **2**: 28-9.
- 2 Preece M A, Ford J A, McIntosh W B, Dunnigan M G, Tomlinson S, O'Riordan J I H. Vitamin D deficiency among Asian immigrants to Britain. *Lancet* 1973; **1**: 907-10.
- 3 Goel K M, Sweet E M, Logan R W, Warren J M, Arneil G C, Shanks R A. Florid and subclinical rickets among immigrant children in Glasgow. *Lancet* 1976; **1**: 1141-5.
- 4 Salimpour R. Rickets in Tehran. *Arch Dis Child* 1975; **50**: 63-6.
- 5 Richards I D G, Sweet E M, Arneil G C. Infantile rickets persists in Glasgow. *Lancet* 1968; **1**: 803-5.
- 6 Mawer E B, Backhouse J, Hill L F, *et al.* Vitamin D metabolism and parathyroid function in man. *Clin Sci Mol Med* 1975; **48**: 349-65.
- 7 Pettifor J M, Ross F P, Wang, J, Moodley G P, Couper-Smith J. Rickets in children of rural origin in South Africa: is low dietary calcium a factor? *J Pediatr* 1978; **92**: 320-4.
- 8 Caffey J. *Pediatric x-ray diagnosis*. 6th ed. Chicago: Yearbook Medical Publishers, 1973: 1222.
- 9 Weiss A. The scapular sign in rickets. *Radiology* 1971; **98**: 633-6.
- 10 Park E A. Vitamin D and rickets. In: Jolliffe N, ed. *Clinical nutrition*. 2nd ed., chapter 14. New York: Harper, 1962: 506.

Correspondence to Dr J M Pettifor, Metabolic and Nutrition Research Unit, Department of Paediatrics, Baragwanath Hospital, PO Bertsham, Johannesburg 2013, Republic of South Africa.