

Micro-organisms in outpatient infantile gastroenteritis

A M WEINDLING, J A WALKER-SMITH, AND R BIRD

Queen Elizabeth Hospital for Children, London, and Electron Microscopy Unit, London School of Hygiene and Tropical Medicine

SUMMARY This study reports the results of an examination of the stools of 58 infants with gastroenteritis who were seen as outpatients. The stools were examined by routine bacterial culture, and by electron microscopy for virus particles. The stools of a comparable control group of infants who had no gastrointestinal symptoms were also similarly examined. Enteropathogenic *Escherichia coli*, *Salmonella* sp., and rotaviruses, as well as other viruses, particularly adenoviruses and coronaviruses, were isolated.

Since the rotavirus was identified as an important aetiological agent in children with acute gastroenteritis,¹ there has been renewed interest in the aetiology of this common illness and several reports of studies have been published. These studies¹⁻² were concerned with the identification of aetiological agents in children ill enough to warrant admission to hospital. However, the present study attempted to determine the micro-organisms in the stools of outpatients attending the casualty department of a children's hospital using both bacterial culture and electron microscopy (EM).

Patients and methods

Single stool specimens from 88 children who were brought to the casualty department of the Queen Elizabeth Hospital for Children between August and November 1977 were examined by routine bacteriological methods in the hospital laboratory, and by EM at the London School of Hygiene and Tropical Medicine. No attempts were made to culture viruses or to obtain sera from the children. All patients were aged less than 18 months and came from the surrounding area.

58 children were suffering from acute diarrhoea and vomiting, diagnosed as acute gastroenteritis. The clinical features of this group were compared with those of 30 children who had no gastrointestinal disturbance, and in all cases were recorded prospectively. Each child was examined by the

doctor conducting this study within 48 hours of initial presentation.

Management of gastroenteritis was by a standard regimen³ of electrolyte mixture to which sugar was added by the parents, or by the use of clear fluids in the case of toddlers, with gradual regrading to a normal diet over 3-5 days.

Results

Gastroenteritis group.

Age, sex, and ethnic origins of the children

58 children were found to be suffering from acute gastroenteritis: 41 (71%) boys and 17 (29%) girls. Most of these children were below age 6 months, but only 3 were under 4 weeks. Age and sex distributions are shown in Table 1. The ethnic origins of these children are shown in Table 2.

Table 1 *Ages and sexes of children with acute gastroenteritis*

	Months		
	<6	6-12	13-18
Boys	27 (47)	12 (21)	2 (3.5)
Girls	15 (26)	2 (3.5)	0

Percentages are given in parentheses.

Table 2 *Ethnic origins of children with acute gastroenteritis*

	White n=36 (62)	Asian n=11 (19)	Black n=7 (12)	Mixed race n=4 (7)
Boys	23 (40)	8 (14)	7 (12)	3 (5)
Girls	13 (22)	3 (5)	0	1 (2)

Percentages are given in parentheses.

Department of Paediatrics, Royal Berkshire Hospital, Reading
A M WEINDLING, registrar
Queen Elizabeth Hospital for Children, London
J A WALKER-SMITH, consultant senior lecturer
Electron Microscopy Unit, London School of Hygiene and Tropical Medicine
R BIRD, director

Micro-organisms indentified and clinical features

Bacterial pathogens. Faeces from 54 of these 58 children were examined using routine bacteriological methods, and bacterial pathogens were isolated from the stools of 8 (14%). Known serotypes of enteropathogenic *E. coli* were isolated from the stools of 6 patients, and *Salmonella* sp. was identified in 2 cases. The stools of 2 children with enteropathogenic *E. coli* also contained myxovirus-like and 20–30 nm particles, considered to be enteroviruses. Another child with enteropathogenic *E. coli* also had a rotavirus in his stool and was admitted to hospital.

Stool virus particles. Rotavirus particles (Fig. 1) were identified in the stools of 4 (7%) children, all aged 6 months or less. Boys and girls were equally represented. The illness in the case of 3 of these children settled at once with routine treatment, but the fourth, aged 2 months, with *E. coli* O128 was admitted for 8 days.

An adenovirus (Fig. 2) was identified in the stool of 2 children; one aged 13 months had an associated slight upper respiratory tract infection (URTI), the other had not. The conditions of both patients settled quickly after treatment with clear fluids.

Particles 20–30 nm in size (enterovirus size) (Fig. 3) were identified in the stools of 3 children with diarrhoea but no vomiting. All were mildly pyrexial; the youngest was exclusively breast fed and had additional signs of an URTI. Neither of the other 2 had any upper respiratory disturbance. One of these 2 had been in contact with a child whose entire family had had diarrhoea; he eventually required

admission, although no bacteria and no virions were found in the stool of the contact, who also needed to be admitted.

Myxovirus-like particles alone (Fig. 4) were identified in 5 patients with gastroenteritis. Their ages ranged from 2 weeks to 10 months. Four suffered from vomiting as well as diarrhoea, and the gastrointestinal disturbance had been present for between one and 3 weeks. In one case, regrading had been attempted at another hospital, but this had failed and the child was admitted. The fifth child was breast fed and had a much less severe illness. Two of these 5 children were pyrexial with additional signs of an URTI.

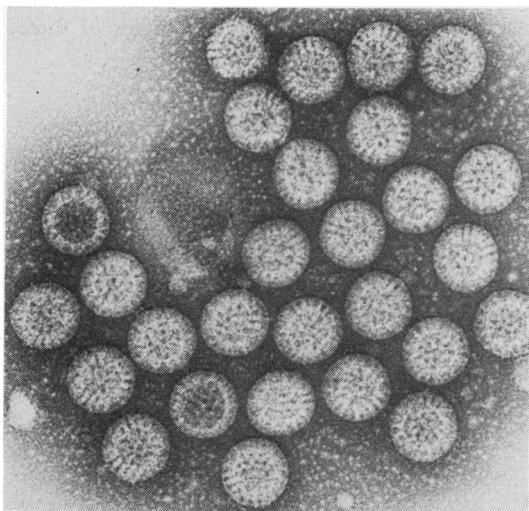


Fig. 1 Rotavirus, $\times 126\ 000$.

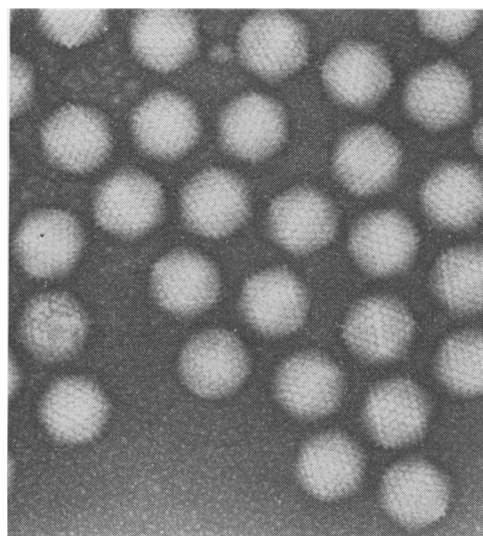


Fig. 2 Adenovirus, $\times 126\ 000$.

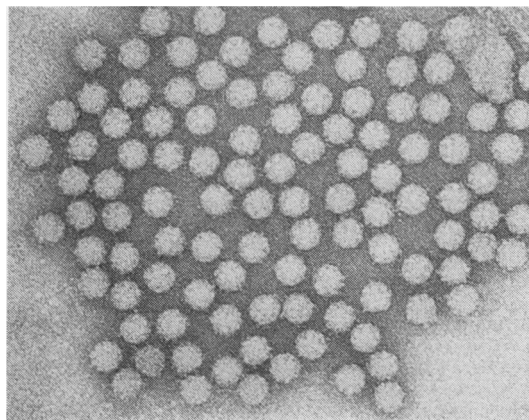


Fig. 3 20–30 nm particles, $\times 126\ 000$.

Both myxovirus-like and enterovirus particles were found simultaneously in the stools in 5 patients; *E. coli* was also isolated from 2 of these. Diarrhoea lasting from 5 days to a week was the main feature. Only one of these (a boy from whose stool *E. coli* was also isolated) was pyrexial and had a pronounced associated URTI.

Coronavirus (Fig. 5) was observed in the stool of a boy aged 9 months. He was pyrexial and there was no associated URTI. He had a colostomy because of Hirschsprung's disease. The colostomy actions had been frequent and watery for 3 days, and the colostomy had prolapsed. He had vomited but only on the first day of the illness. The loose colostomy

actions gradually settled with clear fluids, although admission was required.

The presence of coronavirus particles was suspected in 2 other children. Diarrhoea and vomiting were fairly severe in both, lasting for 5-6 days. One of these children had an URTI in addition, and in his case there were particles resembling both coronavirus and herpesvirus.

Candida. *Candida* sp., but no bacteria or viruses, was isolated from the stools of 2 children. Both were boys aged under one year. One had a strong history of contact with diarrhoea. Neither had any clinical evidence of candidiasis. The diarrhoea settled promptly with electrolyte mixture in both cases.

Hospital admissions

Six (11%) of the children in this group were admitted. One was admitted because of bloody diarrhoea (*Salmonella agona* was subsequently isolated), and 2 others were admitted because of prolonged diarrhoea. They had been in close contact with each other, and an enterovirus (see above) was isolated from the stool of one. Rotavirus was found in one of the others, and coronavirus was isolated from the colostomy actions of another. Two children were admitted for social reasons. None required intravenous fluids.

Infant feeding

The majority of babies were either artificially fed or on mixed feeding. Of the 3 babies who were exclusively breast fed, particles suspected of being myxoviruses were seen in the stool of one, and 20-30 nm particles, thought to be an enterovirus, were seen in the stool of another; no virions were suspected in the third.

Control group.

30 children with no gastrointestinal disturbances were seen during the same period by the same observer. Twice as many boys were seen as girls. The most common diagnoses were 'normal infant' in 20%, and 'feeding problem' in 17%; other presenting complaints varied from squints and asthma to minor trauma. Only one child was aged below 4 weeks. Distribution of age, sex, and ethnic origins are summarised in Tables 3 and 4.

Particles judged to be enteroviruses were seen in the stools of 4. Two had signs of an URTI and one had pronounced expiratory wheezing. The fourth had been screaming intermittently, and was found to be a windy baby.

Myxovirus-like particles were found in 4: two children were off their food but displayed no

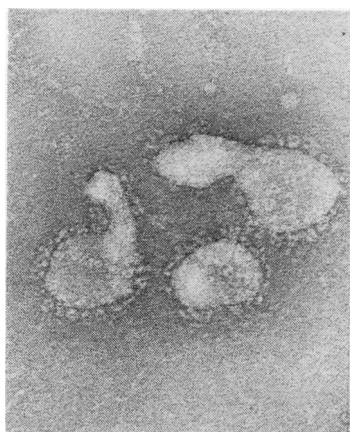


Fig. 4 Myxovirus-like particles, $\times 126\ 000$.

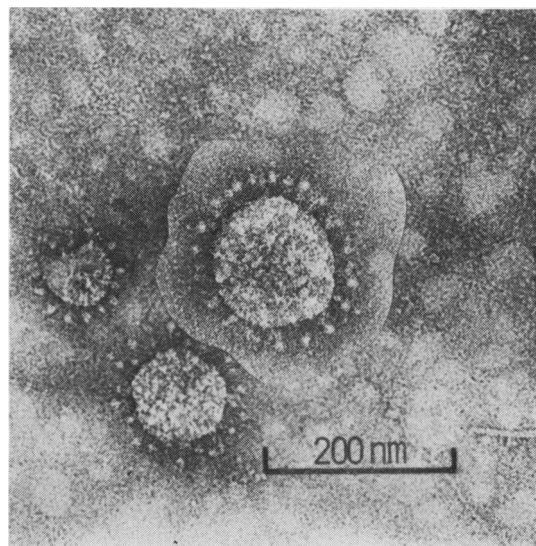


Fig. 5 Coronavirus, $\times 126\ 000$.

Table 3 *Ages and sexes of children in control group*

	Months		
	<6	6-12	13-18
Boys	14 (46)	3 (10)	3 (10)
Girls	5 (17)	2 (7)	3 (10)

Percentages are given in parentheses.

Table 4 *Ethnic origins of children in control group*

	White n=20 (66)	Asian n=5 (17)	Black n=5 (17)	Mixed race
Boys	12 (40)	4 (13)	4 (13)	0
Girls	8 (26)	1 (4)	1 (4)	0

Percentages are given in parentheses.

abnormal physical signs, one had a pronounced URTI, and the loud screaming of the fourth child settled after feeding.

Discussion

It is noteworthy that in Autumn 1977, despite EM, no pathogens were isolated or virions identified in the stools of half the children with clinical gastroenteritis observed as outpatients. Bacteria were absent from the stools of the control group, and no virions were seen in 74% of the stools of this group.

Rotavirus was only found in 4 (7%) cases of the gastroenteritis group, no doubt due to this study being undertaken before the winter peak;⁴ this compares with a previous estimate of an incidence of about 20% during the rest of the year.⁵ There were no rotaviruses among the controls, although Murphy *et al.*⁶ found a high incidence among certain populations of asymptomatic neonates.

Neither adenovirus nor coronavirus was isolated from any child who did not have a gastrointestinal disturbance. Adenoviruses have been previously found in cases of acute diarrhoea.⁶ Coronavirus has been implicated in human gastroenteritis on only 3 previous occasions;⁷ vomiting has hitherto been described as a principal feature,⁸ but was not pronounced in our patients.

The finding of *Candida* sp. in the stools of 2 children with diarrhoea is interesting in view of the previously recognised increased numbers of normal bowel flora, particularly of *C. albicans*, present in the upper small intestine of adults and children with diarrhoea.⁹

Enterovirus and myxovirus-like particles were found in the stools of both groups. The significance of this finding is not clear.

These results are summarised in Table 5 and our findings are compared with those of a previous inpatient study undertaken during the same months in 1976 at the Queen Elizabeth Hospital for Children (W Cutting, 1978, unpublished observations).

Table 5 *Summary of micro-organisms found in stools of control group and gastroenteritis groups (%)*

	Controls	Gastroenteritis groups	
		Outpatients	Inpatients
Particles 20-30 nm	13	5	10
Myxovirus (alone)	13	9	17
Rotavirus	0	7	12
Myxovirus + particles			
20-30 nm	0	9	3
Coronavirus	0	2	2
?Herpes-?coronavirus	0	3.5	0
Adenovirus	0	3.5	4
Bacteria	0	18	25
<i>E. coli</i>	0	11	—
<i>Shigella</i> sp.	0	0	—
<i>Salmonella</i> sp.	0	3.5	—
<i>C. albicans</i>	0	3.5	—
Unknown	N/A	52	27

N/A = not applicable, — figures not available.

This study shows the need for further surveys of the pattern of excretion of stool viruses by children who have acute gastrointestinal symptoms, but who are not necessarily ill enough to need admission to hospital.

We thank the staff of the Microbiology and Casualty Departments, Queen Elizabeth Hospital for Children, for their assistance.

References

- Gribbin M, Walker-Smith J, Wood C. A twelve month prospective survey of admissions to the gastroenteritis unit of a children's hospital. *Acta Paediatr Belg* 1976; **29**: 69-77.
- Flewett T H, Bryden A S, Davies H, Morris C A. Epidemic viral enteritis in a long-stay children's ward. *Lancet* 1975; **1**: 4-5.
- Walker-Smith J A. *Diseases of the small intestine in childhood*. Tunbridge Wells: Pitman Medical, 1975; 141-2.
- Davidson G P, Bishop R F, Townley R R W, Holmes I W, Ruck B J. Importance of a new virus in acute sporadic enteritis in children. *Lancet* 1975; **1**: 242-6.
- Walker-Smith J A. Rotavirus gastroenteritis. *Arch Dis Child* 1978; **53**: 355-62.
- Murphy A M, Albrecht M B, Crewe E B. Rotavirus infections of neonates. *Lancet* 1977; **2**: 1149-50.
- Caul E O, Clarke S K R. Coronavirus propagated from patient with non-bacterial gastroenteritis. *Lancet* 1975; **2**: 953-4.
- Caul E O, Paver W K, Clarke S K R. Letter: Coronavirus particles in faeces from patients with gastroenteritis. *Lancet* 1975; **1**: 1192.
- Bishop R F, Barnes G L, Townley R R W. Microbial flora of stomach and small intestine in infantile gastroenteritis. *Acta Paediatr Scand* 1974; **63**: 418-22.

Correspondence to Dr J A Walker-Smith, Queen Elizabeth Hospital for Children, Hackney Road, London E2 8PS.

Received 10 April 1979