

Therapeutic Monitoring of Experimental Invasive Pulmonary Aspergillosis by Ultrafast Computerized Tomography, a Novel, Noninvasive Method for Measuring Responses to Antifungal Therapy

THOMAS J. WALSH,^{1*} KELSEY GARRETT,¹ ERWIN FEUERSTEIN,² MARY GIRTON,²
MARÍA ALLENDE,¹ JOHN BACHER,³ ANDREA FRANCESCONI,¹ ROBERT SCHAUFLE,¹
AND PHILIP A. PIZZO¹

Infectious Diseases Section, National Cancer Institute,¹ Department of Radiology, Warren Grant Magnuson Clinical Center, National Institutes of Health,² and Surgery Branch, Veterinary Resources Program, National Center for Research Resources,³ Bethesda, Maryland 20892

Received 8 July 1994/Returned for modification 25 February 1995/Accepted 28 February 1995

Pulmonary infiltrates in neutropenic hosts with invasive aspergillosis are due to vascular invasion and hemorrhagic infarction. In order to measure the effect of antifungal compounds on this organism-mediated tissue injury, we monitored the course of pulmonary infiltrates by serial ultrafast computerized tomography (UFCT) in persistently granulocytopenic rabbits with experimental invasive pulmonary aspergillosis. The course of pulmonary lesions measured by serial UFCT scans was compared with those measured by conventional chest radiography, histopathological resolution of lesions, and microbiological clearance of *Aspergillus fumigatus*. Treatment groups included either amphotericin B colloidal dispersion in dosages of 1, 5, and 10 mg/kg of body weight per day intravenously or conventional desoxycholate amphotericin B at 1 mg/kg/day intravenously. Therapeutic monitoring of pulmonary lesions by UFCT demonstrated a significant dose-response relationship. Lesions continued to progress in untreated controls, whereas lesions in treated rabbits initially increased and then decreased in response to antifungal therapy in a dosage-dependent manner ($P \leq 0.05$ to $P \leq 0.005$, depending upon the groups compared). This same trend of resolution of lesions in response to antifungal therapy was also demonstrated by postmortem examination and by microbiological clearance of the organism. These data indicated that amphotericin B colloidal dispersion at 5 and 10 mg/kg/day exerted a more rapid rate of clearance of lesions than conventional amphotericin B. UFCT was more sensitive than conventional chest radiography in detecting lesions due to invasive pulmonary aspergillosis ($P < 0.05$ to $P < 0.005$, depending upon the groups compared). These findings establish a correlation among UFCT-defined lesions, microbiological response, and resolution of pathologically defined lesions in experimental invasive pulmonary aspergillosis. Serial monitoring of UFCT-defined lesions of aspergillosis provides a novel system for determining the antifungal response of organism-mediated tissue injury.

Invasive pulmonary aspergillosis is an important cause of morbidity and mortality in patients with profound neutropenia (4, 13, 25, 28, 34). Vascular invasion and hemorrhagic infarction are critical factors in development of pulmonary injury due to invasive aspergillosis, particularly in neutropenic hosts. The tissue injury due to invasive aspergillosis is detectable as pulmonary infiltrates by conventional chest radiography and computerized tomography (CT).

The role of CT scans for early detection of invasive pulmonary aspergillosis has been described for neutropenic patients (17-19). The recently introduced technology of ultrafast CT (UFCT) provides rapid scanning with sensitivity equivalent to that of conventional CT scanning and greater than that of conventional chest radiography (5-7, 12, 20, 23, 26, 27, 32).

Therapeutic monitoring of pulmonary infiltrates, after initiation of antifungal therapy, has been utilized as a clinically useful tool with neutropenic patients with invasive pulmonary aspergillosis (8, 17-19). Similarly, monitoring the resolution of pulmonary infiltrates in experimental animal models of invasive aspergillosis or other pulmonary mycoses may be a useful

tool for measuring the in vivo activity of different antifungal compounds and dosage regimens. However, there are no reports to our knowledge investigating the role of CT and antifungal responses in experimental pulmonary infections, nor are there any reported findings correlating the microbiological and histological resolution of experimental invasive pulmonary aspergillosis with radiological resolution by CT. Monitoring of CT-defined lesions of aspergillosis may provide a novel system for determining antifungal responses of organism-mediated tissue injury. Furthermore, understanding the correlation among CT-defined lesions, microbiological response, and resolution of pathologically defined lesions would establish a firmer scientific foundation for clinical application. The speed of UFCT is particularly applicable for studying laboratory animals by reducing the scanning time and the duration of general anesthesia.

Several lipid formulations of amphotericin B have been developed (1-3, 9-11, 15, 16, 21, 22, 30, 31). However, little is known about the dose-response relationships of these compounds against invasive pulmonary aspergillosis. We therefore used UFCT to study the comparative responses of conventional amphotericin B and different dosages of a lipid formulation of amphotericin B in experimental pulmonary aspergillosis and further compared these responses with those by

* Corresponding author. Mailing address: Infectious Disease Section, Pediatric Branch, National Cancer Institute, Bldg. 10, Rm. 13N-240, Bethesda, MD 20892.

conventional chest radiography, pathologically defined resolution of lesions, and microbiological clearance of *Aspergillus fumigatus*.

MATERIALS AND METHODS

Animals. Twenty-five female New Zealand White rabbits weighing 2.5 to 3.5 kg were used throughout these experiments. The animals were individually housed and provided food and water ad libitum according to National Institutes of Health guidelines on the care and use of laboratory animals. Silastic venous catheters were surgically placed under sterile operative conditions for nontraumatic venous access, as previously described (35). The central venous catheter facilitated induction, maintenance, and support of persistent neutropenia in rabbits and was used for administration of general anesthesia for CT scanning.

Rabbits were transported between the laboratory animal facility and the UFCT scanner under general anesthesia. An induction dose of a 2:1 mixture (by volume) of 20 mg of ketamine (Fort Dodge Laboratories, Fort Dodge, Iowa) and 2 mg of xylazine (Animal Health Care Division, Mobay Corp., Shawnee, Kans.) was administered intravenously. General anesthesia was maintained during the procedure by an additional dose of 13 mg of ketamine and 1.3 mg of xylazine (also prepared in a 2:1 ratio). Preliminary studies demonstrated no pulmonary lesions in normal rabbits.

Immunosuppression and supportive care. Cytosine arabinoside (kindly provided by Upjohn, Kalamazoo, Mich.) was administered intravenously at 525 mg/m² on days 1 through 5 and at 484 mg/m² on days 8 and 9 to produce profound and persistent neutropenia (≤ 100 neutrophils per μ l). Methylprednisolone (Upjohn) at 5 mg/kg of body weight was administered on days 1 through 3 to inhibit macrophage activity against conidia. Rabbits were closely monitored and supported throughout neutropenia. Granulocyte counts were maintained below 500/ μ l and were usually below 100/ μ l from day 5 onward. Ceftazidime (Glaxo, Research Triangle Park, N.C. [75 mg/kg intravenously twice daily]), gentamicin (Baxter Health Care Corp., Deerfield, Ill. [5 mg/kg intravenously daily]), and vancomycin (Eli Lilly, Indianapolis, Ind. [15 mg/kg intravenously daily]) were administered from day 4 onward to prevent the emergence of opportunistic bacterial infections during neutropenia.

Preparation and administration of the *Aspergillus* inoculum. *A. fumigatus* conidia from a patient with histologically proven pulmonary aspergillosis were used in all experiments. The organism was grown on potato dextrose agar, maintained frozen at -70°C , and then thawed, subplated onto several more potato dextrose agar slants, incubated for 24 to 48 h, and kept at room temperature until used 5 days later. Under a laminar flow hood, 7 ml of 0.025% Tween-saline solution was instilled into each potato dextrose agar slant, and *A. fumigatus* conidia were harvested from the surface by gentle scraping with a transfer pipette. The suspensions of conidia were centrifuged at $3,000 \times g$ for 10 min. The conidia were counted with a hemacytometer, and an inoculum of 6.0×10^8 /ml was prepared by resuspension in 0.025% Tween-saline solution for inoculation. Each rabbit received 1.5×10^8 conidia (suspended in 250 μ l of Tween-saline) via the endotracheal route on day 2 of administration of cytosine arabinoside.

Each rabbit was anesthetized with intravenous ketamine and xylazine. Once a satisfactory level of anesthesia was reached, a laryngoscopically directed Flag 0 straight blade (Welch-Allyn, Skaneateles Falls, N.Y.) was carefully inserted until the vocal cords were clearly visualized. The *A. fumigatus* inoculum was then aspirated with a tuberculin syringe attached to a 5 $\frac{1}{4}$ -in. (13.34-cm) Teflon catheter (Becton Dickinson, Sandy, Utah), and under direct visualization, the inoculum was administered beyond the vocal cords into the trachea. Careful endotracheal intubation was ensured so that the esophagus was not inoculated. This process was repeated for each rabbit enrolled in the particular trial.

Antifungal therapy. Desoxycholate amphotericin B (DAmB) (Fungizone; Bristol Myers-Squibb, Princeton, N.J.) was reconstituted with distilled water and then diluted with 5% glucose in water to a 1-mg/ml concentration immediately prior to use. Amphotericin B colloidal dispersion (ABCD) (kindly provided by Liposome Technology, Inc., Menlo Park, Calif.) was used as an example of a lipid formulation of amphotericin B for this study. ABCD was reconstituted with sterile water to a concentration of 5 mg/ml. The vial was gently rocked until a yellow opalescent suspension without aggregates was obtained. This solution was injected directly or diluted to a 1-mg/ml solution in 5% glucose in water, depending upon the dosage and volume administered. Antifungal therapy with DAmB (1 mg/kg) or ABCD (1, 5, or 10 mg/kg/day) was initiated 24 h after inoculation at a rate of 0.4 ml/min intravenously through the central Silastic venous catheter and continued for 10 days in the surviving rabbits.

Chest radiography. All rabbits were radiographed recumbent in the left lateral and ventral-dorsal positions. Kodak film TMH-1 (Eastman Kodak Co., Rochester, N.Y.) was exposed at 70 mA, 1/50-s exposure time, 54 to 58 kVp, and $\times 2$ magnification with Kodak Lanex regular screens (Eastman Kodak) and a Machlett microfocuss X-ray tube with a 0.13-mm-diameter grid-biased focal spot (Machlett Laboratories, Inc., Stamford, Conn.). Chest radiographs and UFCT scans were performed on the same days.

CT. CT was performed with the C-100XL ultrafast electron beam CT scanner (Imatron, Oyster Point, Calif.). Rabbits were sedated and then placed prone, headfirst on the scanning couch. Scans were made in the high-resolution, table-

TABLE 1. Comparative sensitivities of detection of pulmonary aspergillosis by conventional chest radiograph and UFCT

Therapeutic group (n)	No. of lobes scanned	Diagnostic imaging method ^a	No. (%) of lobes with lesions detected
Untreated controls (9)	54	CXR* UFCT*	16 (29.6) 29 (53.7)
Treated rabbits (37)	222	CXR** UFCT**	70 (31.5) 99 (44.6)

^a CXR, conventional chest radiograph. Significance of comparisons between paired treatment groups was determined by chi-square analysis. *, $P < 0.05$; **, $P < 0.01$.

incremented, volume-acquisition mode. Three-millimeter-thick slices were made every 4 mm. A small scan circle and a 9-cm reconstruction circle with a 512 by 512 matrix were used, which resulted in a pixel size of less than 1 mm. Scan parameters were 130 kV at 630 mA, and scan duration was 100 ms. In virtually all cases, 30 slices were sufficient to scan the entire thorax of the rabbit. Images were photographed with lung windows with a level of -600 Hounsfield units (HU) and a width of 1,800 HU. Each lung was divided into three lobes (upper, middle, and lower), and each lobe was assessed to determine a pulmonary lesion score.

A mean pulmonary lesion score was established by evaluating the infiltrate in each lobe. The pulmonary lesion score in each lobe was initially 0. Each lobe was evaluated and scored independently. If the pulmonary infiltrate within the lobe demonstrated worsening, stabilization, or improvement, a score of +1, 0, or -1 , respectively, was added at that time to the previous score. The mean pulmonary lesion score for that day represents the mean of all lobes of all rabbits in each treatment group.

All chest radiographs were scored by the same three observers, who were blinded to the identity of the study group of each rabbit. All CT scans were scored by the same observer (E.F.), who was also blinded to the identity of the study group of each rabbit. A representative series of CT scans of a rabbit with invasive aspergillosis treated with ABCD is depicted in Fig. 1.

Postmortem studies. Rabbits were euthanized with intravenous pentobarbital. The heart and lungs were resected en bloc. Lung weights were obtained and recorded. Lung weights in experimental aspergillosis reflect the extent of pulmonary hemorrhage and edema related to infection. The lungs were carefully inspected for the presence of any pulmonary lesions and were specifically scored by two observers blinded to the treatment group.

Histologically, these lesions were characterized either by the presence of hyphal angioinvasion, hemorrhagic infarctions, coagulative necrosis, karyorrhexis, and few mononuclear cells or by the presence of a dense cellular infiltrate composed of fibroblasts, macrophages, mononuclear cells, and multinucleate giant cells with occasional granuloma formation. The number of lobes involved with macroscopic lesions was recorded and tabulated for each group. After tissue sectioning of the lesions, portions of each lobe were weighed and homogenized in sterile normal solution. CFU were then determined for each lobe with Sabouraud glucose agar plates incubated at 37°C for 24 h and then placed at room temperature. Colonies were counted at 48 h and recorded as CFU per gram of tissue. The number of lobes that yielded cultures positive for *A. fumigatus* was recorded.

Statistical analysis. Differences in proportions were analyzed by the chi-square test, and differences between means were measured by the unpaired Student *t* test. All analyses were two sided. A *P* value of ≤ 0.05 was considered significant.

RESULTS

Comparison between chest radiography and UFCT. Table 1 demonstrates that UFCT was more sensitive than conventional chest radiography in the detection of pulmonary aspergillosis lesions. Among untreated control rabbits, chest radiography detected lesions in 16 (29.6%) of 54 lobes, while the UFCT detected lesions in 29 (53.7%) of 54 lobes ($P < 0.05$). Among treated rabbits, the chest radiograph detected lesions in 70 (31.5%) of 222 lobes, while the UFCT detected lesions in 99 (44.6%) of 222 lobes ($P < 0.01$).

Therapeutic monitoring by UFCT. Therapeutic monitoring by UFCT pulmonary lesion scores of invasive aspergillosis demonstrated a dose-response relationship with ABCD (Fig. 2). Lesions in untreated controls continued to progress, whereas lesions in treated rabbits initially increased and then

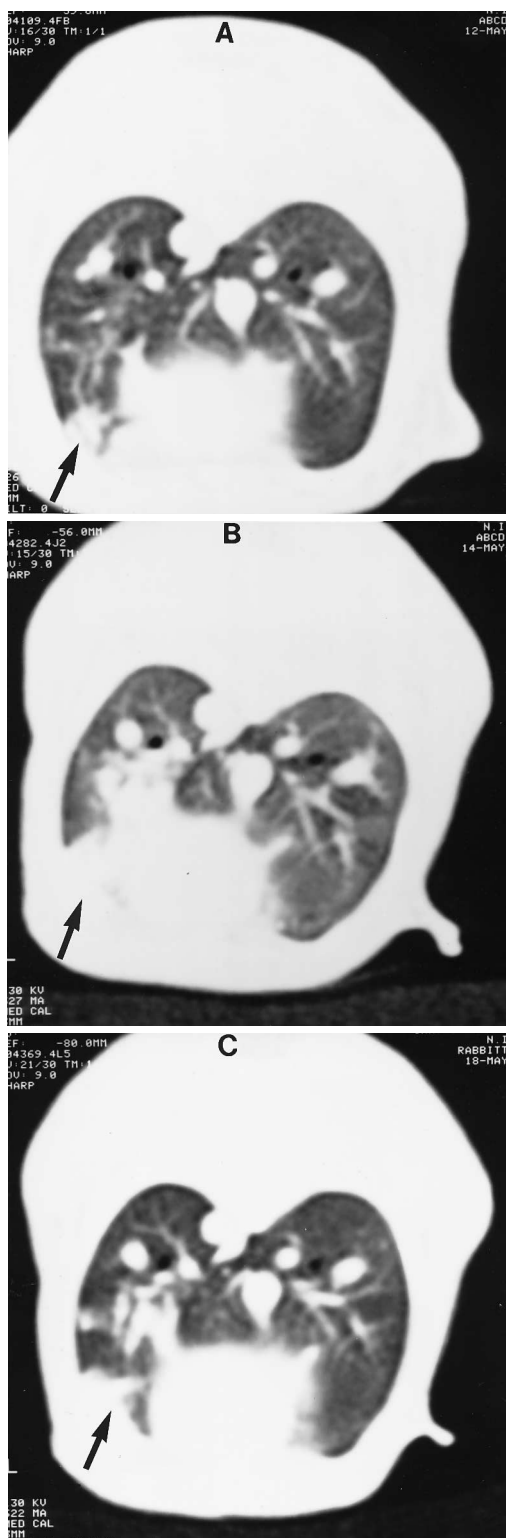


FIG. 1. Representative serial UFCT scans of a neutropenic rabbit with invasive pulmonary aspergillosis. The left lower lobe lesion (arrow) detected 1 day after intratracheal inoculation of *A. fumigatus* (A) continued to enlarge 3 days after inoculation (B) and then began to regress after 6 days of ABCD at 1 mg/kg of body weight per day and 6 days postinoculation (C). The left lower lobe is scored +1 in panel A for worsening from normal baseline, another +1 in panel B for worsening from the previous scan, and -1 in panel C for improvement from the previous scan.

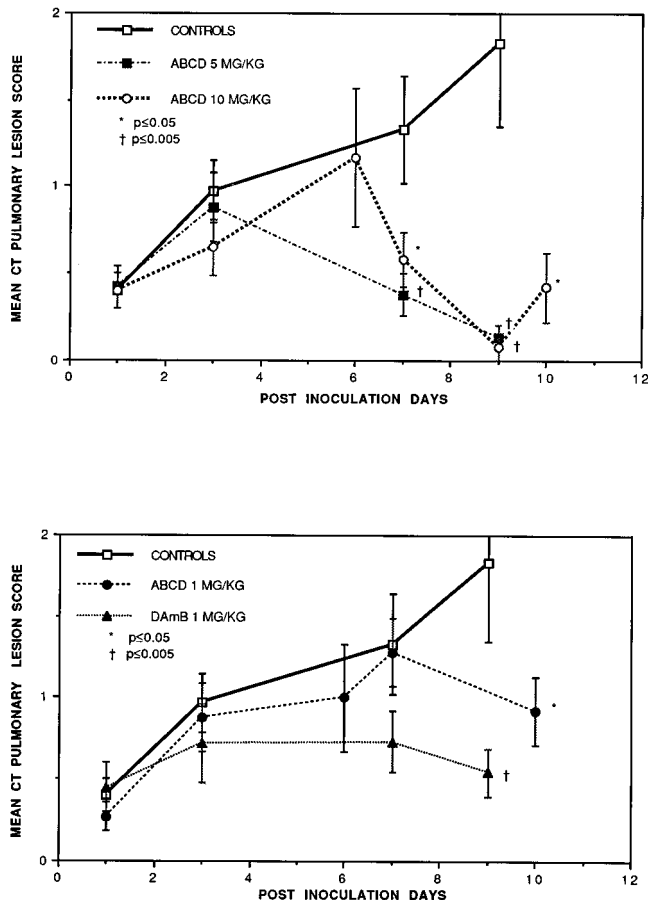


FIG. 2. Therapeutic monitoring of experimental pulmonary aspergillosis by CT of pulmonary lesion scores. Values represent means \pm standard errors of the pulmonary lesion score. Lesions in untreated controls continued to progress. Lesions in ABCD-treated rabbits initially increased and then decreased in response to antifungal therapy in a dosage-dependent manner. There was a more rapid rate of resolution of pulmonary lesions in neutropenic rabbits treated with ABCD at 5 and 10 mg/kg of body weight per day (top panel) than in rabbits treated with ABCD at 1 mg/kg/day (bottom panel). Pulmonary CT lesion scores on days 7, 9, and 10 in rabbits treated with ABCD at 5 and 10 mg/kg/day were significantly reduced (*, $P \leq 0.05$; †, $P \leq 0.005$) compared with those of untreated controls on days 7 and 9. Pulmonary lesion scores of rabbits treated with ABCD at 1 mg/kg/day and DAmB at 1 mg/kg/day also were significantly reduced ($P \leq 0.05$ and $P \leq 0.005$, respectively) compared with those of untreated controls on day 9.

decreased in response to antifungal therapy in a dosage-dependent manner. There were significant differences in pulmonary lesion scores in the untreated control group versus those in treated groups on days 7 and 9.

The pulmonary lesion scores on day 7 of rabbits treated with ABCD (5 and 10 mg/kg/day) were significantly reduced ($P \leq 0.005$ and $P \leq 0.05$, respectively) compared with those of untreated controls on day 7 (Fig. 2, upper panel). The pulmonary lesion scores on days 9 and 10 of rabbits treated with ABCD at 5 and 10 mg/kg/day ($P \leq 0.005$ and $P \leq 0.05$, respectively) (Fig. 2, upper panel) and of rabbits treated with ABCD at 1 mg/kg/day and DAmB at 1 mg/kg/day ($P \leq 0.05$ and $P \leq 0.005$, respectively) (Fig. 2, lower panel) also were significantly reduced compared with those of untreated controls on day 9.

There was a rapid rate of resolution of pulmonary lesions in neutropenic rabbits treated with ABCD at 5 and 10 mg/kg/day (Fig. 2, upper panel). In comparison, there was no net decline

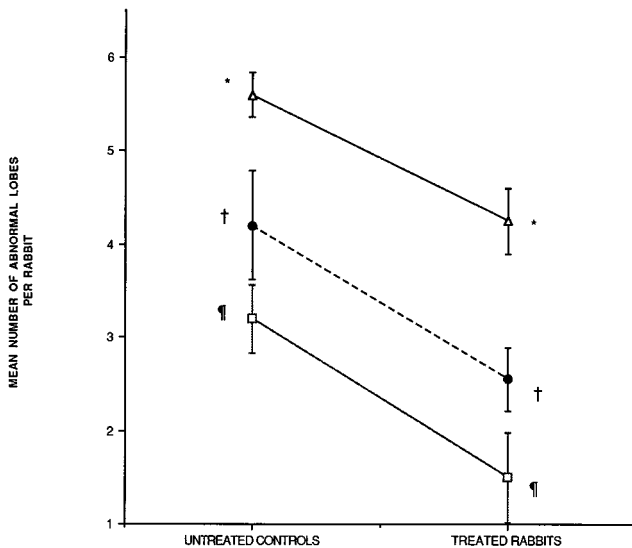


FIG. 3. Similarity of trends of resolution of mean pulmonary lesions in response to antifungal therapy in treated ($n = 120$ lobes) versus untreated ($n = 30$ lobes) rabbits as determined pathologically (Δ), microbiologically (\square), and by concomitant CT (\bullet). Values represent means \pm standard errors. Pathologically, microbiologically, and radiologically demonstrated lesions displayed similar magnitudes of responses to therapy ($P = 0.071$ [*], $P = 0.038$ [†], and $P = 0.099$ [‡], respectively).

in pulmonary lesion scores of rabbits treated with ABCD at 1 mg/kg/day (Fig. 2, lower panel). Moreover, when DAMB at 1 mg/kg/day was compared with ABCD at 1 mg/kg/day, DAMB-treated rabbits demonstrated a trend of more effective stabilization of pulmonary lesions than did the animals treated with the same dosage of ABCD.

Comparison of therapeutic responses as measured by UFCT, quantitative tissue cultures, and pulmonary lesions determined postmortem. There were similar trends of mean pulmonary lesions in response to antifungal therapy in treated versus untreated rabbits, as determined by pathologic examination, quantitative cultures, and concomitant UFCT (Fig. 3). The overall sensitivity of UFCT in detection of lesions demonstrated postmortem was 64% (72 of 113). The sensitivity of UFCT was 75% (21 of 28) in detection of lobes with lesions in untreated animals and 60% (51 of 85) in detection of lobes with lesions in treated rabbits ($P = 0.23$), perhaps related to the smaller sizes of the pulmonary lesions in treated animals.

DISCUSSION

This study demonstrated a significant dose-response relationship between resolution of pulmonary lesions monitored by UFCT and increasing dosages of ABCD. The same trend of resolution of UFCT-detected lesions paralleled the pathological and microbiological responses to antifungal therapy. UFCT was more sensitive than conventional chest radiography in detecting lesions due to invasive pulmonary aspergillosis. These findings indicate that serial examination of UFCT-defined lesions of aspergillosis may provide a useful system for monitoring the response of pathogen-mediated tissue injury to antifungal therapy.

The findings in this study indicate that untreated control animals with invasive aspergillosis continue to develop pulmonary lesions, while treated rabbits appear to have a slight progression of lesions followed by stabilization or resolution, depending upon the dosage and the compound. Rabbits treated

at the highest dosages of ABCD (5 and 10 mg/kg/day) had the most rapid rate of resolution of lesions by UFCT. In comparison, those treated with ABCD at 1 mg/kg/day had a pattern suggesting a stabilization of infiltrates and only a slight downward trend toward the end of the therapy. High dosages (5 and 10 mg/kg/day) of ABCD may be killing the *Aspergillus* hyphae more rapidly than ABCD at 1 mg/kg/day, thus interdicting the course of tissue injury and evolution of progression of pulmonary infiltrates. These patterns of response are consistent with previously reported findings with ABCD in our rabbit model of experimental pulmonary aspergillosis, in which there was a direct relationship between increasing dosage of ABCD and resolution of pulmonary lesions.

There is typically a paucity of neutrophils and mononuclear cells in the infected tissue of neutropenic hosts with invasive aspergillosis. Neutropenic hosts also have a high propensity toward hemorrhage due to concomitant thrombocytopenia. Radiographically evident pulmonary infiltrates in neutropenic hosts with invasive aspergillosis are due to edema, hemorrhage, and infarction rather than to neutrophilic infiltration (3, 11, 29). During the initial course of invasive pulmonary aspergillosis in neutropenic hosts, hyphae invade the distal airways, resulting in an early bronchopneumonia with edema and hemorrhage. As the *Aspergillus* hyphae invade pulmonary blood vessels, hemorrhagic infarction ensues.

The radiological findings in this study provide further insight into the pathogenesis of invasive aspergillosis. Early pulmonary infiltrates in the treated rabbits were reversible, suggesting that if the *Aspergillus* hyphae are damaged or killed by amphotericin B, then pulmonary edema and intra-alveolar hemorrhage may stabilize and then resolve. In comparison, pulmonary infiltrates in untreated animals continue to progress to more advanced stages, including vascular invasion, thrombosis, and infarction. Lesions of pulmonary infarction will likely be more refractory in response to antifungal therapy, because of the nonviability of this tissue. The persistence of some pulmonary infiltrates in invasive aspergillosis despite antifungal therapy may be due in part to persistent small tissue infarcts, which indeed were histologically identified (data not shown).

UFCT permitted the course of invasive pulmonary aspergillosis to be monitored in the same rabbit. Therapeutic monitoring by UFCT permits each rabbit to serve as its own baseline control and substantially decreases the number of rabbits by eliminating the need for timed-sacrifice studies. In addition to the investigation of antifungal compounds, UFCT has potential applications for studying the pharmacodynamic effects of other antimicrobial compounds for experimental bacterial, viral, or *Pneumocystis carinii* pneumonia. Serial scanning can also be applied to the study of immunomodulatory compounds (33) and to the study of pathogenesis of strains with genetic deletions of putative virulence factors. UFCT may be especially applicable for immunocompromised animals, in which the host cellular inflammatory infiltrate is reduced and the direct tissue injury produced by the organism is more clearly evident. As the organism is eliminated, tissue injury is decreased, or abrogated.

The greater speed of UFCT compared with conventional CT permits a rapid scanning time of less than 5 min per animal while maintaining similar resolutions of lesions. This rapid scanning time also permits rapid diagnostic imaging with children, who are less inclined to remain stationary during longer scanning times with conventional CT (6, 7, 14, 23). That UFCT was more sensitive in detection of pulmonary lesions in rabbits with invasive pulmonary aspergillosis is consistent with clinical observations comparing these two radiological diagnostic

methods (5, 17, 24). The times spent in performing conventional chest radiography with an anterior-posterior view plus lateral views versus UFCT scanning of the rabbit thorax were similar. The anatomic detail and diagnostic yield of UFCT, however, were clearly superior to those of conventional chest radiography.

The findings in this study establish a correlation between UFCT-defined lesions with microbiological response and resolution of pathologically defined lesions in experimental invasive pulmonary aspergillosis. Serial monitoring of UFCT-defined lesions of aspergillosis provides a novel system for determining the response of pathogen-mediated tissue injury to antifungal therapy. These imaging methods also may be applicable to the study of the responses to other antimicrobial compounds and immunomodulatory agents, as well as to the study of putative virulence factors of respiratory pathogens.

ACKNOWLEDGMENTS

We thank the staff of the Office of Laboratory Animal Science, National Cancer Institute, and the staff of the Surgery Branch, Veterinary Resources Program, National Center for Research Resources, for excellent laboratory animal care.

REFERENCES

- Adler-Moore, J., and R. T. Proffitt. 1993. Development, characterization, efficacy, and mode of action of AmBisome, a unilamellar liposomal formulation of amphotericin B. *Liposome Res.* **3**:429-450.
- Ahrens, J., J. R. Graybill, P. C. Craven, and R. L. Taylor. 1984. Treatment of experimental murine candidiasis with liposome-associated amphotericin B. *Sabouraudia* **22**:163-166.
- Allende, M. C., J. W. Lee, P. Francis, K. Garrett, H. Dollenberg, J. Berenguer, C. A. Lyman, P. A. Pizzo, and T. J. Walsh. 1994. Dose-dependent antifungal activity and nephrotoxicity of amphotericin B colloidal dispersion in experimental pulmonary aspergillosis. *Antimicrob. Agents Chemother.* **38**:518-522.
- Anaisie, E. 1992. Opportunistic mycoses in the immunocompromised host: experience at a cancer center and review. *Clin. Infect. Dis.* **14**(Suppl. 1):S43-S53.
- Barloon, T. J., J. R. Galvin, M. Mori, W. Stanford, and R. D. Gingrich. 1991. Ultrafast chest CT in the clinical management of febrile bone marrow transplant patients with normal or nonspecific chest roentgenograms. *Chest* **99**: 928-933.
- Brasch, R. C. 1988. Ultrafast computed tomography for infants and children. *Radiol. Clin. N. Am.* **25**:277-286.
- Brody, A. S., J. P. Kuhn, F. G. Seidel, and L. S. Brodsky. 1991. Airway evaluation in children with use of ultrafast CT: pitfalls and recommendations. *Radiology* **178**:181-184.
- Burch, P. A., J. E. Karp, M. G. Merz, J. E. Kuhlman, and E. K. Fishman. 1987. Favorable outcome of invasive aspergillosis in patients with acute leukemia. *J. Clin. Oncol.* **5**:1985-1993.
- Clark, J. M., R. R. Whitney, S. J. Olsen, R. J. George, M. R. Swerdel, L. Kunselman, and D. P. Bonner. 1991. Amphotericin B lipid complex therapy of experimental fungal infections in mice. *Antimicrob. Agents Chemother.* **35**:615-621.
- Fielding, R. M., P. C. Smith, L. H. Wang, J. Porter, and L. S. S. Guo. 1991. Comparative pharmacokinetics of amphotericin B after administration of a novel colloidal delivery system, ABCD, and a conventional formulation to rats. *Antimicrob. Agents Chemother.* **35**:1208-1213.
- Francis, P., J. W. Lee, A. Hoffman, J. Peter, A. Francesconi, J. Bacher, J. Shelhamer, P. A. Pizzo, and T. J. Walsh. 1994. Efficacy of unilamellar liposomal amphotericin B in treatment of pulmonary aspergillosis in persistently granulocytopenic rabbits: the potential role of bronchoalveolar lavage D-mannitol and galactomannan as markers of infection. *J. Infect. Dis.* **169**: 356-368.
- Geraghty, J. J., W. Stanford, S. K. Landas, and J. R. Galvin. 1992. Ultrafast computed tomography in experimental pulmonary embolism. *Invest. Radiol.* **27**:60-63.
- Gerson, S. L., G. H. Talbot, S. Hurwitz, B. L. Strom, E. J. Lusk, and P. A. Cassileth. 1984. Prolonged granulocytopenia: the major risk factor for invasive pulmonary aspergillosis in patients with acute leukemia. *Ann. Intern. Med.* **100**:345-351.
- Gross, G. W. 1992. Pediatric chest imaging. *Curr. Opin. Radiol.* **4**:36-43.
- Guo, L. S. S., R. M. Fielding, and D. Mufson. 1990. Pharmacokinetic study of a novel amphotericin B colloidal dispersion with improved therapeutic index. *Ann. N. Y. Acad. Sci.* **618**:586-588.
- Juliano, R. L., G. Lopez Berestein, R. Hopfer, R. Mehta, K. Mehta, and K. Mills. 1985. Selective toxicity and enhanced therapeutic index of liposomal polyene antibiotics in systemic fungal infections. *Ann. N. Y. Acad. Sci.* **446**:390-402.
- Kuhlman, J. E. 1991. The role of chest CT in evaluation of the febrile bone marrow transplant recipient. *Chest* **99**:794-795.
- Kuhlman, J. E., E. K. Fishman, P. A. Burch, J. E. Karp, E. A. Zerhouni, and S. S. Siegelman. 1988. CT of invasive pulmonary aspergillosis. *Am. J. Roentgenol.* **150**:1015-1020.
- Kuhlman, J. E., E. K. Fishman, and S. S. Siegelman. 1985. Invasive pulmonary aspergillosis in acute leukemia: characteristic findings on CT, the CT halo sign and the role of CT in early diagnosis. *Radiology* **157**:611-614.
- Lipton, M. J., and W. W. Holt. 1989. Value of ultrafast CT scanning in cardiology. *Br. Med. Bull.* **45**:991-1010.
- Lopez-Berestein, G. 1986. Liposomal amphotericin B in the treatment of fungal infections. *Ann. Intern. Med.* **105**:130-131.
- Lyman, C., and T. J. Walsh. 1992. Systemically administered antifungal agents: a review of clinical pharmacology and therapeutic applications. *Drugs* **44**:9-35.
- Lynch, D. A., R. C. Brasch, K. A. Hardy, and W. R. Webb. 1990. Pediatric pulmonary disease: assessment with high-resolution ultrafast CT. *Radiology* **176**:243-248.
- McCloud, T. C., J. Wittenberg, and J. T. Ferrucci. 1979. Computed tomography of the thorax and standard radiographic evaluation of the chest: a comparative study. *J. Comput. Assisted Tomogr.* **3**:170-180.
- Meyer, R. D., L. S. Young, D. Armstrong, and B. Yu. 1973. Aspergillosis complicating neoplastic disease. *Am. J. Med.* **54**:6-15.
- Minor, R. L., R. M. Oren, W. Stanford, and D. W. Ferguson. 1991. Biventricular thrombi and pulmonary emboli complicating idiopathic dilated cardiomyopathy: diagnosis with cardiac ultrafast CT. *Am. Heart J.* **122**:1477-1484.
- Orr, D. P., R. L. Myerowitz, and P. J. Dubois. 1978. Patho-radiologic correlation of invasive pulmonary aspergillosis in the compromised host. *Cancer* **41**:2028-2039.
- Pannuti, C. S., R. D. Gingrich, M. A. Pfaller, and R. P. Wenzel. 1991. Nosocomial pneumonia in adult patients undergoing bone marrow transplantation: a 9-year study. *J. Clin. Oncol.* **9**:77-84.
- Panos, R. J., L. F. Barr, T. J. Walsh, and H. J. Silverman. 1988. Factors associated with fatal hemoptysis in cancer patients. *Chest* **94**:1008-1013.
- Patterson, T. F., P. Minter, J. Dijkstra, F. C. Szoka, Jr., J. L. Ryan, and V. T. Andriole. 1989. Treatment of experimental invasive aspergillosis with novel amphotericin B/cholesterol-sulfate complexes. *J. Infect. Dis.* **159**:717-724.
- Ringden, O., F. Meunier, J. Tollemar, P. Ricci, S. Tura, E. Kuse, M. A. Viviani, N. C. Gorin, J. Klastersky, P. Fenaux, H. G. Prentice, and G. Ksionski. 1991. Efficacy of amphotericin B encapsulated in liposomes (Am-Bisome) in the treatment of invasive fungal infections in immunocompromised patients. *J. Antimicrob. Chemother.* **28**(Suppl. B):63-72.
- Rumberger, J. A., and M. J. Lipton. 1989. Ultrafast cardiac CT scanning. *Cardiol. Clin.* **7**:713-734.
- Walsh, T., C. Gonzalez, C. Lyman, S. Lee, C. Del Guercio, A. Gehrt, T. Sein, E. Roilides, R. Schaefele, A. Francesconi, and P. Pizzo. 1994. Human recombinant macrophage colony stimulating factor (M-CSF) augments pulmonary host defense against *Aspergillus fumigatus*, abstr. F-27, p. 593. In Abstracts of the 94th General Meeting of the American Society for Microbiology 1994. American Society for Microbiology, Washington, D.C.
- Walsh, T. J. 1990. Invasive pulmonary aspergillosis in patients with neoplastic diseases. *Semin. Respir. Infect.* **5**:111-122.
- Walsh, T. J., J. Bacher, and P. A. Pizzo. 1988. Chronic Silastic central venous catheterization for induction, maintenance, and support of persistent granulocytopenia in rabbits. *Lab. Anim. Med.* **38**:467-470.