

Allergic bronchopulmonary aspergillosis complicating cystic fibrosis in childhood

M J BRUETON, L P ORMEROD, K J SHAH, AND CHARLOTTE M ANDERSON

Institute of Child Health, University of Birmingham, and Children's Hospital, Birmingham

SUMMARY Allergic bronchopulmonary aspergillosis, known to be associated with cystic fibrosis in older patients, occurred in 7 young atopic children with cystic fibrosis. The diagnosis was suggested by the onset of, or the increase in, asthmatic symptoms accompanied by major chest x-ray changes ranging from total collapse of a lung or lobe to extensive but changing areas of consolidation. Each of the children had a blood eosinophilia, positive type I skin tests to *Aspergillus fumigatus*, and reversible airways obstruction. Most had a positive type III skin test and circulating precipitins to *A. fumigatus*, with raised IgE levels which contained specific antibodies to the fungus on radioallergosorbent (RAST) test. None had advanced suppurative chest disease of cystic fibrosis. None was given specific antifungal agents; two received systemic treatment with corticosteroids, the others received additional drugs for their asthma. Two developed total collapse of one lung, one child being only 2 years old. Five have had recurrences of pulmonary shadowing typical of allergic aspergillosis but are not showing significant progression of their cystic fibrosis lung disease. Our experience suggests that there should be an increased awareness of this condition, particularly its association with extensive pulmonary collapse or consolidation in children with cystic fibrosis who are atopic.

Aspergillus fumigatus is probably the most important cause of mycotic bronchopulmonary infection in western Europe. The clinical effect of infection with this ubiquitous mould depends on the immunological status of the host.¹ In atopic individuals, allergic bronchopulmonary aspergillosis occurs more commonly than aspergillomas or invasive aspergillosis. The allergic form is characterised by the presence of asthma, pulmonary infiltrates which are often transient, eosinophilia, and positive immediate skin tests to *A. fumigatus*. The condition was first described in 1952 by Hinson *et al.*,² and since then has been increasingly recognised in asthmatic patients.³⁻⁴ Those usually affected are young adults but, in retrospect, the first pulmonary infiltration might have occurred in their childhood.⁵

Mearns *et al.*⁶ reported an association between

allergic aspergillosis and cystic fibrosis (CF) in 1965. Batten⁷ described some older patients in 1967, and subsequently an incidence of 0.5%⁸ and 5%⁹ was reported among adolescents and young adults with CF. We have recently recognised this complication rather more frequently in young children with CF who are predisposed by having reversible airways obstruction and atopy. The purpose of this paper is to describe the spectrum of features seen in such children, with particular reference to allergic aspergillosis as a cause of extensive pulmonary collapse and consolidation. The results of investigations on 7 patients are given in the Table.

The criteria for making the diagnosis of allergic aspergillosis were pulmonary opacity with blood eosinophilia, a positive type I prick test reaction to an extract of *A. fumigatus*, and the presence of reversible airways obstruction. Supportive evidence included the presence of serum precipitins to *A. fumigatus*, culture of the fungus from the sputum, and the presence of radioallergosorbent- (RAST-) specific IgE antibodies to *A. fumigatus* (Table). The diagnosis of CF was made in all 7 children using standard criteria, including persistently raised sweat sodium and chloride concentrations (>60 mmol/l). All the children were being treated with antibiotics

Institute of Child Health, Birmingham
CHARLOTTE M ANDERSON, professor of paediatrics and child health

Westminster Children's Hospital, London

M J BRUETON, senior lecturer in child health

North Manchester General Hospital, Manchester

L P ORMEROD, senior medical registrar

Department of Radiodiagnosis, Children's Hospital, Birmingham

K J SHAH, consultant radiologist

Table Details of investigations concerning the diagnosis of allergic aspergillosis and atopy in 7 patients with cystic fibrosis

Case	Asthma % reversibility of FEV ₁	Type I skin test	Serum precipitins to <i>A. fumigatus</i>	Culture from sputum of <i>A. fumigatus</i> *	Type III skin test	Serum IgE* (IU/ml)	Serum IgE (IU/ml) after resolution of x-ray changes	RAST-specific IgE to <i>A. fumigatus</i>	Blood eosinophil count* (× 10 ⁹ /l)
1	Too young for spirometry	Positive	Negative	—	Positive	8000	200	3+	1.6
2	20	Positive	Positive	Positive	Negative	500	110	0	2.9
3	15	Positive	Positive	Positive	Positive	NA	50	1+	1.05
4	15	Positive	Negative	Positive	Positive	1200	—	2+	1.6
5	30	Positive	Positive	—	Positive	2960	1100	NA	1.7
6	25	Positive	Positive	—	Negative	1672	1100	3+	1.5
7	17.5	Positive	Positive	—	Positive	1950	1000	3+	0.8

*At time of changes in x-rays. NA = not available.

relevant to pathogenic organisms in their sputum or cough swabs, physiotherapy, intermittent inhalation therapy, and pancreatic supplements.

Case reports

The clinical details of the patients illustrating different features and modes of presentation are given below.

The following 2 patients each experienced massive collapse of the lung—Case 1 at age 2½ years and Case 2 at 6 years.

Case 1. This boy, born in England of Pakistani parents, was diagnosed as having CF at age one month. He remained well without persistent cough until aged 2½ years although some wheezing had been noted with upper respiratory infections and when he was excited. Chest x-rays showed only minor changes of increased lung markings and a little overdistention. In January 1978, when aged 2½ years, he was admitted to hospital because wheezing had become severe and persistent, and he was dyspnoeic and pyrexial. Clinical and x-ray examination (Fig. 1a) showed total collapse of the right lung. Extra physiotherapy and parenteral antibiotics failed to bring about improvement, nor did nebulised salbutamol and disodium cromoglycate have any effect, and the lung remained collapsed. Bronchoscopy did not show any mucous plug or extrinsic pressure on the bronchi. As a pronounced eosinophilia was present, allergic bronchopulmonary aspergillosis was suspected and investigations (Table) confirmed this. Oral treatment with corticosteroids was started and was accompanied by considerable re-aeration of the lung (Fig. 1b). One year later the patient is still well and maintained on nebulised salbutamol and disodium cromoglycate, in addition to normal treatment for CF, but there is some

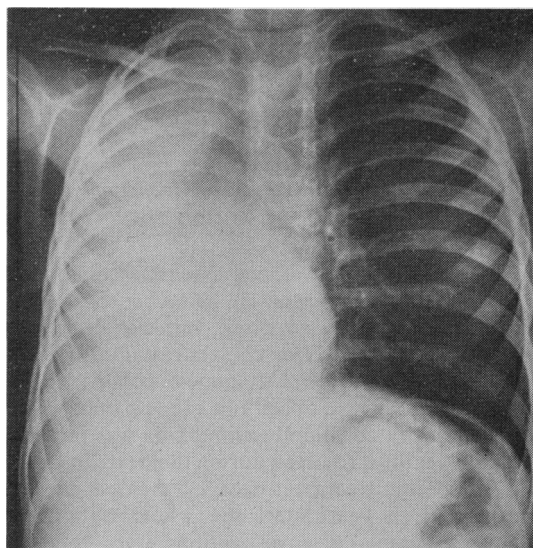


Fig. 1a (Case 1). Total collapse of the right lung and shift of the heart and mediastinal structures to the right side.

residual opacity in the right upper lobe. Serum IgE concentration has fallen to 200 IU/ml and there is no blood eosinophilia.

To our knowledge this boy is the youngest patient to be reported with allergic bronchopulmonary aspergillosis and CF. This case is also unusual in that the condition was recognised at the time of the boy's illness, as in most reported cases the diagnosis has been made retrospectively. Only 3 other children with allergic aspergillosis who were less than 2 years old have been reported and none of them suffers from CF.¹⁰⁻¹¹

Case 2. This boy was diagnosed as having CF at

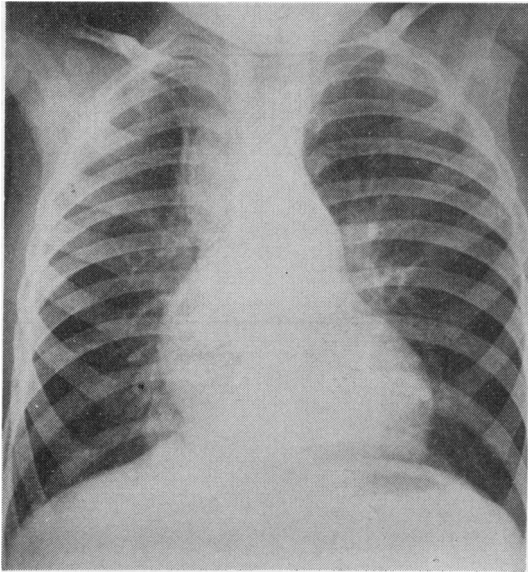


Fig. 1b (Case 1). Re-expansion of the right lung a few weeks later. Now residual partial collapse of right upper lobe and little opacity at the right base medially.

age one month; he developed extensive collapse of the left lung at age 6 years. He had wheezed a great deal during his first year or so, but was otherwise well with a relatively clear chest x-ray until 6 years when he suddenly became dyspnoeic; collapse of left lower lobe and dense opacity in the left upper lobe were demonstrated. Blood eosinophilia was present. The x-ray features resolved during the next 2 months with no specific treatment except increased physiotherapy but, a year later, the whole right lung collapsed. Results of investigations were then as shown in the Table. At bronchoscopy copious brown sputum which cultured *A. fumigatus* was aspirated from the right main bronchus. With intensive physiotherapy, regular nebulised disodium cromoglycate, and salbutamol, a mucus plug was produced and the right lung then re-expanded. Since then there have been no further episodes of gross pulmonary opacity with accompanying eosinophilia and he has remained well.

Five patients have shown the more usually recognised clinical pattern of allergic aspergillosis in the adult asthmatic patient, with changing areas of opacity in the lung fields, usually resolving with the use of antiasthmatic drugs, as exemplified by the following child.

Case 3. This girl was born in 1970 and diagnosed as having CF in the first month of life. She had been

well on treatment until age 6 years when bronchospasm was noted for the first time. The peripheral eosinophil count, IgE level, and chest x-ray were normal. She was given bronchodilators with improvement but a year later she developed a persistent, dry cough and became anorexic. Chest x-ray showed large rounded areas of consolidation in both upper lobes and considerable patchy opacity in the right lower lobe (Fig. 2). Computerised axial tomography (CAT) scan of the thorax showed dilated bronchi in the right upper lobe. Investigations were as shown in the Table and reversible airways obstruction was demonstrated. Administration of salbutamol and disodium cromoglycate was accompanied by considerable clearing of the x-ray changes in the right lung field. The IgE level dropped to 50 IU/ml. Six months later there was still an opacity in the left upper lobe but no symptoms accompanied this and during the next months it partially cleared. About 9 months later she was wheezing on exercise and a new opacity in the right upper lobe appeared. This is currently resolving with extra physiotherapy and bronchodilators.

The following boy posed a more difficult problem both in diagnosis and management.

Case 4. This boy was diagnosed as having CF at one year and remained extremely well until 8 years without persistent respiratory symptoms and with a normal chest x-ray and normal growth. In February

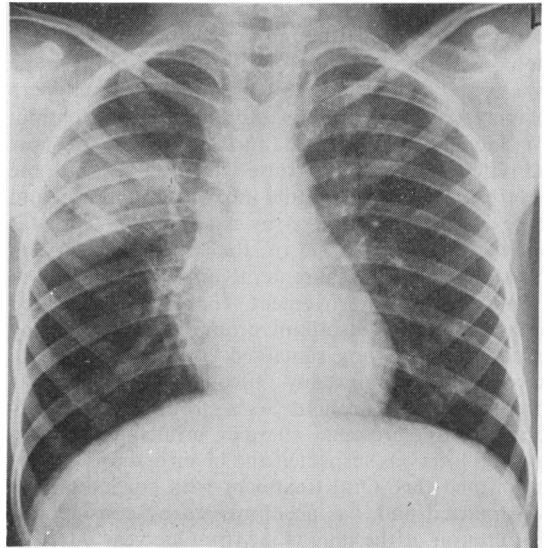


Fig. 2 (Case 3). Large and rounded areas of consolidation in both upper lobes and patchy peribronchial opacity in the right lower lobe.

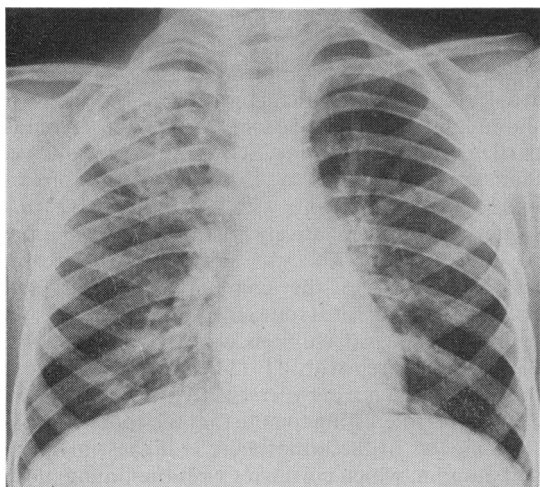


Fig. 3a (Case 4). Development of large area of consolidation in the right upper lobe and extensive opacity in the lower lobe with wheeze and cough.

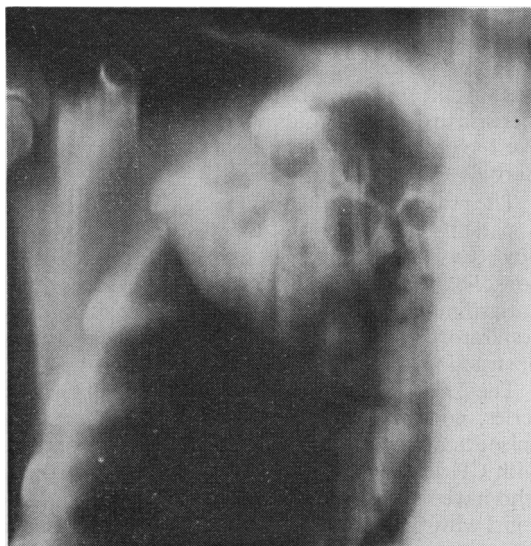

Fig. 3b (Case 4). CAT scan (antero-posterior) of the right upper lobe showing in detail rounded area of consolidation with multiple cavities within it.

1978 he suddenly started to wheeze and cough persistently, appetite waned, and he lost weight. Reversible airways obstruction was demonstrated. The chest x-ray now showed pronounced consolidation in the right upper and lower lobes (Fig. 3a). Investigations were as shown in the Table.

Despite intensive physiotherapy, he produced little sputum but *Proteus vulgaris* sensitive to gentamicin was grown persistently, together with *A. fumigatus*. As the patient was still anorexic and losing weight, a course of intravenous gentamicin was started, as well as oral corticosteroids as wheezing was still very pronounced and had not responded to salbutamol and disodium cromoglycate. There was resolution of the eosinophilia and of the patchy opacity in the right lower lobe but the right upper lobe consolidation persisted. CAT showed dilated bronchi and multiple cavities in the lobe (Fig. 3b). At bronchoscopy brownish tenacious material in which fungal hyphae were seen on microscopical examination was aspirated from the right upper lobe bronchus. A profuse growth of *P. vulgaris* was again obtained, together with *A. fumigatus*. Intravenous gentamicin was continued. During the days after the bronchoscopy he coughed up large volumes of thick brown sputum containing seed-like solid bits and x-ray improvement followed. Wheezing was still difficult to control at home so he was continued on salbutamol, disodium cromoglycate, and a small dose of corticosteroids and, two months later, he had regained his weight, had no cough or wheezing, and considerable

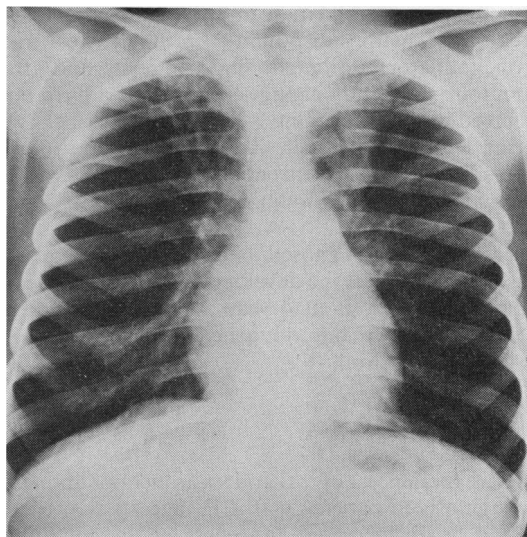


Fig. 3c (Case 4). Considerable clearance of right upper lobe lesion over a period of a few months. Now residual changes of dilatation of bronchi and patchy opacity in both upper lobes and to a lesser extent in the right lower lobe.

clearing had occurred in the right upper lobe (Fig. 3c). The corticosteroid dose was reduced but, after another 2 months, consolidation recurred in the right lower lobe, clearing with increase in the

corticosteroid dose. He recently developed consolidation in the left upper lobe, not at first accompanied by cough or wheeze, but later copious brownish sputum was again produced. Inhaled gentamicin and increase in corticosteroids have resulted in resolution. We have not as yet been able to stop his corticosteroids altogether.

The relevant investigatory details of the remaining 3 patients are given in the Table. A 7-year-old boy (Case 5) had three episodes of pulmonary consolidation within one year, all clearing with antiasthmatic treatment and leaving him with normal respiratory function tests and no reversible bronchial obstruction.

The 2 remaining patients also illustrate that in our series, contrary to those recorded by others,⁹ the episodes of allergic aspergillosis occurred in patients with CF whose lungs were not severely affected and who have remained well after their episodes. Case 6, a girl with CF diagnosed at 9 months, had remained well without cough or sputum until 9 years when she presented with a dry irritating cough and bronchospasm. Consolidation was present in the right upper lobe but there was no sputum and no pathogenic organisms were isolated from the cough swab. Investigations (Table) indicated allergic aspergillosis. Treatment with disodium cromoglycate and bronchodilators initiated improvement and the symptoms and x-ray changes resolved and have not recurred in the succeeding 3 years. However her IgE serum level remains high at 1100 IU/ml, she shows reversible airways obstruction, and still receives treatment with disodium cromoglycate and salbutamol.

Case 7, a girl diagnosed as having CF at 2 years, was quite well until she developed her first episode of allergic aspergillosis at 4 years, and she has had 3 recurrences since but no general deterioration in respiratory function.

Discussion

This experience of allergic bronchopulmonary aspergillosis in patients with CF suggests that there should be an increased awareness of the condition and of its association with extensive pulmonary collapse, or with varying areas of consolidation. It is not clear why we have seen so many cases recently. It seems unlikely that such major x-ray changes could earlier have been missed in our clinic. At the same time, it seems clear that asthmatic symptoms are now more common in patients with CF.¹² Does this represent an increased incidence of atopy in patients with CF generally? Or does it reflect increasing activation of an atopic predisposition, which is

associated with CF lung damage or with some aspects of therapy?

Turner *et al.*¹³ have pointed out that, unlike many atopic individuals, patients with CF are likely to show positive skin reactions to the moulds, particularly *A. fumigatus*. Schwartz *et al.*¹⁴ showed that serum precipitins to *A. fumigatus* were present in up to 30% of patients with CF. Silverman *et al.*¹⁵ suggested that the relatively high prevalence of atopy in children with CF was not due to increased hypersensitivity to the common allergens, grass pollens and house dust mite, as for these allergens the figures for normal children were comparable with those for children with CF (34% and 29%), but to the high prevalence of hypersensitivity to *A. fumigatus* (35%). It is interesting to note that the spore count of *A. fumigatus* in the atmosphere is highest in spring and autumn, which correlates with the timing of the illnesses in our patients.

Contrary to other reports and to the suggestions of Silverman *et al.*¹⁵ that the development of hypersensitivity to *A. fumigatus* was associated with increasingly severe lung damage from CF, it was quite striking that our children were among those who had been progressing well and none was among those of our clinic with poor 'Shwachman scores.' Furthermore most of our patients appear to have made good recoveries although there have been recurrences.

There is no place for specific treatment with antifungal agents in allergic bronchopulmonary aspergillosis but, if the asthmatic symptoms and the lung opacities or collapse do not improve with the disodium cromoglycate and salbutamol (oral or inhaled), together with intensified physiotherapy, oral corticosteroids are indicated.¹⁶ The use of corticosteroids cannot be recommended in children without due consideration, particularly in the presence of serious pulmonary infection. However treatment with corticosteroids did not lead to a worsening of chest infection in CF and in 2 of our patients corticosteroids were associated with rapid and extensive resolution of the x-ray findings and the symptoms.

The immunological features of allergic bronchopulmonary aspergillosis were characterised by McCarthy and Pepsy¹⁷ as a mixture of type I IgE-mediated and type III immunocomplex-mediated hypersensitivity reactions. The use of IgE measurements in diagnosis and prediction of the disease course is important. Rosenberg *et al.*¹⁸ found that specific IgE concentration increased in each of their patients before exacerbation and fell during treatment, rising again before further relapse. Case 2, who had high levels during exacerbations, now, 2

years after his last episodes of pulmonary shadowing, has an IgE level of 110 IU/ml, and is RAST-negative for *A. fumigatus*. We are now following a further patient with CF who has asthma, peripheral eosinophilia, circulating precipitins, and positive immediate and late skin tests to *A. fumigatus*. Six months ago her IgE level was 7000 IU/ml, RAST ++ for *A. fumigatus* but, at that time, there were no typical radiological opacities, only minor changes of CF. However she now shows nodular upper lobe opacity and collapse of the right middle lobe. Rosenberg *et al.*¹⁹ reported three similar cases with normal chest x-rays when blood eosinophils and IgE levels were high. They had proximal bronchiectasis on bronchography and were thought to have been observed at an early stage in the evolution of the disease. It is therefore clear that a critical appraisal in relation to allergic bronchopulmonary aspergillosis is required in any child with CF who develops asthma.

We thank Dr J H Parker, Department of Pathology, Shrewsbury Hospital, and Dr T G Merrett, Pharmacia RAST Allergy Unit, Benenden Chest Hospital, Cranbrook, Kent, for the measurement of RAST-specific IgE antibodies to *A. fumigatus*.

References

- ¹ Pepys J. *Hypersensitivity diseases of the lungs due to fungi and organic dusts*. Basel: Karger, 1969.
- ² Hinson K F W, Moon A J, Plummer N S. Bronchopulmonary aspergillosis: a review and a report of eight new cases. *Thorax* 1952; **7**: 317-33.
- ³ Agbayani B F, Norman P S, Wickerwerder W L. The incidence of allergic aspergillosis in chronic asthma. *J Allergy Clin Immunol* 1967; **40**: 319-26.
- ⁴ Malo J L, Inouye T, Hawkins R, Simon G, Turner-Warwick M, Pepys J. Studies in chronic allergic bronchopulmonary aspergillosis. IV. Comparison with a group of asthmatics. *Thorax* 1977; **32**: 275-80.
- ⁵ Berger I, Phillips W L, Shenker I R. Pulmonary aspergillosis in childhood. A case report and discussion. *Clin Pediatr (Phila)* 1972; **11**: 178-82.
- ⁶ Mearns M, Young W, Batten J. Transient pulmonary infiltrations in cystic fibrosis due to allergic aspergillosis. *Thorax* 1965; **20**: 385-92.
- ⁷ Batten J C. Allergic aspergillosis in cystic fibrosis. International conference on cystic fibrosis of the pancreas (mucoviscidosis), Berne/Grindelwald, 1966. Part I. *Mod Probl Paediatr* 1967; **10**: 227-36.
- ⁸ Wood R E, Boat T E, Doershuk C F. State of the art: cystic fibrosis. *Am Rev Respir Dis* 1976; **113**: 833-78.
- ⁹ Mitchell-Heggs P, Mearns M, Batten J C. Cystic fibrosis in adolescents and adults. *Q J Med* 1976; **45**: 479-504.
- ¹⁰ Katz R M, Kniker W T. Infantile hypersensitivity pneumonitis as a reaction to organic antigens. *N Engl J Med* 1973; **288**: 233-7.
- ¹¹ Imbeau S A, Cohen M, Reed C E. Allergic bronchopulmonary aspergillosis in infants. *Am J Dis Child* 1977; **131**: 1127-30.
- ¹² Warner J O, Taylor B W, Norman A P, Soothill J F. Association of cystic fibrosis with allergy. *Arch Dis Child* 1976; **51**: 507-11.
- ¹³ Turner M W, Warner J O, Stokes C R, Norman A P. Immunological studies in cystic fibrosis. *Arch Dis Child* 1978; **53**: 631-8.
- ¹⁴ Schwartz R H, Johnstone D E, Holsclaw D S, Dooley R R. Serum precipitins to *Aspergillus fumigatus* in cystic fibrosis. *Am J Dis Child* 1970; **120**: 432-3.
- ¹⁵ Silverman M, Hobbs F D R, Gordon I R S, Carswell F. Cystic fibrosis, atopy, and airways lability. *Arch Dis Child* 1978; **53**: 873-7.
- ¹⁶ McCarthy D S, Pepys J. Allergic bronchopulmonary aspergillosis: clinical immunology. I. Clinical features. *Clin Allergy* 1971; **1**: 261-86.
- ¹⁷ McCarthy D S, Pepys J. Allergic bronchopulmonary aspergillosis: clinical immunology. II. Skin, nasal, and bronchial tests. *Clin Allergy* 1971; **1**: 415-32.
- ¹⁸ Rosenberg M, Patterson R, Roberts M. Immunologic responses to therapy in allergic bronchopulmonary aspergillosis: serum IgE value as an indicator and predictor of disease activity. *J Pediatr* 1977; **91**: 914-7.
- ¹⁹ Rosenberg M, Mintzer R, Aaronson D W, Patterson R. Allergic bronchopulmonary aspergillosis in three patients with normal chest X-ray films. *Chest* 1977; **72**: 597-600.

Correspondence to Professor Charlotte M Anderson, Institute of Child Health, The Nuffield Building, Francis Road, Birmingham B16 8ET.

Received 19 June 1979