

# Neuropathic bladder and spinal dysraphism

MALGORZATA BORZYSKOWSKI AND B G R NEVILLE

*Evelina Children's Department, Guy's Hospital, London*

**SUMMARY** The association between spinal dysraphism and a neuropathic bladder is well known, but the diagnosis of the spinal lesion and the associated renal problems is often delayed. Four children referred with orthopaedic problems and in whom the bladder abnormality proved to be the major disability are described. Despite widely differing vertebral involvement, all had lower motor neurone neurological deficits confined to lumbar and upper sacral segments. All had unstable, variably thickened, small bladders, and it is proposed that the bladder abnormality is the result of a partial lesion of lumbosacral innervation, and not of an upper motor neurone lesion.

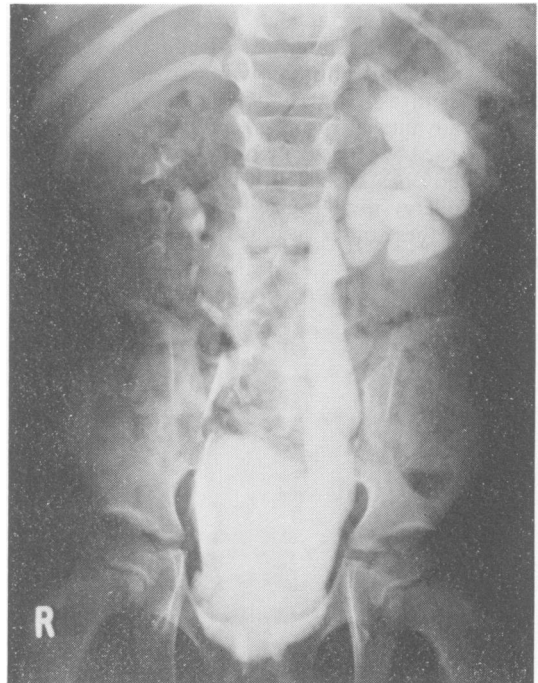
The causes of a neuropathic bladder in childhood are numerous, and include spina bifida (which forms the largest group), spinal dysraphism, spinal cord tumour, trauma, and myelitis. During the course of a study on the management of the neuropathic bladder in childhood we have been surprised at the severity of the bladder problem in children in whom this is due to spinal dysraphism. Spinal dysraphism is a well-known congenital malformation, which may present in many ways. This abnormality of neural tube development may be associated with both distortion and agenesis of neural tissue. In a review of 73 cases of spinal dysraphism, Anderson<sup>1</sup> found that the most common complaint was that of impaired urinary control, which occurred in 33 (45%). Foot deformities were present in 26 (35%). The association with a neuropathic bladder is well known, but the precise patterns of bladder dysfunction and its relationship to skeletal defect and somatic denervation are not clear.

The main purpose of this paper was to investigate the problem of early diagnosis of renal involvement, and to look more closely at the relationship between bladder dysfunction and somatic denervation. Four children are discussed who were referred with orthopaedic problems but in whom the bladder proved to be the major disability.

## Case reports

**Case 1.** This 11-year old girl was referred at age 5½ with left congenital talipes and painful inversion of the right foot for the previous 18 months. On examination she was found to have bilateral wasting, foot deformity (short with high arch), and below

knee weakness (particularly on the left). There was S1 sensory loss, and absence of all lower limb reflexes apart from a slightly increased left knee jerk. There

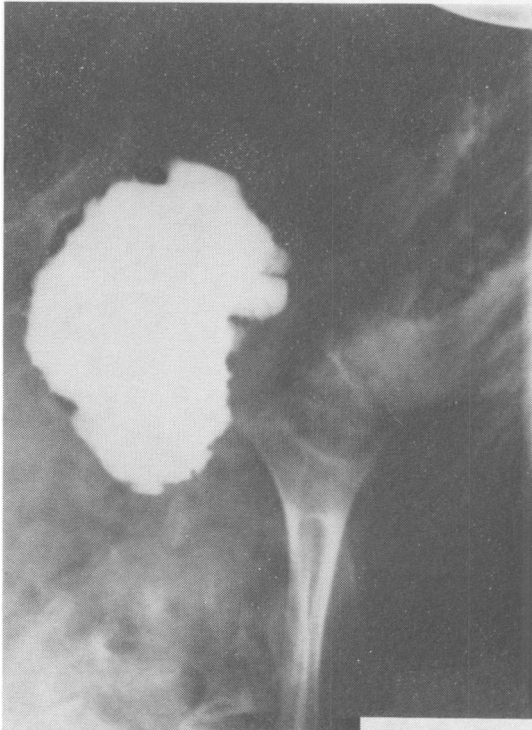


**Fig. 1a** (Case 1.) *Intravenous pyelogram showing the degree of upper tract involvement at the time of diagnosis. The incompletely fused neural arches of the lower thoracic, lumbar, and sacral vertebrae can also be seen.*

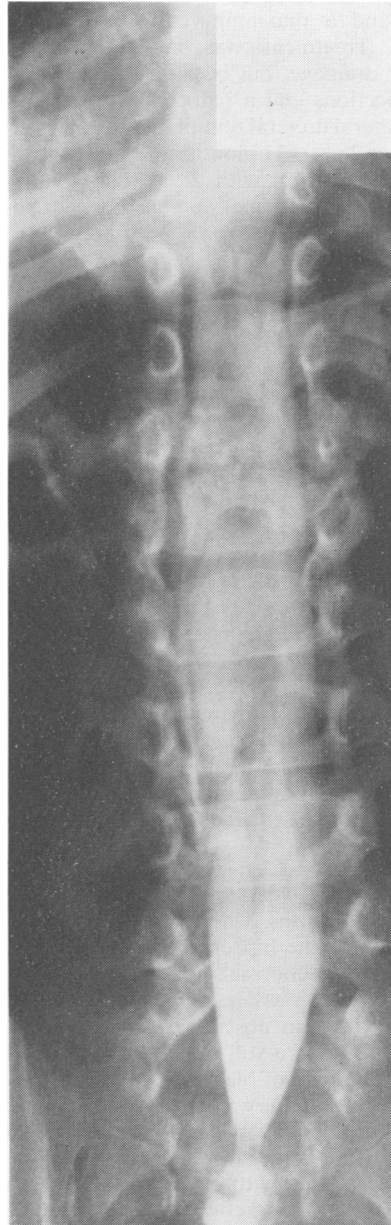was no complaint of bladder problem at that time. Radiology, including myelography, showed sacral agenesis and spinal dysraphism at two levels. Laminectomies were performed at sacral and thoracic levels on separate occasions to release tethering, and she developed postoperative urinary retention after her sacral laminectomy. An intravenous pyelogram showed left hydronephrosis and a dilated right ureter (Fig. 1a). A micturating cystourethrogram showed a small, grossly trabeculated, poorly emptying bladder (Fig. 1b). Because of a reduced glomerular filtration rate and recurrent urinary tract infections, and because bladder expression, drugs (phenoxybenzamine), and long-term catheterisation had failed, a urinary diversion into a colonic conduit was performed at age 8½. Subsequently, there has been a decrease in upper tract dilatation and the glomerular filtration rate remains stable.

**Case 2.** This 4-year old girl was first referred at age 2 years 5 months because of a broad-based and unsteady gait. On examination, she was found to have everted feet, diminished peroneal power, and S1

sensory loss on the right, and only the left knee jerk was present. She had undergone normal potty training, and there was no complaint of bladder problem at that time. Radiology showed spina bifida of the thoracic, lumbar, and sacral spine and diastematomyelia from D8 to D12 (Fig. 2). An



**Fig. 1b** (Case 1.) Micturating cystourethrogram showing the very irregular, trabeculated bladder with many diverticulae.



**Fig. 2** (Case 2.) Myelogram demonstrating diplomyelia and elongation of the conus with a small intrasacral meningocele.

intravenous pyelogram at that time showed bilateral hydronephrosis. Laminectomies were performed at thoracic and lumbosacral levels on separate occasions, and she developed postoperative urinary incontinence after the thoracic laminectomy. A urodynamic study showed a small, unstable, slightly trabeculated bladder associated with gross bilateral reflux, and a maximum detrusor pressure of 50 mmHg. Treatment was initially by continuous catheter drainage, but because of recurrent urinary tract infections and a reduced glomerular filtration rate, bilateral ureteral reimplantation was performed, and at age 2 years 11 months intermittent catheterisation and treatment with drugs (dicyclomine hydrochloride and ephedrine) were introduced. She is now dry and free of infection, and there has been a pronounced decrease in the upper tract dilatation and the glomerular filtration rate has risen from 45 to 74 ml/1.73m<sup>2</sup>.

**Case 3.** This 6½-year old girl was referred at age 4 because of lifelong incontinence, recurrent urinary tract infections, and inversion of the right foot. In infancy, cystoscopy had shown a very trabeculated bladder and urethral dilatation had been performed. On examination she had weakness of eversion of the right foot, an absent left ankle jerk, and a palpable bladder. Radiology showed an abnormal sacrum and a conus at L2, with no abnormality below this. It was felt that surgery would not be helpful. An intravenous pyelogram showed fullness of the upper calyces with scarring on the right and a urodynamic study showed a small, trabeculated, unstable, poorly-emptying bladder with an abnormal urethra (Fig. 3), and with detrusor pressure rising to 55 mmHg. Because of failure of treatment with drugs (phenoxybenzamine), intermittent catheterisation was begun at age 5½, and since then she has been dry and free of infection.

**Case 4.** This 6½-year old girl was first referred at 3 years 2 months with a history of congenital dislocation of the hip on the right, delay in motor development, abnormal posture of the right foot, and lower limb weakness. On examination she was found to have an absent left ankle reflex, a right everted foot, and a stiff gait with planus feet. There was no complaint of bladder problems at the time of referral. Shortly afterwards she developed occasional incontinence, and was found to have a palpable bladder. Radiology showed an abnormal lumbar spine and sacrum, with a split conus tethered at L5. Intravenous pyelography showed bilateral hydronephrosis. After laminectomy and release of tethering, urodynamics showed gross bilateral reflux in association with a small, unstable, slightly

trabeculated bladder, with a maximum detrusor pressure of 65 mmHg (Fig. 4). Initially she was treated with continuous catheter drainage, and subsequently by bladder expression. At age 5 years 2 months intermittent catheterisation was introduced, with improvement in continence, but urinary tract infections continue.

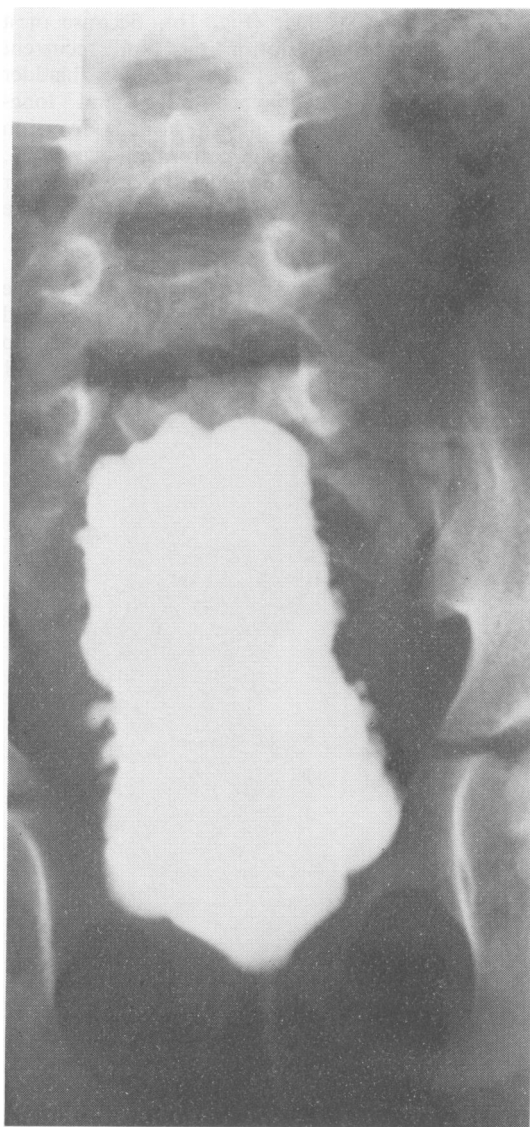


Fig. 3 (Case 3.) Micturating cystourethrogram demonstrating the very abnormal shape and trabeculated outline of the bladder.

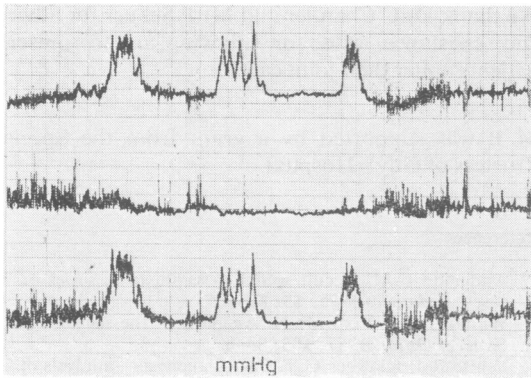


Fig. 4 (Case 4.) Pressure traces from urodynamic study. The bottom trace demonstrates the bladder pressure observed during slow bladder filling; the middle trace shows the simultaneous rectal pressure trace reflecting abdominal pressure, and the top trace shows the detrusor pressure obtained by subtracting the rectal pressure from the bladder pressure. The scale in each case is between 0 and 100 mmHg. Three unstable, uninhibited detrusor contractions can be seen and were associated with both reflux and incontinence.

**Discussion**

There was a considerable delay in diagnosis in all the children, and this may have contributed to the subsequent renal damage. Only one child had never been continent, and it is important to note that in the other 3 renal damage was present before or at the time that the first bladder symptom became apparent. All the children had abnormal, unstable, small, variably thickened bladders, and associated with this, problems of recurrent urinary tract infections, upper tract dilatation, and renal impairment.

The innervation of the bladder and urethra is complex and not yet fully understood. The bladder and urethra are supplied by visceral afferent and efferent fibres that traverse thoracolumbar (sympathetic) and sacral (parasympathetic) spinal nerves—generally T12 to L2 and S2 to 4 respectively. In addition the striated urethral sphincter receives somatic afferent and efferent innervation via the pudendal nerve from sacral spinal nerves (usually S2–4). The parasympathetic component is concerned mainly with detrusor contraction. The two components of the sympathetic are mainly responsible for contraction of the internal sphincter ( $\alpha$  fibres) and exertion of inhibiting influences on bladder activity ( $\beta$  fibres) at high bladder volumes. There are also ascending and descending connections between the pontine reticular formation (influenced by cerebellum and basal ganglia), hypothalamus, and

cortex. There are many proposed integrated storage and voiding reflexes that affect these pathways, but their relative importance in pathological situations is uncertain.

The vertebral, reflex, motor, and sensory abnormalities are compared in the 4 children in Fig. 5. The most striking feature is the wide range of vertebral deficit, particularly if this is compared with the narrow band of neurological deficit that mainly affects L4, L5, and S1. The sacrum was affected in all 4 children, and it is known that bladder dysfunction is common in sacral agenesis.<sup>2–3</sup>

Stark<sup>4</sup> in his studies on 104 children with myelomeningocele found that although there was some correlation between the vertebral level and detrusor activity, there was a much closer correlation with the neurological findings. 92% of children with some S2–4 activity in the legs had some detrusor activity, while 85% of those with no S2–4 activity had no detrusor function.

These 4 girls all have low neurological deficits affecting lower lumbar and upper sacral segments, which are all lower motor neurone in type. In association with this they all have small, variably thickened bladders with pressure studies showing raised pressure and instability. None showed the atonic picture of the traditional lower motor neurone bladder lesion. Theoretically this bladder lesion could be the result of cord or peripheral innervation problems. Although some children had evidence of higher cord lesions there were few upper motor neurone signs, and it is difficult to ignore the fact that their predominant neurological deficit was low lumbar and sacral. Our hypothesis is that the pattern of innervation imbalance which produces a thick walled, raised pressure, unstable bladder with

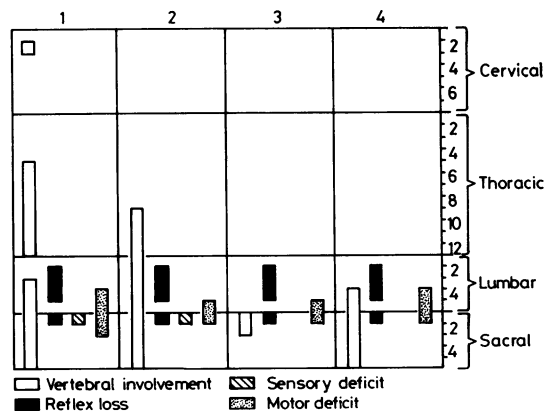


Fig. 5 (Cases 1–4.) A comparison of the vertebral, reflex, sensory, and motor abnormalities.

some lesions of the spinal cord may also be produced by a partial deficiency of lumbosacral innervation, and not therefore be due to an upper motor neurone lesion. From the pattern of motor deficit it could be expected that a major component of the peripheral lesion would be a loss or partial lesion of the parasympathetic.

We have no evidence in these patients of the effect of spinal surgery on bladder function.

### Conclusion

Four children in whom the diagnosis of spinal dysraphism was delayed, and in whom there was evidence of upper renal tract involvement at the time that the first bladder problem was manifest have been discussed. It is obviously very important that renal and bladder investigations are performed in any child in whom this diagnosis is made, and that spinal dysraphism is excluded in any child presenting with incontinence or foot deformity. The possibility of this type of thickened, small, unstable bladder occurring as a result of a defect of lumbosacral innervation rather than an upper motor neurone lesion is discussed.

We thank Dr C Chantler and Mr P Schurr for advice and assistance, and for allowing us to present patients under their joint care.

M B was supported by a grant from the Special Trustees of Guy's Hospital.

### References

- <sup>1</sup> Anderson F M. Occult spinal dysraphism: a series of 73 cases. *Pediatrics* 1975; **55**: 826-35.
- <sup>2</sup> Williams D I, Nixon H H. Agenesis of the sacrum. *Surg Gynecol Obstet* 1957; **105**: 84-8.
- <sup>3</sup> White R I, Klauber G T. Sacral agenesis—analysis of 22 cases. *Urology* 1976; **8**: 521-5.
- <sup>4</sup> Stark G D. Correlative studies of bladder function in myelomeningocele. *Dev Med Child Neurol [Suppl]* 1973; **15**: Supplement 29, 55-68.

Correspondence to Dr M Borzyskowski, Evelina Children's Department, Guy's Hospital, St Thomas Street, London SE1 9RT.

Received 11 December 1979