

Immotile cilia syndrome: a new cause of neonatal respiratory distress

ANDREW WHITELAW, ANDREW EVANS, AND BRYAN CORRIN

Division of Perinatal Medicine, Northwick Park Hospital and Clinical Research Centre, Harrow, Queen Mary's Hospital for Children, Carshalton, Surrey, and Department of Lung Pathology, Cardiothoracic Institute, London

SUMMARY Kartagener's syndrome is a condition that consists of situs inversus, bronchiectasis, and sinusitis. Some patients have respiratory symptoms that date from early infancy, and electron microscopical examination has shown that adults with this condition lack dynein arms in ciliary microtubules. It has been suggested that an inherited defect in ciliary ultrastructure, the immotile cilia, is the basis for the syndrome. We report 6 patients who presented within the first 24 hours of life with tachypnoea, retraction, rales, and dextrocardia. Five of them had situs inversus. They all responded to physiotherapy after antibiotics had failed to improve their condition. Electron microscopical examination of the cilia in 2 of the infants confirmed deficiency of dynein arms. All 6 infants had recurrent respiratory infections. Four went on to develop recurrent otitis media, 2 had sinusitis, and 1 now has bronchiectasis. The immotile cilia syndrome should be added to the list of causes of respiratory distress in newborn infants. The condition is worth diagnosing because of the good response to physiotherapy, and because of the likelihood of recurrent respiratory problems.

Kartagener's syndrome consists of situs inversus, bronchiectasis, and sinusitis. Many patients have had symptoms since childhood and symptomatic cases have been reported in neonates.^{1–6} There has been much debate on whether the bronchiectasis is truly congenital or is acquired after damaging infections in early life. However, Eliasson *et al.*⁷ have placed this disorder on a firm pathophysiological basis—the immotile cilia syndrome. There is evidence of impaired ciliary function, and electron microscopical examination shows disarray of ciliary microtubules and lack, or partial absence, of dynein arms, which are thought to be necessary for ciliary and sperm tail movements. It has been suggested that the fundamental abnormality in Kartagener's syndrome is a genetic defect in the ultrastructure of cilia. Situs inversus is thought to result from defective embryonic organ movement 10 to 15 days after implantation, and the bronchiectasis and sinusitis result from mucus retention and infection after birth.

We describe 6 neonates with dextrocardia; each of them developed respiratory distress with widespread moist rales in both lung fields. In all 6 there was accumulation of pulmonary secretions requiring physiotherapy for removal. Each had repeated

respiratory tract infections both lower and upper after the neonatal period. Two infants had electron microscopical evidence of partial deficiency of dynein arms and disarray of ciliary microtubules. We believe from our observations of these 6 patients, and from reviewing others, that this is a recognisable cause of pulmonary disease in neonates and deserves to be diagnosed because of the good response to physiotherapy and the hope that bronchiectasis can be prevented.

Case reports

Case 1. This boy is the first child of unrelated, healthy, white parents. His mother went into spontaneous labour at 38 weeks' gestation. There was no meconium in the liquor and a normal vaginal delivery followed. Birthweight was 2600 g and Apgar scores were 9 at one minute and 10 at five minutes. He developed tachypnoea, recession, grunting, and cyanosis in air at 6 hours. Examination showed a mucoid nasal discharge, heart sounds best heard to the right of the sternum, and bilateral rales and rhonchi. Chest x-ray film showed situs inversus and multiple small areas of atelectasis (Fig. 1). An electrocardiogram (ECG) showed mirror image

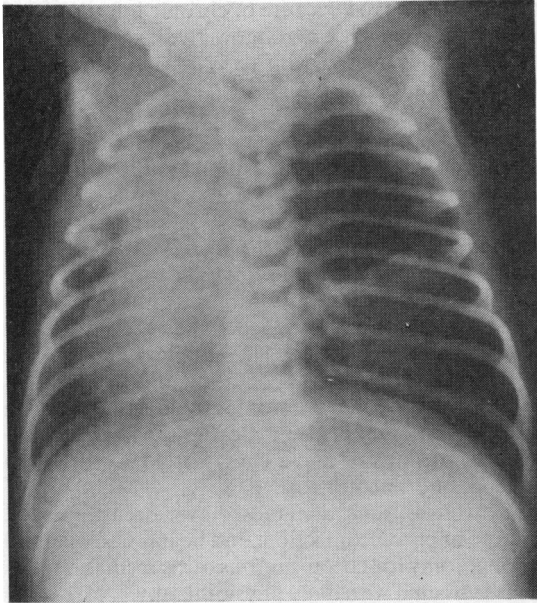


Fig. 1 (Case 1.) Chest x-ray film at 24 hours showing situs inversus and patchy shadowing in the right upper zone and left middle and lower zones.

dextrocardia and echocardiography showed normal cardiac anatomy. Cultures of throat and blood were negative. In 30% oxygen P_{aO_2} was 6.8 kPa (51 mmHg), PCO_2 6.8 kPa (51 mmHg), and pH 7.27. His condition did not improve despite intravenous ampicillin 200 mg/kg per day until chest physiotherapy was started at 48 hours. Immediately his rales and rhonchi cleared and his recession disappeared. Chest physiotherapy was continued and he was free of signs and symptoms except for periodic tachypnoea. If he did not have chest physiotherapy for one day however, his lungs developed rales and he became distressed. His parents were taught how to give chest physiotherapy and at 1 month he was able to go home. Apart from a chronic cough, he has remained well and thrives.

Case 2. This boy is the second child of healthy, unrelated Ugandan Asian parents. The first child, a girl, is healthy. He was delivered by elective caesarean section at 38 weeks' gestation because of cephalopelvic disproportion. Birthweight was 2610 g. He was intubated at birth because of apnoea but responded well to intermittent positive pressure ventilation, having an Apgar score of 9 at five minutes. The heart sounds were noted to be on the right of the sternum. By 4 hours, the respiratory rate had reached 100/minute and there were diffuse rales in both

lungs. Chest x-ray films showed situs inversus with minimal streaking in the left lower lobe. An ECG showed mirror image dextrocardia, and penicillin and gentamicin were started. However, his condition did not improve until he began to have chest physiotherapy. Blood culture was sterile and nose and throat swabs did not grow group B streptococci. He was discharged home to have regular physiotherapy and courses of oral antibiotics. In his first 8 months he had a constant cough, and 2 episodes of otitis media that were slow to resolve. He stopped antibiotics for the first time at 8½ months and developed fever, anorexia, worsening cough, and rales 2 weeks later. He continued with regular chest physiotherapy and during his second year had only 2 respiratory infections. Serum IgG and IgM were within normal limits but serum IgA was transiently low: <0.1 g/l at 6 months and 0.1 g/l at 7 months. Serum IgA was 0.2 g/l at 22 months. T-lymphocyte numbers were normal as was neutrophil chemotaxis (Dr David Webster). Sweat electrolytes were normal. Biopsy of nasal mucosa was carried out at 3 months. Electron microscopical examination showed disarray of ciliary microtubules and partial absence of dynein arms; these findings are similar to those reported in adults with Kartagener's syndrome.⁷

Case 3. This boy is the second child of healthy, white parents who are 2nd cousins. The pregnancy was uneventful and spontaneous labour with normal vaginal delivery occurred at 41 weeks. Birthweight was 3560 g and Apgar score was 8 at one minute. The respiratory rate gradually rose to 70/minute by 31 hours. Rales were heard throughout both lungs and a long grade 3/6 systolic murmur was best heard to the right of the sternum. Chest x-ray films showed dextrocardia and situs solitus. An ECG showed mirror image dextrocardia with dominant S-wave in V2 (V1 in laevocardia) and dominant S-waves across the precordial leads. Two-dimensional echocardiography (Dr M Rigby, Brompton Hospital) showed a common atrium with normal intraventricular septum and atrioventricular valves. Amoxycillin was given and the rales cleared after physiotherapy but recurred if physiotherapy was stopped. A right inguinal hernia was noted at age 1 month and at operation (at 7 weeks) a nasal biopsy was taken. Electron microscopical examination of the ciliary microtubules showed either lack, or pronounced deficiency, of dynein arms (Fig. 2). An intermittent cough persisted but on a programme of physiotherapy 3 times a day the child remained clinically clear.

Case 4. This girl is the first child of healthy, unrelated Asian parents. The pregnancy was normal. Onset

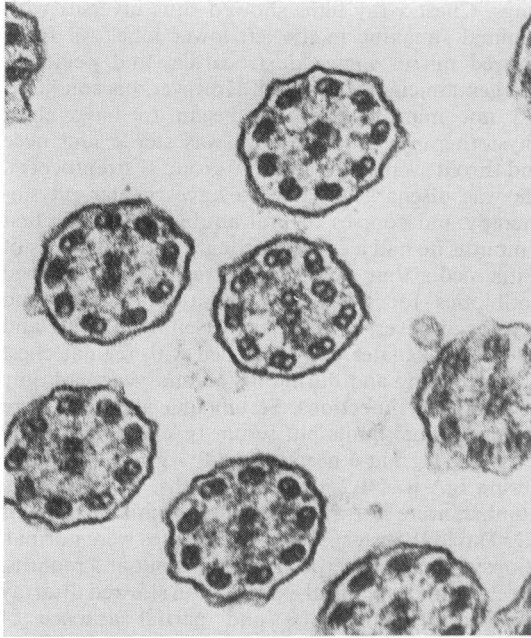


Fig. 2 (Case 3.) Electron micrograph of nasal mucosa showing that the outer microtubules lack dynein arms or that the arms are extremely blunted. $\times 100\ 000$.

of labour was spontaneous, and delivery was by Kielland's forceps for fetal distress. There was no meconium staining of the amniotic fluid. Birthweight was 3045 g. Apgar score was 6 at one minute and 9 at five minutes. Tachypnoea and subcostal recession developed within 24 hours of birth and scattered rales were heard in both lung fields. Chest x-ray films and barium meal showed total situs inversus. An ECG showed mirror image dextrocardia. She was very irritable and a lumbar puncture showed uniformly blood-stained CSF but all bacterial cultures were negative. She was treated with ampicillin and cloxacillin but 5 days later tachypnoea and cough were still present, and a chest x-ray film showed patchy consolidation of the right upper lobe. Physiotherapy was started and her condition improved, although cough and feeding difficulty were still present at 28 days. She developed infantile eczema which has now almost cleared.

She was seen again at 4½ years with chronic cough with vomiting, wheeze, purulent nasal discharge, and bilateral conduction deafness. Examination showed a normally grown child with a hyperinflated chest and bilateral Harrison's sulci, and bilateral chronic serous otitis media. There was radiological evidence of bronchiectasis, and of chronic sinusitis which has needed antral washouts. Her tonsils and adenoids

have been removed because of chronic infection, and she has required a left myringotomy.

She is now treated with daily physiotherapy and continuous antibiotics.

Case 5. This child is the younger brother of Case 4. Pregnancy was uneventful resulting in the delivery of a 3160-g term infant. Apgar score was 9 at one minute and 10 at five minutes. His respiratory rate reached 80/minute at 20 hours. Chest x-ray film showed situs inversus and an ECG showed mirror image dextrocardia. Infection screen, echocardiogram, sweat sodium, and cine radiography of the oesophagus were normal. He remained tachypnoeic for 2 months and then his condition improved.

At 2½ years he had a chronic cough with wheezing and bilateral conduction deafness. There is no evidence of sinusitis and a chest x-ray film shows no evidence of bronchiectasis.

His tonsils and adenoids have been removed because of chronic infection, and he has had bilateral myringotomy for chronic serous otitis media.

He is treated with daily physiotherapy.

Case 6. This girl was born at term by Anderson's forceps delivery for delay in the second stage. Birthweight was 3530 g. Apgar scores were 8 at one minute and 10 at five minutes.

In the first 24 hours she developed cyanosis with feeding, tachypnoea with a rate of 60–70/minute, subcostal recession, and bilateral rhonchi and rales.

Chest x-ray films showed clear lung fields. The total situs inversus was not recognised. Infection screen was negative.

The cyanosis and subcostal recession had settled by day 6, but bilateral rales persisted until the 11th day. No specific treatment was given. By the 20th day she had developed a nasal discharge.

She is now 5½ years and has a history of continuous mucopurulent nasal discharge, recurrent chest infections, wheezing, serous otitis media, recurrent tonsillitis, and chronic constipation. Her height is on the 75th centile and her weight is on the 10th centile. Chest x-ray film shows no evidence of pulmonary disease. Her sweat sodium and immunoglobulins are normal.

She is on no regular treatment and is awaiting tonsillectomy.

Discussion

Cilia line the epithelium not only of the trachea, bronchi, and nasopharynx, but also of the Eustachian tubes, fallopian tubes, and cerebral ventricles. In the immotile cilia syndrome the sperm are immotile, the dynein arms being necessary for sperm tail

movement. Defective embryonic cilia are thought to result in random lateralisation of the viscera with half having laevocardia and half having dextrocardia.⁷ This suggestion is supported by the finding of siblings of patients with Kartagener's syndrome, who have bronchiectasis and sinusitis but do not have situs inversus.

Our ultrastructural findings are similar to those described by Eliasson *et al.*⁷ for the immotile cilia syndrome. Fox and Bull⁸ reported similar findings in normal controls and it is evident that more ultrastructural studies of normal subjects are required before the significance of dynein arm deficiency can be established.

Nichamin¹ reported the onset of Kartagener's syndrome at age 33 hours with cyanosis, retraction, mucopurulent material in the nostrils, diffuse rales, situs inversus, and atelectasis in the right lung. Holmes *et al.*⁴ described 8 cases of Kartagener's syndrome, 7 of whom had mucoid nasal discharge in the neonatal period, and 2 chronic serous otitis media in childhood. Schoemperlen and Carey² described a case of Kartagener's syndrome with the onset of cyanosis and respiratory distress at 5 days of life. Hartline and Zelkowitz⁶ described a case of Kartagener's syndrome with onset of symptoms at 2 days. Monnet⁵ described 4 newborn infants with situs inversus and respiratory difficulties, 1 of whom had rales and 3 had areas of atelectasis.

The 6 patients that we have described all presented within the first 24 hours of life with tachypnoea, retraction, rales, and dextrocardia. Five of them had situs inversus. All 6 responded to physiotherapy after antibiotics had failed to improve their condition and each had recurrent respiratory problems. Cases 2, 4, 5, and 6 had otitis media that was particularly slow to resolve, consistent with impaired middle-ear drainage as described by Fischer *et al.*⁹ We believe that the clinical findings in our 6 patients are likely to have been caused by impaired mucus

clearance, and that the immotile cilia syndrome should be added to the list of causes of respiratory distress in the newborn. Recognition of the syndrome is worthwhile because of the good response to physiotherapy. Regular physiotherapy and prompt antibiotic treatment of respiratory infection offer the best hope of preventing permanent lung damage.

We thank John Fentem, Asit Das, and Anne Dewar for assistance with electron microscopy, and Dr David Harvey and Dr Patrick Cox for encouraging us to report patients under their care.

References

- ¹ Nichamin S J. Kartagener's syndrome in a newborn infant. *JAMA* 1956; **161**: 966-8.
- ² Schoemperlen C B, Carey S L. Kartagener's syndrome. *Am Rev Respir Dis* 1963; **88**: 698-702.
- ³ Marland P, Descomps H, Rigaut J P. Le syndrome de Kartagener et le problème étiopathogénique des bronchiectasies idiopathiques (à propos d'un cas familial). *Poumon et Coeur* 1967; **23**: 41-68.
- ⁴ Holmes L B, Blennerhassett J B, Austen K F. A reappraisal of Kartagener's syndrome. *Am J Med Sci* 1968; **255**: 13-28.
- ⁵ Monnet P. Situs inversus et bronchopneumopathies au long cours, des la période neonatale. *Arch Fr Pediatr* 1978; **35**: 607-19.
- ⁶ Hartline J V, Zelkowitz P S. Kartagener's syndrome in childhood. *Am J Dis Child* 1971; **121**: 349-52.
- ⁷ Eliasson R, Mossberg B, Camner P, Afzelius B A. The immotile cilia syndrome. *N Engl J Med* 1977; **297**: 1-6.
- ⁸ Fox B, Bull T B. Electron microscopic structure of human cilia: what is normal? (abstract). *J Clin Pathol* 1979; **32**: 969-70.
- ⁹ Fischer T J, McAdams J A, Entis G N, Cotton R, Ghory J E, Ausdenmoore R W. Middle ear ciliary defect in Kartagener's syndrome. *Pediatrics* 1978; **62**: 443-5.

Correspondence to Dr A Whitelaw, Department of Paediatrics and Neonatal Medicine, Hammersmith Hospital, Du Cane Road, London W12 0HS.

Received 23 April 1980