

Umbilical cord serum creatine kinase BB in the diagnosis of brain damage in the newborn: problems in interpretation

B KUMPEL, S M WOOD, P P ANTHONY, AND F S W BRIMBLECOMBE

Paediatric Research Unit, Royal Devon and Exeter Hospital (Heavitree), Postgraduate Medical School, Barrack Road, and the Area Department of Pathology, Heavitree, Exeter

SUMMARY Raised values of creatine kinase BB (CKBB) in umbilical cord serum were obtained with some normal babies and those with fetal distress. Further investigation showed that the umbilical artery and vein tissue contain high CKBB activity, indicating that some cord blood samples may not solely reflect CKBB liberated from the brain.

Research in Cambridge has found that raised serum concentrations of creatine kinase BB (CKBB) may reflect brain injury in adults.¹ We investigated the possibility that CKBB in umbilical cord serum may similarly give an indication of perinatal brain damage. Previous reports have stated that cord serum CKBB values were slightly raised in preterm infants and those with fetal distress,^{2,3} but there was considerable overlap in the range of values.

Methods

Blood samples were taken by venepuncture from the umbilical veins of 87 cords after delivery. Extracts of tissues were made in physiological saline and the supernatant analysed. CKBB activity in sera and tissue extracts was calculated from the total creatine kinase activity (measured kinetically) and the percentage of CKBB estimated quantitatively by densitometer, after cellulose acetate electrophoresis. Localisation of CKBB in umbilical cords was shown by immunohistochemistry using a modification of the indirect immunoperoxidase method.⁴

Results

Although most umbilical cord sera had CKBB values that came within a fairly broad range, below 100 U/l, a few samples had high activities which could be associated with various obstetric problems and fetal distress. Some sera with high CKBB activity came, however, from babies with neither clinical problems nor signs of asphyxia, and in these cases difficulty was experienced in obtaining more than about 1 ml of blood from unclamped cords. The possibility that the high values of CKBB might have more to do with the method of blood sampling than

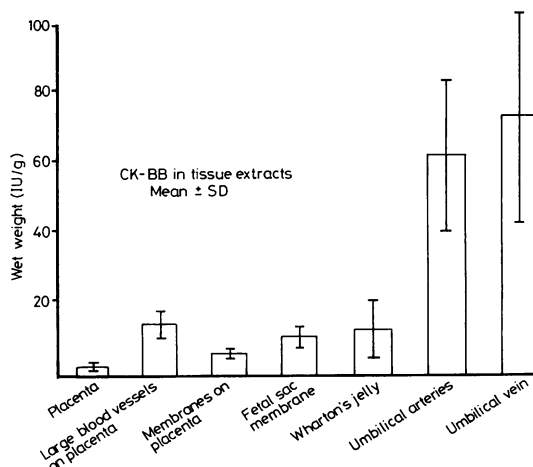


Figure CKBB activity in components of placenta and umbilical cord ($n=7$).

the clinical state of the infant was investigated by determining the activity of CKBB in the tissues of the umbilical cord and placenta (Figure). This showed that the vessel walls of both the umbilical artery and vein had high enzyme activity, significantly greater ($P < 0.001$) than the other tissues analysed, including the large blood vessels of the placenta.

Localisation of CKBB in the umbilical cord by immunohistochemistry showed that the greatest activity was in the walls of the arteries and veins. There was also some activity in the endothelium, and the stellate cells scattered throughout Wharton's jelly showed positive CKBB activity.

Discussion

The presence of CKBB in umbilical arteries and veins suggests that CKBB can leak into the blood if these tissues are damaged; it would take only a small amount of tissue with high CKBB activity to give an erroneously high cord blood value. This may explain the inconsistent results of other workers studying cord blood CKBB values in normal and high risk babies. We have found that to obtain

reliable cord blood samples for CKBB analysis the cord must be clamped in two places about 20 cm apart at delivery, and that by careful venepuncture only the first few millilitres of blood should be used for CKBB estimation.

We thank the staff of the Maternity Unit, Royal Devon and Exeter Hospital, and the Department of Biological Sciences, University of Exeter, for co-operation.

This work was supported by the Children's Research Fund and the Northcott Devon Medical Foundation.

References

¹ Phillips J P, Jones H M, Hitchcock R, Adams N,

Thompson R J. Radioimmunoassay of serum creatine kinase BB as an index of brain damage after head injury. *Br Med J* 1980; **281**: 777-9.

² Chemnitz G, Nevermann L, Schmidt E, Schmidt F W, Lobers J. Creatine kinase (EC-No. 2.7.3.2.) and creatine kinase isoenzymes during pregnancy and labour and in the cord blood. *Clin Biochem* 1979; **12**: 277-81.

³ Cuestas R A, Jr. Creatine kinase isoenzymes in high risk infants. *Pediatr Res* 1980; **14**: 935-8.

⁴ Burns J. Background staining and sensitivity of the unlabelled antibody-enzyme (PAP) method. Comparison with the peroxidase labelled antibody sandwich method using formalin fixed paraffin embedded material. *Histochemistry* 1975; **43**: 291-4.

Correspondence to Dr B Kumpel, Paediatric Research Unit, Royal Devon and Exeter Hospital (Heavitree), Gladstone Road, Exeter, Devon EX1 2ED.

Received 21 December 1982

Obstructive jaundice secondary to chronic midgut volvulus

L SPITZ, J D ORR, AND J T HARRIES

Hospital for Sick Children, Gt Ormond Street, London

SUMMARY A case of progressive extrahepatic biliary obstruction due to chronic midgut volvulus secondary to malrotation in a 5-month-old girl is presented. The obstruction to the bile duct was relieved after correction of the malrotation and division of the obstructing bands.

Malrotation with associated Ladd's bands is a common cause of extrinsic obstruction to the second part of the duodenum in infancy and early childhood.¹ This results in bilious vomiting which is usually the initial and may be the sole presenting feature of the anomaly. The jaundice that has been noted in association with malrotation is invariably described as a consequence of intestinal gangrene secondary to midgut volvulus.^{2,3} Mechanical obstruction to the extrahepatic biliary tract secondary to malrotation has not been previously reported.

Case report

A 5-month-old girl was referred for investigation of failure to thrive, persistent diarrhoea, and progressive jaundice. She was the first-born infant after a normal pregnancy and delivery, and weighed 3340 g. At age 2 days she vomited bile-stained material but a straight x-ray film of the abdomen

was normal. The vomiting continued for a further 3 days but contained only milk. After discharge from the maternity unit she continued to feed poorly and vomit intermittently. At 3 months she developed explosive diarrhoea which persisted in hospital despite a variety of diets. A barium meal showed gross gastro-oesophageal reflux but was otherwise interpreted as normal. Jaundice was first noted at 5 months and serial liver function tests showed a progressive conjugated hyperbilirubinaemia.

Weight on admission was 5300 g at 5 months (<3rd centile). Abdominal examination showed a 2 cm globular-shaped cystic mass in the right hypochondrium and a 2 cm palpable hepatomegaly. Laboratory investigations showed a total bilirubin of 199 $\mu\text{mol/l}$ (11.6 mg/100 ml), alkaline phosphatase 293 KA units/100 ml, AST 400 IU/100 ml, total protein 400 g/l (albumin 222 g/l), alpha-1-antitrypsin activity 3.2 (normal range 2.0-4.0) g/l, and a sweat sodium concentration of 10 mmol/l.

Ultrasound scan of the liver showed grossly dilated intra- and extra-hepatic bile ducts, and the common bile duct was grossly dilated proximally but distally narrowed to a fine stricture; the gallbladder was distended and contained 'sludge'.

Laparotomy via a right upper quadrant transverse muscle-cutting incision revealed a tensely distended gallbladder and common bile duct to a maximum diameter of 1.5 cm. Cholangiogram via the gall-