

Limited finger joint mobility in diabetes

J E H BRICE, D I JOHNSTON, AND J L NORONHA

University Hospital and City Hospital, Nottingham

SUMMARY Limited finger joint mobility was assessed in 112 diabetic children, in their first-degree relatives, and in 50 unrelated non-diabetic children. In 42% of the diabetic children there was limited joint mobility, but 14% of them had more severe involvement. Limited joint mobility was correlated with increasing age, early presentation, and longer duration of diabetes. First-degree relatives of affected diabetic children had a higher incidence (35%) of limited joint mobility compared with relatives of non-affected diabetic children (13%).

Limited joint mobility or deformity was described in early reports of diabetic dwarfism and was assumed to indicate poor metabolic control. Recently limited joint mobility has been increasingly recognised among insulin-dependent or type 1 diabetics with better diabetic control. Rosenbloom's group¹ found limited joint mobility of the hands in 28% of juvenile diabetics attending a diabetic camp. Other groups have reported a prevalence rate of 0–32%.^{2–6} We have studied limited joint mobility in the hands of children attending a diabetic clinic, and compared the results with the hands of their families, and with the hands of unrelated non-diabetic children attending hospital.

Subjects and methods

We studied 112 diabetic children aged between 2 and 16 years, in whom the duration of diabetes was between 2 months and 14 years, together with 214 first-degree relatives, and 50 unrelated non-diabetic children aged between 3 and 16 years. Each was asked to place his hands together in a 'prayer-like' position and the ability to oppose the full palmer surfaces of the fingers was assessed. In addition, each was asked to place both hands palms down with fingers fanned on to the desk top and the ability to oppose the fingers to the flat surface was assessed. Finger joint deformity for each finger was recorded and graded from 0 to 2: grade 0 if there was no joint flexion deformity, grade 1 if there was mild flexion deformity which was correctable by passive manipulation, grade 2 if there was a more severe fixed deformity which was not correctable by passive manipulation (Figure). These techniques were simple

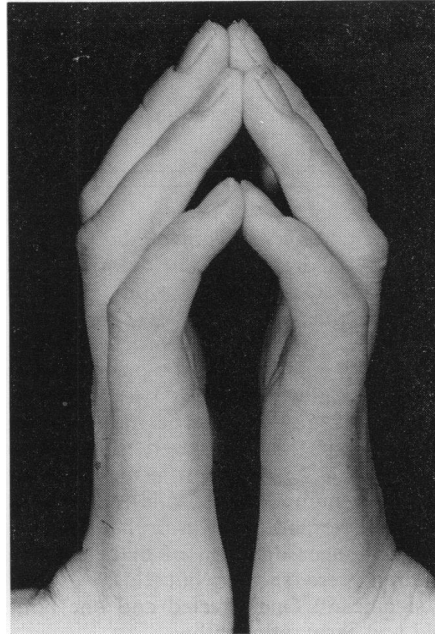


Figure 'Prayer-like' position showing severe grade 2 involvement of all fingers and not correctable with manipulation

and easily reproducible. Other information was obtained from clinical records.

Results

Forty-seven (42%) of the children examined had some finger flexion deformity (Table). Boys and girls were equally affected. The majority had minor (grade 1) involvement of the 5th fingers, fourth- and third-finger involvement occurring less often. The Table gives data for the 16 (14%) children with more severe involvement, having either grade 2 (4 children) of at least one finger, or grade 1 (12 children) of 3 fingers of each hand. The children with finger flexion deformity were significantly older ($P < 0.02$), their diabetes had presented at a younger age ($P < 0.05$), and consequently they had had diabetes for longer ($P < 0.001$) than children without flexion deformity. This trend was accentuated in the children with more

Table 112 diabetic children examined

	Finger flexion		With grade 2 or 3 fingers grade 1 each hand
	Children without	Children with	
Age (years) (\pm SD)	65 (58%) 10.3 (\pm 3.8)	47 (42%) 11.8 (\pm 2.6)	16 (14%) 12.3 (\pm 2.0)
	P < 0.02		
Age of onset (years) (\pm SD)	6.9 (\pm 3.6)	5.5 (\pm 3.3)	5.1 (\pm 3.4)
	P < 0.05		
Duration (years) (\pm SD)	3.3 (\pm 2.7)	6.3 (\pm 3.4)	7.2 (\pm 3.6)
	P < 0.01		

severe involvement. After 7 years of diabetes the majority (78%) of children had some deformity. All 4 children with grade 2 fixed deformity had had diabetes for longer than 7 years.

The mean HbA_{1c} percentage recorded from 3-monthly clinic visits made during the previous year was similar in the affected (13% \pm 1.8) and non-affected children (12.5% \pm 1.8). The mean insulin doses at the time of the study were similar too (0.9 \pm 0.2 and 0.8 U/kg \pm 0.2). Affected children had had a greater number of hospital admissions because of the diabetes, but this was probably only a reflection of the longer duration of diabetes. The affected children were shorter but this was not statistically significant. One affected and one non-affected child had early retinopathy.

There was an increased incidence of finger flexion deformity in the parents and siblings of affected diabetic children. Thirty-five per cent of the examined relatives of affected children were similarly affected, compared with 13% of relatives of the non-affected diabetic children. Only 1 (2%) of the 50 unrelated non-diabetic children of similar age attending hospital had grade 1 deformity of both 5th fingers.

Discussion

The prevalence of limited joint mobility was higher in our population of diabetic children (42%) than previously reported. The majority of our affected children had minor (grade 1) involvement of only the 5th finger. Although our method of examination was similar to that of Grgic *et al.*¹ it is possible that we included more children with minimal involvement. The incidence of more severe involvement (14%) was similar to that reported by the same group of workers.¹ We also noted 'waxy' thickened skin and other larger joint involvement in a few children, but did not systematically quantify them.

The strong correlation of limited joint mobility

with duration and early onset of diabetes agreed with previous reports.^{1,3,7} A correlation between limited joint mobility and diabetic management or development of other complications could not be shown in our population. Although limited joint mobility was strongly correlated with duration of diabetes, some children developed this complication early while others had many years of sometimes unstable diabetes without this complication developing. This suggests that other factors, possibly heredity, are important.

Traisman *et al.*⁴ showed a similar incidence (8.4%) of limited joint mobility in diabetic children and in their non-diabetic siblings (9.4%). The incidence in their control population was 2%, the same as our incidence. Our family studies have shown that diabetic children with limited joint mobility are more likely to have a similarly affected parent or sibling (35% of relatives) than non-affected children (13% of relatives).

Increased glycosylation and cross-linking of periarthicular collagen has been suggested as the cause of limited joint mobility.⁸ Similar collagen abnormalities may possibly be important in the development of microvascular complications. We could not demonstrate a correlation between limited joint mobility and microvascular complications although other workers⁹ have. Our results suggest that familial factors may be important in the individual variable development of limited joint mobility with duration of diabetes. Further study is necessary to determine if a familial tendency to limited joint mobility is correlated with later microvascular complications.

References

- Grgic A, Rosenbloom A L, Weber F T, Giordano B, Malone J J, Shuster J J. Joint contracture—common manifestation of childhood diabetes mellitus. *J Pediatr* 1976; **88**: 584–8.
- Beacom R, Kennedy L, Carson D, Campbell S L. Joint contractures in Type I (insulin dependent) diabetes. In the proceedings of the British Diabetic Association Medical and Scientific Section meeting, Exeter, September 1981.
- Benedetti A, Noacco C. Hand changes in childhood onset diabetes. *Paediatr Adolesc Endocrinol* 1981; **9**: 149–55.
- Traisman H S, Traisman E S, Marr T J, Wise J. Joint contractures in patients with juvenile diabetes and their siblings. *Diabetes Care* 1978; **1**: 360–1.
- Jackson R J, Holland E, Chatman I D, Guthrie D, Hewett J E. Growth and maturation of children with insulin dependent diabetes mellitus. *Diabetes Care* 1978; **1**: 96–107.
- Anonymous. Stiffness of the hand in diabetes. *Lancet* 1981; **ii**: 1027–8.
- Rosenbloom A L, Silverstein J H, Lezotte D C, Richardson K, McCallum M. Limited joint mobility in childhood diabetes mellitus indicates increased risk for microvascular disease. *N Engl J Med* 1981; **305**: 191–4.

⁸ Buckingham B A, Uitto J, Sandborg C, Keens T, Kaufman F, Landing B. Scleroderma-like syndrome and the non-enzymatic glucosylation of collagen in children with poorly controlled insulin-dependent diabetes (IDDM). *Pediatr Res* 1981; **15**: 626.

Correspondence to Dr J E H Brice, Green Wood Children's Centre, City Hospital Hucknall Road, Nottingham NG5 1PD.

Received 16 July 1982

Congenital generalised fibromatosis

NEENA MODI

Medical Paediatric Unit, Western General Hospital, Edinburgh

SUMMARY A case of congenital generalised fibromatosis is described. The need to avoid unnecessary treatments is stressed.

Congenital generalised fibromatosis is a rare disease which presents in the newborn period. Multiple nodules of fibrous tissue are formed in muscle, bone, subcutaneous tissue, and viscera. Only 33 cases have been described.

Case report

A baby girl, delivered at term, was found on routine initial examination to have a rubbery 3-cm nodule overlying the posterior iliac crest. In addition, five 3-cm circular, pigmented macules were scattered over the back and buttocks. There was no lymphadenopathy or hepatosplenomegaly and the baby was clinically well. Her 25-year-old mother had been in good health throughout pregnancy and exposed to no drugs or toxic substances. On the baby's second day of life another nodule appeared and by the next day there were 2 more. The pigmented macules darkened and new lesions appeared. The original nodule increased in size to 9 cm in diameter. All investigations including biochemistry, haematology, bone marrow, and radiographs of the chest were normal. The largest tumour was excised but apart from confirming that it was locally invasive the histopathology proved difficult to interpret. For this reason tumour sections were sent to several centres around the world. The sections showed pronounced variation from field to field. The non-encapsulated, cellular neoplasm was predominantly fibroblastic but contained numerous thin-walled vascular spaces. Areas of necrosis were present. Some areas had a predominantly angiomatous appearance and some a neural appearance.

In view of the uncertainty about their nature, and the fact that the tumours were known to be locally invasive, the decision whether to recommend multiple excision remained. However on the baby's seventh day one of the nodules appeared to be

decreasing in size; by the end of the second week there was no doubt about the clinical regression. At age one month the baby developed a nappy rash with superimposed staphylococcal sepsis; the nodules continued to regress. At 2 months no palpable nodules remained. At 3 months she required admission for severe seborrhoeic dermatitis and diarrhoea, but responded well to conservative treatment. At 4 months her mother attempted suicide in the belief that her child was suffering from cancer. At 7 months she remains well, with no evidence of active disease. Biochemistry, haematology, serum immunoglobulins, bone scan, and skeletal survey are normal.

The pathological opinions received included the following diagnoses: 'fibrous type tumour', haemangioendothelioma, haemangiopericytoma, angiomatous mesenchymoma, and congenital generalised fibromatosis. A search of the literature confirmed that both on clinical and histopathological grounds a diagnosis of congenital generalised fibromatosis could be made.

Discussion

Congenital generalised fibromatosis, although rare, is well defined clinically and histologically. Of the 33 cases cited, the majority come from America and a few from France, Germany, and Australia.¹⁻³ The term was first used by Stout in 1954 to describe two rapidly fatal cases. Eleven years later Kauffman and Stout, reviewing their own cases, distinguished two groups dependent on the presence or absence of visceral involvement.⁴ In both groups presentation is in the newborn period with widespread, multiple, rubbery nodules. There is often a dominant nodule; solitary lesions also occur.⁵ The clinical course of the lesions is to enlarge initially but ultimately to regress. In the so-called generalised group (with visceral involvement) survival is poor and death, invariably in the first year of life, owing to the involvement of vital structures during the phase of active growth and regression, producing for example, respiratory failure,³ intestinal obstruction,² renal masses,⁶ and