

Loperamide in severe protracted diarrhoea

B K SANDHU, J H TRIPP, P J MILLA, AND J T HARRIES

The Hospital for Sick Children, Great Ormond Street, and Institute of Child Health, London

SUMMARY Six infants with severe life-threatening protracted diarrhoea were treated with loperamide. Steady-state perfusion studies of the jejunum showed that in 2 of them the small intestine was in a net secretory state with respect to water, and in the others this was inferred from the fact that the diarrhoea persisted despite nothing by mouth. Loperamide resulted in a prompt and impressive improvement in the condition of each infant. We conclude that this drug has an important role in the management of protracted diarrhoeal states in some infants who are unresponsive to current treatments, and that its effect is related to its antisecretory action.

Loperamide (Imodium), an opiate analogue, has been shown to be an effective antidiarrhoeal agent in adults,¹⁻⁵ its effect being attributed to an action on smooth muscle and intestinal motility.^{6, 7}

However, our clinical observations which are reported in this paper prompted us to question whether the drug also had an effect on the intestinal absorption of fluid and electrolytes in the experimental animal, and it was subsequently shown to be a potent antisecretory agent.⁸⁻¹¹

The pathogenesis and management of certain protracted diarrhoeal states in infancy continue to pose important questions, and morbidity and mortality may be very high.¹²⁻¹⁶

In this paper, we report 6 infants with severe and life-threatening protracted diarrhoea who were successfully treated with loperamide.

Materials and methods

Dosage of loperamide. The daily mean \pm 1 SD dosage of loperamide in the 6 patients was 1.26 ± 0.94 mg/kg actual body weight, and 0.68 ± 0.44 mg per expected (that is assuming weight to be on the 50th centile for age) body weight. The total daily amount of administered loperamide was given in divided doses (see below).

Perfusion studies. Steady-state perfusion studies were performed in 20-cm segments of proximal jejunum using a double lumen tube at a rate of 8 ml/min as previously described.¹⁷ All the solutions perfused contained polyethylene glycol (4000) 3 g/l, KCl

4 mmol/l, NaHCO₃ 25 mmol/l, and either no added sugar or fructose 20 mmol/l and glucose 2 mmol/l, or glucose 56 mmol/l. The solutions were then made isotonic by the addition of NaCl and gassed with CO₂ to a pH of 7.

Case reports.

Case 1

He was the third child of healthy unrelated parents, born at term by caesarean section weighing 2.8 kg; there were no neonatal problems and no relevant family history. He remained well until age 9 months when he developed severe watery diarrhoea which necessitated admission to hospital and treatment with intravenous fluids. *Escherichia coli* and *Shigella sonnei* were cultured from the stools. He passed 400-600 ml of stool daily despite nothing by mouth. His condition deteriorated with electrolyte imbalance and generalised convulsions, and was transferred to The Hospital for Sick Children at age 9.5 months. On arrival his weight was 7.2 kg (<3rd centile), he was severely dehydrated with cold extremities, and was semicomatose. After resuscitation and rehydration, parenteral nutrition was started via a central vein and he continued to pass 400-600 ml of stool daily while having nothing by mouth. No pathogens were cultured from the stools. Normal results were obtained from the following investigations which included a full immunological screen, jejunal biopsy, cultures of jejunal juice, and plasma vasoactive intestinal peptide hormone. A perfusion study showed net

jejunal secretion of water which was greatly reduced by the addition of glucose (56 mmol/l) to the perfusate (Table). The addition of loperamide (16 mg/l) to the perfusate had no effect on secretion during the subsequent 2-hour perfusion period, and this was presumably owing to an effect of loperamide which is time related; the addition of glucose to the perfusate again modified net secretion of fluid in a reproducible fashion. A striking reduction in daily stool volume was noted the next day but 48 hours later it had returned to preperfusion level (Fig. 1). In view of this observation, loperamide in a dose of 8 mg/day (1 mg/kg per 24 hours) was given orally in 4 divided doses, and again a similar reduction in stool volume occurred (Fig. 1); 48 hours later a maintenance dose of loperamide, 1 mg twice a day

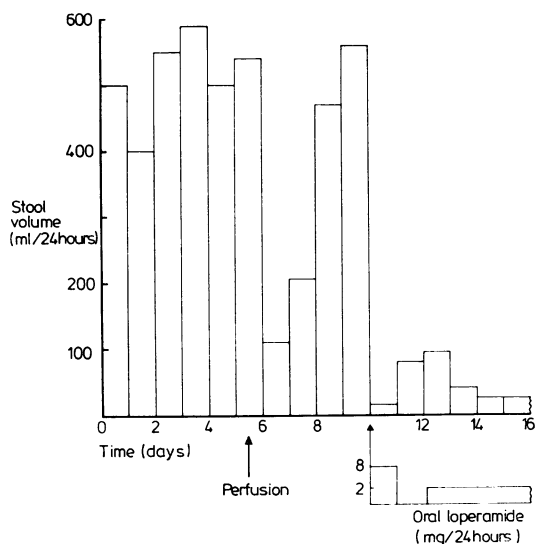


Fig. 1 Effect of loperamide on stool volume in Case 1.

(0.25 mg/kg per 24 hours) was instituted. He was now 11 months and weighed 8 kg. Oral feeds were introduced during the next few days, consisting of a comminuted chicken-based formula.¹⁸ Parenteral nutrition was stopped, he gained weight, and was discharged home at 14 months weighing 10.2 kg (25th–50th centiles). A normal diet was introduced at 18 months and loperamide was stopped without event at age 19 months.

Our experience with this patient prompted us to use loperamide in other infants with severe life-threatening protracted diarrhoea that was unresponsive to a variety of dietary manipulations and pharmacological agents (for example antibiotics, prednisolone, cholestyramine, amphotericin) and which persisted when the patients were receiving nothing by mouth. We report a further 5 successfully treated cases.

Case 2

He was transferred to us from Malta at age 5 months, because of protracted diarrhoea since birth; he was considered to have fallen within the category of 'lethal familial protracted diarrhoea' as previously reported by us,¹⁵ and was referred to in that report in the addendum. Extensive investigations failed to show an established cause for the diarrhoea. Perfusion studies demonstrated net secretion of water, and defective absorption of glucose and fructose (Table). Diarrhoea persisted despite nothing by mouth and parenteral nutrition was necessary, as for Cases 3, 4, and 5. At age 21 months he weighed only 5 kg, daily stool volume varied between 200 and 600 ml, and he remained dependent on parenteral nutrition. At 22 months loperamide was introduced in a dose of 2 mg 4 times a day (1.5 mg/kg per day) and there was a rapid reduction in stool volume to 30–80 ml daily within 24 hours (Fig. 2). Oral feeding with a chicken-based formula¹⁸ was started, parenteral nutrition was stopped, and he began to

Table Jejunal perfusion studies in Cases 1 and 2

Case	Solutions perfused	Net absorption rates		
		Water (μ l/min per cm)	Glucose (μ mol/min per cm)	Fructose (μ mol/min per cm)
1	Bicarbonate/saline	-137.5	—	—
	Bicarbonate/saline \pm 56 mmol/l glucose	-46.0	+1.45	—
	Bicarbonate/saline + 16 mg/l loperamide	-110.2	—	—
	Bicarbonate/saline + 56 mmol/l glucose + 16 mg/l loperamide	-40.6	+1.24	—
2	Bicarbonate/saline + 2 mmol/l glucose + 20 mmol/l fructose	-30.1 (+47.1 \pm 7.0)	+0.23 (+0.58 \pm 0.02)	+0.85 (+2.19 \pm 0.08)

— = secretion, + = absorption.

Values in parentheses indicate control values (mean \pm 1 SEM; n=9): 4 boys, 5 girls aged 3 months to 7 years, with the irritable bowel syndrome.

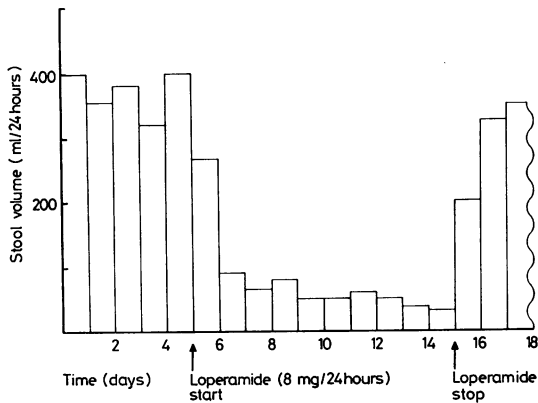


Fig. 2 Effect of loperamide on stool volume in Case 2.

gain weight. Two weeks later an attempt was made to stop loperamide but this resulted in recurrence of diarrhoea (Fig. 2). Reintroduction of loperamide did not immediately control the diarrhoea, and a further period of parenteral nutrition was necessary; loperamide was continued and the diarrhoea resolved. He was eventually discharged at 29 months weighing 6.1 kg on loperamide (1 mg/kg per day) and a diet comprising Pregestamil and Baby Rice, and he thrived. On returning to Malta, an entirely normal diet was introduced and loperamide stopped. He was said to be doing well on no treatment when at age 3 years he suddenly became ill and died; the cause of death is not known.

Case 3

She was referred to us aged 3 weeks because of diarrhoea since birth. After a normal pregnancy and delivery she had been born at 37 weeks' gestation weighing 2.5 kg and there was no relevant family history. Breast feeding was supplemented with Cow and Gate Premium milk preparation. On admission she weighed 2.3 kg (<3rd centile) and parenteral nutrition was started. Extensive investigations failed to find a cause for the diarrhoea and these included electron microscopical examination and culture of stools, an immunological screen, barium studies, chest x-ray film, and rectal and jejunal biopsies. Parenteral nutrition was continued for 3 weeks. At 2 months she was receiving the chicken-based formula but her stools remained loose and frequent (8–12 a day) and there was no weight gain. Treatment with loperamide, 1 mg 4 times a day (1.3 mg/kg per day) reduced stool frequency (2–4 a day) and changed the consistency within 48 hours and she began to thrive. She was discharged aged 5 months, on loperamide 0.5 mg 4 times a day

(0.5 mg/kg per day) weighing 4.1 kg, and it was possible gradually to stop the drug and concomitantly introduce a normal diet during the subsequent 4 months.

Case 4

She had been born at term after a normal pregnancy and delivery to healthy unrelated parents weighing 2.9 kg; the neonatal period was uneventful, and there was no relevant family history. From soon after birth there were intermittent episodes of diarrhoea and dehydration which did not respond to various dietary manipulations, and she was referred to us at age 3.1 months. Investigations led to a diagnosis of short segment Hirschsprung's disease and an associated mid-gut malrotation. Parenteral nutrition was instituted before surgery at 5 months, when the malrotation was corrected (Ladd's procedure), and a left transverse colostomy performed. Postoperatively, the chicken-based formula was introduced and she was discharged home at 6 months weighing 4.9 kg. Thereafter she developed recurrent episodes of watery colostomy effluent (300–600 ml/day) in association with failure to thrive, which necessitated readmission for parenteral nutrition. At age 14 months when she weighed 5.6 kg (<3rd centile), loperamide was started in a dose of 2 mg 4 times a day (1.4 mg/kg per day); on this dose colostomy output within 12 hours fell to 100–150 ml/day, and she began to thrive. At 16 months, she was discharged (7.2 kg) on the chicken-based formula and loperamide, 2 mg 4 times a day (1.1 mg/kg per day). The colostomy was closed at 2 years when she weighed 10.4 kg (10th centile). A normal diet was introduced at 3 years, and loperamide was stopped a month later, without recurrence of symptoms.

Case 5

She was born at 34 weeks' gestation to healthy unrelated parents, weighing 2.1 kg and there was no relevant family history. On day 2, intestinal obstruction was suspected and a laparotomy revealed an 'apple-peel' bowel arrangement with a dilated blind loop of ileum with some dilatation of distal jejunum, and an absent superior mesenteric artery. The dilated bowel was resected and a jejuno-ileal anastomosis performed. Postoperatively attempts at oral feeding were unsuccessful and her weight fell to 1.5 kg and she was referred to us at age 3 weeks. Parenteral nutrition was instituted and 2 weeks later oral feeding was attempted but she developed signs of intestinal obstruction. Laparotomy showed extensive adhesions and a dilated jejunum; the dilated jejunum was resected and an

anastomosis between the D-J flexure and ileum performed, leaving 40 cm of small bowel. Parenteral feeding was continued, her stools remained loose, and 2 weeks later nasogastric feeding was started with Pregestimil. The stools became looser and more frequent (8–12 daily), and contained up to 2% reducing substances. At 14 weeks she weighed 2 kg (<3rd centile) and loperamide was started in a dose of 1 mg 3 times a day (1.5 mg/kg per day) and slowly increased to 2 mg 4 times a day (3.8 mg/kg per day) over a period of one week. This resulted in the stools becoming formed and less frequent (2–4 daily) and she began to gain weight at a rate of 250–350 g a week. The feeds were changed from nasogastric to oral 3-hourly and she was discharged on Pregestimil and loperamide, 3 mg 4 times a day (2 mg/kg per day) aged 6 months weighing 5.9 kg (3rd–10th centiles). At 14 months she weighed 9.3 kg (25th–50th centiles), loperamide was gradually stopped and a normal diet successfully introduced.

Case 6

She was born at term after an uneventful pregnancy and delivery to healthy unrelated parents, weighing 2.9 kg, and there was no relevant family history. She was exclusively breast-fed for the first month of life, and thereafter with a cows' milk formula. At 10 weeks, she was admitted because of an acute episode of vomiting and diarrhoea, and dehydration; rotavirus was isolated from the stools. Dehydration was corrected with intravenous fluids but the watery diarrhoea persisted (8–10 stools daily) for more than 2 weeks and she lost weight. The stools no longer contained any pathogens but the diarrhoea persisted despite nothing by mouth. On loperamide 1 mg twice a day (0.5 mg/kg per day) the stools became formed and less frequent (1–2 daily) after 24 hours, and she began to gain weight (30–70 g/day). Stopping loperamide resulted in recurrence of diarrhoea, and reintroduction of the drug resulted in disappearance of the diarrhoea. At age 4 months she was discharged on Galactomin 17, weighing 5.2 kg (3rd–10th centiles). A normal diet was reintroduced during the subsequent 3 months and the loperamide was stopped. Six months later she was thriving and weighed 8.6 kg (25th centile).

Dosage of loperamide. When actual body weight was corrected for expected weight, the dose of loperamide was <1 mg/kg per day in all the patients with the exception of Case 5.

Discussion

These cases are the first well-documented instances of loperamide having a beneficial effect in patients

with severe and protracted secretory diarrhoeal states.

In Cases 1 and 2, small intestinal secretion was established by perfusion studies, and in Cases 3, 4, and 5 secretion can be assumed since diarrhoea persisted despite nothing by mouth.^{19 20} The notion that the drug reduced the diarrhoea by modifying secretion is supported by our previous studies in the experimental animal showing that loperamide reversed cholera enterotoxin and prostaglandin E₂ induced fluid secretion to net absorption.^{9 11}

Currently the precise mode of action of loperamide in modifying intestinal secretion is not clear. However, our previous *in vivo* studies in the rat jejunum suggested that the drug exerted its anti-secretory effect via opiate receptors, acting at a point distal to the adenylate cyclase-cyclic AMP system.¹¹ Although loperamide may act on the secretory process itself, it could also alter transport by stimulating absorption. This notion is supported by *in vitro* studies in rabbit ileum showing that loperamide enhances chloride and sodium absorption, and that this effect is blocked by the opiate antagonist naloxone,^{21 22} as well as *in vivo* studies in rat colon showing that the drug stimulated water absorption.²¹ Morphine and enkephalins also stimulate chloride and sodium absorption in the rabbit ileum *in vitro*.^{23 24} Thus, current evidence suggests that the antisecretory effects of loperamide are, at least in part, due to stimulation of absorption, and are mediated via opiate receptors.

There is little doubt in our experience that loperamide can be a life-saving drug in some infants with severe protracted diarrhoeal states in whom dietary manipulations have failed to control the diarrhoea, and in whom diarrhoea persists despite nothing by mouth; usually parenteral nutrition is essential in these patients. Not every patient responds to the drug, and the reasons for this lack of response require clarification so that patients can be selected.

As an opiate analogue, loperamide has an effect on smooth muscle^{6 7} as well as on transport of fluid and electrolytes^{8–11} and this should be borne in mind when using the drug in ill patients similar to those reported in this paper. For example, 2 very ill infants developed ileus while receiving loperamide and the ileus resolved when the drug was stopped. Some metabolic abnormalities may predispose to ileus, as in hypokalaemia, and we strongly recommend frequent monitoring of plasma potassium in any sick infant receiving loperamide.

B S was financially supported by Janssen Pharmaceuticals.

References

- ¹ Amery W, Duyck F, Polak J, Van den Bouwhuysen G. A multi-centre double-blind study in acute diarrhoea comparing loperamide (R 18553) with two common antidiarrhoeal agents and placebo. *Curr Ther Res* 1975; **17**: 263-70.
- ² Tiyyat G N, Meuwissen S G M, Huibregtse K. Loperamide in the symptomatic control of chronic diarrhoea double-blind placebo-controlled study. *Ann Clin Res* 1975; **7**: 325-30.
- ³ Pelemans W, Vantrappen G. A double-blind crossover comparison of loperamide with diphenoxylate in the symptomatic treatment of chronic diarrhea. *Gastroenterology* 1976; **70**: 1030-4.
- ⁴ Galambos J T, Hersh T, Schroder S, Wenger J. Loperamide: a new antidiarrheal agent in the treatment of chronic diarrhea. *Gastroenterology* 1976; **70**: 1026-9.
- ⁵ Gordon S J, Kinsey M D, Kowlessar O D. Efficacy of loperamide in control of diarrhea after ileal resection (IR) (abstract). *Gastroenterology* 1977; **72**: 1064.
- ⁶ Van Nueten J M, Janssen P A J, Fontaine J. Loperamide (R18553) a novel type of antidiarrheal agent. III. *In vitro* studies in the peristaltic reflex and other experiments on isolated tissues. *Arzneimittelforsch* 1974; **24**: 1641-5.
- ⁷ Nakayama S, Yamasato T, Mizutani M. Effects of loperamide on the motility of the isolated intestine in guinea pigs, rats, and dogs. *Nippon Heikatsukin Gakkai Zasshi* 1977; **13**: 69-74.
- ⁸ Karim S M M, Adaikan P G. The effect of loperamide on prostaglandin-induced diarrhoea in rat and man. *Prostaglandins* 1977; **13**: 321-31.
- ⁹ Sandhu B K, Tripp J H, Candy D C A, Harries J T. Letter: Loperamide inhibits cholera toxin-induced small intestinal secretion. *Lancet* 1979; **ii**: 689-90.
- ¹⁰ Beubler E, Lembeck F. Inhibition of stimulated fluid secretion in the rat small and large intestine by opiate agonists. *Naunyn-Schmiedeberg's Arch Pharmacol* 1979; **306**: 113-8.
- ¹¹ Sandhu B K, Tripp J H, Candy D C A, Harries J T. Loperamide: studies on its mechanism of action. *Gut* 1981; **22**: 658-62.
- ¹² Avery G B, Villavicencio O, Lilly J R, Randolph J G. Intractable diarrhea in early infancy. *Pediatrics* 1968; **41**: 712-22.
- ¹³ Fordtran J S. Speculations on the pathogenesis of diarrhea. *Fed Proc* 1967; **26**: 1405-14.
- ¹⁴ Davidson G P, Cutz E, Hamilton J R, Gall D G. Familial enteropathy: a syndrome of protracted diarrhea from birth, failure to thrive, and hypoplastic villus atrophy. *Gastroenterology* 1978; **75**: 783-90.
- ¹⁵ Candy D C A, Larcher V F, Cameron D J S, *et al*. Lethal familial protracted diarrhoea. *Arch Dis Child* 1981; **56**: 15-23.
- ¹⁶ Milla P J, Ogilvie D A, Harries J T. Studies on the pathophysiology of severe protracted diarrhoea of infancy (SPDI) (abstract). *Pediatr Res* 1981; **15**: 1194.
- ¹⁷ Milla P J, Atherton D A, Leonard J V, Wolff O H, Lake B D. Disordered intestinal function in glycogen storage disease. *J Inherited Metab Dis* 1978; **1**: 155-7.
- ¹⁸ Larcher V F, Shepherd R, Francis D E M, Harries J T. Protracted diarrhoea in infancy. Analysis of 82 cases with particular reference to diagnosis and management. *Arch Dis Child* 1977; **52**: 597-605.
- ¹⁹ Krejs G J, Fordtran J S. Physiology and pathophysiology of ion and water movement in the human intestine. In: Sleisenger M H, Fordtran J S, eds. *Gastrointestinal disease*. Philadelphia: Saunders, 1978: 297-335.
- ²⁰ Gardner J D. Pathogenesis of secretory diarrhea. In: Field M, Fordtran J S, Schultz S G, eds. *Secretory diarrhea*. Bethesda, Maryland: American Physiological Society, 1980: 153-8.
- ²¹ Binder J, Laurenson M, Dobbins J W. Mechanisms of loperamide antidiarrhoeal action (abstract). *Gastroenterology* 1981; **80**: 1111.
- ²² Ilundain I, Naftalin R J. Opiates increase chloride permeability of the serosal border of rabbit ileum. Proceedings of the Physiological Society, February 1981. *J Physiol (Lond)* 1981; **316**: 56-7.
- ²³ Dobbins J, Racusen L, Binder H J. Effect of D-Alanine methionine enkephalin amide on ion transport in rabbit ileum. *J Clin Invest* 1980; **66**: 19-28.
- ²⁴ McKay J S, Linaker B D, Turnberg L A. Influence of opiates on ion transport across rabbit ileal mucosa. *Gastroenterology* 1981; **80**: 279-84.

Correspondence to Professor J T Harries, Department of Child Health, Institute of Child Health, 30 Guilford Street, London WC1N 1EH.

Received 5 October 1982