

Bleeding disorders and non-accidental injury

A E O'HARE AND O B EDEN

Department of Paediatric Haematology, Royal Hospital for Sick Children, Edinburgh

SUMMARY Fifty children with suspected non-accidental injury, most of whom had bruising, were investigated to exclude a bleeding disorder. The following investigations were undertaken in each child: full blood count; platelet count, size, and shape; prothombin time; partial thromboplastin time including mix with normal plasma; fibrinogen; and a bleeding time. The results of these initial investigations were abnormal in eight children (16%). One child had a severe coagulopathy secondary to spontaneously acquired inhibitory activity to coagulation factors which led to spontaneous bruising and noticeable signs of injury after a minor accident. The remaining children had several features supporting a diagnosis of non-accidental injury. Two had associated bleeding disorders in the form of von Willebrand's disease and a platelet aggregation abnormality and a baby had an acquired platelet disorder secondary to salicylates, provoking severe haemorrhage from a minor injury. The remaining four children initially had an abnormal laboratory finding—a prolonged partial thromboplastin time—which resulted in lengthy discussions during subsequent legal proceedings. Evidence of a bleeding disorder is not uncommon in non-accidental injury and the two conditions are not mutually exclusive.

A discrepancy between physical findings and history is one of the cardinal signs of child abuse.¹ There may be additional features of bruising that are suggestive of abuse: for example ecchymoses may be at different stages of evolution despite a reported single injury; bruising may be in a particular pattern secondary to the use of an implement or hand; and those areas of the body affected may be the most unlikely to have been injured accidentally. As many of these features occur with a bleeding disorder, it is recommended that investigations to exclude this possibility are carried out.²

Over a two year period we found that 16 per cent of investigations were abnormal. Assessment of an underlying bleeding disorder is only part of the overall consideration of these children. It may clarify the aetiology of bruising that is said to have arisen spontaneously but more often it is used as an assessment of the severity of injury in an abused child.

This study identifies a group of children in whom the initial coagulation screen suggested an abnormality of the intrinsic coagulation system reflected by a prolongation of the partial thromboplastin time. The interpretation of these abnormalities is particularly important when they are referred to in any subsequent legal proceedings.

Patients and methods

Fifty children referred consecutively to this hospital with suspected non-accidental injury over a two year period beginning January 1981 were investigated. Most children presented with bruising. Venepuncture was usually carried out by the referring paediatric staff.

The tests done to exclude a bleeding disorder are shown in Table 1. Venous blood was anticoagulated at a ratio of nine parts blood to one part 3.8% trisodium citrate, and plasma was separated by centrifugation at 3000 g for 10 minutes at 4°C. All clotting end points were determined using a fibrometer (Depex Coagulometer). Prothrombin time, activated partial thromboplastin time, and thrombin time were determined by standard methods. Bleed-

Table 1 *Tests to exclude a bleeding disorder in non-accidental injury*

-
- (1) Full blood count, film
 - (2) Platelet count, size, and shape
 - (3) Partial thromboplastin time
 - (4) Prothombin time
 - (5) Thrombin time
 - (6) Fibrinogen
 - (7) Bleeding time
-

Table 2 Presentation and coagulation results in children investigated for non-accidental injury

Group	Case No	Age	Presenting features	Abnormalities
(1) Accidental injury and coagulation disorder	1	19 mths	Bruising and frontal haematoma	PTT 86.5 secs (32.5),* mix 85.5 Inhibition to factors VIII, IX
(2) Non-accidental injury and coagulation disorder	2	6 yrs	Bruising of buttocks and legs	Bleeding time 8 mins. Abnormal platelet aggregation
	3	3 yrs	Bruising of the genitalia and chest	Bleeding time 3 mins 20 secs PTT 43 secs (33)* Factor VIIIc 0.46 U/ml VIII:RAg 0.37 U/ml Ristocetin cofactor 0.27 U/ml von Willebrand's type IV
(3) Non-accidental injury and laboratory abnormality of coagulation	4	2 mths	Oral injury	Bleeding time 5 mins 25 secs—platelet dysfunction due to salicylates
	5	18 mths	Bruising	PTT 57 secs (34),* mix 45.5 secs
	6	3 yrs	Bruising of the face and bleeding from the ear	PTT 47 secs (34)*
	7	14 mths	Bruising. Laceration to the lip	PTT 41 secs (33),* mix 37 secs
	8	4 mths	Strangulation	PTT 51 secs (32),* mix 36 secs

*Figures in parentheses=control values.
PTT=partial thromboplastin time.

ing time was assessed by the Ivy method. A sphygmometer cuff above the child's elbow was inflated to 40 mm Hg. Seventy per cent ethanol was used to clean the forearm and three punctures were inserted manually 5 cm apart by an autolet (Lancet 3 mm × 1 mm). The exuding blood was gently blotted from the puncture sites every 15 seconds. The final bleeding time was averaged out from the results of the three punctures.

Patients were divided into three groups on the basis of their clinical features, and laboratory results as shown in Table 2. All patients had been referred to the hospital team receiving emergencies except for case 1 who was referred directly to the haematology department. In all cases the general practitioner or clinical medical officer felt that the child's injuries were not explained by the parent's history and a suspicion of child abuse was raised.

Group 1. This group comprised one child with a coagulation disorder in whom non-accidental injury was not confirmed.

Case 1

A 19 month old girl was referred from her local child welfare clinic for further investigation of possible non-accidental injury. She had florid periorbital ecchymoses and a large haematoma on her forehead as a result of a collision with a door the day before. She was noted to have widespread bruising of the limbs and trunk which had arisen spontaneously. She had been well apart from a brief diarrhoeal illness two weeks before. There was no family history of bleeding, she had taken no medication, and there were no features of autoimmune disease.

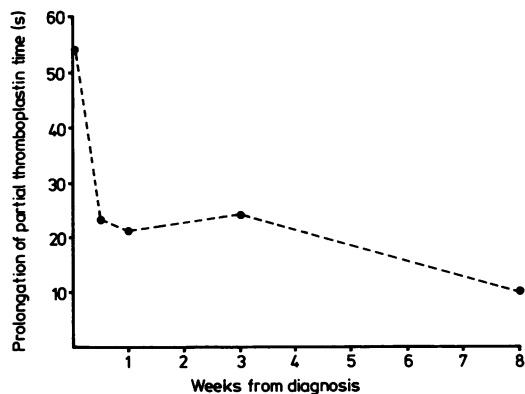


Figure Prolongation of partial thromboplastin time (patient-control) over the two months after presentation in case 1.

A coagulation screen was abnormal with a prolonged partial thromboplastin time (Figure). This failed to correct when her plasma was incubated with normal plasma, confirming inhibitory activity. Low concentrations of factors II, VIII, and IX were found. With conservative management she had no further haemorrhagic symptoms and the inhibitory activity settled spontaneously. The presenting features were explained as a spontaneously developing severe coagulopathy and non-accidental injury was not confirmed.

Group 2. Patients in this group were found to have sustained non-accidental injury in association with a coagulation disorder.

Case 2

A 6 year old girl was brought to the casualty department by her father. She had extensive bruising of the buttocks and legs. There was a long standing history of domestic violence and the parents were separated and shared the child's care. The father, who was an alcoholic and a compulsive gambler, could not explain the aetiology of the bruising, and the child said she had been kicked by a 'grown up'. There was a previous history of easy bruising and prolonged bleeding after tooth extraction. A coagulation screen was subsequently reported to be normal. Bleeding time was not investigated. The child's name was placed on the 'at risk' register and the family was closely supervised. One year later she was admitted to hospital for adenoidectomy and bilateral myringotomy. In view of the history of easy bruising and abnormal bleeding she was assessed again and the bleeding time was prolonged to eight minutes. (Although the recognised range is two to six minutes we have found in our laboratory that a bleeding time of over three and a half minutes has only occurred in children subsequently shown to have a platelet or vascular abnormality). Her platelets showed absence of second phase aggregation with adenosine diphosphate and adrenaline. Her mother and brother showed the same abnormality.

Case 3

A 3 year old girl was referred from her local authority nursery. She was noted to have unexplained bruising to the genitalia and chest wall. There was a history of numerous admissions to hospital with episodes of screaming, poor feeding, and rectal bleeding. There was a deprived home environment and her name was on the 'at risk' register. Her bleeding time was at the upper limit of normal for our laboratory, that is three minutes 20 seconds. Partial thromboplastin time was 43 seconds (control 33 seconds), factor VIIIc was 0.46 U/ml, factor VIII related antigen was 0.37 U/ml, and factor VIII ristocetin cofactor was 0.27 U/ml. A diagnosis of von Willebrand's disorder, type IV was made and was subsequently confirmed in her mother and sister.

Group 3. Patients in this group were found to have sustained non-accidental injury and also had a laboratory abnormality of coagulation.

Case 4

A 2 month old baby was admitted bleeding from the mouth. He was shocked and required resuscitation. An excoriated area at the base of the tongue was found. The bleeding time was five minutes 25

seconds. The parents were of low intellect, denied giving the baby any medication, and could recall no injury. Two weeks later the baby was again admitted bleeding from the mouth and was shown to have a torn frenulum. At the same time a neighbour visited the local medical practice and told the receptionist that she knew the parents were putting soluble salicylate (Junior Disprin) in the baby's milk feed.

Case 5

An 18 month old girl was admitted with bruising to the buttocks and back. Her mother was single and unemployed and was living in a hostel for the homeless. The child had been left in the care of a male friend while the mother attended bingo and the bruising had been noticed the following morning. Coagulation screen showed an abnormality of the intrinsic system with a partial thromboplastin time prolonged to 57 seconds (control 34.5 seconds). The mix partial thromboplastin time was 45.5 seconds indicating inhibitory activity. Shortly afterwards, despite close supervision, the family was lost to follow up and were subsequently traced a year later in another city. At this time the coagulation screen was normal.

Case 6

A 3 year old boy was admitted with bruising to the left side of the face and bleeding from the left ear. There was no satisfactory history to explain this and there had been a previous non-accidental injury. The child's name was on the 'at risk' register and there had been problems in the past with the children being left unattended. Investigations showed a prolonged partial thromboplastin time of 47 seconds (control 34 seconds).

Case 7

A 14 month old girl was admitted with widespread bruising said to have been sustained when she fell from a windowsill. She had had a previous history of an injury to the head and laceration to the lip after a fall at the age of 8 months and bruising to the face after bumping into a door at the age of 3 months. Partial thromboplastin time was prolonged to 41 seconds (control 33 seconds) with a mix partial thromboplastin time of 37 seconds. When the coagulation screen was repeated four days later there was no abnormality.

Case 8

A 4 month old girl was referred by her general practitioner. It was suspected that she had been subjected to attempted strangulation. She had widespread petechiae around the neck and periorbital region. Her teenage parents were alcoholics and

lived in a residential hostel. They could give no explanation for the injuries. Coagulation screen showed a prolonged partial thromboplastin time at 51 seconds (control 32 seconds) and mix partial thromboplastin time of 36 seconds. Repeat investigations 10 days later showed resolution of the abnormality.

Results

Eight of 50 children investigated for non-accidental injury showed abnormalities on laboratory assessment. One child showed spontaneous development of inhibitory activity against coagulation factors that led to the development of severe bruising which suggested non-accidental injury. The inclusion of a bleeding time helped identify a child with a platelet aggregation disorder, a child with a von Willebrand's disorder, and a baby with abnormal platelet function from ingestion of salicylates. Four children had a prolonged partial thromboplastin time at first assessment which subsequently resolved. In one of these children the partial thromboplastin time did not correct on incubation with normal plasma, suggesting inhibitory activity.

Discussion

It is recommended, particularly when bruising is a feature in a case of suspected non-accidental injury, that appropriate tests to exclude bleeding disorders be carried out. Suspicion of non-accidental injury arises from characteristic physical signs of injury to the child, a discrepant history, and abnormal parental attitudes or behaviour.³ Antecedent stress factors may alert the clinician and non-accidental injury occurs more commonly in families with financial problems, poor housing, unemployment, and marital stress.^{4,5} The bruising itself may be highly suggestive¹ and all these considerations help to establish the diagnosis, the goal being to minimise any further risk of injury to the child.

The assessment of whether or not a bleeding disorder is present is simply one aspect of this overall examination. The types of bruising and the manner in which they are said to occur may be very similar in non-accidental injury and in a bleeding disorder.⁶ The presence of the latter compounds the risks to the child who is abused. We have reported eight children presenting over a two year period who had initial abnormalities when assessed in this context. In the patient in case 1 the bleeding disorder clarified her mode of presentation and in conjunction with her other features made non-accidental injury most unlikely. A bleeding time is shown to be mandatory to exclude abnormalities of

blood vessels or qualitative platelet defects.^{7,8} We have found in our laboratory that any child with a bleeding time over three and a half minutes has a bleeding disorder. Although a reference range of up to eight minutes may be quoted, it is difficult to standardise this test in a struggling infant. The normal value should therefore be determined by the laboratory performing the test.⁹ The diagnosis of a platelet aggregation disorder in case 2 was initially missed. There seemed little doubt that this child had been subject to non-accidental injury when she first presented. She can be expected, however, to show easy bruising for which a clear history may not be evident and this needs to be considered.

A drug history is very important. The addition of salicylates to a baby's milk led to severe bleeding from a minor injury. The platelet abnormality was suspected from the prolonged bleeding time despite the initially absent relevant drug history. Prolongation of the partial thromboplastin time occurred as an isolated finding in four children. All had been abused and the laboratory abnormality did not alter this conclusion. Nevertheless, in at least one child the fact that the initial blood test was abnormal proved a matter of interest when legal proceedings followed, and the clinical witness must know what the possible explanations are. In the child showing inhibitory activity a repeat partial thromboplastin time investigation four days after presentation was normal, as were the factor VIII and IX concentrations. We suggest that circulating anticoagulants after minor viral infections in children may be more common than currently appreciated.¹⁰ The inaccuracy of a single coagulation study must be recognised and may have been the explanation for the abnormalities seen in cases 6, 7, and 8.

In a study of 86 children under investigation for a bleeding disorder, 19% did not have the same result on repeat testing.¹¹ Difficulty in obtaining blood may lead to clotting in the syringe, leading to consumption of coagulation factors and platelets with falsely abnormal results.⁷ An alternative explanation, however, may be circulating thromboplastic substances from tissue injury which may prolong the partial thromboplastin time. This is well recognised in the context of severe injury, particularly to the brain,^{12,13} but is unclear in more minor injury. Children who have been abused are the one group where coagulation studies are undertaken after minor injury leading to superficial bruising. Perhaps the same percentage of abnormalities would be seen in children with accidental bruising of the same degree.

The children in this study illustrate that non-accidental injury and bleeding disorders are in no way mutually exclusive. It is as potentially danger-

ous and unhelpful for the child and family to have an inappropriate diagnosis of non-accidental injury made when there is a bleeding disorder¹⁴ as it is for non-accidental injury to be dismissed. The child with a bleeding disorder is at particular risk from abuse and this will influence his management.¹⁵

Therefore, if a laboratory investigation is carried out when a child is feared to have been injured non-accidentally it must be done properly. When the clinician is called upon to give witness and when the coagulation screen is not entirely normal the help of an interested haematologist may be invaluable.

AEO'H was supported by a Leukaemia Research Fellowship.

References

- ¹ Ellerstein NA. The cutaneous manifestations of child abuse and neglect. *Am J Dis Child* 1978;**133**:906-9.
- ² Lothian Regional Review Committee. *Non-accidental injury to children. Guidelines*. Edition 3. Edinburgh: Lothian Regional Social Work Committee and Lothian Health Board, 1983:15.
- ³ Anonymous. Non-accidental injury to children [Editorial]. *Br Med J* 1973;**iv**:656-60.
- ⁴ Altemcier WA, O'Connor S, Vietze PM, Howard MS, Sherrord KB. Antecedents of child abuse. *J Pediatr* 1982;**100**:823-8.
- ⁵ Sills HA, Thomas LJ, Rosenbloom L. Non-accidental injury: a 2 year study in Liverpool. *Dev Med Child Neurol* 1977;**19**:26-33.
- ⁶ Schwer W, Brueschke EE, Dent T. Haemophilia. *J Fam Pract* 1982;**14**:661-74.
- ⁷ Taylor GP. Severe bleeding disorders in children with normal coagulation screening tests. *Br Med J* 1982;**284**:1851-2.
- ⁸ Oppenheimer EH, Schwartz A. Easy bruisability and terminal coma in a 'normal' 5-month old infant. *J Pediatr* 1977;**88**:1049-53.
- ⁹ Abilgaard CF. Diseases of coagulation: the fluid phase. In: Natten DS, Oski FA, eds. *Haematology of infancy and childhood*. 2nd ed. Philadelphia: WB Saunders, 1981:1193.
- ¹⁰ Berman BW, McIntosh S, Clyne LP, Goldberg B, Lobel J, Komp DM. Spontaneously acquired Factor IX inhibitors in childhood. *Am J Pediatr Hemotol Oncol* 1981;**3**:77-81.
- ¹¹ Ho-Yen DO, Todd AS. Severe bleeding disorders in children with normal coagulation screening tests. *Br Med J* 1982;**285**:377.
- ¹² Sarnaik AP, Stringer KD, Jewell PF, Sarnaik SA, Ravindranath Y. Disseminated intravascular coagulation with trauma: treatment with exchange transfusion. *Pediatrics* 1979;**63**:337-9.
- ¹³ Watts C. Disseminated intravascular coagulation. *Surg Neurol* 1977;**8**:258-62.
- ¹⁴ Carpentieri U, Gustavson LP, Haggard ME. Misdiagnosis of neglect in a child with a bleeding disorder and cystic fibrosis. *South Med J* 1978;**71**:854-5.
- ¹⁵ Darbyshire P, Eden OB. Severe bleeding disorders in children with normal coagulation screening tests. *Br Med J* 1982;**285**:134.

Correspondence to Dr O B Eden, Department of Paediatric Haematology, Royal Hospital for Sick Children, 17 Millerfield Place, Edinburgh EH9 1LF.

Received 4 June 1984