

Morphological Investigations of Fibrogenic Action of Estonian Oil Shale Dust

by V. A. Küng*

A review of morphological investigations carried out to clarify the pathogenicity of industrial dust produced in the mining and processing of Estonian oil shale is given. Histological examination of lungs of workers in the oil shale industry taken at necropsies showed that the inhalation of oil shale dust over a long period (more than 20 years) may cause the development of occupational pneumoconiotic changes in oil shale miners. The pneumoconiotic process develops slowly and is characterized by changes typical of the interstitial form of pneumoconiotic fibrosis in the lungs. Emphysematous changes and chronic bronchitis also occur.

The average chemical content of oil shale as well as of samples of oil shale dust generated during mining and sorting procedures is given.

The results of experiments in white rats are presented; these studies also indicate a mild fibrogenic action of Estonian oil shale dust.

The territory of the Estonian S.S.R. has rich deposits of kukersite oil shale.

According to chemical analysis (1) the mean chemical content of industrial oil shale from the area of Kütte-Jöud (which is situated approximately in the center of the Estonian oil shale field) is as follows: 37.01% organic substances; 12.69% SiO₂; 2.96% Al₂O₃; 0.88% FeO₃; 22.99% CaO; 18.20% CO₂; 1.95% FeS₂; 0.29% SO₃. Of the SiO₂ in oil shale, 42% is quartz and 58% is made up of various silicates.

According to Feoktistov (2), the mean chemical content of samples of oil shale dust generated during mining and sorting procedures is very similar to that of industrially used oil shale. The major peculiarity of the chemical composition of oil shale dust is its low free silica content, which is about 3.0-4.0% (5.3%) in oil shale.

The concentration of dust in the atmosphere of the underground part of oil shale mines is relatively low, according to Akkerberg et al. (3) and Feoktistov (2), 2-30 mg/m³ (in drifts 6-9 mg/m³). The dust in oil shale mines is of relatively fine dispersion: up to 80% of the dust particles are under 2 μm in size (2).

Until recently, the investigations of the pathogenicity of industrial dust produced in the mining and industrial processing of oil shale was one of the most topical problems of industrial hygiene in oil shale industry. Of major concern was whether long-term inhalation of oil shale dust causes the development of pneumoconiosis in workers of this industry.

The earliest data concerning the development of occupational pneumoconiosis in persons exposed to inhalation of oil shale and oil shale ash dust for many years, were obtained as a result of x-ray observations by Salzman (4). According to Salzman (4), lung changes in workers suffering from oil shale pneumoconiosis are characterized by vascular and bronchial deformation as linear shadows along bronchi and vascular channels appear. In addition to interstitial lung fibrosis, in most patients with oil shale pneumoconiosis the x-ray examination shows enlarged hilar shadows and fibrotic changes.

Histological examinations of autopsy materials (5, 6) clearly demonstrated the development of coniotic fibrosis of the lungs and regional lymph nodes in oil shale industry workers. Kukersite oil shale dust is not only deposited in lungs and regional lymph nodes, but exerts a reactive connective tissue proliferation. More specific dust ac-

* Institute of Experimental and Clinical Medicine, Tallinn Est. S.S.R.

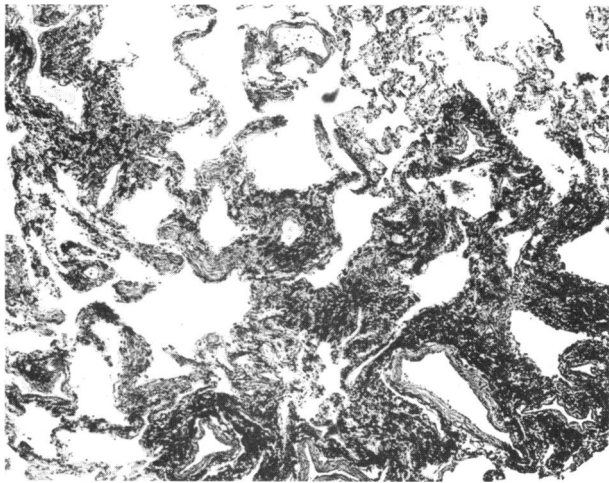


FIGURE 1. Pulmonary interstitial dust fibrosis in an oil shale miner employed in mines for 22 years. $\times 80$.

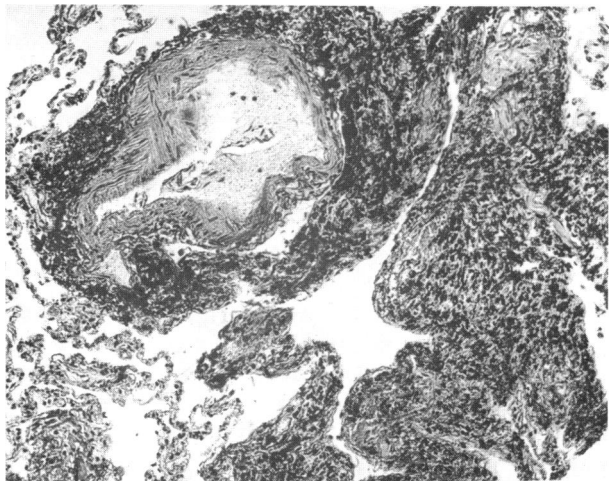


FIGURE 2. Perivascular and peribronchial lung fibrosis in oil shale miner. Same case as in Fig. 1. $\times 120$.

cumulations and proliferative sclerotic pulmonary changes are located perivascularly and peribronchially. Coniotic fibrosis from long-term inhalation of oil shale dust develops slowly and is of mild to moderately expressed diffuse interstitial character. The pneumoconiotic lesions show irregular thickening of interalveolar and interlobular septa as well as perivascular and peribronchial sclerosis. More intense fibrous coniotic foci are found in a small number of cases. Some of the dust-containing interstitial fibrous thickenings have the appearance of irregular bundles. More widespread dense sclerotic foci are not to be found.

The major part of inhaled oil shale dust is transported into the hilar lymph nodes, where well defined sclerotic changes develop. In several cases of miners investigated in this study, typical silicotic

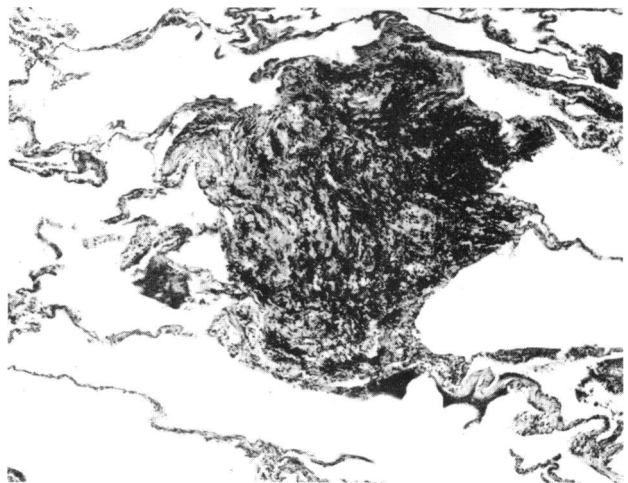


FIGURE 3. Fibrous-coniotic focus and emphysematous changes in the lung of an oil shale miner employed in mines for 28 years. $\times 110$.

nodules in bronchopulmonary lymph nodes were found; all these miners had worked for a considerable length of time in the oil shale industry.

Experiments on white rats also indicated fibrogenic action of Estonian oil shale dust. The dust was administered intratracheally in a dose of 50 mg in 1 ml of sterile physiological saline solution; the experiment lasted up to 12 to 18 months. The pneumoconiotic process resulting from the action of oil shale dust was characterized by relatively slight fibrotic changes. The same lesions resulting from dust of oil shale ash are more intensely expressed than with the lung changes in experiments with oil shale dust.

Autopsy of workers with coniotic pneumoconiosis showed the development of lung emphysema also; diffuse obstructive as well as perifocal forms of emphysematous changes were found. Striking evidence of the role of dust in the development of lung emphysema in oil shale mine workers was the presence of small foci of distended alveoli perifocally to fibrotic lesions containing dust accumulations. It is of importance to note, that in workers who had inhaled oil shale dust for prolonged periods morphological signs of chronic bronchitis and bronchiolitis were found.

One may conclude that inhalation of kukersite oil shale dust causes coniotic fibrosis, chronic bronchitis, and emphysematous changes. The incidence of these pulmonary changes among mine workers is relatively low. This fact will be explained by the low content of free silica in oil shale dust as well as by low concentration of dust in the atmosphere of the underground parts of oil shale mines and by the high relative humidity of this industrial environment.

REFERENCES

1. Torpan, B. On the chemical and mineralogical composition of the strata of the kukersite oil shale. In: Trans. Polytech. Inst. Tallinn, Ser. A. 57: 22 (1954).
2. Feoktistov, G. S. Materials concerning the hygienic estimation of dust factor in the process of mining of oil shale (Kukersite). Dissertation, Tartu, 1967.
3. Akkerberg, I., Vidomenko, A., Jurgenson, and I., Jänes, H. In: The Problems of Occupational Hygiene in Oil Shale Industry of the Estonian S.S.R., Vol. 2, Tallinn, 1955, pp. 61-85.
4. Salzman, S. M. Silicosis and silico-tuberculosis in workers of the oil shale industry. In: The Problems of Occupational Hygiene in Oil Shale Industry of the Estonian S.S.R. Tallinn, 1953, Vol. 1, pp. 27-39.
5. Küng, V. Pneumoconiosis Produced by Inhalation of Oil Shale (Kukersite) Dust. Publisher, Tallinn, 1959.
6. Küng, V. On question of development of occupational pneumoconiosis in workers of oil shale industry. In: Nauchno-Prankvicheskaya Deyatel'nost Instituta Eksperimental' noiĭ Klinicheskoi Meditsina. Tallinn, 1972, pp. 22-30. (In Russian).