

Carcinogenicity and Toxicity of Methoxychlor

by Melvin Dwaine Reuber*

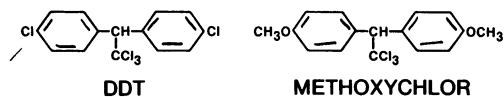
Methoxychlor is carcinogenic for the liver of C3H and BALB/c mice and Osborne-Mendel rats, and possibly for the liver of dogs. Methoxychlor is also carcinogenic for the testis of BALB/c male mice, bone of B6C3F₁ female mice, and the ovary of Osborne-Mendel female rats. The incidences of carcinomas of the liver were increased in C3H male mice and BALB/c male and female mice fed methoxychlor. There also was an increase in malignant neoplasms at all sites in BALB/c male and female mice. C3H and BALB/c male mice were more susceptible to the carcinogenic effects of methoxychlor than were female mice. BALB/c mice were more susceptible than C3H mice. Osborne-Mendel male and female rats developed significant incidences of carcinomas of the liver. The incidence of sarcomas of the spleen and abdomen, mostly hemangiosarcomas, was increased in male rats. Neoplasms of the pituitary, adrenals, and mammary gland were also increased in methoxychlor-treated female rats. Miniature swine given methoxychlor developed chronic renal disease in relatively short periods of time. There also was hyperplasia of the mammary gland and uterus, suggesting an estrogen-like effect on those organs. Methoxychlor applied to the skin of rabbits caused a dose-related atrophy of the testes, as well as chronic renal disease. Atrophy of the testes and chronic renal disease could not be evaluated in mice and rats because of insufficient data.

Introduction

Methoxychlor [1,1'-(2,2,2-trichloroethyldene) bis(4-methoxy) benzene], also known as dianisyltrichlorethane, dimethoxy DDT, and DMDT, is a structural analog of DDT. It is used against a wide range of insects that attack fruits, vegetables, shade trees, home gardens, forage crops, and livestock. Methoxychlor is also used for the spray treatment of barns, grain storage bins, mushroom houses, dairies, and other agricultural buildings. Since methoxychlor is relatively ineffective against soil organisms, it is generally applied directly to crops by ground or aerial spraying.

This review includes, to the best of our knowledge, every study on the carcinogenicity of methoxychlor in animals. The results and conclusions are based upon my examination of the raw data and, whenever possible, of the histological sections. The histological sections were examined for the FDA Methoxychlor Mouse Study, FDA Me-

thoxychlor Rat Study, FDA Methoxychlor Dog Study, FDA Methoxychlor Swine Studies, FDA Methoxychlor Rabbit Study, NCI Methoxychlor Rat Study, and NCI Methoxychlor Mouse Study. Other studies reviewed were by Hodge et al., Radomsky et al., and Deichmann et al.



FDA Methoxychlor Mouse Study

BALB/c (BALB/cJ) and C3H (C3HeB/FeJ) strains male and female mice ingested 750 ppm technical methoxychlor (1,2). Mice, 3 weeks of age, were given the pesticide in ground laboratory meal for periods up to 2 years. There were 100 mice of each strain and sex given methoxychlor, as well as 100 controls of each sex.

Tissues from all mice with lesions, as well as tissues from many grossly normal mice, were fixed in 10% formalin. Hematoxylin and eosin

* Experimental Pathology Laboratory, NCI Frederick Cancer Research Center, Frederick, Maryland, 21701.

stained paraffin sections were prepared from all gross lesions in which tumors were suspected and from tissues with incidental gross lesions. The procedures have been described (3).

BALB/c male mice ingesting methoxychlor survived for an average of 80.8 weeks (55-104), and controls for 94.8 weeks (60-104) (Table 1). Females given methoxychlor survived for 95.4 weeks (59-104), compared to 96.2 weeks (59-104) for controls.

C3H male mice receiving methoxychlor survived for an average of 99.4 weeks (71-104), and control mice for 101.4 weeks (89-104) (Table 2). The survival of methoxychlor-treated female mice did not differ from that of control female mice.

Carcinomas of the Testis

Carcinomas of the testis were observed in BALB/c male mice ingesting methoxychlor, as well as in a small number of control mice (Table 3). C3H male mice ingesting methoxychlor did not develop tumors of the testis.

Carcinomas of the testis were present in 27 of 51 BALB/c male mice (53%) ingesting methoxychlor compared to 8 of 71 control male mice (11%) ($p = 0.000,000,6$). Tumors of the testis were more malignant in methoxychlor-treated mice than in the control mice. They were observed at an earlier age (an average of 87.5 weeks for treated and 103.8 weeks for controls); were larger in size (carcinomas were large in treated mice; whereas three of the seven carcinomas in controls were 2-4 mm in size); were less differentiated histologically; and were more invasive in methoxychlor-treated mice than in control mice. They also occasionally were bilateral in treated mice. One treated mouse had a metastasis to a lymph node adjacent to the left adrenal, which was seen grossly. The incidence of metastases is not reliable unless serial sections of lymph nodes and other organs are examined histologically, which was not the case in this study.

Neoplasms of the Liver

C3H Mice. Male C3H mice ingesting methoxychlor were more susceptible to the development of carcinomas of the liver than were female mice. Carcinomas of the liver were present in 43 of 92 C3H male mice (47%) ($p = 0.00088$) and 15 of the 83 female mice (18%) ingesting methoxychlor; whereas 23 of 96 control male mice (24%) and 11 of 99 control female mice (11%) developed hepatocellular carcinomas (Table 4).

There was occasionally more than one carci-

Table 1. Survival times for male and female BALB/c mice ingesting methoxychlor (FDA mouse study).

Dose, ppm	Survival time, weeks			
	Males		Females	
	Average	Range	Average	Range
0	94.8	60-104	96.2	59-104
750	80.8	55-104	95.4	59-104

noma of the liver measuring 3-5 cm in diameter in mice given the pesticide in the diet. By contrast, the carcinomas in control mice were solitary. There were metastases in the lungs of one male mouse ingesting methoxychlor and two control male mice. The reporting of the incidence of lung metastases is not reliable unless, among other things, serial sections are done, which was not the case in this study.

BALB/c Mice. Both BALB/c male and female mice given methoxychlor were susceptible to hepatic carcinogenesis. BALB/c male mice developed more malignant neoplasms of the liver than female mice. Neoplasms of the liver were observed in 18 of 67 BALB/c male mice (27%) ($p = 0.00014$) and 12 of 96 female mice (13%) ingesting methoxychlor in the diet ($p = 0.00745$) (Table 5). There were carcinomas of the liver in 3 of 73 control male (4%) and 2 of 89 control female mice (2%). The neoplasms in methoxychlor-treated mice were hepatocellular carcinomas and hemangiosarcomas of the liver. The number of neoplasms per liver generally did not differ in treated and untreated mice. Carcinomas were often completely necrotic, probably from infarction. Metastases from neoplasms of the liver to the lung were not seen in either treated or control mice.

Neoplasms at all Sites

BALB/c male mice ingesting methoxychlor were more susceptible to the development of malignant neoplasms at all sites than were female mice. Malignant neoplasms were seen in 48 of 67

Table 2. Survival times for male and female C3H mice ingesting methoxychlor (FDA mouse study).

Dose, ppm	Survival time, weeks			
	Males		Females	
	Average	Range	Average	Range
0	101.4	89-104	98.0	71-104
750	99.4	71-104	98.5	81-104

Table 3. Number of BALB/c male mice ingesting methoxychlor with carcinomas of the testis (FDA mouse study).^a

Dose, ppm	Carcinomas
0	8/71 (11%)
750	27/51 (53%), $p = 0.000,000,6$

^a Corrected for survival times in this and following tables

BALB/c male (72%) ($p < 0.00001$) and 45 of 96 female mice (47%) ($p = 0.03355$) ingesting methoxychlor and 20 of 73 control male (27%) and 29 of 89 control female mice (33%) (Table 6).

The neoplasms were predominantly carcinomas in treated male and control male mice; whereas female mice had both carcinomas and sarcomas. Sarcomas metastasized in 3 male mice (4%) and 4 female mice (4%) given methoxychlor, compared to 0 in the control mice. Carcinomas in male mice receiving methoxychlor in the diet developed in the liver, testis, and lung. Sarcomas of the uterus and liver were observed in female mice given methoxychlor.

Summary

Methoxychlor is carcinogenic for the liver of C3H and BALB/c male mice and BALB/c female mice and for the testis of BALB/c male mice. There also was an increase in malignant neoplasms at all sites in BALB/c male and female mice. C3H and BALB/c male mice were more susceptible to the carcinogenic effects of methoxychlor than were female mice. BALB/c mice were more susceptible than C3H mice.

FDA Methoxychlor Rat Study

Osborne-Mendel strain male and female rats, 21 days of age, 12 per group, were used (4). Littermates were selected at random for the test and control groups. Rats were housed individually and were allowed food and water ad libitum. Technical methoxychlor was dissolved in 1% corn oil and incorporated into ground commercial laboratory meal in a food mixer. Rats ingested dietary levels

Table 4. Number of C3H male and female mice ingesting methoxychlor with carcinomas of the liver (FDA mouse study).

Dose, ppm	Males	Females
0	23/96 (24%)	11/99 (11%)
750	43/92 (47%), $p = 0.00088$	15/83 (18%)

of 0, 10, 25, 100, 200, 500, or 2000 ppm for 104 weeks.

Histological sections were made on tumors observed on gross examination, except for a few "lymphosarcomas." In 19 rats, additional organs were also examined histologically. Tissues were sectioned from 22 rats given 2000 ppm, 19 rats given 500 ppm, 18 rats given 200 ppm, 16 rats given 100 ppm, 5 rats receiving 25 ppm, 3 rats receiving 10 ppm methoxychlor, and 16 control rats.

Histological sections from 19 rats included lung, heart, liver, spleen, pancreas, stomach, small intestine, colon, kidney, adrenal, thyroid, testis, uterus, ovary, leg muscle, leg bone, and bone marrow. In the other 80 rats, sections were made of liver, kidney, and testis.

Neoplasms of the Liver in Female Rats

Carcinomas were present in the liver of treated females. Three of nine female rats (33%) ingesting 2000 ppm had carcinomas compared to 0% control female rats; and an additional rat had a hyperplastic nodule, which increased the incidence of hepatic neoplasms to 44% in female rats given 2000 ppm methoxychlor ($p = 0.04118$) (Table 7). Ten of 52 treated female rats (19%) had hyperplastic nodules or carcinomas of the liver. This incidence is significant when compared with the usual 1 of 50 neoplasms of the liver observed in control rats in this laboratory (FDA) ($p = 0.00478$). All but one of the neoplasms were found in the survivors.

Female rats ingesting methoxychlor developed severe diffuse hyperplasia of the liver which generally was 2-3+ in rats given 25 ppm and increased to 5+ in rats receiving 2000 ppm methoxychlor. Hyperplasia was 0-1+ in control rats.

Table 5. Number of BALB/c male and female mice ingesting methoxychlor with malignant neoplasms of the liver (FDA mouse study).^a

Dose, ppm	Males	Females
0	3/73 (4%)	2/89 (2%)
750	18/67 (27%), $p = 0.00014$	12/96 (13%), $p = 0.00745$

^a One male mouse given methoxychlor had hemangiosarcoma of the liver; five female mice receiving methoxychlor developed hemangiosarcomas of the liver; the other mice had hepatocellular carcinomas.

Table 6. Number of BALB/c male and female mice ingesting methoxychlor with malignant neoplasms at all sites (FDA mouse study).

Dose, ppm	Males	Females
0	20/73 (27%)	29/89 (33%)
750	48/67 (72%), $p < 0.00001$	45/96 (47%), $p = 0.03355$

Neoplasms of the Liver in Male Rats

Carcinomas of the liver were observed in three of eight male rats (38%) ingesting 2000 ppm methoxychlor and in 0% controls (Table 8). An additional treated rat had a hyperplastic nodule, increasing the incidence of hepatic neoplasms to 50%. Eight of 32 male rats (25%) given methoxychlor developed hyperplastic nodules and carcinomas of the liver; whereas 0% were observed in control male rats. This incidence is significant when compared to the usual 1 of 50 neoplasms of the liver generally observed in this laboratory (FDA) ($p = 0.00189$).

Control rats had hyperplasia that was 0-1+, and treated male rats had severe diffuse hyperplasia which increased from 2-3+ in rats given 25 ppm methoxychlor to 5+ in rats given 200, 500, or 2000 ppm.

Carcinomas of the Ovary in Female Rats

Five of 10 female rats (50%) ingesting 500 ppm and 1 of 10 (10%) given 100 ppm developed carcinomas of the ovary. There were small carcinomas in rats given 500 ppm. The one in the female given 100 ppm was a large carcinoma, measuring several centimeters in diameter. When ovarian tumors are included, the incidence of carcinomas in female rats given 500 ppm increased from 20% to 70% ($p = 0.0099$) and the incidence of malignant tumors to 90% (Table 9). The incidence of carcinomas of the ovary is significant when compared to 0 of 10 control rats ($p = 0.01625$) and also

when compared to 0 to 50 observed in control rats in this laboratory (FDA) ($p = 0.00005$).

Malignant Neoplasms in Other Organs

Malignant neoplasms present in other organs in methoxychlor-treated and untreated female rats were carcinomas of the mammary gland or lymphosarcomas, generally of the lung. Lymphosarcomas also were present in male rats.

Summary and Conclusions

Male and female rats developed significant incidences of hepatocellular carcinomas of the liver. Carcinomas of the ovary were also significantly increased in treated female rats. Methoxychlor-treated male and female rats also had severe diffuse hyperplasia of the liver.

Methoxychlor is carcinogenic for the liver in male and female Osborne-Mendel rats and for the ovary of Osborne-Mendel female rats.

FDA Methoxychlor Dog Study

One male and three female dogs were fed 300 mg/kg/day of methoxychlor for 3.5 years (5). Methoxychlor was given in capsules as a 10% solution in corn oil.

Two dogs died after 105 and 260 days. One of those was a female dog that had tremors after the beginning and before the end of the treatment. The cause of death was probably acute pneumonia. The second dog, a male, had hemorrhage

Table 7. Number of female rats ingesting methoxychlor with neoplasms of the liver (FDA fat study).^a

Dose, ppm	Hyperplastic nodules	Carcinomas	Total neoplasms
0	0/9 (0%)	0/9 (0%)	0/9 (0%)
10	1/7 (14%)	0/7 (0%)	1/7 (14%)
25	1/11 (9%)	0/11 (0%)	1/11 (9%)
100	1/7 (14%)	0/7 (0%)	1/7 (14%)
200	2/9 (22%)	0/9 (0%)	2/9 (22%)
500	1/9 (11%)	0/9 (0%)	1/9 (11%)
2000	1/9 (11%)	3/9 (33%)	4/9 (44%), $p = 0.04118$
10-2000	7/52 (13%)	3/52 (6%)	10/52 (19%), $p = 0.00478^b$

^a Corrected for survival times in this and following tables.

^b Ten of 52 versus 1 of 50 (2%) controls with neoplasms of the liver.

Table 8. Number of male rats ingesting methoxychlor with neoplasms of the liver (FDA rat study).^a

Dose, ppm	Hyperplastic nodules	Carcinomas	Total neoplasms
0	0/4 (0%)	0/4 (0%)	0/4 (0%)
10	0/5 (0%)	0/5 (0%)	0/5 (0%)
25	0/4 (0%)	0/4 (0%)	0/4 (0%)
100	3/7 (43%)	0/7 (0%)	3/7 (23%)
200	0/4 (0%)	0/4 (0%)	0/4 (0%)
500	1/4 (25%)	0/4 (0%)	1/4 (20%)
2000	1/8 (12%)	3/8 (38%)	4/8 (50%)
10-2000	5/32 (16%)	3/32 (9%)	8/32 (25%), $p = 0.00189^b$ $p = 0.0161^c$

^a Corrected for survival time.

^b Eight of 32 versus 1 of 50 (2%) controls with neoplasms of the liver.

^c Test for positive trend.

in the lung, as well as small hemorrhages elsewhere, and increased fat in the liver and adrenal.

The other two female dogs, each about 6 years old, were killed after receiving methoxychlor for 3.5 years. There were two pale round foci, 6 and 8 mm in diameter, in the left lobe of the liver of one dog. A whitish nodule, 8 mm in diameter, was noted in the spleen of the same dog. Tissues of all organs were examined histologically.

The foci observed on gross examination were small hepatocellular carcinomas of the liver. There also was a small number of hepatic cells with foamy cytoplasm around central veins in the same dog. In the second dog, which was described as "negative" grossly, there was "slight fibrosis, with fibrotic areas containing macrophages with yellowish pigment, new blood vessels, and small bile duct-like structures." Fat stains disclosed a small amount of fat in the livers.

The adrenals in both dogs had slightly ballooned cells in the zona fasciculata, in which increased fat was demonstrated. The nodule in the spleen was lymphoid tissue. There was increased fat in the outer cortex of the kidney in 1 dog and chronic cholecystitis in both dogs.

In summary, one female dog given methoxychlor in the diet for 3.5 years developed carcinoma of the liver; another had fibrosis of the liver.

There also was increased lipid in the adrenal glands.

FDA Methoxychlor Miniature Male and Female Swine Study

Twenty-eight miniature swine, 6.5-23.5 months old were started on a study in which methoxychlor was added to the feed at a daily dosage level of 1 g/kg body weight (6). The 28 swine were divided into the following groups: three spayed gilts, four boars, four sows, and seven gilts bred prior to test, four sows and four gilts started on test and then bred (one gilt did not come into heat), one gilt started on test at the time of farrowing, and one bred gilt sacrificed as a control.

At periods from 4-12 weeks on test the dosage level was increased to 2 g/kg body weight in four sows and three gilts. One control was also given 1 g/kg after she had farrowed.

The three spayed gilts exhibited signs of continuous heat after 21 days on methoxychlor and 1 also had a prolapsed vagina. Female piglets from three animals developed swollen vulvas and showed signs of heat. Eight females started on test before breeding had moderate hyperplasia of the mammary gland with milk-like secretion prior

Table 9. Number of female rats ingesting methoxychlor with malignant neoplasms (FDA rat study).

Dose, ppm	Carcinomas	Sarcomas	Total ^a
0	1/10 (10%)	1/10 (10%)	2/10 (20%)
10	2/10 (20%)	0/10 (0%)	2/10 (20%)
25	4/11 (36%)	2/11 (18%)	4/11 (36%)
100	3/10 (30%)	1/10 (10%)	4/10 (40%)
200	2/11 (18%)	1/11 (9%)	3/11 (27%)
500	7/10 (70%), $p = 0.0099$	2/10 (20%)	9/10 (90%)
2000	3/11 (27%)	0/11 (0%)	3/11 (27%)
10-2000	21/63 (33%), $p = 0.0558^b$	6/63 (10%)	25/63 (32%)

^a Rats with carcinoma and sarcoma are counted only once.

^b Departure from trend.

to breeding or pregnancy; six of the eight showed signs of pseudocyesis, one failed to come into heat, and one conceived and farrowed. Changes were not observed in the four male swine.

Histological examination was done on brain, thyroid, liver, pancreas, spleen, kidney, adrenal, testis, uterus, ovary, and mammary gland. In addition, the pituitary, heart, lung, thymus, spinal cord, small intestine, colon, and male accessory glands were examined from several pigs. Six testes from castrated boars were used as controls.

Two animals died after periods of 10 and 17 weeks of test. The sow that died after 10 weeks had severe hemorrhage and necrosis of the gastrointestinal tract. The remaining 25 swine given methoxychlor in the feed were killed at periods varying from 6-40 weeks.

Lesions Observed on Gross Examination

Severe fibrotic lesions or scarring of the kidneys was seen consistently in all animals given methoxychlor in the feed. Cysts were present in the uteri of the three spayed gilts. Two females that had farrowed and four that did not conceive had edematous uteri. There were cysts in the mesosalpinx or mesovarium in four females. Two of the four boars had small testes.

Liver changes were described as yellowish and reticulated in a pregnant sow and as light brown and hard in a gilt that had farrowed. Ascites was present in one boar and in one sow that had farrowed.

Renal and Hepatic Disease

Chronic interstitial fibrosis was present in all pigs given methoxychlor. There was extensive golden brown pigment in the cytoplasm of tubular epithelial cells in the kidney of 19 of 27 swine (70%). Special stains characterized the pigment as lipofuscin.

There was moderate to severe fatty change in the livers of four females; three of the females had farrowed and one was killed during pregnancy. The hepatic cells varied in size in one female. Pigment similar to that in the kidney was observed in the cytoplasm of the hepatic cells of all animals, and it was marked in 21.

Changes in the Uterus, Mammary Gland, and Testis

Endometrial hyperplasia was seen in the uteri of all females given methoxychlor. There was se-

vere mammary gland hyperplasia in 16 female pigs, including five unsplayed, nonpregnant females. Two spayed gilts had mild hyperplasia. The testes of one boar did not contain interstitial cells.

Summary

Swine given methoxychlor developed chronic interstitial fibrosis of the kidney in relatively short periods of time. There also was hyperplasia of the mammary gland and uterus, suggesting an estrogen-like effect on those organs.

FDA Methoxychlor Mature Male Swine Study

Six mature, castrated, miniature male swine were started on an experiment in which methoxychlor was mixed in the diet at a level of 1 g/kg body weight/day (?). Two of the six swine were fed standard rations and served as controls. One control and two test animals were sacrificed after 3.5 months on test. The remaining two test animals were maintained on 1 g/kg for approximately 4.5 months and then given 2 g/kg for an additional 26 days before termination of the study. Histopathological examinations were detailed.

Lesions of the Mammary Gland

The teats of all test animals were enlarged after 2.5 months on test. There appeared to be no further enlargement of the teats in any of the animals regardless of time on test (up to 5.5 months), or an increase in dose level of methoxychlor. Histopathologically, all test animals showed a definite development of glandular tissue with secretory material in the acini in the mammary glands. No glandular development was noted in the controls.

Hepatic and Renal Lesions

The kidneys of all test animals showed chronic interstitial fibrosis, and various amounts of brownish pigment in the cytoplasm of tubular cells. The two animals maintained on methoxychlor at levels of 1 g/kg body weight/day for 4.5 months and 2 g/kg for an approximate additional month showed a fine, granular brownish pigment in the cytoplasm of hepatic cells.

Summary

Mature castrated male swine given methoxychlor developed pseudopregnancy. Therefore this

effect is not limited to mature and mature castrated female swine as previously shown (6). Age did not influence the development of chronic renal disease.

FDA Methoxychlor Immature Male Swine Study

Four castrated male miniature swine, approximately 11 weeks of age, were started on an experiment in which methoxychlor was added to the diet at a level of 2 gm/kg of body weight per day (8). One male castrate was fed standard ration and served as a control. All animals survived and were sacrificed at the end of the 18-week test period. Histopathological examination consisted of liver, kidney, and mammary gland.

Lesions Observed on Gross Examination

There was enlargement of the teats and bases of the teats in all the animals fed methoxychlor. The kidneys of all test animals showed extensive pitting and scarring on gross examination. An abscess approximately 1 cm in diameter was present in the myocardium of the control animal.

Lesions of the Kidney, Mammary Gland, and Liver

Changes in the mammary glands were not as striking as in the experiment with mature castrated males in which there was definite development of secretory acini. Changes in immature castrated male swine consisted of a slight but definite increase and development of the duct system with an occasional secretory tubule. There was hyperplasia of the duct epithelium in all test animals and squamous metaplasia of the epithelium in the mammary gland in one. In the mammary glands of the control swine there were small or rudimentary ducts.

The livers of two test animals contained small amounts of a yellowish-brown pigment in the cytoplasm of hepatic cells. Swine also had chronic interstitial fibrosis of the kidneys.

Summary

Immature castrated male swine given methoxychlor developed hyperplasia of the ducts of the mammary gland and chronic renal disease.

FDA Methoxychlor Rabbit Study

Methoxychlor was applied to the skin, 30% in dimethyl phthalate, of male and female rabbits

(9). The doses were 0.5, 1.0, 2.0, or 4.0 ml/kg/day, 5 days a week, over a 109-day period (78 applications). There were two males and one female in each group, with the exception of three male rabbits given the 2.0 ml dose. Complete necropsies were done on male rabbits given the 2.0 or 4.0 ml doses, except for one given 4.0 ml because of advanced autolysis. The heart, liver, gallbladder, kidney, testes, uterus, ovary, skin, and bone marrow were examined histologically in the remaining six rabbits. A Giemsa-stained smear of bone marrow was studied for every rabbit.

Rabbits receiving methoxychlor developed severe anorexia, depression, and emaciation; one male rabbit receiving 4.0 ml/kg/day was dead after 10 days and one female died after 28 days. The following changes were observed in the male rabbit: slight atrophy of liver, spleen, muscle and pancreas; moderate atrophy of skin appendages and marrow; severe atrophy of testes; edema of the wall of the gallbladder; slight to moderate hyperkeratosis; and slight thickening of the stratum spinosum of the skin.

One male rabbit given 2.0 ml/kg/day methoxychlor was markedly emaciated and moribund and was killed after 10 days. The rabbit had moderate atrophy of the liver, spleen, bone marrow, testes, and pancreas.

The remaining nine rabbits survived for the duration of the study. The male rabbit given 4.0 ml/kg/day was markedly emaciated; the rabbits given the other doses were slightly to moderately emaciated.

Skin Lesions

The skins of all the surviving rabbits were slightly rough with a small or moderate amount of whitish branny scaling. "Hyperkeratosis was moderate, or slight to moderate; thickening of the stratum spinosum of the epidermis was either slight or slight to moderate; infiltration of the subepidermal corium with chiefly mononuclear cells varied from almost none to a small amount. No ulceration of the skin was seen."

Chronic Renal Disease

The male rabbit given 4.0 ml/kg/day methoxychlor had kidneys which were double the normal size and were slightly pale, fibrous and granular, and the testes were markedly atrophic. There was slight portal fibrosis, cellular infiltration and atrophy of the liver. The chronic interstitial fibrosis was severe. One female given 1.0 ml/kg/day and one male receiving 2.0 ml/kg/day had focal nephritis.

"The cortex and outer medulla are diffusely damaged to a moderate degree; the damage consists of narrow bands or groups of dilated, enlarged or atrophic tubules mixed with other small groups or bands of tubules which appear normal except for perhaps some compensatory hypertrophy. Such glomerular atrophy or other glomerular damage as is present appears to be secondary to the tubular damages in the same locality. Intermingled with the atrophic tubules is a moderate amount of loose fibrous tissue and a relatively small amount of chronic inflammatory cellular exudate" (9).

Atrophy of the Testes

Atrophy of the testes was proportional to the dosage of methoxychlor and was present in all surviving rabbits (7 of 7 rabbits). The atrophy was severe in rabbits given 2.0 or 4.0 ml/kg/day, moderate in those receiving 1.0 ml/kg/day, and slight in one rabbit at the lowest dose; the remaining rabbit at the lowest dose had focal marked atrophy. There was marked atrophy in the rabbit receiving the highest dose for only 10 days. Atrophy was not described in the rabbits given 2.0 ml/kg/day for a 15-day period.

Lesions of the Bone Marrow

There was reduction in the number of mature granulocytes of the bone marrow in a male rabbit given 2.0 ml/kg/day. The marrow was slightly hyperplastic in a male given the highest dose, and another male receiving 1.0 ml/kg/day. The marrow was hyperplastic in one male and one female at the 0.5 ml dose.

Summary

Methoxychlor applied to the skin over a period of 109 days caused atrophy of the testes in male rabbits. The degree of atrophy was related to the dose, i.e., severe at the two highest doses and moderate at the lower doses. The one surviving rabbit receiving the highest dose developed severe chronic interstitial fibrosis of the kidney. Changes were also observed in the skin and bone marrow.

NCI Methoxychlor Rat Study

Osborne-Mendel male and female rats, 44 days of age, were given methoxychlor at two dose levels in the diet (10). There were 50 treated rats in each group, and 20 control rats of each sex.

Male rats ingested an average of 442 or 845 ppm for 78 weeks. Female rats ingested an average of 845 or 1385 ppm (Table 10). Rats were killed after 111 weeks.

The life span of rats ingesting methoxychlor was shortened, particularly those receiving the low dose (Table 11).

Sarcomas in Male Rats

There was an increase in sarcomas in male rats ingesting methoxychlor (Table 12). Most of the sarcomas were hemangiosarcomas and they occurred in the spleen and abdomen. There were more sarcomas of the spleen (19%) in male rats given the low dose. There were more sarcomas of the abdomen (10%) in male rats receiving the high dose or methoxychlor.

Neoplasms of the Pituitary

Female rats given the high dose of methoxychlor had over two times as many adenomas and carcinomas of the pituitary (43%) ($p = 0.067$) compared to the controls (20%) (Table 13). The neoplasms were dose-related ($p = 0.038$).

Neoplasms of the Adrenal Gland

Carcinomas of the adrenal gland, as well as both adenomas and carcinomas, were increased in female rats given the low or high doses of methoxychlor (Table 14). Benign and malignant neoplasms were observed in 15% of the controls, in 30% of the rats on the low dose, and 38% of the rats on the high dose.

Neoplasms of the Ovary

Carcinomas of the ovary were present in 0 of 20 control female rats (0%), 5 of 46 female rats (11%) given the low dose, and 11 of 47 female rats (23%) ($p = 0.014$) receiving the high dose of methoxychlor (Table 15). Neoplasms of the ovary were dose-related ($p = 0.0034$).

Table 10. Dose levels for male and female rats ingesting methoxychlor (NCI rat study).

	Males		Females	
	Low	High	Low	High
Initial dose, ppm	360	720	750	1500
Average dose, ppm	442	845	845	1385

Table 11. Survival times for male and female rats ingesting methoxychlor (NCI rat study).

Dose	Survival times, weeks			
	Males		Females	
	Average	Range	Average	Range
0	106.0	84-111	108.8	94-111
Low dose	101.6	74-111	103.2	76-111
High dose	106.1	25-111 ^a	106.9	54-111

^a One rat had a subcutaneous sarcoma with metastases at 25 weeks.

Neoplasms of the Mammary Gland

Carcinomas of the mammary gland were observed in 3 of 20 control female rats (15%), 15 of 46 female rats (33%) ingesting the low dose, and 14 of 47 female rats (30%) given the high dose of methoxychlor (Table 16).

Neoplasms of the Liver

Female rats ingesting the high dose of methoxychlor developed increased incidences of hyperplastic nodules and carcinomas of the liver. Of 47 female rats, 21 (45%) had hyperplastic nodules ($p = 0.00010$) compared to 0% in the controls (Table 17). Six of 47 female rats (13%) on the high dose and 1 of 20 female control rats (5%) had carcinomas of the liver. Neoplasms of the liver were seen in 27 of 47 methoxychlor-treated female rats given the high dose (58%) and 1 of 20 control female rats (5%) ($p = 0.00003$). Neoplasms of the liver were dose related ($p = 0.39 \times 10^{-8}$). In addition, 12 rats given the high dose of methoxychlor developed moderate or severe diffuse hyperplasia of the liver.

Lesions Other Than Neoplasms

One low dose male rat given methoxychlor had a thrombus in a hepatic vein. None were seen in controls.

Comments

This study most likely should be considered an unsatisfactory study. Many of the rats had only

one to three histological sections, and autolysis was often advanced (Tables 18 and 19). Furthermore, the incidence of benign and malignant neoplasms in control rats was so high that differences between the controls and methoxychlor-treated rats could not be detected. This high incidence in control rats strongly suggests contamination of those rats with methoxychlor.

There were some positive findings despite these shortcomings.

Hepatic vein thrombi, seen in mice receiving dieldrin, aldrin, heptachlor, or heptachlor epoxide, were rarely seen in Osborne-Mendel rats given dieldrin or aldrin (11, 12).

Summary

Methoxychlor is carcinogenic for the liver and ovary of female rats. The incidence of sarcomas of the spleen and abdomen, mostly hemangiosarcomas, was increased, but not significantly, in male rats. Neoplasms of the thyroid, pituitary, adrenals, and mammary gland were also increased in methoxychlor-treated female rats.

NCI Methoxychlor Mouse Study

B6C3F₁ male and female mice, 41 days of age, ingested methoxychlor at 2 dose levels in the diet (10). There were 50 treated mice in each group, and 20 control mice of each sex.

Female mice ingested 750 or 1500 ppm methoxychlor for 14 days and 1000 or 2000 ppm for 532 days. Male mice received 1400 or 2800 ppm methoxychlor for 14 days and 1750 or 3500 ppm for 532 days (Table 20). Mice were killed after 92 weeks.

Some male mice given the low or high dose of methoxychlor died early, as did some control male mice (Table 21).

Examinations of male and female mice ingesting methoxychlor, particularly female mice, were not adequate (Tables 22 and 23). The 19 male mice on the high dose and 17 male mice on the low dose of methoxychlor were not examined histologically, although some may have been examined grossly. Eleven low dose male mice were dis-

Table 12. Number of male rats ingesting methoxychlor with sarcomas of the spleen, abdomen, or subcutaneous tissue (NCI rat study).^a

Dose	Spleen	Abdominal	Subcutaneous tissue	Total
0	1/20 (5%)	0/20 (0%)	2/20 (10%)	3/20 (15%)
Low dose	8/43 (19%)	2/43 (5%)	1/43 (2%)	11/43 (26%)
High dose	4/41 (10%)	0.084 ^b	3/41 (7%)	11/41 (27%)

^a Corrected for survival time in this and the following tables.

^b Test for positive trend.

Table 13. Number of female rats ingesting methoxychlor with neoplasms of the pituitary (NCI rat study).

Dose	Adenomas	Carcinomas	Total
0	0/20 (0%)	4/20 (20%)	4/20 (20%)
Low dose	7/46 (15%)	8/46 (17%)	15/46 (33%)
High dose	5/49 (10%)	15/47 (32%)	20/47 (43%), $p = 0.067$ 0.038 ^a

^a Test for positive trend.

carded because of autolysis. Large numbers of female mice ingesting methoxychlor were not examined histologically (30 mice on the low dose and 35 mice on the high dose).

Neoplasms of the Liver

Small numbers of male mice ingesting methoxychlor developed carcinomas of the liver, as did the control mice. The carcinomas were larger and more undifferentiated in the methoxychlor-treated mice than in the control mice.

Neoplasms at All Sites

Of females ingesting the low dose of methoxychlor, 34% (6 of 17) developed malignant neoplasms, compared with 1 of 20 (5%) control female mice ($p = 0.0259$) (Table 24). Small numbers of sections of the spleen and lymph nodes showed hyperplasia and/or early lymphomas.

Hemangiosarcomas of the Vertebrae

Hemangiosarcomas of the vertebral bone were present in 12 of 14 female mice (86%) ($p < 0.00001$) and 5 of 33 male mice (15%) ingesting the high dose of methoxychlor, 16 of 16 female mice (100%) ($p < 0.00001$) and 2 of 36 male mice (6%) ingesting the low dose of methoxychlor (Table 25). By contrast, 0 of 20 control male mice (0%) and 1 of 17 control female mice (6%) developed sarcomas of the bone.

Lesions Other Than Neoplasms

Three of 36 male mice (8%) given the low dose of methoxychlor developed thrombosis of the atria of the heart.

Table 14. Number of female rats ingesting methoxychlor with neoplasms of the adrenal gland (NCI rat study).

Dose	Adenomas	Carcinomas	Total
0	2/20 (10%)	1/20 (5%)	3/20 (15%)
Low dose	7/46 (15%)	7/46 (15%)	14/46 (30%)
High dose	7/47 (15%)	11/47 (23%)	18/47 (38%)

^a Test for positive trend.

B6C3F₁ male mice, both untreated and treated, in this laboratory (Hazelton) developed chronic renal disease and amyloidosis of the kidney and spleen, as well as liver; whereas they did not in some other laboratories (Table 26).

Comments

Hemangiosarcomas of the vertebra were strikingly increased in female mice receiving methoxychlor. Such incomplete histopathological examinations do not make it possible to reach conclusions concerning the carcinogenicity of methoxychlor for other organs of mice. Neoplasms of the liver, as well as in other organs, might well be overlooked. There was, however, a slightly increased incidence of malignant neoplasms in female mice given the low dose.

The doses of methoxychlor were toxic and killed many of the mice. The small number of histological sections of spleen and lymph nodes suggested that at least some mice may have developed malignant lymphomas if they had lived for a long enough period of time. There also were severe chronic renal disease, particularly in the male mice (Table 26).

B6C3F₁ female mice given chloroform developed a significant incidence of thrombosis in the atria of the heart (13).

C3H mice are more susceptible to the induction of hepatic neoplasms by the chlorinated hydrocarbons and should be used rather than B6C3F₁ (14, 15).

Summary

Methoxychlor is carcinogenic for bone of female B6C3F₁ mice. There was also a significantly

Table 15. Number of female rats ingesting methoxychlor with carcinomas of the ovary (NCI rat study).

Dose	Adenomas	Carcinomas
0	6/20 (30%)	0/20 (0%)
Low dose	11/46 (24%)	5/46 (11%)
High dose	8/47 (17%)	11/47 (23%), $p = 0.014$ 0.0034 ^a

^a Test for positive trend.

Table 16. Number of female rats ingesting methoxychlor with carcinomas of the mammary gland.

Dose	Female
0	3/20 (15%)
Low dose	15/46 (33%)
High dose	14/47 (30%)

increased incidence of malignant neoplasms at other sites in female mice ingesting the low dose of methoxychlor. Methoxychlor was toxic, particularly to female mice, and large numbers were not examined histologically because of autolysis.

Methoxychlor Mouse Study of Hodge et al.

Male and female mice, 50 of each sex in a group, of the C3H/Anf strain, were housed on wood shavings, 12 or 13 to a cage (16). They were 2-4 months old at the beginning of the treatment. They were given Purina laboratory chow. Methoxychlor was dissolved in trioctanoin (0.05% and 5.0%).

Mice were examined weekly. They were observed until death, at which time the carcass was placed in formalin. Gross necropsy was done later and, if autolysis had not occurred, sections of the skin were taken for histological study.

Subcutaneous

Single subcutaneous injections of 0.02 ml were made in the midscapular region. The mean survival time varied from 372-419 days.

Many mice died with pneumonitis. Neoplasms were not observed in these mice; however, newborn or young mice are preferable for single subcutaneous injection studies rather than mice 2-4 months of age.

Skin Painting

Mice were shaved with an electric clipper and their hair removed from an area approximately 3

× 3 cm in the scapular region. Methoxychlor, 0.10 mg in 0.20 ml of acetone, or methoxychlor, 10 mg in 0.20 ml of acetone, was applied to the area once each week. Mice survived for an average time of 342-450 days.

Neoplasms of the skin were not observed in these mice.

Summary

The oral route should be used for the testing of methoxychlor for carcinogenicity.

Methoxychlor Dog Study of Hodge, Maynard, and Blanchet

Two dogs, sex not given, were each fed 0, 20, 100, or 300 mg/kg/day of methoxychlor for 1 year (17). One female given 100 mg/kg died after 9 months with severe stomach ulcers. Another female dog given 20 mg/kg died after 11 months following an acute illness resembling distemper.

Histological examination was done for heart, lungs, spleen, stomach, large and small intestine, liver, adrenal, kidney, bladder, lymph node, bone marrow, and brain.

Two dogs given 20 mg/kg and the 2 dogs given 300 mg/kg developed hyperplastic lymphoid and marrow tissue and pyelonephritis and granulomas of the kidney, as did 1 control dog. The dog given 150 mg/kg/day for 1 year had acute and chronic cholangitis. One dog receiving 300/mg/kg had mesenteric adenitis.

Summary

Small numbers of dogs were used in this study of limited duration. Dogs given methoxychlor did die and did develop diseases, i.e., cholangitis, mesenteric adenitis, and stomach ulcers, which were not seen in the control dogs.

Methoxychlor Study of Haag et al.

Male and female albino rats about 30 days old and 7 in each group were used. Rats ingested 0,

Table 17. Neoplasms of the liver in female rats ingesting methoxychlor (NCI rat study).

Dose	Hyperplastic nodules	Carcinomas	Total
0	0/20 (0%)	1/20 (5%)	1/20 (5%)
Low dose	2/46 (4%)	1/46 (2%)	3/46 (6%)
High dose	21/47 (45%)	6/47 (13%)	27/47 (58%), ^a $p = 0.00003$
	0.24×10^{-7b}	—	0.39×10^{-8b}
	0.011 ^c	0.066 ^c	0.0019 ^c

^a Twelve additional rats had diffuse hyperplasia of the liver.

^b Test for positive trend.

^c Departure from trend.

Table 18. Number of female rats ingesting methoxychlor with organs studied histologically (NCI rat study).

Organ	0	Low dose	High dose
Liver	20	46	47
Kidney	20	32	30
Spleen	20	46	48
Heart	20	32	30
Lungs	20	33	33
Brain	20	32	30
Salivary gland	0	0	0
Pituitary	20	32	36
Adrenal	20	30	31
Thyroid	20	28	31
Ovary	19	30	30
Urinary bladder	20	32	30
Pancreas	20	31	30
Uterus	19	34	35
Bone marrow	20	31	30
Lymph node	20	30	28
Stomach	20	31	31

300, 600, 900, 1200, 2500, 5000, or 10000 ppm of methoxychlor (recrystallized) in ground Purina dog chow for periods up to 1 year (18).

Histological examinations on selected rats were done for heart, lungs, gastrointestinal tract, liver, spleen, kidney, adrenal, pancreas, thyroid, gonads, skeletal muscle, and skin. In some cases, bone marrow and brain were examined. Examinations were done on 7 rats at 1000 ppm, 7 rats at 5000 ppm, 1 at 2500 ppm, and 1 at 600 ppm.

Female rats ingesting 10000 ppm methoxychlor became emaciated and died within 10 weeks. Male and female rats given the other doses of methoxychlor survived about as well as the control rats. Retarded growth was observed in males and females given 2500 ppm. Lymphosarcomas were found in 1 rat given 2500 ppm and 1 rat receiving 600 ppm methoxychlor.

Table 19. Number of male rats ingesting methoxychlor with organs sectioned histologically (NCI rat study).

Organ	0	Low dose	High dose
Liver	19	37	37
Kidney	19	21	28
Spleen	20	44	42
Heart	20	21	20
Lungs	20	20	23
Brain	20	19	20
Salivary gland	0	0	2
Pituitary	18	21	22
Adrenal	20	18	19
Thyroid	19	27	24
Testes	15	19	21
Pancreas	19	20	20
Urinary bladder	20	16	21
Bone marrow	20	18	20
Lymph nodes	18	15	17
Stomach	20	20	21

Table 20. Dose levels for male and female mice ingesting methoxychlor (NCI mouse study).

	Males		Females	
	Low	High	Low	High
Initial dose, ppm	1400	2800	750	1500
Average dose, ppm	1746	3941	997	1994

Small numbers of rats were used in this study. Histological examinations were limited. Results were not separated by sex.

Methoxychlor Rat Study of Radomsky et al.

Methoxychlor

Methoxychlor, 80 ppm, was added to Purina laboratory chow supplemented with 1% cod liver oil (19). The diet was ingested by Osborne-Mendel weanling male and female rats, 30 in each group, for 2 years. Control rats were given the diet without the pesticide. All rats which died or were killed were examined for the presence of tumors. Tumors were examined histologically.

Treated rats did not have more tumors than the control rats; however, control rats developed a high incidence of tumors, particularly mammary gland. In addition, histological examinations were incomplete.

Methoxychlor Plus Other Pesticides

A mixture of 50 ppm of each of methoxychlor, DDT, aramite, and thiourea was ingested by 50 rats of each sex under comparable conditions (given above). Groups of rats were not given the individual pesticides by themselves.

Six of 50 control female rats (12%) had hepatic tumors compared to 9 of 49 female rats (18%) given the mixture. Tumors of the liver were observed in 1 of 50 male control rats (2%) and 10 of 50 male rats (20%) ingesting the mixture of pesticides ($p = 0.0039$).

Another mixture of 80 ppm of each pesticide

Table 21. Survival times for mice ingesting methoxychlor (NCI mouse study).

Dose	Survival time, weeks			
	Males		Females	
	Average	Range	Average	Range
0	72.1	21-92	89.2	80-92
Low dose	73.4	24-92	90.8	71-93
High dose	80.3	34-92	91.8	32-93

Table 22. Gross and/or histopathology or no examinations of male mice ingesting methoxychlor (NCI mouse study).

	0	Low dose	High dose
Initially	20	50	50
Missing	—	—	1
Necropsied	12	39	47
Histopathology	12	33	31
Necropsied/no histopathology	—	6	16
Autolysis/no necropsy	8	11	2

was given to rats. An increase in tumors of the liver was not noted. Toxicity was not described in these rats.

Summary

Methoxychlor given with DDT, aramite, and thiorea is carcinogenic for the liver of male rats. Untreated female rats developed an unusually high incidence of neoplasms of the liver. Additional data are needed in order to draw further conclusions from this study.

Methoxychlor Rat Study of Hodge et al.

Male and female rats, 25 per group, ingested 0, 25, 200, or 1600 ppm of methoxychlor in Purina fox chow meal with meat for two years (17). Surviving rats were killed and necropsied. Histological examination was done for heart, lungs, spleen, stomach, small and large intestine, adrenal, kidney, testes, bladder, bone marrow, and brain, as well as any abnormal tissues.

Growth was not affected in rats receiving 25 or 200 ppm methoxychlor; however, there was growth retardation in rats given 1600 ppm. Male rats had lost 50 g and female rats 20 g at the end of 1 year. Mortalities of 4-30% occurred in the various groups during the first year and infection caused many deaths. There were large numbers of rats that were unaccounted for in this study.

Four of 11 females (36%) and one of five male

Table 23. Gross and/or histopathology or no examinations of female mice ingesting methoxychlor (NCI mouse study).

	0	Low dose	High dose
Initially	20	50	50
Missing	—	1	—
Necropsied	20	47	50
Histopathology	20	17	15
Necropsied/no histopathology	—	30	35
Autolysis/no necropsy	—	2	—

Table 24. Malignant neoplasms at sites other than the vertebrae in female mice ingesting methoxychlor (NCI mouse study).^a

Dose	Females
0	1/20 (5%)
Low dose	6/17 (35%), $p = 0.0259$
High dose	1/15 (7%)

^a Only animals that had histological examinations are included.

rats (20%) ingesting 1600 ppm, one of seven female rats (14%) given 200 ppm, and two of ten female rats (20%) given 25 ppm developed neoplasms, whereas zero of eight male and five female control rats had neoplasms. A total of seven of 28 female rats (25%) ingesting methoxychlor had neoplasms. There were six surviving male rats, three receiving 25 ppm and three given 200 ppm methoxychlor, that did not develop neoplasms.

The neoplasms in the female rats ingesting 1600 ppm methoxychlor were cystadenoma of the ovary, neoplasms of the abdominal wall, adenocarcinoma of the pancreas, and epidermoid carcinoma. There was a mammary neoplasm in a female rat given 200 ppm and neurofibroma and lung neoplasms in the female rats receiving 25 ppm. One male rat given 1600 ppm had a mammary tumor.

The authors stated that: "One of the most frequent causes of death during the second year in our rats is cancer. The large number of tumors in the 0.16% group of females is believed to be coincidental." However, the data concerning neoplasms developing in rats in this study during the second year were not given.

The results of the study suggest that methoxychlor is carcinogenic, particularly for female rats. An unusual neoplasm, adenocarcinoma of the pancreas, was present in a treated female rat. Since additional data concerning all rats that died or were killed before the end of two years is unavailable, conclusions cannot be made from this study.

Table 25. Hemangiosarcomas of the vertebrae in male and female mice ingesting methoxychlor (NCI mouse study).

Dose	Males	Females
0	0/20 (0%)	1/17 (6%)
Low dose	2/36 (6%)	16/16 (100%), $p < 0.00001$
High dose	5/33 (15%)	12/14 (86%), $p < 0.00001$
	0.03132 ^a	0.18×10^{-7a} 0.0002 ^b

^a Test for positive trend.

^b Departure from trend.

Table 26. Number of male mice ingesting methoxychlor with chronic renal disease and amyloidosis of the spleen and kidney (NCI mouse study).^a

Dose	Chronic renal disease	Amyloidosis	
		Spleen	Kidney
0	4/12 (33%)	4/12 (33%)	1/12 (8%)
Low dose	10/36 (33%)	9/36 (25%)	4/36 (11%)
High dose	1/33 (3%)	2/33 (6%)	0/33 (0%)

^a These data are not reliable because many of the kidneys and spleens were not examined histologically.

Methoxychlor Rat Study of Deichmann et al.

Osborne-Mendel male and female rats, 30 per group, were used. Rats ingested 0 or 1000 ppm methoxychlor (recrystallized) in ground Purina laboratory chow for 27 months (20).

The liver, heart, lung, brain, pituitary, kidney, spleen, pancreas, stomach, small intestine, and testes or ovary, as well as all tumors, were examined histologically.

The weight of the rats ingesting methoxychlor remained the same during the second year. At the end of 24 months, 43% of the male rats and 37% of the female rats given methoxychlor were living compared to 50% and 60% of the control rats.

Five of 28 male rats (18%) ingesting methoxychlor developed neoplasms, compared to 1 of 28 control male rats (4%). Data concerning the location or the number of malignant neoplasms are not given for these rats. Many of the neoplasms in female rats were mammary gland.

There was hydropic change, fatty change, and focal centrolobular necrosis in the liver and hemosiderin in the spleen of methoxychlor-treated rats.

There was an increased incidence of neoplasms in male rats ingesting methoxychlor; however, the data given are incomplete and conclusions cannot be made concerning the effects of methoxychlor.

Comments

BALB/c strain male mice ingesting methoxychlor developed a highly significant incidence of interstitial cell carcinomas of the testes. Since BALB/c strain male mice treated with estrogens readily develop carcinomas of the testis, the carcinogenicity of methoxychlor for testis is most likely related to its estrogenic activity (2). Methoxychlor was estrogenic for the mammary gland and uterus in swine in the FDA studies (6-8).

The estrogenic activity of methoxychlor, DDT, and other analogs has been established. There are some structural similarities between these compounds and diethylstilbestrol (21). Technical methoxychlor stimulated uterine growth in mice and rats (22); caused atrophy and abnormal development of the testis of young male rats (23,24); interfered with reproduction in rats (25); and interfered with the *in vivo* uptake of estradiol by the rat uterus (26, 27).

DDT, the structural analog of methoxychlor, is carcinogenic for the liver of mice and rats and for the ovary of rats (28-35).

The formation and occurrence of tumors in all mammals is quite similar. Virtually every chemical which has been found to be carcinogenic in humans is also carcinogenic in one or more other mammalian test animals (36). It has been demonstrated that if a chemical will produce neoplasms in any one species, it will likely produce neoplasms in another. We strongly feel that a finding of carcinogenicity in one mammalian species is therefore relevant to all mammals, including humans. This threat may not be manifested for up to 30 or 40 years, given the long latent period of many known human carcinogens. Given the state of carcinogenicity testing and knowledge, there can be only one safe tolerance for a carcinogen—an absolute zero tolerance—and the only way a substance shown to be carcinogenic in test animals will not be a threat to human health is simply to prevent that substance from entering the environment. To the extent that it does enter man's environment, it will constitute a very real threat to his health.

The carcinogenicity of methoxychlor was reviewed at the IARC. They concluded that "the available data did not provide evidence that methoxychlor is carcinogenic in animals."

Interpretation of carcinogenicity studies varies with the reviewer. Problems are often found with the incomplete presentation and analysis of the data, as well as with different diagnoses by pathologists (37). The IARC monograph did not include the FDA mouse and rat studies on methoxychlor because "... , only reports that have been published or accepted for publication are reviewed by the working groups, ..." (38).

The statistical analyses, one sided P (probability) values, were done by C. W. Riggs, Frederick Cancer Research Center, Frederick, Maryland, 21701. The NCI methoxychlor rat and mouse studies were performed under contract at Hazleton Laboratories, Inc.

REFERENCES

1. Davis, K. J. Histopathological diagnosis of lesions noted in mice fed DDT or methoxychlor. Prepared as a memoran-

- dum to W. Hansen, Food and Drug Administration, Washington, D.C., January 30, 1969.
2. Reuber, M. D. Interstitial cell carcinomas of the testis in BALB/c male mice ingesting methoxychlor. *J. Cancer Res. Clin. Oncol.* 93: 173 (1979).
 3. Davis, K. J., and Fitzhugh, O. G. Tumorigenic potential of aldrin and dieldrin in mice. *Toxicol. Appl. Pharmacol.* 4: 197 (1962).
 4. Nelson, A. A. Pathological changes produced in rats by feeding of methoxychlor at levels up to 0.2% of diet for two years. Prepared as a memorandum to A. J. Lehman, Food and Drug Administration, Washington, D. C., October 23, 1951.
 5. Nelson, A. A. Pathological changes produced in dogs by feeding of methoxychlor 300 mg/kg/day for 3-1/2 years. Prepared as a memorandum to A. J. Lehman, Food and Drug Administration, Washington, D. C., June 9, 1953.
 6. Bierbower, G. W. Histopathology in miniature swine fed methoxychlor in the diet. Prepared as a memorandum to A. J. Lehman, Food and Drug Administration, Washington, D. C., May 27, 1966.
 7. Bierbower, G. W. Histopathology in castrated male swine fed methoxychlor mixed in the diet. Prepared as a memorandum to A. J. Lehman, Food and Drug Administration, Washington, D. C., April 18, 1967.
 8. Bierbower, G. W. Histopathology in young castrated miniature swine fed methoxychlor mixed in the diet. Prepared as a memorandum to A. J. Lehman, Food and Drug Administration, Washington, D. C., July 24, 1967.
 9. Nelson, A. A. Pathological changes in rabbits produced by injection of methoxy DDT, 30% in NTM. Prepared as a memorandum to A. J. Lehman, Food and Drug Administration, Washington, D. C., December 9, 1942.
 10. Bioassay of methoxychlor for possible carcinogenicity. NCI Carcinogenesis Technical Report Series No. 35, 1978.
 11. Reuber, M. D. Testimony at hearings in Aldrin/Dieldrin. EPA and Environmental Defense Fund vs. Shell. FIFRA Docket No. 145, 1973.
 12. Reuber, M. D. Hepatic vein thrombosis in mice ingesting chlorinated hydrocarbons. *Arch. Toxicol.* 38: 163 (1977).
 13. Reuber, M. D. Carcinogenicity of chloroform. *Environ. Health Perspect.* 31: 171 (1979).
 14. Reuber, M. D. Histopathology of carcinomas of the liver in mice ingesting heptachlor or heptachlor epoxide. *Exptl. Cell Biol.* 45: 147 (1977).
 15. Reuber, M. D. Histopathology of carcinomas of the liver in mice ingesting dieldrin or aldrin. *Tumori* 62: 463 (1976).
 16. Hodge, H. C., Maynard, E. A., Downs, W. C., Ashton, J. K., and Salerno, L. L. Tests on mice for evaluating carcinogenicity. *Toxicol. Appl. Pharmacol.* 9: 583 (1966).
 17. Hodge, H. C., Maynard, E. A., and Blanchet, H. J., Jr. Chronic oral toxicity tests of methoxychlor (2,2-di-*p*-methoxyphenyl)-1,1,1-trichloroethane) in rats and dogs. *J. Pharmacol. Exptl. Therap.* 104: 60 (1952).
 18. Haag, H. B., Finnegan, J. K., Larson, P. S., Riese, W., and Dreyfuss, M. L. Comparative chronic toxicity for warm-blooded animals of 2,2-bis-(*p*-chlorophenyl)-1,1,1-trichloroethane (DDT) and 2,2-bis-*p*-methoxyphenyl)-1,1,1-trichloroethane (DDMT, methoxychlor). *Arch. Internat. Pharmacodyn.* 83: 491 (1950).
 19. Radomski, J. L., Deichmann, W. B., MacDonald, W. E., and Glass, E. M. Synergism among oral carcinogens. I. Results of the simultaneous feeding of four tumorigens to rats. *Toxicol. Appl. Pharmacol.* 7: 652 (1965).
 20. Deichmann, W. B., Keplinger, M., Sala, F., and Glass, E. M. Synergism among oral carcinogens. IV. The simultaneous feeding of four tumorigens to rats. *Toxicol. Appl. Pharmacol.* 11: 88 (1967).
 21. Bitman, J., and Cecil, H. C. Estrogenic activity of DDT analogs and polychlorinated biphenyls. *J. Agr. Food Chem.* 18: 1108 (1970).
 22. Tullner, W. W. Uterotrophic action of the insecticide methoxychlor. *Science* 133: 647 (1961).
 23. Hodge, H. C., Maynard, E. A., Thomas, J. F., Blanchet, H. S., Jr., Wilt, W. G., Jr., and Mason, K. E. Short-term oral toxicity tests of methoxychlor (2,2-di(*p*-methoxyphenyl)-1,1,1-trichloroethane) in rats and dogs. *J. Pharmacol. Exptl. Therap.* 99: 140 (1950).
 24. Tullner, W. W. and Edgcomb, J. H. Cystic tubular nephropathy and decrease in testicular weight in rats following oral methoxychlor treatment. *J. Pharmacol. Exptl. Therap.* 138: 126 (1962).
 25. Harris, S. J., Cecil, H. C., and Bitman, J. Effect of several dietary levels of technical methoxychlor on reproduction in rats. *J. Agr. Food Chem.* 22: 969 (1974).
 26. Welch, R. M., Levin, W., and Conney, A. H. Estrogenic activity of DDT and its analogs. *Toxicol. Appl. Pharmacol.* 14: 358 (1969).
 27. Nelson, J. A. Effects of dichlorodiphenyltrichloroethane (DDT) analogs and polychlorinated biphenyl (PCB) mixtures on 17β -[^3H] estradiol binding to rat uterine receptor. *Biochem. Pharmacol.* 23: 447 (1974).
 28. Tarján, R. and Kemeny, T. Multigenerational studies on DDT in mice. *Food Cosmet. Toxicol.* 7: 215 (1969).
 29. Terracini, B., Testa, M. C., Cabral, J. R., and Day, N. The effects of long-term feeding of DDT to BALB/c mice. *Int. J. Cancer* 11: 747 (1973).
 30. Tomatis, L., Turosov, V., Day, N., and Charles, R. T. The effect of longterm exposure to DDT on CF₁ mice. *Int. J. Cancer* 10: 489 (1972).
 31. Turosov, V. S., Day, N., Tomatis, L., Gati, E., and Charles, R. T. Tumors in CF₁ mice exposed for six consecutive generations to DDT. *J. Natl. Cancer Inst.* 51: 983 (1973).
 32. Vlahakis, G. and Reuber, M.D. Carcinomas of the liver in C3H-AxY-fB mice ingesting DDT. In preparation.
 33. Reuber, M. D. Carcinomas of the liver in Osborne-Mendel rats ingesting DDT. *Tumori* 64: 571 (1978).
 34. Rossi, L., Ravern, M., Repetti, G., and Santi, L. Long-term administration of DDT or phenobarbital-Na in Wistar rats. *Int. J. Cancer* 19: 179 (1977).
 35. Fitzhugh, O. G., and Nelson, A. A. The chronic oral toxicity of DDT (2,2-bis-*p*-chlorophenyl-1,1,1-trichloroethane). *J. Pharmacol. Exptl. Therap.* 89: 13 (1947).
 36. Reuber, M. D. Carcinogenicity testing of chemicals with particular reference to organochlorine pesticides. *Sci. Total Environ.* 10: 105 (1978).
 37. Reuber, M. D. Review of toxicity test results submitted in support of pesticide tolerance petitions. *Sci. Total Environ.* 9: 135 (1977).
 38. IARC Monographs on the Evaluation of the Carcinogenic Risk of Chemicals to Humans. Some halogenated hydrocarbons. World Health Organization, IARC, Lyon, France, 1979, pp. 259-281.