

The second case, a woman aged 26, presented with a six-month history of intermittent abdominal pain and diarrhoea, the stools being semi-formed and not containing blood. She was noted to be anxious but no other abnormality was found on examination, including sigmoidoscopy. The initial clinical diagnosis was that of the irritable bowel syndrome. A barium enema, barium meal and follow-through, and a colonic motility study showed no abnormality. A rectal biopsy specimen taken routinely at the initial sigmoidoscopy showed submucosal granulomata very similar to those of case 1.

The third case, a man aged 26, gave a six-month history of intermittent abdominal pain and diarrhoea with stools of ribbon-like appearance. Blood had been noted in the stool on two isolated occasions but had been attributed to haemorrhoids. Examination, including sigmoidoscopy, disclosed no abnormality, and a provisional diagnosis of the irritable bowel syndrome was made. A barium enema and barium meal and follow-through were normal but a rectal biopsy specimen showed typical sarcoid-type granulomata similar to those in the first case.

### Discussion

The rectum is macroscopically affected in only about half the cases of Crohn's disease of the colon.<sup>1</sup> Biopsy of normal-looking rectal mucosa may be reluctantly performed when the history and examination findings are typical of the irritable bowel syndrome. This reluctance may be reinforced by a normal barium enema and barium meal and follow-through.

The cases presented here, however, illustrate the importance of biopsy under these circumstances. All three were young people with a tendency to anxiety or introspection, and their symptoms were entirely consistent with the irritable bowel syndrome. A striking histological feature of the rectal mucosa in these cases was the contrast between the pronounced submucosal granulomatous changes and the intact state of the surface mucosa. This characteristic distribution of the lesions presumably accounts for the normal macroscopic appearances on sigmoidoscopy and barium enema. A rectal biopsy should be carried out routinely in apparent cases of irritable bowel syndrome even when the rectal mucosa looks normal.

I thank Drs W Sircus and J N Webb for their advice and criticism, and Drs Sircus, M A Eastwood, and Anne Ferguson for permission to report the cases of patients under their care.

<sup>1</sup> Lennard-Jones, J E, Lockhart-Mummary, H E, and Morson, B C, *Gastroenterology*, 1968, **54**, 1162.

Gastrointestinal Unit, University of Edinburgh, Western General Hospital, Edinburgh EH42XU

M WARD, MB, MRCP, lecturer in gastroenterology

## Immunodepressive serum treatment of acute heart transplant rejection

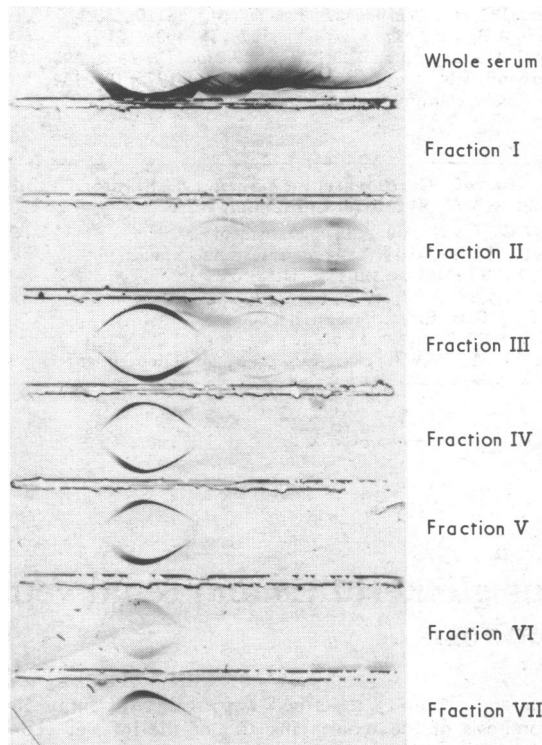
Immunodepressive factors in serum<sup>1</sup> appear to be naturally occurring proteins that depress lymphocyte activity in vitro. We have been studying them in heart transplant recipients for the past few years.<sup>2</sup> This report describes their use for the first time in acute cardiac allograft rejection.

### Case report

A 15-year-old boy with fulminating cardiomyopathy received a heart transplant on 19 August 1974. Lymphocyte tissue culture studies showed a lack of immunodepressive factors in his serum<sup>2</sup> but a normal lymphocyte reactivity screen. Subsequently he began to reject severely, and despite steroids, azathioprine, and rabbit antihuman thymocyte globulin he continued to deteriorate with a drop in QRS voltage, biopsy on day 50 showing acute rejection. At the time, studies were being done on another heart recipient, who had the most powerful depressive factors encountered by our laboratory. We decided to transfuse two units of plasma from this patient into the first patient to try to reduce severity of rejection. The second patient underwent plasmapheresis, and two units of his plasma were absorbed with washed A and B cells. This was continued until the Coombs test result

became negative. On 10 October the first patient was transfused with the depressive serum, tests showing that it depressed in-vitro lymphocyte responses. Clinically he improved and was successfully supported until retransplanted on 15 October. Subsequently he did well, returned to school, and was leading an active life.

Serum from the second patient was fractionated on Sephadex G-200; seven fractions were recovered, the highest molecular weight proteins being eluted in fraction I, and the lowest in fraction VII. Immunoelectrophoresis of each fraction (fig) after dialysis and concentration using a Diaflo 5UM2 ultrafiltration membrane showed that fractions I, III, and IV depressed the mixed lymphocyte responses, whereas the others did not.



Immunoelectrophoresis of serum fractions from second patient. Fraction I appeared to be  $\alpha_2$ -macroglobulin. Fractions III and IV contained albumin and  $\alpha$ -,  $\beta$ -, and  $\gamma$ -globulin; the latter was thought to be the effective component.

### Discussion

There appear to be factors in normal human serum that inhibit or dampen lymphocyte activity, and these may be the equivalent of a normal hormonal regulatory mechanism. In some diseases they are increased, cellular immunity being impaired accordingly.<sup>3</sup> There appear to be three classes of depressive factors— $\alpha_2$ -macroglobulins,  $\gamma$ -globulin, and toxic factors related to uraemic states or toxic metabolic factors resulting from impaired hepatic or cardiac function. Possibly patients with chronic severe heart failure or after cardiopulmonary bypass have increased amounts of similar depressive factors, which after transplantation may dampen their cellular immunity by depressing lymphocyte activity.<sup>2</sup>

Occhino *et al*<sup>1</sup> have isolated an immunosuppressive peptide fraction from Cohn fraction IV of normal plasma that suppresses both the phytohaemagglutinin-induced lymphocyte proliferation in vitro and the in-vivo induction of splenic plaque-forming cells in mice. Most authorities agree that the factor must be added to the cultures early to have maximal effect. Cooperband *et al*<sup>4</sup> showed that the factor has its own receptor on the lymphocyte surface and that this differs from the receptor for mitogen activation. Other workers have suggested that inhibition may be mediated by the depressing substance neutralising the cellular mediators secreted by stimulated lymphocytes.

Several reports have emphasised the role of IgG as an immunodepressive; sera from dogs with kidney transplants contain an inhibitory factor that migrates with IgG, and human alloimmune plasma also has a direct inhibitory effect on responding lymphocytes in culture.<sup>5</sup>

Based on the Sephadex fractionation and immunoelectrophoretic studies the serum from the second patient appears to have contained two factors, one of high molecular weight—probably  $\alpha_2$ -macroglobulin—and the other of lower molecular weight—probably

$\gamma$ -globulin. When more fully characterised there is hope that these factors may be useful as adjuvants to conventional immunosuppressive regimens and may find regular application in the protocol for the treatment of severe rejection rather than being used as a "last-ditch" measure.

This work was supported by National Heart and Lung Institute Research grants HL 08696 and HL 13108, and US Public Health Service Research grant RR 70.

- <sup>1</sup> Occhino, J C, *et al*, *Journal of Immunology*, 1973, **110**, 685.
- <sup>2</sup> Coulson, A S, *et al*, *Transplantation*, 1974, **18**, 409.
- <sup>3</sup> Coulson, A S, and Inman, D R, *Guy's Hospital Reports*, 1971, **120**, 89.
- <sup>4</sup> Cooperband, S R, *et al*, *Journal of Immunology*, 1972, **109**, 154.
- <sup>5</sup> Buckley, R H, *et al*, *Journal of Immunology*, 1972, **108**, 34.

Department of Cardiovascular Surgery, Stanford University Medical Centre, Stanford, California, USA

ALAN S COULSON, MB, PHD, chief resident  
 VIRGINIA H ZEITMAN, BS, ASCP, research technician  
 EDWARD B STINSON, MD, associate professor  
 RANDALL B GRIEPP, MD, assistant professor  
 CHARLES P BIEBER, MD, research associate  
 EUGENE DONG jun, MD, associate professor  
 NORMAN E SHUMWAY, MD, FACS, chairman of department

## Lupus glomerulitis and renal vein thrombosis

Hamilton and Tumulty described a patient with lupus nephritis and thrombosis of the renal veins and of the inferior vena cava.<sup>1</sup> We report here a case of systemic lupus erythematosus with lupus glomerulitis, unilateral renal vein thrombosis, and the nephrotic syndrome.

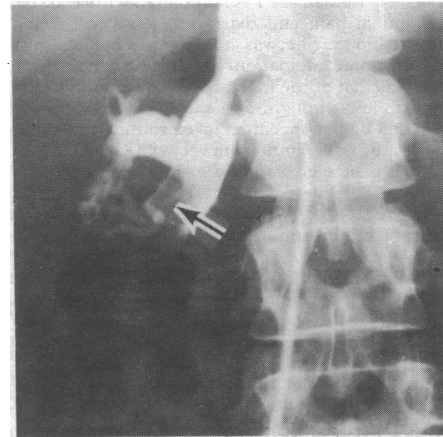
### Case report

A 24-year-old woman was admitted to hospital in January 1975 because of fever, myalgia, and arthralgia of two years' duration. She had frontal alopecia, splenomegaly, hemolytic anaemia, leucopenia, positive LE cell test, and a C3 of 0.56 g/l (normal 0.9-1.8). SLE was diagnosed. The urine contained protein, occasional red and white blood cells (high power field), and a few granular casts. Serum creatinine was 62  $\mu$ mol/l (0.7 mg/100 ml), albumin 24 g/l, and cholesterol 3.6 mmol/l (140 mg/100 ml). Creatinine clearance was 84 ml/min and 24-hour urinary protein excretion was 5.2 g. An intravenous pyelogram showed nothing abnormal. Renal biopsy showed slight mesangial hypercellularity and focal glomerulitis with one haematoxylin body. She was discharged on 20 mg of prednisone and 6 mg of chlorambucil daily.

By April, despite restoring the serological abnormalities to normal (negative ANF anti-DNA tests and a C3 of 0.92 g/l), she had oedema up to the thighs. Prednisone was increased to 60 mg/day and she was readmitted. Her serum albumin was 13 g/l, cholesterol 9.2 mmol/l (355 mg/100 ml), and the urinary protein loss 18.6 g/24 h. The platelet count and coagulogram were normal and no cryoglobulins were found. Renal venography showed a non-occlusive thrombus on the right side (fig). Diuretics were given along with heparin. By May the oedema had gone and the serum albumin had risen to 21 g/l. Protein loss was 9 g/24 h. When last seen in July 1975 she was symptom free, with a serum albumin of 38 g/l and normal serology and creatinine clearance, but she was excreting protein 5 g/24 h. She was receiving warfarin, dipyridamole, prednisone, and chlorambucil.

### Discussion

The normal anti-DNA titre and the hypocomplementaemia at the onset of massive proteinuria in this patient suggests a renal disease other than lupus.<sup>2</sup> Unilateral renal vein thrombosis may be associated with the nephrotic syndrome,<sup>3</sup> in some cases of which a hypercoagulable state has been identified,<sup>4</sup> but the normal coagulogram was against this in our case. There was no evidence of thrombotic thrombocytopenic purpura, intravascular coagulopathy,



Non-occlusive thrombus in major inferior renal vein (arrow) on right side.

Raynaud's phenomenon, macroglobulinaemia, or cryoglobulinaemia—conditions that are associated with SLE and could result in transient or permanent vascular occlusion.

The most common glomerular lesion associated with renal vein thrombosis is membranous glomerulopathy.<sup>5</sup> The association in our case, however, is more difficult to explain. Minimal glomerular disease, such as glomerulitis, in SLE rarely causes massive proteinuria. Factors predisposing to deep venous thrombosis, such as oral contraception, pregnancy, and pelvic or extremity phlebitis, were absent. We must assume that she had either a lupus glomerulitis which caused the nephrotic syndrome and that the latter led to renal vein thrombosis, or that she had lupus glomerulitis and a concomitant, but unrelated, renal vein thrombosis. Whichever is correct, a full renal investigation, including venography or delayed arteriography, seems appropriate whenever the renal manifestations of lupus are greater than the renal lesion or the extrarenal and serological activity of the disease seem to warrant, since prompt diagnosis and early anticoagulation treatment of renal vein thrombosis reduce further renal damage.

- <sup>1</sup> Hamilton, C, and Tumulty, P, *Journal of the American Medical Association*, 1968, **206**, 2315.
- <sup>2</sup> Townes, A, *Johns Hopkins Medical Journal*, 1967, **120**, 337.
- <sup>3</sup> Moore, H L, *et al*, *Pediatrics*, 1972, **50**, 598.
- <sup>4</sup> Kendall, A G, Lohmann, R C, and Dossetor, J B, *Archives of Internal Medicine*, 1970, **127**, 1021.
- <sup>5</sup> Johannessen, J V, *Archives of Pathology*, 1974, **97**, 277.

Department of Internal Medicine, American University of Beirut Hospital, Beirut, Lebanon

GEORGE S BRIDI, MD, clinical assistant professor, nephrology section  
 RIDA A FRAYHA, MD, assistant professor rheumatology section

## Serum ferritin levels in acute hepatocellular damage from paracetamol overdose

Serum ferritin levels accurately reflect the iron storage status of the individual in health and also in certain diseases.<sup>1</sup> In liver disease, however, levels are elevated, reflecting hepatocellular damage, and Prieto *et al*<sup>2</sup> found a close linear correlation between the serum ferritin-transaminase ratio and liver iron concentration. We have measured serum ferritin levels in 25 patients admitted for acute paracetamol overdose and examined their correlation with both transaminase levels and the degree of hepatocellular damage ascertained from liver biopsy.