

Section of Ophthalmology

President Norman Ashton FRS

Meeting November 11 1971

Neuro-ophthalmology

Mr T H Kirkham (*The National Hospital, Queen Square, London WC1*)

The Ocular Symptomatology of Pituitary Tumours

Early recognition of pituitary tumours is often the responsibility of the ophthalmologist (Lyle & Clover 1961). The purpose of this paper is to describe the ocular symptomatology of patients with bitemporal hemianopia. A single illustrative case is described.

Case Report

A 59-year-old woman was admitted to the National Hospital under the care of Dr C J Earl, with a ten-year history of failing vision. Symptoms arose when visual tasks demanding anteroposterior orientation were undertaken; for example, difficulty was experienced in cutting finger nails and pruning roses.

For the past year she had experienced intermittent difficulty with reading, gaps appearing in the page, in lines of print or in individual words. Occasionally the page appeared to split and the two portions to separate in a vertical direction making it impossible to scan the page. Alteration of head posture had no effect on these symptoms. Intermittent distortion of objects was noticed; usually there was splitting and separation in a vertical direction of shelves, cars and people's faces and bodies.

On examination the visual acuity was 6/60 in each eye and perimetry revealed a dense bitemporal hemianopia. The pupillary reactions were normal. The fundi showed slight pallor of the optic discs. The ocular movements were of normal range and velocity. At operation a large chromophobe adenoma with suprasellar extension was excised. Postoperatively the visual acuity improved to 6/9 in each eye and the fields returned to normal.

Discussion

The presence of a bitemporal defect may give rise to two groups of visual symptoms (Nachtigaller & Hoyt 1970) which are well illustrated by the

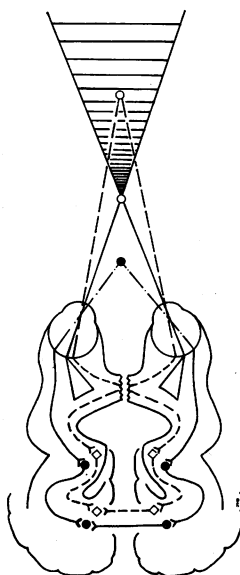


Fig 1 The shaded area represents the blind area beyond the fixation point which is present in patients with a bitemporal hemianopia

present patient. The first group consists of difficulties with depth perception and may be called 'chiasmatic post-fixational blindness', and the second group of complaints is that of horizontal or vertical separation of images occurring in the absence of a muscle paresis and may be called the 'hemifield slide phenomenon'.

Chiasmatic post-fixational blindness: This group of symptoms depends upon the fact that there is a blind area beyond the fixation point of a patient with a bitemporal hemianopia (Fig 1). The image of an object posterior to fixation falls on nasal retina which in patients with bitemporal hemianopia is blind and therefore such objects in the central field of vision disappear. Patients in this group have multiple symptoms relating to precision tasks demanding anteroposterior orientation such as cutting finger nails, threading needles,

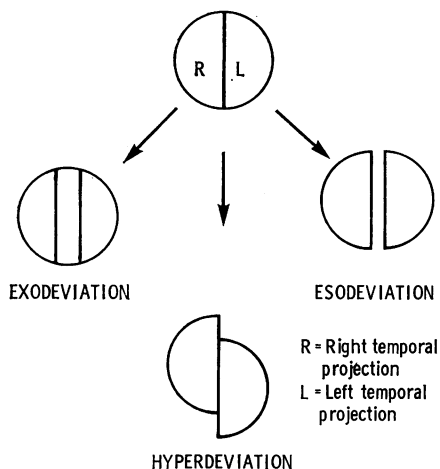


Fig 2 The possible overlap or separation of the two half fields

using screwdrivers or performing precision surgery. There may also be complaints of difficulty with focusing and judging distance. Blakemore (1970) described the case of a man with traumatic splitting of his chiasm who was unable to appreciate depth beyond his fixation point but who had normal depth perception anterior to fixation because such objects were imaged on temporal, seeing, retina. Depth perception proximal to fixation depends on physiological linkage of the half fields across the corpus callosum and the studies of Hubel & Wiesel (1967) support the concept of binocularly driven cortical cells dependent upon the presence of such interhemispheric linkages.

The hemifield slide phenomenon: The second group of complaints is that of horizontal or vertical deviation of images occurring in the absence of a muscle paresis.

Stone (1966) analysed the ganglion cell density in the central area of the retina and found there to be a vertical median strip of the retina, 0.2 mm wide, from which the ganglion cells projected to both optic tracts. Because of the overlap of the receptive fields of ganglion cells in the vertical median strip the visual fields appear uniform without interruption in the mid-line (Hubel & Wiesel 1967). The literature concerning the naso-temporal overlap of the visual fields has been summarized by Sanderson & Sherman (1971).

Patients with bitemporal hemianopia, whose visual fields represent only the temporal projection from each eye, do not have a physiological linkage between the two half fields.

Fisher *et al.* (1968) compared the situation of a one-eyed man to that of a patient with bitemporal

hemianopia. Although both have a full field of vision the hemianopic patient has an unstable field and the patient they described had binocular single vision when the eyes were still, but could not maintain this when the eyes were moving.

The presence of a motor imbalance therefore produces sensory problems for the patient with bitemporal hemianopia since the loss of physiological linkage results in difficulty in maintaining in juxtaposition the two half fields and thus exo-, eso- or hyper-deviation produce startling results, objects appearing respectively to overlap, separate horizontally or diverge vertically (Fig 2). It must be emphasized that the occurrence of these symptoms is intermittent.

The earliest clinical documentation of this sensory phenomenon was the case described by Fisher (1911) of a man who could not count rows of cocoa trees and who experienced transient diplopia on a sea voyage, seeing four funnels on a ship instead of the two she possessed. Episodes of diplopia in the absence of muscle paresis have often been described in patients with pituitary tumours (Beckman & Kubie 1929, Kubie & Beckman 1929, Chamlin *et al.* 1955, Lyle & Clover 1961, Wybar & Bloom 1963, Elkington 1968, Nachtigaller & Hoyt 1970). The term 'non-paretic diplopia' was introduced by Bardram (1949) to describe this condition. The term 'hemifield slide phenomenon' seems preferable, however, since it describes pictorially the symptoms of these patients and recalls the underlying physiological mechanism responsible for their production.

Acknowledgments: I am indebted to Dr C J Earl for permission to report his case and to Mr J Banfield for the illustrations.

REFERENCES

- Bardram M T
(1949) *Acta ophthalmologica (København)* 27, 225
- Beckman J W & Kubie L S
(1929) *Brain* 52, 127
- Blakemore C (1970) *Vision Research* 10, 43
- Chamlin M, Davidoff L M & Feiring E H
(1955) *American Journal of Ophthalmology* 40, 353
- Elkington S G
(1968) *British Journal of Ophthalmology* 52, 322
- Fisher J H (1911) *Transactions of the Ophthalmological Society of the United Kingdom* 31, 51
- Fisher N F, Jampolsky A & Flom M C
(1968) *American Journal of Ophthalmology* 65, 574
- Hubel D H & Wiesel T N
(1967) *Journal of Neurophysiology* 30, 1561
- Kubie L S & Beckman J W
(1929) *Brain* 52, 317
- Lyle T K & Clover P
(1961) *Proceedings of the Royal Society of Medicine* 54, 611
- Nachtigaller H & Hoyt W F
(1970) *Klinische Monatsblätter für Augenheilkunde* 156, 821
- Sanderson K J & Sherman S M
(1971) *Journal of Neurophysiology* 34, 453
- Stone J (1966) *Journal of Comparative Neurology* 126, 585
- Wybar K C & Bloom H J G
(1963) *Transactions of the Section of Ophthalmology of the American Medical Association* p 16