

# Secondary Haemorrhagic Disease of the Newborn

JUDITH M. CHESSELLS and J. S. WIGGLESWORTH

From the Neonatal Research Unit, Institute of Child Health, and the Department of Haematology, Royal Postgraduate Medical School, University of London, Hammersmith Hospital

**Chessells, J. M., and Wigglesworth, J. S. (1970).** *Archives of Disease in Childhood*, 45, 539. **Secondary haemorrhagic disease of the newborn.** Clinical, laboratory, and necropsy findings are presented in 5 newborn infants who died with a haemorrhagic diathesis developing within 24 hours after birth. 4 babies were born prematurely; 3 suffered birth asphyxia; and 3 became hypothermic. Laboratory studies showed fibrin degradation products, low platelet counts, and deficient coagulation factors. At necropsy extensive subarachnoid haemorrhages of a characteristic type were seen in all cases, and intravascular fibrin deposits in all but one.

Haemorrhage in these babies is considered to be due to consumption of platelets and coagulation factors as a consequence of disseminated intravascular coagulation.

Predisposing conditions and possible pathogenic mechanisms are discussed.

Platelet counts aid early diagnosis of this form of haemorrhagic disease. Treatment by exchange transfusion using fresh heparinized blood is suggested.

A generalized bleeding diathesis is not uncommonly seen in sick and premature infants, and has been classified by Aballi and de Lamerens (1962) as 'Secondary haemorrhagic disease of the newborn'. It must be distinguished from classical haemorrhagic disease of the newborn due to a deficiency of vitamin K-dependent coagulation factors (II, VII, IX, X), which is virtually confined to healthy breast-fed babies who have not been given prophylactic vitamin K (Sutherland, Glueck, and Gleser, 1967).

The purpose of this communication is to record the findings in 5 such 'secondary cases' of haemorrhagic disease and to discuss possible aetiological factors.

## Material and Methods

The patients studied were admitted over a period of 8 months. Blood for coagulation studies was taken from a peripheral vein or recently inserted umbilical venous catheter into 1/10th volume of 3.2% trisodium citrate. In order to inhibit fibrinolysis *in vitro*, 1/10th volume of 10% epsilon amino caproic acid was added to samples intended for estimation of plasma fibrinogen and fibrin degradation products.

Platelet counts and coagulation tests were performed by the methods described by Dacie and Lewis (1968). Vitamin K-dependent coagulation factors (II, VII, IX,

X) were assessed by the thrombotest. The thromboplastin generation screening test was used as a test of the intrinsic coagulation system; it is sensitive to deficiency of factors V and VIII as well as IX and X. Estimation of fibrin degradation products (FDP) was performed on thrombin-treated plasma using Merskey's recent modification of the tanned red cell haemagglutination inhibition technique with antifibrinogen serum prepared in this laboratory (Merskey, Lalezari, and Johnson, 1969). Using this method, we find FDP in low titre in only a small percentage of infants who have no other evidence of disturbed haemostasis. Post-mortem sections from organs were stained with Lieb's phosphotungstic acid haematoxylin, and by the periodic acid Schiff technique to detect fibrin and hyaline thrombi.

## Case Reports

Major clinical findings in these cases are detailed in Table I and results of laboratory investigations in Table II.

**Case 1.** A twin pregnancy was complicated by a urinary infection and premature labour at 28 weeks. Twin 1 weighed 1080 g. and was not asphyxiated at birth, but subsequently developed respiratory distress. Apnoeic attacks started at 2 hours of age. On admission to this unit at 5 hours his temperature was 33 °C. He was given artificial ventilation but developed generalized bleeding and died at 34½ hours. A venous sample of blood taken at 17 hours showed a platelet count of 132,000/cu. mm. FDP were present in serum diluted to a titre of 1 in 16.

TABLE I  
Clinical Features; Five Babies With Haemorrhagic Disease

Case No. and Sex	Antenatal	Birthweight (g.)	Gestation (wk.)	Birth Asphyxia	Respiratory Distress	Minimum Temperature (°C.)
1 (M)	Twin pregnancy	1080	28	No	Yes	33
2 (F)	Placenta praevia	1600	31	Yes	Yes	31
3 (F)	Rhesus antibodies	2840	39	Yes	No	35
4 (F)	Rhesus antibodies	1070	28	Yes	Yes	32·8
5 (M)	—	1110	32	No	Yes	35

*Necropsy.* The brain showed haemorrhage within the cerebellar cortex extending into the subarachnoid space. Histological study revealed disseminated fibrin thrombi within the sinusoids of the liver.

**Case 2.** The pregnancy was complicated by placenta praevia necessitating emergency caesarean section at 32 weeks. The baby was asphyxiated at birth and weighed 1600 g. Respiratory distress was present from the age of a half-hour. Apnoeic attacks developed at 8 hours of age after aspiration of a pneumothorax. The baby was transferred to this unit at 18 hours, and was found to be hypothermic with a temperature of 31 °C. She developed generalized bleeding, and died despite an exchange transfusion with fresh heparinized blood. Blood taken at 23 hours, before exchange transfusion, showed a platelet count of 72,000/cu. mm., reduced coagulation factors (Table II), and FDP in undiluted serum.

*Necropsy.* Multiple haemorrhages into connective tissue and muscle were seen at all sites of minor trauma. Within the brain there was a haematoma replacing the right cerebellar hemisphere, with subarachnoid spread to the Sylvian fissure and over the surface of the temporal lobe. Additional small haemorrhages had occurred into the cerebellar vermis. On microscopy a few small thrombi were seen in pulmonary arterioles and there were disseminated fibrin thrombi in the sinusoids of the liver (Fig. 1).

**Case 3.** The mother was rhesus negative with an antibody titre of 1 in 32. Labour was induced at another hospital at 39 weeks, and the infant, birthweight 2840 g., was asphyxiated and oedematous with a cord Hb of 5·0 g. Apnoeic attacks developed and cardiac arrest occurred at 1½ hours. An exchange transfusion was done from 2½ hours with ACD blood, and generalized bleeding was reported from 4 hours. Spontaneous respirations were not re-established, and the baby was transferred to this unit at 13½ hours, but died before a further exchange was effected. Blood taken at 14 hours showed a platelet count of 32,000/cu. mm., FDP at a serum dilution of 1 in 2, and low factor V concentration.

*Necropsy.* This showed jaundice and skin petechiae. There was a large haematoma destroying most of the frontal lobe of the right cerebral hemisphere, with extensions to the subarachnoid space and slight extension to the ventricles. Petechiae were seen in the cerebellum and an additional haematoma was present in the fourth ventricle. Microscopical examination showed hyaline membrane formation associated with moderate alveolar haemorrhage in the lungs, and disseminated fibrin deposits within the adrenal sinusoids.

**Case 4.** The mother had 2 intrauterine intraperitoneal transfusions during pregnancy because of severe Rhesus iso-immunization. Premature labour occurred at 28 weeks. The baby weighed 1070 g. and was asphyxiated and oedematous at birth, with a cord Hb of

TABLE II  
Laboratory Findings

Case No.	Age Sample Taken (hr.)	Platelets (10 <sup>3</sup> /cu.mm.)	Fibrinogen (mg./100 ml.)	FDP Titre	Thrombin Ratio	Thrombo-test (%)	Thromboplastin Generation Screening Test (sec.)	Factor V (%)	Factor VIII (%)
1	17	131	—	16	—	—	—	—	—
2	23	72	163	1	>6	<5	60	5	9
3	14	32	148	2	>6	12	16	28	128
4	2	—	—	16	—	—	—	—	—
5	7	70	112	2	2·6	9	27	—	—
Normal newborn	Day 1	150-400	130-260	Neg.	1-2	6-56	9-20	—	—

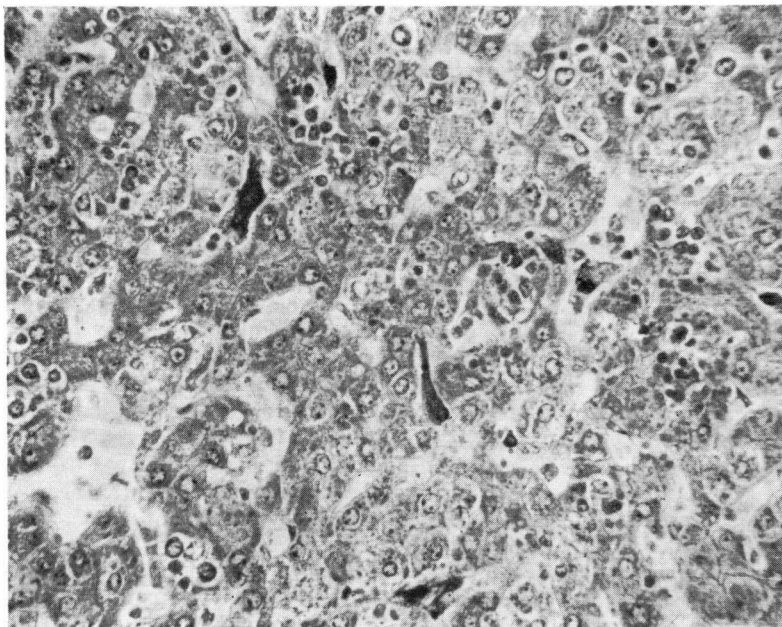


FIG. 1.—Case 2. Liver section (PTAH  $\times 840$ ) showing fibrin thrombi within hepatic sinusoids.

9.6 g. (94% cells contained Hb A on Kleihauer stain). Spontaneous respirations were not maintained and the baby bled from umbilicus and respiratory tract. Exchange transfusion, started from 2 hours, produced no improvement in the condition of the infant, and he died at 10½ hours. The sample of blood taken before exchange did not clot. FDP were present in serum diluted 1 in 16.

*Necropsy.* There was extensive bruising round injection sites and blood sampling sites of thigh and arms. Within the cranium a large haematoma had destroyed the right cerebellar hemisphere and spread to the subarachnoid space, and there was a small additional haemorrhage in the subependymal germinal layer of the cerebrum. At microscopical levels the lungs showed alveolar haemorrhage with inhaled epithelial squames and amniotic debris. No fibrin deposits were seen in the internal organs.

**Case 5.** The infant was born by quick spontaneous vertex delivery at 32 weeks gestation; birthweight 1110 g., after a normal pregnancy. There was no birth asphyxia, but respiratory distress rapidly ensued, and at 4½ hours apnoeic attacks started with bleeding from the skin and umbilicus. He was transfused with fresh blood but died at 11 hours of age.

*Necropsy.* This revealed haemorrhages over heart, lungs, and thymus. There was haemorrhage into the subarachnoid space over the right cerebral hemisphere and an unrelated small right germinal layer haemorrhage with minor spread to the ventricle. Histological studies showed hyaline membrane formation in the

lungs and disseminated fibrin deposits in hepatic and adrenal sinusoids.

### Results

The results of laboratory investigations are shown in Table II, together with the range of findings in normal newborn infants. Studies are incomplete in some cases.

FDP were detectable in the sera of all 5 babies; 4 babies had a reduced platelet count, and in the 3 infants on whom more extensive tests were performed there were deficiencies in the intrinsic and extrinsic coagulation systems with prolongation of the thrombin time.

The thrombin ratio is a comparison of the time taken by the patient's plasma to clot with the addition of thrombin compared to a normal adult plasma. This ratio is prolonged in the normal neonate but not to the extent noted in these patients. We do not have a series of factor V and factor VIII assays on normal infants but most authors find a normal or low normal value in infancy (Fresh, Ferguson, and Lewis, 1956; Preston, 1964). The vitamin K-dependent factors assessed by the thrombotest were low in all the infants studied.

Histological examination of tissues obtained at necropsy showed disseminated fibrin in some organs in 4 of the 5 babies (Table III).

This finding, together with the laboratory results,

TABLE III  
Findings at Necropsy

Case No.	Intracranial Haemorrhage	Fibrin*			
		Liver	Lungs	Adrenals	Kidneys
1	+	+	-	-	-
2	+	+	+	-	-
3	+	-	-	+	-
4	+	-	-	-	-
5	+	+	-	+	-

\* + = fibrin present; - = fibrin absent.

suggests that haemostatic failure in this group of infants was due to consumption of platelets and clotting factors as a consequence of disseminated intravascular coagulation (DIC).

### Discussion

These 5 babies all showed clinical evidence of a bleeding tendency which developed within the first 24 hours of life. The clinical picture of early haemorrhage in sick or premature newborn infants is in complete contrast to that seen in classical haemorrhagic disease of the newborn. The presence of FDP, low platelet count, and deficiency of labile coagulation factors distinguishes the two types of bleeding from the laboratory standpoint.

Necropsy revealed an unusual type of cerebral haemorrhage, and in all but one case microscopical evidence of intravascular fibrin deposition.

The concept of haemostatic failure as a result of consumption of platelets and clotting factors has achieved widespread acceptance and is being increasingly described in the newborn (Abildgaard, 1969; Hathaway, Mull, and Pechet, 1969). The final stage of the reaction is the conversion of fibrinogen to fibrin which may be seen histologically in the blood vessels. Fibrin may be cleared by the reticulo-endothelial system or by activation of the fibrinolytic system. In the latter case fibrin degradation products are formed, which are in themselves anticoagulant, since they interfere with the conversion of fibrinogen to fibrin (thus prolonging the thrombin time). FDP also interfere with fibrin polymerization and platelet function (Sherry, 1968).

In view of the pathways available for fibrin dispersal, it is hardly surprising to find on occasion a discrepancy between the severity of the haemostatic defect in life and the extent and distribution of the fibrin deposits at necropsy (e.g. Case 4). One might, in theory, expect to find an inverse relation between the level of circulating FDP and the extent of fibrin deposition.

Three aspects of these cases deserve further discussion: the identity of the factors that may have precipitated intravascular coagulation, the nature of the intracranial haemorrhage, and possible methods of diagnosis and treatment of this condition. Factors that may have contributed to the initiation of intravascular coagulation include hypothermia, asphyxia and acidosis, and severe haemolytic disease of the newborn (see Table I).

**Hypothermia.** Johansson and Nilsson (1964) have shown that consumption of platelets and coagulation factors may occur in hypothermic animals and be prevented by heparin. They have suggested that stagnation of red cells as a result of venous congestion may be a possible initiating factor. The low body temperatures recorded, 33 °C. or less, in 3 of the babies indicate that the newborn infant may react in a similar way to the experimental animal.

**Asphyxia, shock, and acidosis.** These inter-related factors may be present from birth or follow collapse or apnoeic attacks. Their role in the pathogenesis of intravascular coagulation has been discussed by Hardaway *et al.* (1964) and Hardaway (1966). The poor peripheral circulation in the shocked neonate might result both in stagnation of red cells and anoxic tissue damage.

**Severe rhesus-isoimmunization.** It has long been known that infants with erythroblastosis fetalis may exhibit thrombocytopenia and generalized bleeding, and may be found to have intracranial haemorrhage at necropsy (Javert, 1942; Leonard, 1945). Rice in 1953 described such an infant who had reduced plasma prothrombin and fibrinogen. In Case 3 the use of stored blood for exchange transfusion must have contributed to the thrombocytopenia, but does not explain the presence of fibrin deposits at necropsy. Disseminated intravascular coagulation (DIC) may perhaps occur in severe rhesus iso-immunization, though the mechanism involved is obscure. The haemolysis in this disease is extravascular, but it is possible that thromboplastic material could be released from disintegrating red cells and their precursors into the circulation and initiate activation of coagulation. The sick rhesus affected infant may also be shocked, acidotic, and hypothermic.

Some authors (Edson *et al.*, 1968; Abildgaard, 1969) have noted an association between DIC in the newborn and complications of pregnancy such as toxæmia and ante-partum haemorrhage. It has been suggested that 'placental thromboplastin' may

be released into the fetal circulation in these conditions (Boyd, 1967), but factors related to birth asphyxia, as noted above, may provide at least as plausible an explanation. Antepartum haemorrhage due to placenta praevia occurred in Case 2 of our series, but toxæmia was not seen in any case.

The massive intracerebral and subarachnoid haemorrhage seen at necropsy in these babies constitutes a distinct form of intracranial bleeding (Fig. 2). The haemorrhage is in the form of a thick

tests on all sick newborns will seldom be feasible, and the results of most tests could not be obtained soon enough to be of practical value. There is, however, a place for more frequent recourse to platelet counts in sick newborns, particularly those who have become hypothermic or suffer from severe rhesus iso-immunization. In our experience, if correct technique is employed, counts below 150,000/cu. mm. are abnormal, and if associated with any clinical evidence of a haemorrhagic tendency (e.g. oozing of blood injection sites) could be taken as an indication for exchange transfusion with fresh heparinized blood.

We thank Professor J. P. M. Tizard and Dr. W. R. Pitney for helpful advice and criticism. J.M.C. is in receipt of a Clinical Research Fellowship from the Medical Research Council.

## REFERENCES

- Aballi, A. J., and de Lamerens, S. (1962). Coagulation changes in the neonatal period and in early infancy. *Pediatric Clinics of North America*, **9**, 785.
- Abildgaard, C. F. (1969). Recognition and treatment of intravascular coagulation. *Journal of Pediatrics*, **74**, 163.
- Boyd, J. F. (1967). Disseminated fibrin thromboembolism among neonates dying within 48 hours of birth. *Archives of Disease in Childhood*, **42**, 401.
- Dacie, J. V., and Lewis, S. M. (1968). *Practical Haematology*, p. 256. Churchill, London.
- Edson, J. R., Blaese, R. M., White, J. G., and Krivit, W. (1968). Defibrination syndrome in an infant born after abruptio placentae. *Journal of Pediatrics*, **72**, 342.
- Fresh, J. W., Ferguson, J. H., and Lewis, J. H. (1956). Blood-clotting studies in parturient women and the newborn. *Obstetrics and Gynecology*, **7**, 117.
- Hardaway, R. M. (1966). *Syndromes of Disseminated Intravascular Coagulation, with Special Reference to Shock and Hemorrhage*. C. C. Thomas, Springfield, Illinois.
- , Elovitz, M. J., Brewster, W. R., Jr., and Houchin, D. N. (1964). Clotting time of heparinized blood. *Archives of Surgery*, **89**, 701.
- Hathaway, W. E., Mull, M. M., and Pechet, G. S. (1969). Disseminated intravascular coagulation in the newborn. *Pediatrics*, **43**, 233.
- Javert, C. T. (1942). Erythroblastosis neonatorum. *Surgery, Gynaecology and Obstetrics*, **74**, 1.
- Johansson, B. W., and Nilsson, I. M. (1964). The effect of heparin and  $\epsilon$ -amino caproic acid on the coagulation in hypothermic dogs. *Acta Physiologica Scandinavica*, **60**, 267.
- Leonard, M. F. (1945). Hemolytic disease of the newborn. *Journal of Pediatrics*, **27**, 249.
- Merskey, C., Lalezari, P., and Johnson, A. J. (1969). A rapid, simple, sensitive method for measuring fibrinolytic split products in human serum. *Proceedings of the Society for Experimental Biology and Medicine*, **131**, 871.
- Preston, A. E. (1964). The plasma concentration of factor VIII in the normal population. I. Mothers and babies at birth. *British Journal of Haematology*, **10**, 110.
- Rice, W. G. (1953). Deficient prothrombin and fibrinogen in fatal erythroblastosis fetalis. *Journal of Pediatrics*, **42**, 231.
- Sherry, S. (1968). Fibrinolysis. *Annual Review of Medicine*, **19**, 247.
- Sutherland, J. M., Glueck, H. I., and Gleser, G. (1967). Hemorrhagic disease of the newborn. *American Journal of Diseases of Children*, **113**, 524.

Correspondence to Dr. J. S. Wigglesworth, Institute of Child Health, Hammersmith Hospital, Du Cane Road, London W.12.

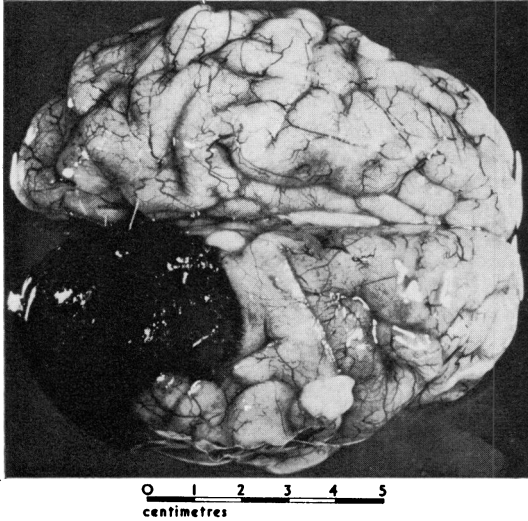


FIG. 2.—Brain of baby with severe rhesus iso-immunization and haemorrhagic symptoms, who died within 24 hours of birth. There is a large focal subarachnoid haemorrhage over the right occipital lobe. (This case has not been included in the text due to lack of laboratory studies.)

subarachnoid clot associated with a varying amount of destruction and infiltration of the underlying cerebral tissue. There is not necessarily any spread to the base of the brain or the cisterna magna, and the clot is not merely an extension of an intraventricular or germinal layer haemorrhage, though these may coexist. Further study of these lesions is being undertaken.

Logical treatment of this condition demands exchange transfusion using fresh heparinized blood as a source of platelets and labile coagulation factors. To be of value, it is clear that treatment must be instituted before the occurrence of massive intracranial or pulmonary haemorrhage, and thus often before there is unequivocal evidence of a haemorrhagic diathesis. Diagnosis at a stage when treatment can be effective is a major problem. Routine performance of a battery of coagulation