

Technetium-99m pertechnetate imaging in diagnosis of Meckel's diverticulum

JOHN C. LEONIDAS and DONALD R. GERMANN

From the Departments of Radiology, Children's Mercy and St. Luke's Hospitals; and the University of Missouri School of Medicine, Kansas City, Missouri, U.S.A.

Leonidas, J. C., and Germann, D. R. (1974). *Archives of Disease in Childhood*, **49**, 21. **Technetium-99m pertechnetate imaging in diagnosis of Meckel's diverticulum.** Abdominal imaging after intravenous injection of ^{99m}Tc pertechnetate is a simple, safe, and noninvasive diagnostic procedure to show ectopic gastric mucosa, which is present in most cases of symptomatic Meckel's diverticulum. It was performed in 13 infants and children suspected of having a Meckel's diverticulum, mainly because of unexplained rectal bleeding. Two of the three proven Meckel's diverticula were correctly identified by scintiscanning, while meticulous contrast x -ray studies were negative in each case. It is concluded that abdominal imaging is useful in the pre-operative diagnosis of symptomatic Meckel's diverticulum.

Meckel's diverticulum is often asymptomatic; yet it may cause alarming symptoms in the presence of complications, such as haemorrhage, intussusception, or perforation (Gross, 1953). Bleeding from a Meckel's diverticulum is quite common in infants; it is the result of peptic ulceration at the junction between ectopic gastric and normal ileal mucosa (Gross, 1953; Longino and Holder, 1959). Pre-operative diagnosis is extremely difficult, and conventional x -ray studies are rarely successful in showing a Meckel's diverticulum (Sloan *et al.*, 1954; Fortier-Beaulieu *et al.*, 1969; Caffey, 1972). As a result, surgical exploration has been recommended in unexplained significant rectal bleeding in infants and children.

In the past 3 years a number of reports have indicated that ectopic gastric mucosa in a Meckel's diverticulum may be identified by radioisotope scanning or imaging (Jewett, Duszynski, and Allen, 1970; Rosenthal *et al.*, 1972; Jaros, Schussheim, and Levy, 1973). The radionuclide technetium 99m (^{99m}Tc), resembling iodine in its biological properties, readily concentrates in gastric mucosa and appears in the gastric juice (Harden, Alexander, and Kennedy, 1967; Irvine *et al.*, 1967). After intravenous injection of ^{99m}Tc pertechnetate, a Meckel's diverticulum containing ectopic gastric mucosa appears as an abnormal localization of the radiopharmaceutical. Since most symptomatic

diverticula contain gastric mucosa, radionuclide imaging offers a quick, safe, and convenient method for the pre-operative investigation of patients suspected of having a Meckel's diverticulum at a low radiation exposure.

Since January 1972, radionuclide abdominal imaging has been performed in all infants and children presenting with symptoms consistent with a Meckel's diverticulum, and the results of this study are presented.

Material and methods

Between January 1972 and June 1973, 13 patients had radionuclide imaging studies in search of ectopic gastric mucosa, presumably in a Meckel's diverticulum. The records of clinical features, conventional contrast x -ray studies, and abdominal scans were studied. 4 of these patients had exploratory laparotomies and the surgical findings, as well as gross and histological features, were recorded.

Patients were injected intravenously with 100 $\mu\text{Ci/kg}$ body weight of ^{99m}Tc pertechnetate. Images of the abdomen were made at 15, 30, and 45 minutes after injection.* Early attempts at more delayed imaging were abandoned due to radioactivity moving from the stomach into the distal ileum.

Total body radiation dose is calculated to be 0.1 rads/mCi injected. This is in the same general range as a single abdominal x -ray exposure.

*All images were obtained with Nuclear of Chicago gamma camera, H-P system.

TABL
Data in 13 cases of suspect

Case no.	Sex	Age	Rectal bleeding*	Abdominal pain	Hb (g/100 ml)†
1	M	1 mth	+		16·4
2	F	7 yr	+	+	14·2
3	F	11 yr	++	—	11·8
4	M	1 dy	‡		13·4
5	M	7 mth	++		10·4
6	F	9 yr	+	+	13·2
7	M	13 yr	+	—	14·2
8	M	9 mth	++		7·8
9	F	6 mth	—		3·9
10	F	3 yr	++	—	12·2
11	F	18 mth	+++	—	10·8
12	F	11 mth	++		6·3
13	M	16 yr	—	+	12·6

*Number of (+) indicates number of admissions for rectal bleeding.

†Hb in most recent admission.

‡Fetal Hb by Apt test.

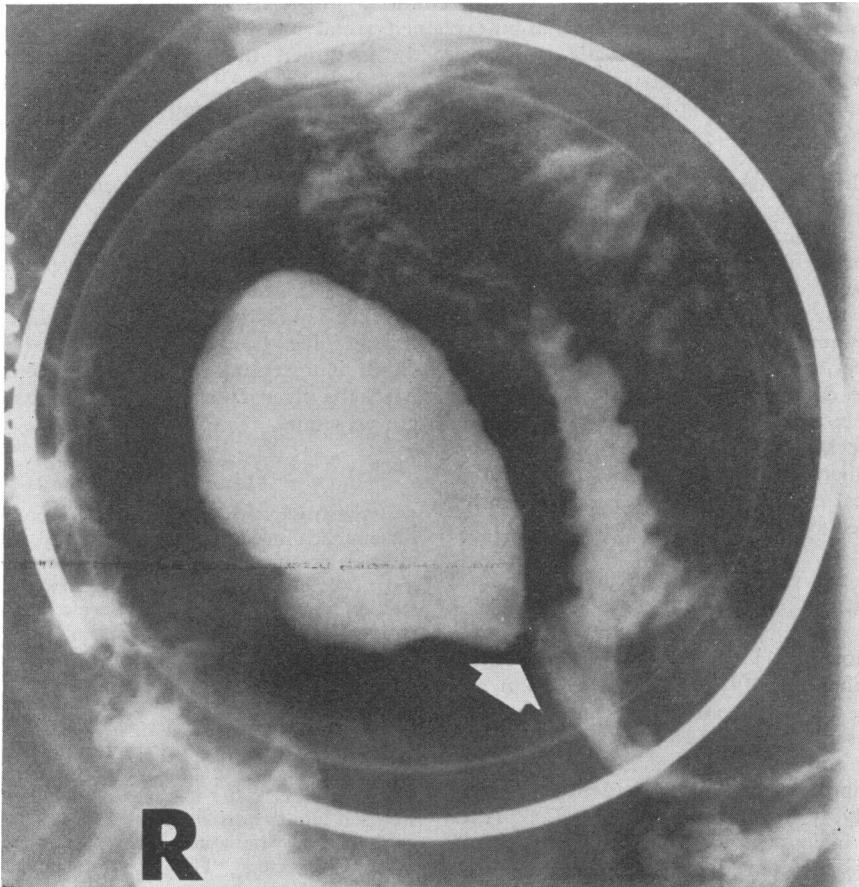


FIG. 1.—Case 13. 16-year-old boy with severe abdominal pain. Barium was induced to reflux into ileum during barium enema examination. A large pouch was opacified connected to the small bowel by a narrow outlet, bearing features of a Meckel's diverticulum or an intestinal duplication.

Meckel's diverticulum

X-ray studies	^{99m} Tc abdominal imaging	Exploratory laparotomy	Histological examination
Negative	Negative	Not done	—
Negative	Negative	Not done	—
Negative	Negative	Not done	—
Negative	Negative	Not done	—
Negative	Negative	No Meckel's or other cause for bleeding found	—
Negative	Negative	Not done	—
Negative	Negative	Not done	—
Negative	Negative	Meckel's diverticulum	Ectopic gastric mucosa
Negative	Negative	Not done	—
Lymphoid polyposis of colon	Rapid colonic uptake of ^{99m} Tc	Not done	—
Negative	Positive	Meckel's diverticulum	Ectopic gastric mucosa
Negative	Positive	Meckel's diverticulum	Ectopic gastric mucosa
Meckel's diverticulum	Positive	Not done	—

There were no patients with documented Meckel's diverticulum during the period of this study who did not have radionuclide studies.

Results

The findings in this group of 13 patients are presented in the Table. There were 6 males and 7 females, ranging in age from 1 day to 16 years. Since they were selected because they had abdominal scans with ^{99m}Tc pertechnetate, their symptoms were predictably those expected in Meckel's

diverticulum. 11 patients had significant rectal bleeding, usually recurrent (see Table). The blood was bright or dark red in 10 patients and black (melaena) in one infant (Case 4). It was often described as 'soaking the diapers or clothing.' 2 patients had no history of rectal bleeding. Case 13 had abdominal pain only, whereas one infant (Case 9) had unexplained iron deficiency anaemia. Abdominal pain was difficult to assess in small infants; pain was definitely present in 3 patients only.

Sigmoidoscopy was normal in every instance. Barium enema examination showed a large pouch arising from the ileum of Case 13 (Fig. 1). It had a narrow neck connecting it to the bowel, and in all respects it resembled a Meckel's diverticulum, though a duplication could not be excluded altogether. In Case 10, a 3-year-old girl with repeated episodes of passing bright red blood from the rectum, barium enema showed the typical features of lymphoid hyperplasia (Capitanio and Kirkpatrick, 1970). In all other cases both barium enema and barium meal studies were within normal limits.

Radionuclide imaging with ^{99m}Tc pertechnetate was positive in 3 cases (Fig. 2, 3, and 4). In two of these cases subsequent laparotomy confirmed the presence of a Meckel's diverticulum with ectopic gastric mucosa. In both cases conventional x-ray studies had been repeatedly negative during multiple hospital admissions. Case 13, a 16-year-old boy with abdominal pain and an ileal pouch on contrast x-ray study, also had a positive ^{99m}Tc scan. It was therefore concluded that the diverticulum contained ectopic gastric mucosa. The patient has refused surgery.

One patient with negative contrast x-ray studies

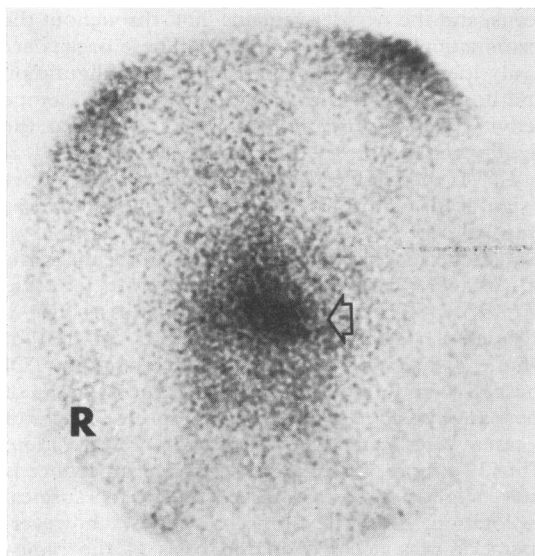


FIG. 2.—Case 13. 45-minute exposure during abdominal imaging after injection of 5 mCi ^{99m}Tc pertechnetate. Arrow indicates the area of high uptake in the midabdomen, representing ectopic gastric mucosa.

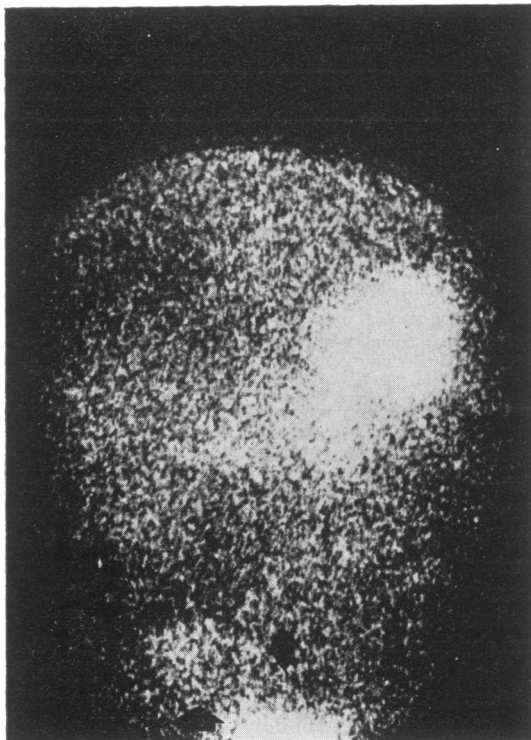


FIG. 3.—Case 11. Abdominal imaging (45-minute exposure) shows abnormally high concentration of ^{99m}Tc in the right lower quadrant. A Meckel's diverticulum was found at operation. Note also high uptake by the stomach (upper left abdomen) and bladder (lower abdomen). Increased uptake appears white in this Fig.

and a negative scan (Case 8) was found to have a Meckel's diverticulum with ectopic gastric mucosa. Another patient had an exploratory laparotomy despite negative x -ray studies and a normal abdominal scan (Case 5); no lesion responsible for bleeding was found.

Thus of three documented Meckel's diverticula containing gastric mucosa, two were correctly identified by ^{99m}Tc pertechnetate abdominal imaging. None of these had any radiographical abnormality on multiple conventional barium studies. 4 patients had exploratory laparotomies. In 2 with positive pre-operative scans, a Meckel's diverticulum was found to be the cause of rectal bleeding. Of the 2 cases who had laparotomies despite negative scans, a Meckel's diverticulum was found in 1 and no cause for the bleeding was found in the other. As expected, x -ray studies were not helpful in any of the three cases of documented Meckel's diverticulum.

There is one case in this group (Case 13) who had a diverticulum arising from the ileum on barium study; gastric mucosa in an ectopic location was shown by ^{99m}Tc scanning. It certainly represented either a Meckel's diverticulum or a duplication with ectopic gastric mucosa, but surgical and histological confirmation was lacking.

Discussion

Pre-operative diagnosis of Meckel's diverticulum is notoriously difficult, and in the majority of patients who present with symptoms consistent with this entity, surgical exploration is ultimately performed. In most cases, however, no definite cause for the clinical manifestations is found, and surgery proves unnecessary (Jaros *et al.*, 1973).

Abdominal rectilinear scanning, or imaging with the γ -ray scintillation camera, after intravenous injection of ^{99m}Tc pertechnetate has been shown thus far to be valuable in the identification of ectopic gastric mucosa. Though most Meckel's diverticula do not contain gastric mucosa, it is the latter that is implicated in the majority of *symptomatic* cases (Rutherford and Akers, 1966). Consequently the diagnostic value of radionuclide studies increases considerably.

Early scans show a high uptake of the radiopharmaceutical by the stomach, and relatively large amounts are seen in the proximal duodenum. The liver and kidneys may also be identified in initial scans, and the bladder remains 'hot' throughout the examination (Duszynski, 1972). These organs are easily identified by their position and configuration and do not interfere with the focus of high isotope activity seen in the midabdomen, usually to the right, when ectopic gastric mucosa is present (Fig. 2, 3, 4). If the bladder is full and its activity occupies a significant part of the lower abdomen, it should be emptied.

Radiopertechnetate has been used in the diagnosis of Meckel's diverticulum only since 1970 (Jewett *et al.*, 1970). The largest published series is that of Rosenthal *et al.* (1972) who studied 45 children, of whom 10 had proven Meckel's diverticulum. Of these, 8 were found to have gastric mucosa and 4 of them gave positive scans. In the present series 2 of 3 cases were correctly diagnosed before operation. Thus, a simple, safe, and noninvasive procedure is only slightly inferior in accuracy to surgical exploration. In the present series, however, operation was decided on the basis of the radioisotope scan findings, and it might have been less successful without its benefit. Surgical exploration has been unrewarding in the past in the investigation of rectal bleeding in infants and children.

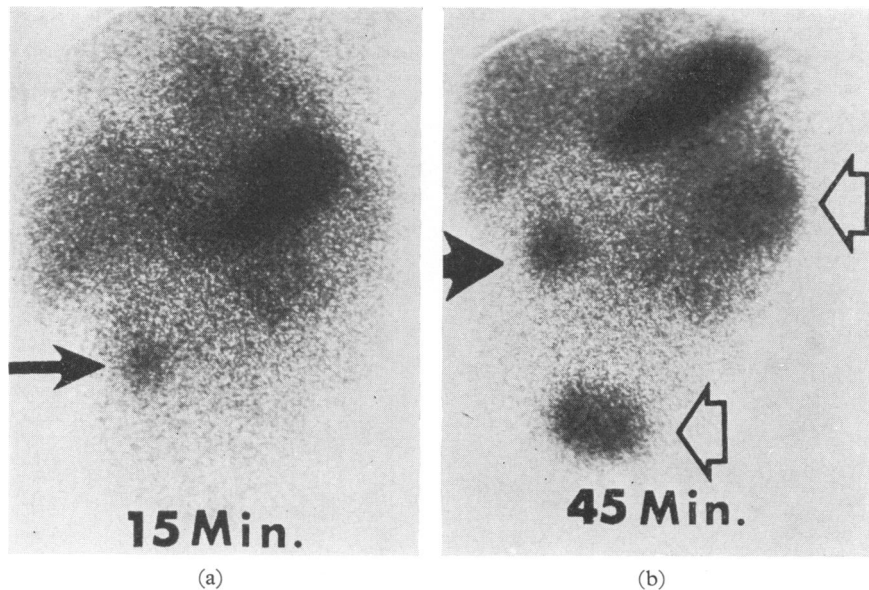


FIG. 4.—Case 12. (a) 15-minute exposure during abdominal imaging shows abnormal localization of ^{99m}Tc in area of ectopic gastric mucosa (black arrow). Note also high uptake by the stomach and liver. (b) 45-minute exposure shows further concentration of ^{99m}Tc by the ectopic gastric mucosa (black arrow). White arrows point to radiopharmaceutical in the jejunum (upper arrow) and bladder (lower arrow). A Meckel's diverticulum was resected at operation.

One false negative scan in this series remains unexplained. Rosenthal *et al.* (1972) list several factors to account for false negative results in the presence of gastric mucosa. They include superimposed inflammation, haemorrhage, obstruction of the sac outlet with back-pressure prevention of uptake, and insufficient amount of gastric mucosa. There were no false positive cases in this series. Localized bowel irritation or inflammation, however, and intussusception may give high uptake of ^{99m}Tc (Duszynski, 1972) and radioisotope scans should be interpreted in conjunction with the clinical and radiological features.

Differential diagnosis between a Meckel's diverticulum and an intestinal duplication containing gastric mucosa is impossible, as exemplified by Case 13. Such differentiation would be, however, academic, since for all practical purposes both lesions are of similar clinical significance and should be managed the same way.

In the patients not operated upon we can only assume that no Meckel's diverticulum exists. There has been no recurrence of rectal bleeding in the majority of these children (Table) and all of them have been symptom free for at least 6 months, and most of them for over one year.

In conclusion, considering the very low yield of other diagnostic methods including fluoroscopy and

radiography in Meckel's diverticulum, ^{99m}Tc pertechnetate imaging is probably the most effective diagnostic technique today. Its accuracy, convenience, and radiation exposure compare favourably with conventional radiological investigation, and it is hoped that its use will lead to an earlier and more accurate diagnosis of Meckel's diverticulum and reduce the number of unnecessary operations.

REFERENCES

- Caffey, J. (1972). *Pediatric X-ray Diagnosis*, 6th ed., p. 637. Year Book Medical Publishers, Chicago.
- Capitanio, M. A., and Kirkpatrick, J. A. (1970). Lymphoid hyperplasia of the colon in children. *Radiology*, **94**, 323.
- Duszynski, D. O. (1972). Radionuclide imaging studies of gastrointestinal disorders. *Seminars in Nuclear Medicine*, **2**, 383.
- Fortier-Beaulieu, M., Chaumont, P., Labrune, M., and Goldust, D. M. (1969). The radiological approach to the diagnosis of Meckel's diverticulum during infancy. In *Progress in Pediatric Radiology*, Vol. 2, p. 303. Ed. by H. J. Kaufmann. Karger, Basle.
- Gross, R. E. (1953). *The Surgery of Infancy and Childhood*, p. 212. Saunders, Philadelphia and London.
- Harden, R. McG., Alexander, W. D., and Kennedy, I. (1967). Isotope uptake and scanning of stomach in man with ^{99m}Tc -pertechnetate. *Lancet*, **1**, 1305.
- Irvine, W. J., Stewart, A. G., McLoughlin, G. P., and Tohill, P. (1967). Appraisal of the application of ^{99m}Tc in the assessment of gastric function. *Lancet*, **2**, 648.
- Jaros, R., Schussheim, A., and Levy, L. M. (1973). Preoperative diagnosis of bleeding Meckel's diverticulum utilizing ^{99m}Tc pertechnetate scintigraphy. *Journal of Pediatrics*, **82**, 45.

- Jewett, T. C., Duszynski, D. O., and Allen, J. E. (1970). The visualization of Meckel's diverticulum with ^{99m}Tc -pertechnetate. *Surgery*, **68**, 567.
- Longino, L. A., and Holder, T. M. (1959). Rectal bleeding in infants and children. *Pediatric Clinics of North America*, **6**, 1153.
- Rosenthal, L., Henry, J. N., Murphy, D. A., and Freeman, L. M. (1972). Radiopertechnetate imaging of the Meckel's diverticulum. *Radiology*, **105**, 371.
- Rutherford, R. B., and Akers, D. R. (1966). Meckel's diverticulum. A review of 148 pediatric patients, with special reference to the pattern of bleeding and to mesodiverticular bands. *Surgery*, **59**, 618.
- Sloan, R. D., Stafford, E. S., Singewald, M. I., and Sinn, C. M. (1954). Meckel's diverticulum. *American Journal of Roentgenology, Radium Therapy and Nuclear Medicine*, **71**, 64.

Correspondence to Dr. J. C. Leonidas, Department of Radiology, Children's Mercy Hospital, 24th at Gillham Road, Kansas City, Missouri 64108, U.S.A.