

Intrarenal reflux and the scarred kidney

G. L. ROLLESTON, T. M. J. MALING, and C. J. HODSON*

From the Department of Radiology, Christchurch Hospital and Clinical School, New Zealand

Rolleston, G. L., Maling, T. M. J., and Hodson, C. J. (1974). *Archives of Disease in Childhood*, **49**, 531. **Intrarenal reflux and the scarred kidney.** The incidence and significance of intrarenal reflux (pyelotubular backflow) occurring during micturating cystourethrography has been studied in 386 examinations on patients with vesicoureteric reflux. This phenomenon has not been observed in patients over the age of 4 years.

Renal damage having the radiographic appearance of 'atrophic pyelonephritic scarring' has been shown in 13 out of 20 kidneys showing intrarenal reflux. In 12 out of these 13 kidneys the damage corresponded exactly to those parts of the kidney in which intrarenal reflux had been evident. We suggest that severe degrees of vesicoureteric reflux and intrarenal reflux form the basis of renal scarring peculiar to 'chronic atrophic pyelonephritis'.

In recent years a new phenomenon has been recognized radiographically in patients with vesicoureteric reflux. The contrast medium can be shown to flow into the kidney substance during micturating cystography and opacify large segments of renal tissue (Fig. 1), though occasionally only small areas scarcely larger than a single renal lobule are involved. A preliminary account of the incidence and apparent effect of this intrarenal reflux on the kidneys of infants and young children is presented.

Materials and methods

A total of 386 micturating cystourethrograms in patients known to have vesicoureteric reflux without urinary tract obstruction have been reviewed. Most, but not all, of these patients were investigated radiologically because of urinary infection. Their ages at the time of the micturating cystourethrogram ranged from 3 days to 48 years (Table I).

Before 1967 the diagnosis of urinary infection at Christchurch Hospital was made on the basis of two consecutive midstream specimens showing a bacterial count of $>100,000$ organisms/ml, but subsequently the technique of direct bladder puncture has been used (Shannon, Sepp, and Rose, 1969) and any growth of bacteria has been regarded as significant.

Technique of micturating cystourethrography. This has been outlined in detail elsewhere (Maling and Rolleston, 1974). The technique varied slightly

depending on the age of the patient, but in all cases contrast material was infused into the bladder under low pressure. To ensure maximum radiographic detail of the upper and lower urinary tracts, films were taken with an overcouch tube and a film focus distance of 40 inches.

Classification of vesicoureteric reflux. Vesicoureteric reflux was classified into three grades of severity—slight, moderate, and gross (Rolleston, Shannon, and Utley, 1970). Reflux was regarded as slight when only incomplete filling of the upper urinary tract occurred; moderate when the urinary tract filled completely with slight dilatation, but without ballooning of the calyces; and gross when there was marked dilatation of the upper urinary tract with obvious ballooning of the calyces.

Results

Reflux of contrast medium into the renal substance was shown in 16 different patients. It was bilateral in 4 patients and this has provided a total of 20 kidneys with intrarenal reflux. Table I shows the incidence of intrarenal reflux in relation to age. It was not observed in patients over the age of 4 years and was present in 6.7% of examinations below the age of 5 years.

Intrarenal reflux was seen only in conjunction with moderate or severe degrees of vesicoureteric reflux. However, the incidence of the severer grades of vesicoureteric reflux was no higher in infancy and early childhood than in older children and adults to account for intrarenal reflux only being seen below the age of 5 years. Table I also analyses

Received 26 November 1973.

*Present address: Memorial University of Newfoundland.

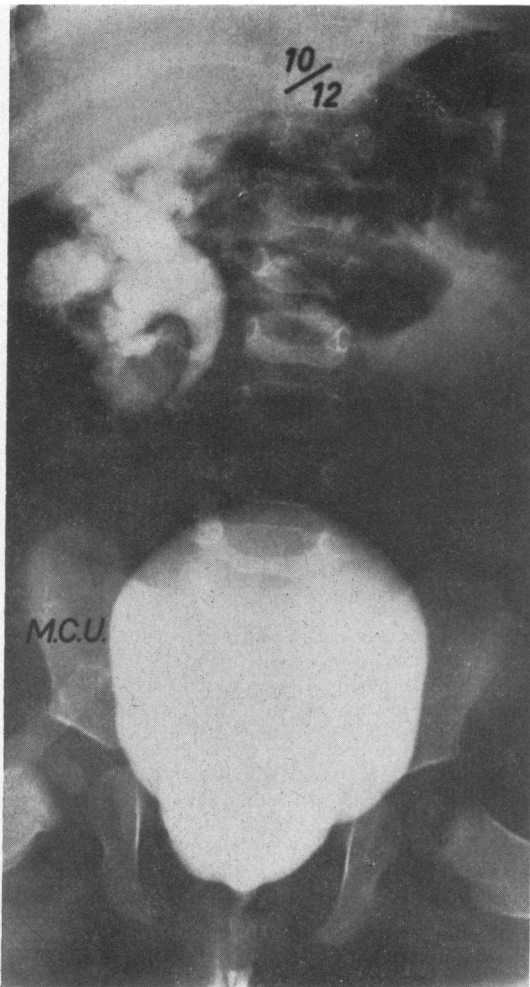


FIG. 1.—Cystogram on a 10-month-old girl showing severe right vesicoureteric reflux with extensive intrarenal reflux involving much of the right kidney.

the severity of vesicoureteric reflux found in 564 refluxing ureters during the 386 examinations.

The incidence of renal damage in the 20 kidneys showing intrarenal reflux was assessed on the basis of excretion urography. Renal damage was diagnosed if there was focal loss of kidney substance and papillary damage and/or diminished total renal size. Nine of the 20 kidneys showing intrarenal reflux were damaged at the time of the first examination, and in 8 of these 9 kidneys the damage was directly related to the anatomical area where the intrarenal reflux had been shown. Furthermore, the vesicoureteric reflux had been classified as gross in these 9 kidneys (Table II).

Follow-up examination. 18 of the 20 kidneys which initially showed intrarenal reflux were re-examined by excretion urography at intervals varying from 1 to 10 years to determine whether further damage had occurred. Of these 18 kidneys there were 7 in which damage had been shown at the initial examination. More extensive damage had occurred in 2 of these and was still confined to the same areas (Fig. 2). In the remaining 5 kidneys in which initial damage had been shown, surgical correction of reflux had been performed successfully, and these showed no increase in damage on follow-up examination (Fig. 3).

Of the other 11 kidneys, which initially were normal, 4 showed evidence of damage at the follow-up examination. In each instance, as in the first group, the damage had occurred in those areas in which intrarenal reflux had been shown at the initial examination (Fig. 4 and 5). Therefore, 13 kidneys out of a total of 20 (65%) in which intrarenal reflux was shown were damaged initially or subsequently (Table II). Furthermore, all 11 kidneys associated with gross vesicoureteric reflux became damaged but only 2 of the 9 associated with moderate reflux were similarly affected (Fig. 5 and 6).

TABLE I

Incidence of intrarenal reflux and its relation to age, and severity of vesicoureteric reflux related to age

Age of patients (yr)	Patients with vesicoureteric reflux	Patients with intrarenal reflux	Total no. of refluxing ureters	Degree of vesicoureteric reflux		
				Slight (%)	Moderate (%)	Gross (%)
0-1	144	10 (12 kidneys)	220	44 (20)	128 (58)	48 (22)
1-4	97	6 (8 kidneys)	145	23 (16)	56 (39)	66 (45)
5-12	103	0	146	53 (36)	45 (31)	48 (33)
13+	42	0	53	15 (28)	17 (32)	21 (40)
Total	386	16	564	135	246	183

TABLE II

Renal damage and intrarenal reflux and their relation to severity of vesicoureteric reflux

Severity of vesicoureteric reflux	Kidneys with intrarenal reflux	Kidneys with renal damage at initial examination	Kidneys with renal damage at follow-up
Gross	11	9	11
Moderate	9	0	2
Slight	0	0	0
Total	20	9	13

Analysis of renal damage associated with 365 refluxing ureters in children under the age of 5 years disclosed a total of 58 damaged kidneys. Intrarenal reflux was present in 13 (24%) of these kidneys and in 12 the damage corresponded exactly to the area in which intrarenal reflux had been shown.

Voiding cystourethrography. 8 micturating cystourethrograms were performed as part of the follow-up examination of the patients showing intrarenal reflux. In only 1 kidney was there evidence of persisting intrarenal reflux. It was present in the same distribution and degree as before and the interval between the examinations was 18 months (Case 9, Fig. 6). No scarring has occurred yet in this case.

Discussion

This phenomenon of intrarenal reflux has been described hitherto in a small number of publications. Brodeur, Goyer, and Melick (1965) reported 1 case, using barium sulphate as the contrast medium, in which barium was seen to enter the renal parenchyma in association with vesicoureteric reflux. They pointed to this as a hazard if barium were to be used as a contrast medium for cystography.

Hodson (1969), in discussing the mechanism of scar formation in chronic atrophic pyelonephritis, described intrarenal reflux and invoked this as a likely pathway for organisms to enter the renal parenchyma. Rolleston *et al.* (1970) reported having seen pyelotubular backflow in several cases in association with vesicoureteric reflux in children.

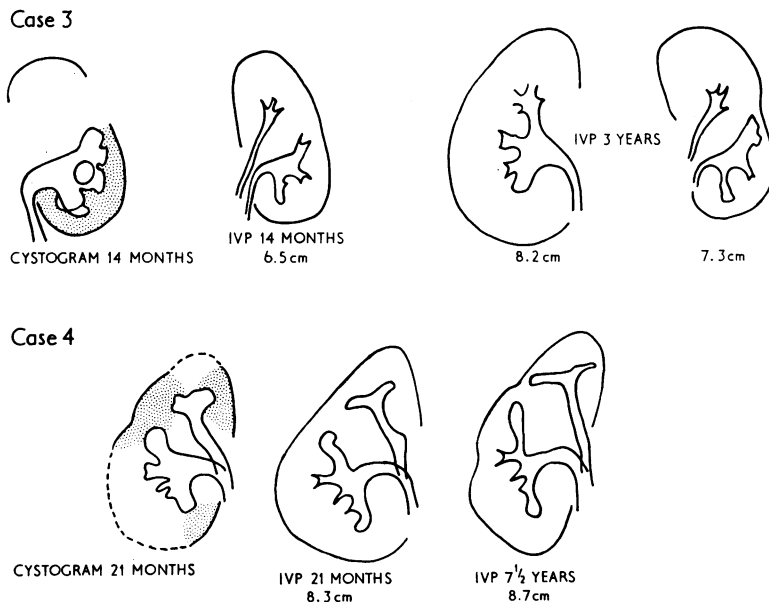
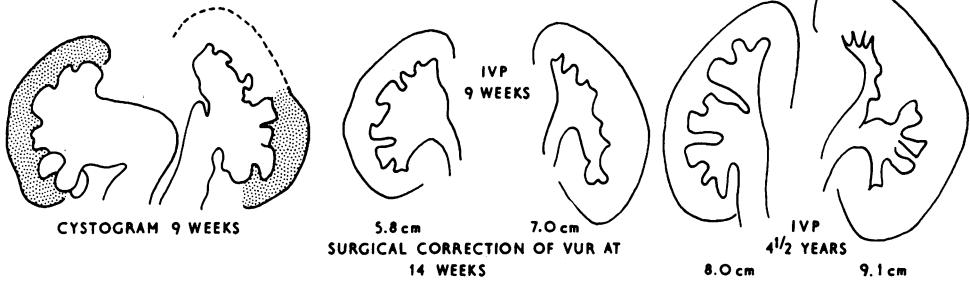
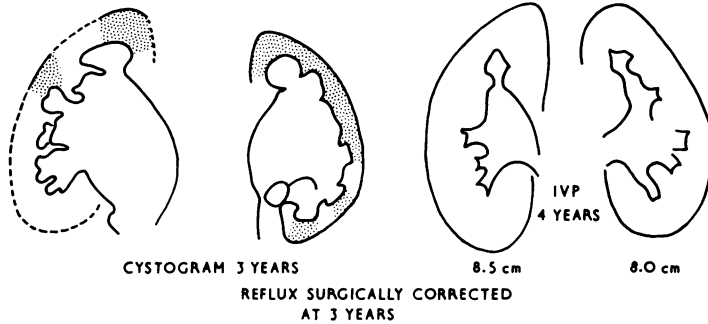


FIG. 2.—Tracings of cystograms and intravenous pyelograms from 2 patients. Both had intrarenal reflux (shaded area) associated with gross vesicoureteric reflux on cystography. At this time intravenous pyelography showed renal damage in the areas corresponding to the intrarenal reflux. At follow-up, the damage was more marked but confined to the same areas.

Case 5



Case 6



Case 7

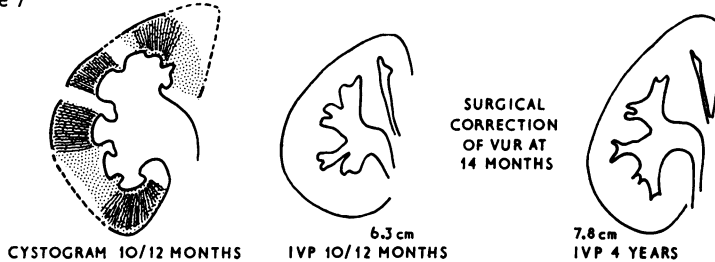


FIG. 3.—Tracings of the cystograms and intravenous pyelograms from Cases 5–7, who all showed intrarenal reflux (shaded areas) associated with gross vesicoureteric reflux at cystography. Renal damage which corresponded to the areas of intrarenal reflux was present at the initial intravenous pyelogram. After surgical correction of the vesicoureteric reflux (VUR) the damage has not progressed and the kidneys have grown.

Amar (1970) reported 8 cases occurring in both children and adults with the oldest patient being 59 years. He called it calicotubular backflow and, in speculating on the role of this phenomenon in chronic pyelonephritis, concluded that this was a route for bacteria 'to initiate, complicate, and perpetuate pyelonephritis'. Mellins (1971) refers to intrarenal reflux as the 'ultimate step' in the process of infection of the renal parenchyma.

It seems certain, both from the work of Brodeur *et al.* (1965) and experimental work on animals, that the phenomenon is a form of pyelotubular backflow (the term intrarenal reflux has been used to emphasize its association with vesicoureteric reflux).

Pyelotubular backflow is the least commonly seen of the various forms of breakout from the pelvis and calyces due to an increase in pressure. The other three, i.e. pyelovenous, pyelointerstitial, and pyelolymphatic backflow, are more common and result from a severe acute rise in pressure as occurs when a calculus is impacted in the ureter.

The accumulated clinical evidence suggested that intrarenal reflux could be associated with focal renal damage. This clinical study provides further evidence of this association.

The chief interest of the above observations obviously lies in the 0 to 4 age group where a relation between vesicoureteric reflux, intrarenal reflux,

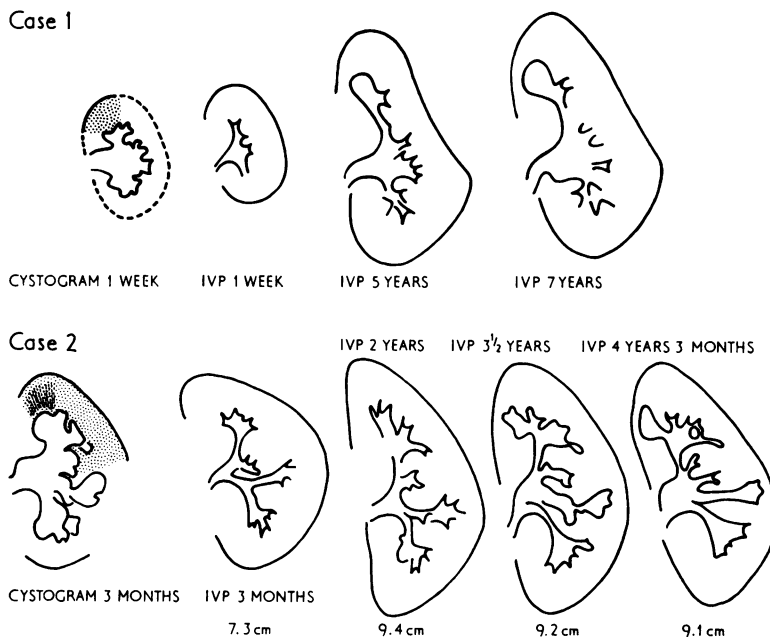


FIG. 4.—Tracings of cystograms and intravenous pyelograms from 2 patients. Both had intrarenal reflux (shaded areas) associated with gross vesicoureteric reflux on cystography, but normal kidneys on intravenous pyelography at this time. Follow-up intravenous pyelography showed the appearance of renal damage in areas corresponding to the intrarenal reflux.

infection, and focal renal damage is so suggestive. These children were investigated simply on the basis of proven bacteriuria, but those with obvious obstructive lesions have been excluded. It must be emphasized also that these data are derived from a retrospective radiological study extending back over 10 years, which was not in all cases orientated towards fine renal definition during micturating cystography. In spite of this, intrarenal reflux was shown in 6.7% of cystograms in children under the age of 5 with vesicoureteric reflux. It is almost certain that this is an underestimate of its true incidence, as we consider its radiographic demonstration very much depends on the technique used (Maling and Rolleston, 1974).

That intrarenal reflux was not shown over the age of 5 years is impressive and requires explanation. Though it has been shown occasionally in older children and even in adults, this was not the case in this series. It is unlikely that this was due to radiographic technique as the procedure was varied only slightly in the older age groups. It is well recognized that vesicoureteric reflux decreases with age both in frequency and degree (Rolleston *et al.*, 1970), but this again appears to be an insufficient explanation. Some factor appears to be present in

these very young children which predisposes to intrarenal reflux.

Of equal interest is the observation that intrarenal reflux was only seen in association with the more severe degrees of vesicoureteric reflux and that the incidence of intrarenal reflux was higher in the gross than in the moderate grades. These findings suggest that not only does its very existence depend on vesicoureteric reflux but that back pressure probably plays some part in its occurrence.

Most striking of all is the data bearing on the association between intrarenal reflux and focal renal damage. This damage is, in the main, radiologically identical to atrophic pyelonephritic scarring. Of the kidneys in which intrarenal reflux was shown, 65% showed focal renal damage by the end of the follow-up period. This amounts to 24% of the total number of damaged kidneys in children under the age of 5 years in this series. In 12 out of the 13 kidneys which finally showed focal damage, this corresponded exactly to those parts of the kidney in which intrarenal reflux had been shown. This remarkable observation is good evidence of a pathogenic relation between intrarenal reflux and focal scarring.

Underlying the vast amount of investigation that

Case 8

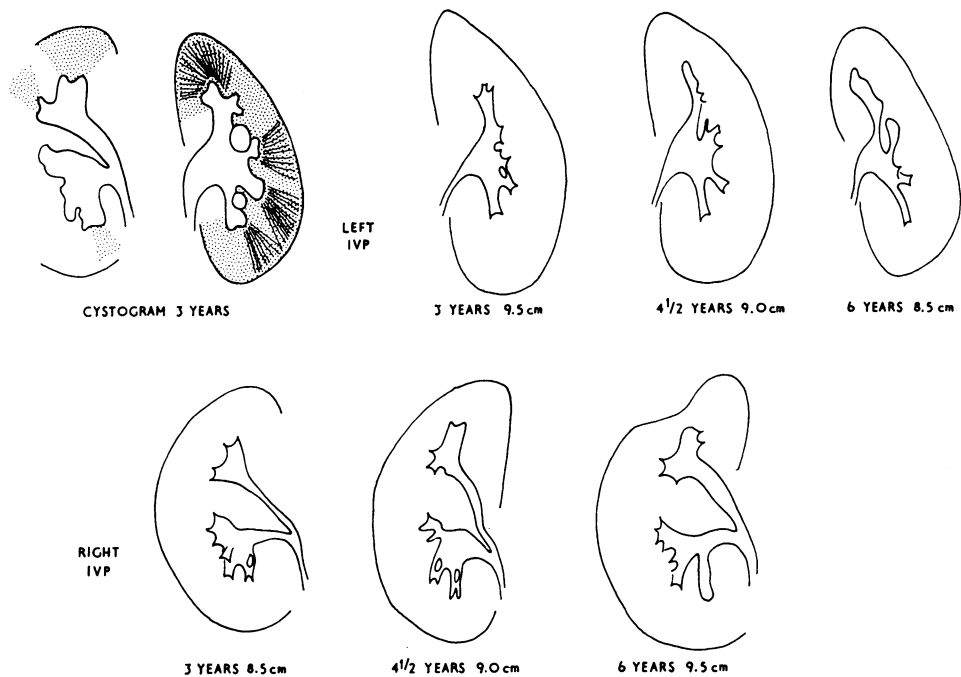


FIG. 5.—Tracings of cystogram and serial intravenous pyelograms from a child. There is intrarenal reflux (shaded area) associated with vesicoureteric reflux which was classified as moderate, but with subsequent development of renal damage in areas corresponding to the previously shown intrarenal reflux.

has been carried out in recent years on children with urinary tract infection has been the problem of defining which 'kidney is at risk' so that appropriate treatment can be undertaken to prevent scarring if

possible. In the light of these data, no physician can give a reassuring prognostication for any child in which intrarenal reflux and severe vesicoureteric reflux have been shown.

TABI
Period of follow-up an

Case no.	Sex	Age at presentation	Period of follow-up (yr)	No. of occasions urine examined	No. of infections
1	F	10 dy	9	23	1
2	F	3 mth	5	37	4
3	F	14 mth	3	4	Nil
4	F	21 mth	5	2	Nil
5	M	7 wk	5	53	10
6	M	2½ yr	5	17	1
7	F	10 mth	3	23	3
8	F	3 yr	3	22	5
9	M	7 wk	2	17	3
10	F	7 mth	10	7	Nil
11	F	3 yr	1	6	Nil
12	M	3 wk	6	14	2
13	M	2 mth	3	13	1
14	M	3 mth	2	8	Nil
15	F	3½ yr	Nil		
16	M	4 wk	Died—septicaemia		

On the other hand, the occurrence of renal damage with intrarenal reflux associated with the less severe forms of vesicoureteric reflux, appears to possess a better prognosis, providing the vesicoureteric reflux does not become more severe. In this study, the 2 kidneys in which damage was associated with moderate vesicoureteric reflux were in the same patient, a girl (Case 8 in Fig. 5). This child did not present until the age of 3 years and in her case exact categorization of the degree of vesicoureteric reflux presented difficulties. The other 7 kidneys in this group not only appeared undamaged, but maintained a normal growth rate which is valuable evidence that they were free from disease (Fig. 6).

These 7 kidneys, which despite the demonstration of intrarenal reflux have remained normal, form a very important group when contrasted with those kidneys that have become scarred. It should be pointed out that it was our practice to carry out the micturating cystourethrogram after the bacteriuria had been eliminated. Thus the demonstration of intrarenal reflux under these circumstances is not clear-cut evidence that bacteria have entered the renal parenchyma in any given case. In other words, we cannot say as yet whether intrarenal reflux shown by present cystographic techniques is valid proof that it occurs at every act of micturition in the natural state and is not a technical artefact in some. The pressures at which this examination is performed may be critical in this regard. In the experimental animal all intrarenal reflux in the presence of infection resulted in localized inflammatory lesions (work to be published later).

One further point is of interest. There are two

types of renal damage associated with severe vesicoureteric reflux; one is the focal scar of atrophic pyelonephritis and the other is generalized damage which possesses the radiographic features of obstructive atrophy (Hodson and Craven, 1966). Generalized damage is often seen in association with posterior urethral valves in the male and in the lower half of the duplex kidney in either sex, when the relative ureteric orifice is incompetent. Such damage was present in 3 cases in this series (Cases 5, 6, 7 in Fig. 3). It is to be expected with severe degrees of vesicoureteric reflux.

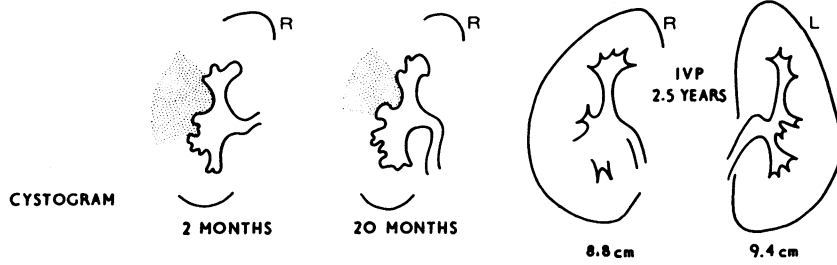
One point of apparent weakness in the general conclusion is the relatively small proportion (24%) of the total number of damaged kidneys in which intrarenal reflux was shown. Several factors may account for this figure. There may be false negatives due to imperfect radiographic technique. Intrarenal reflux, like vesicoureteric reflux, may not be shown at every examination even though recurring at times into the same portion of kidney. Urine formed within the affected segment before reflux of contrast takes place may block its passage into the kidney. The tubular flow at the time of examination must be of importance in determining whether intrarenal reflux occurs. The fibrosis associated with scarring may, somewhere along the line, prevent further intrarenal reflux.

The role that infection plays in the production of a renal scar is by no means as clear cut as that of vesicoureteric reflux. The 16 children in this series presented initially with bacteriuria, but a striking feature of the follow-up examinations was that in 5 of these patients there was no episode of illness suggestive of urinary tract infection and on no

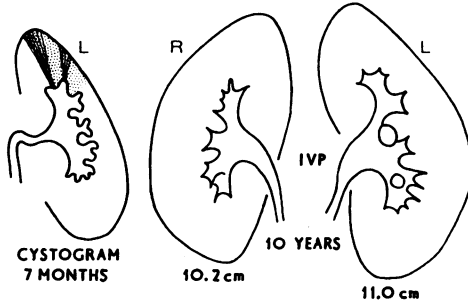
II
episodes of infection

Clinical infections	Degree of vesicoureteric reflux	Kidneys at presentation	Kidneys at follow-up
Nil	Gross	Normal	Damaged
2	Gross	Normal	Damaged
Nil	Gross	Damaged	Damage progressed
Nil	Gross	Damaged	Damage progressed
2	Gross	Damaged	Surgical correction of reflux—damage unchanged
Nil	Gross	Damaged	Surgical correction of reflux—damage unchanged
1	Gross	Damaged	Surgical correction of reflux—damage unchanged
2	Moderate	Normal	Damaged
2	Moderate	Normal	Normal
Nil	Moderate	Normal	Normal
Nil	Moderate	Normal	Normal
Nil	Moderate	Normal	Normal
1	Moderate	Normal	Normal
Nil	Moderate	Normal	Normal
	Gross	Damaged	
	Gross	Damaged	

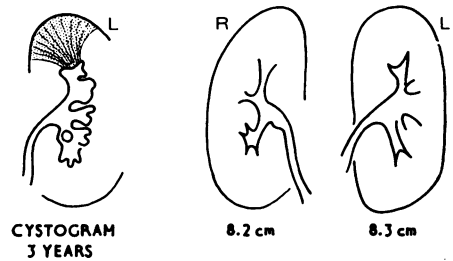
Case 9



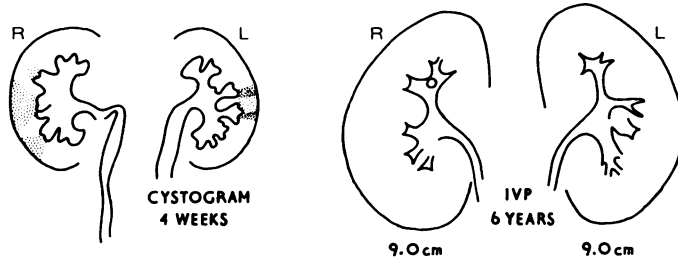
Case 10



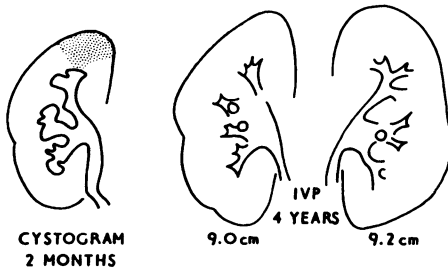
Case 11



Case 12



Case 13



Case 14

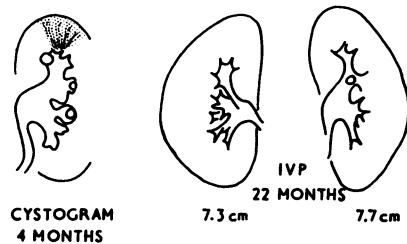


FIG. 6.—Tracings of cystograms and intravenous pyelograms from 6 patients show intrarenal reflux (shaded areas) associated with moderate vesicoureteric reflux at cystography. Follow-up intravenous pyelograms show kidneys without damage and with normal growth.

occasion on routine follow-up was bacteriuria detected (Table III). These include some patients whose kidneys remained normal and others in whom scars progressed.

In 3 of the patients who had moderate vesicoureteric reflux with intrarenal reflux the kidneys have continued to grow normally despite proven episodes of bacteriuria in the follow-up period

(Table III). Many questions concerning the relation of urinary infection and renal scarring have no answer at present and the whole subject demands close study. (An account of extensive experimental work supporting most of the ideas in this article is in preparation for publication, indicating, among other things, that intrarenal reflux is indeed pyelotubular backflow and that focal scarring can occur in the experimental animal in a sterile situation.)

We are indebted to the paediatricians, urologists, and renal physicians at Christchurch Hospital who have referred patients for investigation and have contributed to our understanding of vesicoureteric reflux by frank and free discussion.

In particular we wish to acknowledge the helpful advice, collaboration, and follow-up clinical data provided by Professor F. T. Shannon and Mr. W. L. F. Utley.

REFERENCES

- Amar, A. D. (1970). Calicotubular backflow with vesicoureteral reflux. *Journal of the American Medical Association*, **213**, 293.
- Brodeur, A. E., Goyer, R. A., and Melick, W. (1965). A potential hazard of barium cystography. *Radiology*, **85**, 1080.
- Hodson, C. J. (1969). The effects of disturbance of flow on the kidney. *Journal of Infectious Diseases*, **120**, 54.
- Hodson, C. J., and Craven, J. D. (1966). The radiology of obstructive atrophy of the kidney. *Clinical Radiology*, **17**, 305.
- Maling, T. M. J., and Rolleston, G. L. (1974). Intra-renal reflux in children demonstrated by micturating cystography. *Clinical Radiology*, **25**, 81.
- Mellins, H. Z. (1971). Chronic pyelonephritis and renal medullary necrosis. *Seminars in Roentgenology*, **6**, 292.
- Rolleston, G. L., Shannon, F. T., and Utley, W. L. F. (1970). Relationship of infantile vesico-ureteric reflux to renal damage. *British Medical Journal*, **1**, 460.
- Shannon, F. T., Sepp, E., and Rose, G. R. (1969). Diagnosis of bacteriuria by bladder puncture in infancy and childhood. *Australian Paediatric Journal*, **5**, 97.

Correspondence to Dr. T. M. J. Maling, Department of Radiology, Christchurch Hospital, Christchurch 1, New Zealand.