

Renin and hypertension in childhood

It is clearly established that hypertension is a major factor in the genesis of arterial disease in adult life (Kannel and Dawber, 1974). Severe hypertension in childhood is a relatively uncommon but important disorder, for in at least 80% of cases it is secondary to some underlying, often treatable, condition (Loggie, 1971; Kaufman *et al.*, 1972). Furthermore, it is increasingly being realized that essential hypertension may have its origins in childhood (Londe *et al.*, 1971). The renin-angiotensin system plays an important causative or perpetuating role in many forms of hypertension; for this reason a review of its status in children and its relevance to childhood hypertension is appropriate.

Renin-angiotensin system (Fig.)

Renin is a proteolytic enzyme produced by the juxtaglomerular cells of the afferent arterioles in response to a variety of stimuli. The most important of these is a decrease in renal arterial perfusion pressure, but changes in renal tubular fluid sodium concentration and sympathetic nervous

activity also play a part. The renin is released into the circulation and acts on an α_2 -globulin, renin substrate, generating the physiologically inactive decapeptide, angiotensin I. In the plasma and on passage through the lungs, angiotensin I is converted to the active pressor octapeptide, angiotensin II, which causes arteriolar vasoconstriction and hence an increase in total peripheral resistance. Angiotensin II also has a less well understood direct natriuretic action on the renal tubules, but this effect is overshadowed by its stimulatory action on the production of aldosterone by the adrenal cortex. This in turn promotes sodium reabsorption in exchange for potassium in the distal renal tubules. Renin itself cannot be measured easily, but the activity of the renin system can be gauged by the rate of production of angiotensin I from endogenous substrate during incubation of plasma in the presence of inhibitors of the converting enzyme and angiotensinases; this estimation is known as the plasma renin activity (PRA). A similar measurement is available known as plasma renin concentration, in which excess exogenous substrate is added eliminating the effect of substrate variation. In addition there are assays for determining the levels of circulating angiotensin II (Boyd, Landon, and Peart, 1967).

In children interpretation of plasma renin values has proved difficult because of the limited normal data available. Contributory factors in this dearth of paediatric information have been the large quantities of blood hitherto required for measurement of the various parameters of the renin-angiotensin system and the sampling difficulties encountered in young children. Several studies have suggested that in children peripheral venous plasma renin levels were higher than in adults (Godard *et al.*, 1968; Amsterdam *et al.*, 1969; Kotchen *et al.*, 1972). Krause, Schillmöller, and Hayduk (1972) confirmed these findings utilizing a bioassay technique for plasma renin concentration and showed a significant negative correlation between renin concentration and body surface area. More recently, Dillon and Ryness (1974), using a semi-micro radioimmunoassay have established normal ranges for peripheral plasma renin activity in infancy

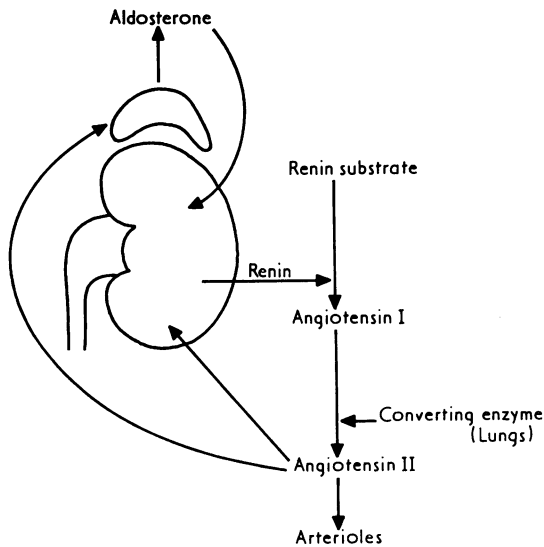


FIG.—The renin-angiotensin system.

and childhood and observed a tenfold decline in PRA with age, falling from 1392 pg angiotensin I/ml per hr in infancy to 87 pg angiotensin I/ml per hr in adult life. Plasma aldosterone concentration similarly declines from 20.2 ng/100 ml to 11.7 ng/100 ml.

Sodium deprivation enhances renin secretion, and it is established that PRA should be interpreted in relation to sodium turnover (Laragh *et al.*, 1972) or total exchangeable sodium (Davies *et al.*, 1973). It is not obvious how to compare rates of sodium turnover in infants and adults but the decline of PRA with age cannot be wholly attributable to differences in sodium intake. A possible explanation is that the young infant is more dependent than the adult upon renin-aldosterone stimulated distal tubular sodium reabsorption for the maintenance of salt balance.

Renal hypertension

The conditions in which hypertension is associated with activation of the renin-angiotensin system include renal ischaemia due to renal artery stenosis, many varieties of parenchymal renal disease especially when hypertension is resistant to saline depletion (Weidmann *et al.*, 1971; Schalekamp *et al.*, 1973), rare renin-secreting tumours (Robertson *et al.*, 1967), occasionally Wilms's tumours (Mitchell *et al.*, 1970), and malignant hypertension in some individuals. Secondary hyperaldosteronism with hypokalaemia may occur in all these situations.

Renovascular disease. Renovascular hypertension can be defined as hypertension caused by a lesion of the renal artery or its branches which impairs blood flow to all or part of the kidney (Leumann *et al.*, 1970). It is a curable disorder that has recently been recognized with increasing frequency. It is second only to coarctation of the aorta as a cause of surgically remediable hypertension in children (Fry *et al.*, 1973). Renal artery stenosis with hypertension has been reported in neonates (Ljungqvist and Wallgren, 1962; Schmidt and Rambo, 1965; Angella *et al.*, 1968; Formby and Emery, 1969). It is sometimes familial (Bergstein *et al.*, 1971; Kaufman *et al.*, 1972). Renal artery stenosis has been associated with idiopathic hypercalcaemia (Wiltse *et al.*, 1966), Marfan's syndrome (Loughridge, 1959), the rubella syndrome (Menser *et al.*, 1966), Takayashi disease (Fry *et al.*, 1973), and neurofibromatosis (Halpern and Currarino, 1965; Bourke and Gatenby, 1971; Klecker and Roth, 1974). A variety of pathological lesions have been reported, including hypoplasia,

intimal hyperplasia, arteritis, and external compression. However, the commonest finding is fibromuscular dysplasia, particularly in older children (Fry *et al.*, 1973). The disease may be bilateral, may involve segmental vessels (Kaufman *et al.*, 1972; Fry *et al.*, 1973), and occasionally the renal artery is replaced by many smaller vessels (Barratt, 1974).

Other causes of renovascular hypertension in children include renal artery aneurysm (Grossman and Babbit, 1967; Kaufman *et al.*, 1972), arteriovenous fistula (Long, Javid, and Julian, 1964), intrarenal vascular anomalies (Leumann *et al.*, 1970; Chrispin and Scatliff, 1973), and renal artery disruption after trauma (Fry *et al.*, 1973).

The ischaemic kidney secretes excess renin but not all cases of renal artery stenosis have raised peripheral plasma renin activity (Brown *et al.*, 1965) or angiotensin II concentration (Catt *et al.*, 1971). On the other hand, Vaughan *et al.* (1973) found that if peripheral plasma renin levels were related to the urinary sodium excretion they were abnormally high in adults with renal artery stenosis. Dillon and Ryness (1974) have confirmed that most children with hypertension secondary to renal vascular anomalies or renal scarring have higher PRA than healthy children of equivalent age.

In terms of preoperative prediction of surgical cure it appears that it is not the peripheral plasma renin activity but the differential renal vein renin levels which are of greatest value (Michelakis *et al.*, 1967; Stockigt *et al.*, 1972). A renal vein renin ratio of greater than 1:1.5, especially if associated with evidence of suppression of renin release from the contralateral kidney, predicts a good response in terms of surgical treatment for renovascular disease and is useful in patients with other types of renal hypertension (Stockigt *et al.*, 1972). However, renal vein renin determinations in children are even more prone to error than in adults. False negative ratios may occur for many reasons (Poutasse *et al.*, 1973; Vaughan *et al.*, 1973) and it must be remembered in this context that β -adrenergic blockers specifically depress renin release and should be withdrawn at least 3 days, but ideally 2 weeks, before this investigation is undertaken. Selective sampling from segmental veins draining underperfused areas of kidney may allow the identification of localized sources of renin secretion which may be overlooked by main renal-vein sampling (Schambelan *et al.*, 1974). Successful revascularization of an ischaemic kidney in childhood offers a good prospect of permanent cure of hypertension (Kaufman *et al.*, 1972; Fry *et al.*, 1973).

Parenchymal renal disease. The relation between parenchymal renal disease and hypertension is very complex. Hypertension is regularly associated in children, as in adults, with advanced renal disease and uraemia. However, with some important exceptions, the renin-angiotensin system cannot be implicated in this group of patients. In most of the patients the hypertension responds to salt depletion but in the remainder this fails to lower the blood pressure; these individuals have high circulating renin levels in their peripheral blood in relation to their exchangeable sodium (Schalekamp *et al.*, 1973).

Lesser degrees of parenchymal renal damage may be implicated in the causation of renin-dependent hypertension in children. Included within this group are probably segmental renal hypoplasia (Ask-Upmark, 1929; Royer *et al.*, 1971), the kidney after renal venous thrombosis (Perry and Taylor, 1940), and also children with localized pyelonephritic scarring and hypertension. In unilateral renal disease with negligible function on that side and with an apparently normal or hypertrophied contralateral kidney, nephrectomy may well be undertaken in the hope that the blood pressure will fall. In bilateral disease in which the disparity of function is less marked, then medical treatment is to be preferred (Barratt, 1974). Renal vein renin studies may well reveal clear lateralization of renin output in this type of case, but it is worth noting that with some pyelonephritic kidneys the hypertension sometimes subsides spontaneously without resort to operation (Barratt, 1974). No clear guidelines have been established in children for deciding which kidney should be removed and if in doubt, a conservative approach is preferable.

Renal tumours. It has been reported that Wilms's tumours are occasionally associated with hypertension (Koons and Ruch, 1940; Hughes, Rosenblum, and Horn, 1949) and that this has been associated with increased renin output from the offending kidney (Mitchell *et al.*, 1970). Whether this is due to impairment of vascular supply to part of the kidney or to increased secretion of renin from the tumour itself is not entirely clear, but the findings suggest the latter (Lee, 1971). More recently it has become apparent that specific renin-secreting tumours exist, known as haemangiopericytomas. There have been 7 published reports (Robertson *et al.*, 1967; Kihara *et al.*, 1968; Eddy and Sanchez, 1971; Bonnin, Hodge, and Lumbers, 1972; Conn *et al.*, 1972; Schambelan *et al.*, 1973; Brown *et al.*, 1973) and of these, 3 were in children, the youngest being a girl of 8 years.

Characteristically, those affected have hypertension, evidence of secondary hyperaldosteronism, normal renal function, normal IVP, and a normal or only slightly abnormal renal arteriogram. Divided renal vein renin levels reveal clear lateralization to the side affected and nephrectomy results in cure. So far, there is no evidence of malignancy and no metastases have been reported.

In conclusion, it is becoming increasingly apparent that disturbances of the renin-angiotensin system in childhood are of considerable importance. An understanding of the physiology and pathology is essential for the satisfactory diagnosis and treatment of many hypertensive disorders which affect children. With development of semimicro methods for measurement of plasma renin activity and more refined techniques of arteriography and reconstructive vascular surgery, there is every reason to expect improvement in the evaluation and treatment of these children.

This work was undertaken during tenure of the Alan Moncrieff Educational Research Fellowship supported by the Buttle Trust.

REFERENCES

- Amsterdam, E. A., Albers, W. H., Christlieb, A. R., Morgan, C. L., Nadas, A. S., and Hickler, R. B. (1969). Plasma renin activity in children with coarctation of the aorta. *American Journal of Cardiology*, **23**, 396.
- Angella, J. J., Sommer, L. S., Poole, C., and Fogel, B. J. (1968). Neonatal hypertension associated with renal artery hypoplasia. *Pediatrics*, **41**, 524.
- Ask-Upmark, E. (1929). Über juvenile maligne Nephrosklerose und ihr Verhältnis zu Störungen in der Nierentwicklung. *Acta Pathologica et Microbiologica Scandinavica*, **6**, 383.
- Barratt, T. M. (1974). Hypertension in childhood. In *Encyclopaedia of Urology*, Vol. XV (Suppl.), *Urology in Childhood*, p. 34. Ed. by D. Innes Williams. Springer, Berlin, Heidelberg, and New York.
- Bergstein, J. M., Fangman, J., Fish, A. J., Herdman, R., and Good, R. A. (1971). Severe hypertension in identical twin infants. *American Journal of Diseases of Children*, **122**, 348.
- Bonnin, J. M., Hodge, R. L., and Lumbers, E. R. (1972). A renin-secreting renal tumour associated with hypertension. *Australian and New Zealand Journal of Medicine*, **2**, 178.
- Bourke, E., and Gatenby, P. B. B. (1971). Renal artery dysplasia with hypertension in neurofibromatosis. *British Medical Journal*, **3**, 681.
- Brown, J. J., Davies, D. L., Lever, A. F., and Robertson, J. I. S. (1965). Plasma renin concentration in human hypertension. II. Renin in relation to aetiology. *British Medical Journal*, **2**, 1215.
- Brown, J. J., Fraser, R., Lever, A. F., Morton, J. J., Robertson, J. I. S., Tree, M., Bell, P. R. F., Davidson, J. K., and Ruthven, I. S. (1973). Hypertension and secondary hyperaldosteronism associated with a renin-secreting renal juxtaglomerular-cell tumour. *Lancet*, **2**, 1228.
- Boyd, G. W., Landon, J., and Peart, W. S. (1967). Radioimmunoassay for determining plasma-levels of angiotensin II in man. *Lancet*, **2**, 1002.
- Catt, K. J., Cran, E., Zimmet, P. Z., Best, J. B., Cain, M. D., and Coghlan, J. P. (1971). Angiotensin II blood-levels in human hypertension. *Lancet*, **1**, 459.
- Chrispin, A. R., and Scatliff, J. H. (1973). Systemic hypertension in childhood. *Paediatric Radiology*, **1**, 75.

- Conn, J. W., Cohen, E. L., Lucas, C. P., McDonald, W. J., Mayor, G. H., Blough, W. M., Eveland, W. C., Bookstein, J. J., and Lapidus, J. (1972). Primary reninism. Hypertension, hyperreninemia and secondary aldosteronism due to renin-producing juxtaglomerular cell tumors. *Archives of Internal Medicine*, **130**, 682.
- Davies, D. L., Schalekamp, M. A., Beevers, D. G., Brown, J. J., Briggs, J. D., Lever, A. F., Medina, A. M., Morton, J. J., Robertson, J. I. S., and Tree, M. (1973). Abnormal relation between exchangeable sodium and the renin-angiotensin system in malignant hypertension and in hypertension with chronic renal failure. *Lancet*, **1**, 683.
- Dillon, M. J., and Ryness, J. (1974). Plasma renin activity and aldosterone concentration in children. (Abstr.) *Archives of Disease in Childhood*, **49**, 823.
- Eddy, R. L., and Sanchez, S. A. (1971). Renin-secreting renal neoplasm and hypertension with hypokalemia. *Annals of Internal Medicine*, **75**, 725.
- Formby, D., and Emery, J. L. (1969). Intimal hyperplasia of the aorta and renal vessels in an infant with hypertension. *Journal of Pathology*, **98**, 205.
- Fry, W. J., Ernst, C. B., Stanley, J. C., and Brink, B. (1973). Renovascular hypertension in the pediatric patient. *Archives of Surgery*, **107**, 692.
- Godard, C., Riou, A. M., Veyrat, R., Mégevand, A., and Muller, A. F. (1968). Plasma renin activity and aldosterone secretion in congenital adrenal hyperplasia. *Pediatrics*, **41**, 883.
- Grossman, R. E., and Babbit, D. P. (1967). Renal artery aneurysms; their diagnosis and endocrine implications: a case report in a child. *Journal of Urology*, **97**, 172.
- Halpern, M., and Currarino, G. (1965). Vascular lesions causing hypertension in neurofibromatosis. *New England Journal of Medicine*, **273**, 248.
- Hughes, J. G., Rosenblum, H., and Horn, L. G. (1949). Hypertension in embryoma (Wilms' tumor). *Pediatrics*, **3**, 201.
- Kannel, W. B., and Dawber, T. R. (1974). Hypertension as an ingredient of a cardiovascular risk profile. *British Journal of Hospital Medicine*, **11**, 508.
- Kaufman, J. J., Goodwin, W. E., Waisman, J., and Gyepes, M. T. (1972). Renovascular hypertension in children. Report of seven cases treated surgically including two cases of renal autotransplantation. *American Journal of Surgery*, **124**, 149.
- Kihara, I., Kitamura, S., Hoshino, T., Seida, H., and Watanabe, T. (1968). A hitherto unreported vascular tumor of the kidney: a proposal of 'juxtaglomerular cell tumor.' *Acta Pathologica Japonica*, **18**, 197.
- Klecker, R. L., and Roth, J. B. (1974). Visceral neurofibromatosis and hypertension in childhood. *Pediatrics*, **53**, 417.
- Koons, K. M., and Ruch, M. K. (1940). Hypertension in a 7-year-old girl with Wilms' tumor relieved by nephrectomy. *Journal of the American Medical Association*, **115**, 1097.
- Kotchen, T. A., Strickland, A. L., Rice, T. W., and Walters, D. R. (1972). A study of the renin-angiotensin system in newborn infants. *Journal of Pediatrics*, **80**, 938.
- Krause, D. K., Schillmöller, U., and Hayduk, K. (1972). Increased plasma-renin concentration in healthy infants, young children and school-children in comparison to normal adults. *German Medicine*, **2**, 103.
- Laragh, J. H., Baer, L., Brunner, H. R., Buhler, F. R., Sealey, J. E., and Vaughan, E. D. (1972). Renin, angiotensin and aldosterone system in pathogenesis and management of hypertensive vascular disease. *American Journal of Medicine*, **52**, 633.
- Lee, M. R. (1971). Renin-secreting kidney tumours. A rare but remediable cause of serious hypertension. *Lancet*, **2**, 254.
- Leumann, E. P., Bauer, R. P., Slaton, P. E., Biglieri, E. G., and Holliday, M. A. (1970). Renovascular hypertension in children. *Pediatrics*, **46**, 362.
- Ljungqvist, A., and Wallgren, G. (1962). Unilateral renal artery stenosis and fatal arterial hypertension in a newborn infant. *Acta Paediatrica Scandinavica*, **51**, 575.
- Loggie, J. M. H. (1971). Systemic hypertension in children and adolescents. Causes and treatment. *Pediatric Clinics of North America*, **18**, 1273.
- Londe, S., Bourgoignie, J. J., Robson, A. M., and Goldring, D. (1971). Hypertension in apparently normal children. *Journal of Pediatrics*, **78**, 569.
- Long, L., Javid, H., and Julian, O. C. (1964). Arteriovenous fistula of renal vessels: report of a case believed to be congenital and review of the literature. *Annals of Surgery*, **160**, 239.
- Loughridge, L. W. (1959). Renal abnormalities in the Marfan syndrome. *Quarterly Journal of Medicine*, **28**, 531.
- Menser, M. A., Dorman, D. C., Reye, R. D. K., and Reid, R. R. (1966). Renal-artery stenosis in the rubella syndrome. *Lancet*, **1**, 790.
- Michelakis, A. M., Foster, J. H., Liddle, G. W., Rhamy, R. K., Kuchel, O., and Gordon, R. D. (1967). Measurement of renin in both renal veins. *Archives of Internal Medicine*, **120**, 444.
- Mitchell, J. D., Baxter, T. J., Blair-West, J. R., and McCredie, D. A. (1970). Renin levels in nephroblastoma (Wilms' tumour). Report of a renin-secreting tumour. *Archives of Disease in Childhood*, **45**, 376.
- Perry, C. B., and Taylor, A. L. (1940). Hypertension following thrombosis of the renal veins. *Journal of Pathology and Bacteriology*, **51**, 369.
- Poutasse, E. F., Marks, L. S., Wisoff, C. P., Vinson, A. M., and Wan, A. T. (1973). Renal vein renin determinations in hypertension; falsely negative tests. *Journal of Urology*, **110**, 371.
- Robertson, P. W., Klidjian, A., Harding, L. K., Walters, G., Lee, M. R., and Robb-Smith, A. H. T. (1967). Hypertension due to a renin-secreting renal tumour. *American Journal of Medicine*, **43**, 963.
- Royer, P., Broyer, M., Habib, R., and Nouaillie, Y. (1971). L'hypoplasie segmentaire du rein chez l'enfant. In *Actualités Néphrologiques de l'Hôpital Necker*, p. 151. Flammarion Médecine-Sciences, Paris.
- Schalekamp, M. A., Beevers, D. G., Briggs, J. D., Brown, J. J., Davies, D. L., Fraser, R., Lebel, M., Lever, A. F., Medina, A., Morton, J. J., Robertson, J. I. S., and Tree, M. (1973). Hypertension in chronic renal failure. An abnormal relation between sodium and the renin-angiotensin system. *American Journal of Medicine*, **55**, 379.
- Schambelan, M., Glickman, M., Stockigt, J. R., and Biglieri, E. G. (1974). Selective renal-vein renin sampling in hypertensive patients with segmental renal lesions. *New England Journal of Medicine*, **290**, 1153.
- Schambelan, M., Howes, E. L., Stockigt, J. R., Noakes, C. A., and Biglieri, E. G. (1973). The role of renin and aldosterone in hypertension due to a renin-secreting tumor. *American Journal of Medicine*, **55**, 86.
- Schmidt, D. M., and Rambo, O. N. (1965). Segmental intimal hyperplasia of the abdominal aorta and renal arteries producing hypertension in an infant. *American Journal of Clinical Pathology*, **44**, 546.
- Stockigt, J. R., Collins, R. D., Noakes, C. A., Schambelan, M., and Biglieri, E. G. (1972). Renal-vein renin in various forms of renal hypertension. *Lancet*, **1**, 1194.
- Vaughan, E. D., Buhler, F. R., Laragh, J. H., Sealey, J. E., Baer, L., and Bard, R. H. (1973). Renovascular hypertension: renin measurements to indicate hypersecretion and contralateral suppression, estimate renal plasma flow, and score for surgical curability. *American Journal of Medicine*, **55**, 402.
- Weidmann, P., Maxwell, M. H., Lupu, A. N., Lewin, A. J., and Massry, S. C. (1971). Plasma renin activity and blood pressure in terminal renal failure. *New England Journal of Medicine*, **285**, 757.
- Wiltse, H. E., Goldbloom, R. B., Antia, A. U., Ottesen, O. E., Rowe, R. D., and Cooke, R. E. (1966). Infantile hypercalcemia syndrome in twins. *New England Journal of Medicine*, **275**, 1157.

M. J. DILLON

The Hospital for Sick Children,
Great Ormond Street, and

Institute of Child Health, London WC1N 1EH.