

Combined Retrolabyrinthine- Retrosigmoid Approach for Improved Exposure of the Posterior Fossa Without Cerebellar Retraction

Abstract—The combined retrolabyrinthine-retrosigmoid (CRR) approach utilizes anterior retraction of the sigmoid sinus to improve exposure of the posterior fossa without cerebellar retraction. The CRR was initially used for vestibular neurectomy but is now utilized for acoustic neuroma excision with hearing preservation and exposure for clipping of basilar and vertebrbasilar aneurysms. This excellent exposure of the cerebellopontine angle without cerebellar retraction can be used for all posterior fossa exposures. (*Skull Base Surgery*, 5(3): 177–180, 1995)

The combined retrolabyrinthine-retrosigmoid (CRR) approach was developed to improve exposure of the posterior fossa through a small craniotomy without cerebellar retraction. This approach utilizes a limited mastoidectomy, complete removal of bone from the sigmoid sinus, and anterior retraction of the sinus after an incision in the dura is made parallel and 3 mm posterior to the sigmoid sinus. The CRR approach was first utilized for vestibular neurectomy and expanded to include acoustic neuroma excision with hearing preservation.^{1,2} Because this approach allows for excellent exposure of the cerebellopontine angle (CPA) without cerebellar retraction, it is now being used for all posterior fossa exposures.

In addition, the CRR approach can be extended by ligating and transecting the sigmoid sinus to expose widely the posterior fossa and petroclival region.³ This exposure allows for clipping midbasilar and vertebrbasilar artery aneurysm while avoiding cerebellar and temporal lobe retraction.

METHODS

Operative Technique

The patient is placed in the supine position with the neck in maximum flexion, rotated away from the surgeon. The head is taped to the table. A Foley catheter is placed. Facial nerve, direct VIIIth nerve, and auditory brainstem evoked response monitoring is performed. Intravenous nafcillin 2 g is given 1 hour prior to surgery, on skin incision, and 8 hours postoperatively. The mastoid tip is identified. A 5 × 4 cm, U-shaped flap based anteriorly on the postauricular crease is drawn on the skin. The vertical dimension is 5 cm. The incision is made down to the periosteum, and the flap is elevated in one layer off the mastoid cortex. Bleeding from the emissary vein is controlled with electrocautery and bone wax. Fishhook retractors are used to hold the skin flap forward, and large

Weitlander retractors are inserted to allow maximum exposure. Mannitol 1.5 g/kg intravenously is administered at the time of skin incision. A limited mastoidectomy is performed using a Midas Rex (Ft. Worth, TX) pneumatic drill with cutting and diamond burrs. The sigmoid sinus is identified and skeletonized to a distance 3 cm inferior to the transverse sinus. Bone is removed completely from the sigmoid sinus. Bleeding from the sinus is controlled with an Avitene Gelfoam pack.

Next, the bone is removed behind the sigmoid sinus exposing a 1.5 cm width of dura (Fig. 1). A 3 cm dural incision is made 3 mm behind and parallel to the sigmoid sinus. Three stay sutures are placed through the sigmoid sinus cuff and are used to retract it anteriorly. A Penrose drain is placed against the cerebellum, and the posterior wall of the temporal bone is followed toward cranial nerves (CNs) IX to XI until the arachnoid layer is identified over the jugular foramen.

An important landmark in the CPA cistern is the white jugular dural fold that is attached to the temporal bone just lateral to the jugular foramen and above the exit of the CNs IX, X, and XI. After the cerebrospinal fluid (CSF) is released by opening the arachnoid adjacent to the CN IX, the cerebellum falls away from the temporal bone and allows excellent exposure of the structures within the CPA (Fig. 2). No cerebellar retraction is necessary. CNs V through XI can be identified.

If the internal auditory canal (IAC) is to be opened, a 1 cm U-shaped incision is made in the dura over the temporal bone from the operculum of the endolymphatic sac to the porus acousticus. It is based at the sinus (Fig. 3). The dural flap is elevated by sharp dissection. A large diamond bur drill is used to remove 5 to 7 mm of bone over the posterior portion of the IAC. It is important to measure the distance between the porus acousticus and the singular nerve on the preoperative bone window computed tomography scan to determine how much bone can

be removed without opening the labyrinth. Air cells that connect with the IAC are sealed with bone wax to prevent a postoperative CSF leak.

The posterior fossa dura is closed in a watertight fashion using interrupted 4-0 silk sutures. All mastoid air cells are filled with bone wax. The surgical defect is filled with adipose tissue obtained from a left lower quadrant incision. The postauricular flap is closed in two layers and the skin is closed with staples. No drain is used.

DISCUSSION

The CRR approach offers several important advantages over the standard suboccipital approach. The extra exposure produced by anterior retraction of the sigmoid sinus allows the surgeon to follow the temporal bone to the arachnoid layer over the CPA without retracting the cerebellum. Once CSF is released, wide exposure of all structures in the posterior fossa is obtained. To date, this procedure has been used to perform selective vestibular nerve sections in more than 100 patients. Ninety-one percent were cured of their vertigo and hearing was preserved to within 20 decibels of their preoperative value.⁴ In addition, 16 acoustic neuromas have been excised by this technique.²

The combined retrosigmoid retrolabyrinthine approach provides the surgeon with a rapid, wide exposure of the posterior fossa and cranial nerves without cerebellar retraction. The main advantage of the combined approach is to improve exposure of the posterior fossa and posterior body wall of the temporal bone by retracting the lateral sinus anteriorly. Performing a limited mastoidectomy allows exposure of the lateral sinus from the jugular bulb to the transverse sinus. Skeletonizing the lateral sinus allows placement of the dural incision to within 3 mm of the posterior border of the sinus. Stay sutures are

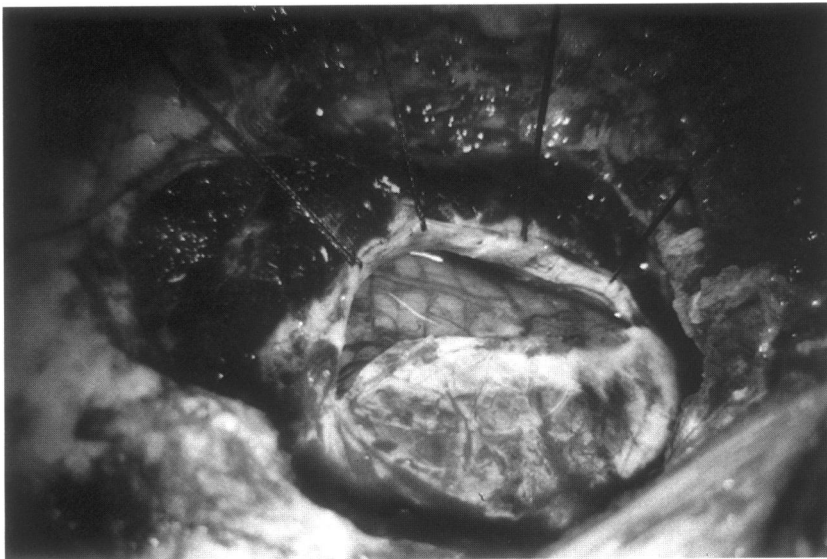


Figure 1. Right combined retrolabyrinthine-retrosigmoid approach showing bone removed surrounding the sigmoid sinus. The sigmoid sinus is retracted anteriorly giving added exposure of the temporal bone and posterior fossa.

Figure 2. Right combined retrolabyrinthine-retrosigmoid approach showing excellent exposure of the posterior fossa after releasing cerebrospinal fluid from the cerebellopontine angle.

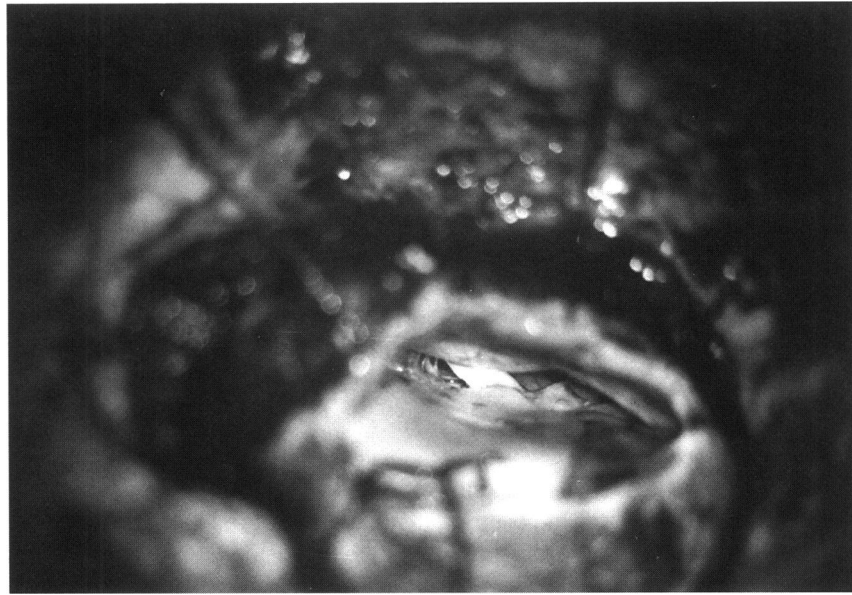
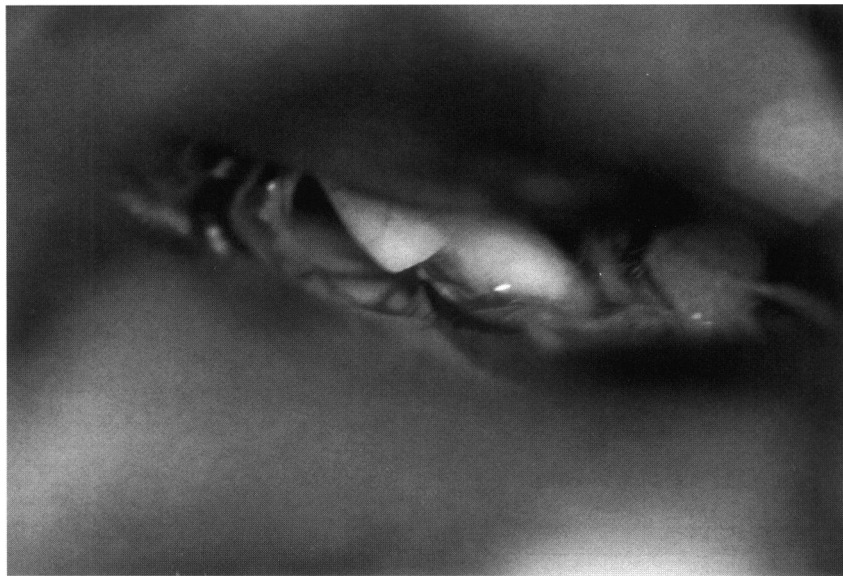

Figure 3. Right vestibular neurectomy completed through the combined retrolabyrinthine-retrosigmoid approach.



then placed to retract the sinus anteriorly. This provides immediate exposure of the posterior wall of the jugular-dural fold.⁵ This important landmark helps to orient the surgeon as to the location of the CNs in the posterior fossa. The CNs and IAC can then be exposed directly without the need for cerebellar retraction. Further exposure is achieved by incising the arachnoid and releasing CSF.

Drilling the IAC during posterior fossa surgery increases the risk of a postoperative CSF leak, particularly in cases where peri-IAC pneumatization is extensive. It is often difficult to ensure that all opened air cells within the IAC have been identified and occluded. It is possible to extend a limited mastoidectomy to a complete cortical

mastoidectomy to identify and repair a CSF leak originating from a peri-IAC air cell. This is an added advantage of the combined approach.

CONCLUSION

The extra time taken to remove bone surrounding the sigmoid sinus is worth the effort because it allows the added exposure of the posterior fossa without cerebellar retraction. The combined retrolabyrinthine-retrosigmoid approach is helpful for all procedures performed in the posterior fossa.

REFERENCES

1. Silverstein H, Norrell H, Smouha E, Jones R: Combined retrolab retrosigmoid vestibular neurectomy. An evolution in approach. *Am J Otol* 10:166-169, 1989
2. Rosenberg S, Flamm E, Hoffer M, Schwartz D: The retrolabyrinthine transsigmoid approach to midbasilar artery aneurysms. *Laryngoscope* 102:100-104, 1992
3. Silverstein H, Rosenberg S, Hoffer M, Nichols M, Willcox T: Posterior fossa vestibular neurectomy: 14 years experience. In Filipo R, Barbara H (eds): *Meniere's Disease: Perspectives in the '90s*. Amsterdam, NY: Kugler Publications, 1994
4. Silverstein H, Rosenberg S: Management of acoustic neuroma. In *Surgical Techniques of the Temporal Bone and Skull Base*. Philadelphia: Lea & Febiger, 1992, 145-169
5. Silverstein H, Willcox TO, Rosenberg SI, Seidman MD: The jugular dural fold: A helpful skull base landmark to the cranial nerves. *Skull Base Surg* 5:1:57-61, 1995

REVIEWER'S COMMENTS

The technique described by Silverstein et al is not new but indications for using it have been expanded. The advantage of this approach for acoustic neuroma removal over a standard suboccipital approach is that there is less cerebellar retraction. This seems logical but is unproven until a comparison of results using the two methods is presented. Using this approach for basilar artery aneurysm exposure is an interesting suggestion. In our experience, after wide exposure of dura around the sigmoid, a presigmoid incision with ligation of the superior petrosal sinus and division of the tentorium gives the best exposure to these difficult aneurysms. This can give wide exposure without the risks of sigmoid sinus ligation.

Thomas L. Eby, M.D., F.A.C.S.