

Intraoperative Electro-oculographic Monitoring for Skull Base Surgery

ABSTRACT—During surgery on the skull base, preservation of the integrity of the ocular motor nerves is vitally important. Intraoperative electrophysiological monitoring methods for protecting such functions have been reported by several investigators. However, these methods so far have not been popularized sufficiently, due to the difficulty and complexity of the procedures involved. The authors have developed an extremely simple but far more reliable method using electro-oculography under total intravenous anesthesia with propofol to preserve the integrity of the ocular motor nerves. The ocular motor nerves were stimulated with a monopolar electrode intracranially, and the polarity of the waves was recorded using surface electrodes placed around the eyeball, yielding precise information concerning the locations of the oculomotor nerve and/or abducent nerve. In addition, by performing continuous monitoring, invasive procedures affecting the ocular motor nerves could be detected as spontaneous ocular movements. In practice at our department, this method has been applied in 12 cases with tumors close to the ocular motor nerves, and has produced excellent results.

Intraoperative electromyographic (EMG) monitoring for protecting the integrity of the ocular motor nerves has been described by several groups.¹⁻⁵ However, these methods so far have not been widely popularized, due to the difficulty and complexity of the procedures involved. We have reported elsewhere⁶ an electro-oculographic (EOC) technique for such a purpose, which is extremely simple and far more reliable. We describe here the details of our technique and discuss its efficacy for preserving ocular motor nerve functions during skull base surgery, and present some representative cases.

METHODS

Total intravenous anesthesia was maintained by administering propofol and fentanyl without using mus-

cle relaxants except for intubation. In general, the dose of propofol was kept at approximately 10 mg/kg/hr during surgery and a bolus injection of 1 or 2 μ /kg of fentanyl was added on the basis of the patient's heart rate and blood pressure. To stimulate the cranial nerves electrically during surgery, a monopolar stimulator was used. The tip diameter of this stimulator is 0.75 mm, and it is made of malleable silver. The portion 7 cm from the head of the stimulator can be bent as necessary so that the stimulator, with its small and bendable tip, can reach a deep and narrow operative field. Cathodal stimulation was performed through this electrode, and an anodal electrode was placed on Fz (International 10-20 system). Rectangular pulses of 0.2-msec duration were applied with a repetition rate of 3 times per sec. The stimulus intensity that we used was restricted to up to 3 mA in the present study.

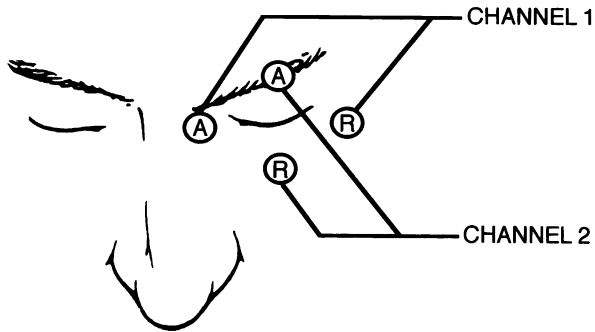


Figure 1. Surface electrodes were placed on the skin around the eyeball. For channel 1, the active electrode was placed on the right side and the electrode for reference on the left side. For channel 2, the active electrode was placed on the upper side of the eyeball and the reference on the lower side.

The cornea is positively charged relative to the retina, giving rise to a corneo-retinal potential difference, which reaches the millivolt level in humans. Marg⁷ has thus stated that "the eyeball may be thought of as a rotatable battery situated within a conducting medium." EOG detects movements of the eyeball as a response observed in the resting potential recorded at the periorbital skin.⁸ This technique is commonly used in the field of ophthalmology, and provides a convenient noninvasive means of examining the movement directions of the eyeball. Surface electrodes were placed on the periorbital skin, as shown in Fig. 1. For channel 1, the active electrode was placed on the right side and the electrode for reference on the left side. For channel 2, the active electrode was placed on the upper side of the eyeball and the reference on the lower side. The surface electrodes used here were conventional ones that were identical to those used for recording electrocardiograms. The bandpass ranged from 5 Hz to 3 KHz. No signal processing was needed.

RESULTS

Intraoperative EOG monitoring was applied in 12 cases with brain tumors close to the skull base in whom there was some possibility that the ocular motor nerves might suffer injury during surgery. These cases included six large cerebellopontine angle tumors, four petrosal apex meningiomas, and two cavernous sinus tumors.

Electrical Stimulation-induced EOG Responses

It proved possible to record EOG responses to electrical stimulation of the oculomotor nerve in all of the 10 cases in which this nerve was exposed within the op-

erative field. Electrical stimulation of the left oculomotor nerve consistently elicited a positive monophasic wave in traces from the pair of electrodes in a horizontal orientation (channel 1), indicating movements of the eyeball toward the right side, whereas stimulation of the right oculomotor nerve elicited a negative wave, indicating movements of the eyeball toward the left side. The oculomotor nerve was identified by visual inspection during surgery in all of the present cases. The electrical stimulation-induced EOG responses provided little additional information concerning the location of the oculomotor nerve, but were useful in two cases to detect a segment of the oculomotor nerve that was located behind or involved in the tumor mass before such a segment was exposed within the operative field. Thus, electrical stimulation activated the oculomotor nerve located beneath the tumor tissue, insofar as the stimulation was applied to the proximity of the oculomotor nerve.

It proved possible to record EOG responses to electrical stimulation of the abducent nerve in all of the 11 cases in which this nerve was exposed within the operative field. Electrical stimulation of the left abducent nerve consistently elicited a negative monophasic wave in traces from the pair of electrodes in a horizontal orientation (channel 1), indicating movements of the eyeball toward the left side, whereas stimulation of the right abducent nerve elicited a positive wave, indicating movements of the eyeball toward the right side. Thus, the oculomotor and abducent nerves of the same side could be clearly differentiated on the basis of the opposite polarity of their EOG responses. In seven cases, a segment of the abducent nerve located behind the tumor mass was identified from EOG responses before this nerve was actually exposed within the operative field. Thus, electrical stimulation activated the abducent nerve located beneath the tumor tissue or the dura, insofar as the stimulation was applied to the proximity of the abducent nerve.

We attempted to record EOG responses to electrical stimulation of the trochlear nerve in the four earlier cases when this nerve was exposed within the operative field. However, no consistent EOG responses were recorded with either the pair of electrodes in a horizontal orientation (channel 1) or the pair of electrodes in a vertical orientation (channel 2). In the subsequent eight cases, we abandoned the pair of electrodes in a vertical orientation because the oculomotor and abducent nerves could be consistently identified and their function was satisfactory, monitored only with the pair of electrodes placed in a horizontal orientation.

Mechanically Induced EOG Responses

In seven cases, EOG responses elicited by surgical manipulation were recorded in the pair of electrodes in a

horizontal orientation (channel 1) as polyphasic waves during mechanical dissection of the oculomotor and/or abducent nerves from the tumor tissue. While an electrical current associated with hemostatic coagulation may cause similar EOG responses, electrical artifacts prevented such responses from being detected. The mechanically induced EOG responses usually consisted of multiple spiky waves followed by a slow wave. The polarity of the multiple spiky waves was opposite to that of the electrical stimulation-induced EOG responses. In the present series of cases, we attempted to avoid the induction of a prolonged EOG response with a polarity opposite to that of the electrical stimulation-induced EOG responses because such a response could indicate cessation of nerve function. None of these cases demonstrated any new postoperative deficit in their ocular movements.

ILLUSTRATIVE CASES

Case 1

This 52-year-old woman presented with a large acoustic neurinoma of the left side (Fig. 2). She had been operated on 1 year previously via a suboccipital approach at another hospital and the caudal one third of the tumor had been excised. She had then developed ataxic gait progressively and referred to our service. Her ocular movements were intact preoperatively. She underwent excision of the tumor via a combined presigmoid transpetrosal approach. Electrical stimulation of the trochlear nerve did not elicit any evident EOG responses. During piecemeal excision of the tumor, the tu-

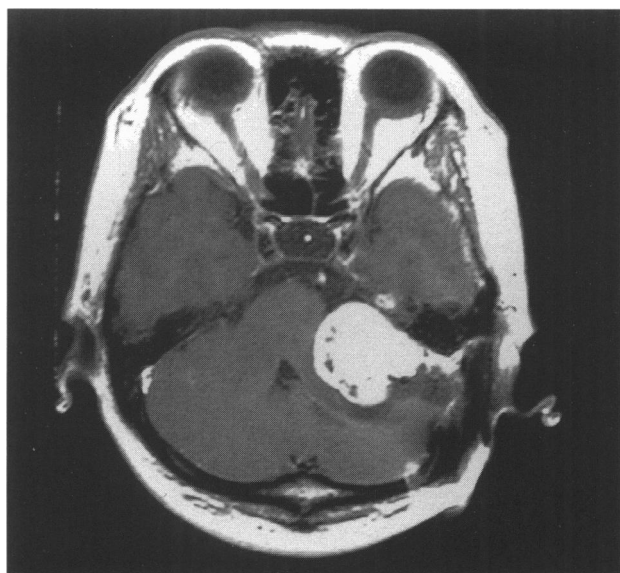

Figure 2. Preoperative MRI in Case 1, revealing a large mass lesion in the cerebellopontine angle.

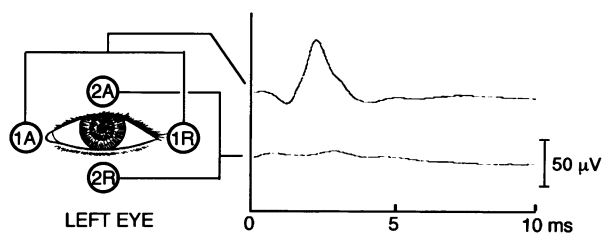


Figure 3. Intraoperative recordings elicited by intracranial stimulation. In the left eyeball, when the surgeon stimulated the abducent nerve, an ocular movement toward the left side was induced. It yielded a negative wave. 1A = active electrode of channel 1; 1R = reference electrode of channel 1; 2A = active electrode of channel 2; and 2R = reference electrode of channel 2.

mor mass was stimulated intermittently to confirm the extent of the facial and abducent nerves. The surgeon sometimes used the stimulation electrode as a tumor dissector while electrical stimulation was continued. Just before the surgeon identified the abducent nerve visually, electrical stimulation-induced EOG responses were detected. Electrical stimulation of the abducent nerve elicited ocular movements toward the left side, yielding a clear negative monophasic wave with a high reproducibility in traces obtained from the pair of electrodes in a horizontal orientation (Fig. 3). The postoperative ocular movement was full, and gross total excision of the tumor was confirmed by postoperative magnetic resonance imaging (MRI) (Fig. 4). The findings in this case indicated that application of the stimulation electrode as a tumor dissector with continued electrical stimulation was useful for earlier identification of the ocular motor nerves.

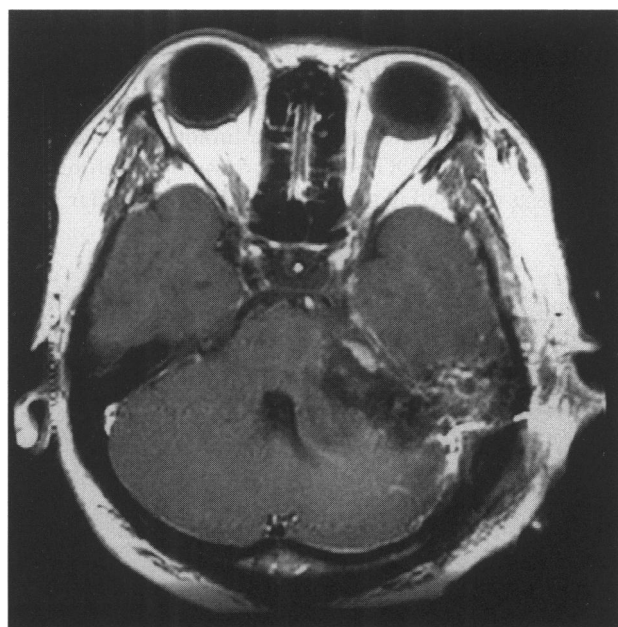

Figure 4. Postoperative MRI in Case 1.

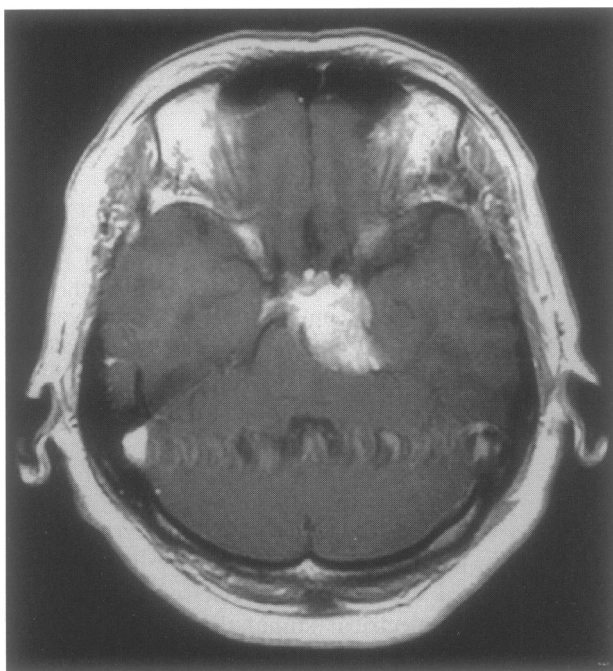


Figure 5. Preoperative MRI in Case 2, revealing an enhanced mass lesion in the left petroclival region.

Case 2

This case was a 69-year-old woman who had a petroclival meningioma on the left side (Fig. 5). Her ocular movements were intact preoperatively. She underwent excision of the tumor via a combined presigmoid transpetrosal approach. The electrical stimulation-induced EOG responses obtained in this case were useful for detecting a segment of the oculomotor nerve displaced by the tumor mass before such a segment was exposed within the operative field. Electrical stimulation of the oculomotor nerve provoked a clear negative monophasic wave in traces from the pair of electrodes in a horizontal orientation (Fig. 6). A segment of the abducent nerve located beneath the tumor mass was also identified from EOG responses observed before this nerve was exposed in the operative field. A similar EOG

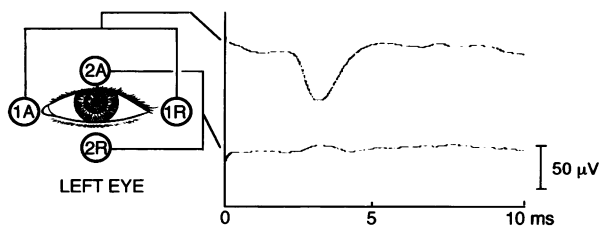


Figure 6. In the left eyeball, when the oculomotor nerve was stimulated intracranially, an ocular movement towards the right side was induced. It yielded a clear monophasic positive wave with a high reproducibility. The electrode placements were the same as in Fig. 1.

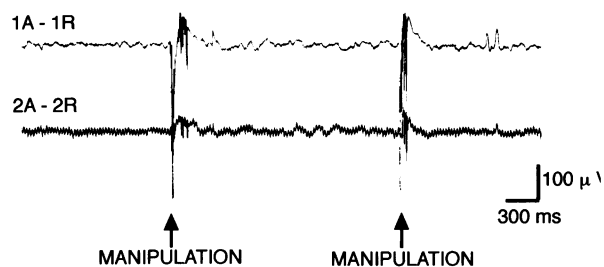


Figure 7. Ocular movements recorded an intermittent multiple spiky waves when the surgeon manipulated the abducent nerves mechanically in Case 2.

response to those obtained in case 1 was noted when the abducent nerve was stimulated. EOG responses were also elicited by surgical manipulation performed during mechanical dissection of the abducent nerves from the tumor tissue (Fig. 7). The postoperative ocular movement was full, and MRI demonstrated total removal of the tumor except for immediately adjacent to the abducent nerve (Fig. 8). The findings in this case suggested that monitoring of mechanically induced EOG responses may be useful for avoiding damage to the ocular motor nerves.

DISCUSSION

Techniques for intraoperative electrical stimulation of cranial nerves have been reported by several investigators.^{9,10} Broadly speaking, these techniques can be separated into two groups: monopolar and bipolar stim-

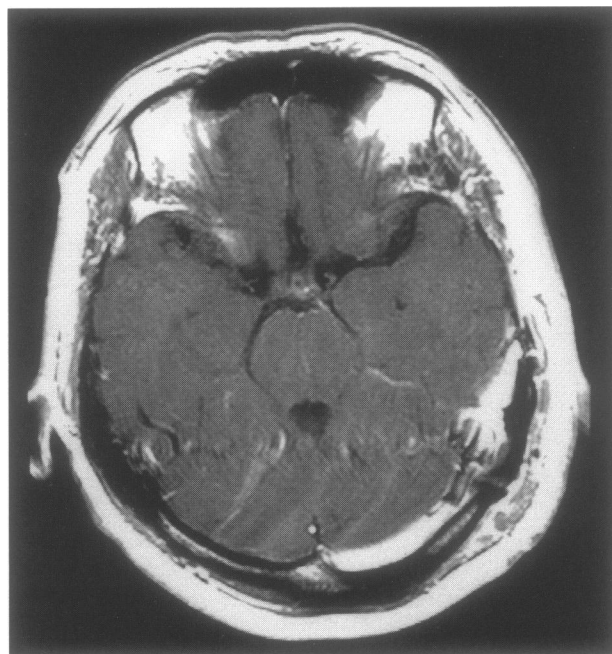


Figure 8. Postoperative MRI in Case 2.

ulations. Each method has certain advantages and disadvantages.^{1,5} In the present study, we used monopolar stimulation, mainly because a monopolar electrode is easy to manipulate and can be utilized also as a tumor dissector. Although we do not intend to discuss the selection of stimulation techniques here, emphasize that the use of a stimulation electrode as a tumor dissector with continued electrical stimulation was useful for earlier identification of the ocular motor nerves.

Among the above intraoperative electrophysiological monitoring methods that have so far been reported to protect the ocular motor nerves, all (insofar as we are aware) have used EMG of the extraocular muscles recorded with a needle¹⁻³ or special ring electrode.^{4,5} It is often difficult and a highly skilled technique is required, to insert needle electrodes into the extraocular muscles precisely because the latter are exceedingly thin and exist in the deep part of the orbit where they must be reached almost blindly. Sekhar's methods for monitoring the function of the oculomotor and abducent nerves involved needle electrodes inserted transcutaneously near the orbital muscles and, in other patients, directly into these muscles, which were exposed after orbital osteotomy.¹⁰ Sekiya et al.^{4,5} stimulated the ocular motor nerves intracranially, and recorded the compound muscle action potential directly from the extraocular muscles with a ring electrode that they developed for this purpose. Even these methods cannot be performed quickly without some extent of invasion of the patient and the use of special tools.

In contrast, our new recording technique is simple to apply and noninvasive. The present study further indicated that this procedure is sufficiently sensitive to identify the location of the ocular motor nerves. The trochlear nerve, however, was not identified by the EOG technique. This appears to be related to how the trochlear nerve acts upon the eyeball. The trochlear nerve imparts rotational movements to the eyeball, and such movements are not discernible by EOG. Impairment of trochlear nerve function has been said to give rise to less serious clinical effects than impairments of the oculomotor and abducent nerves.³ The inability of EOG to monitor the trochlear nerve function does not therefore detract seriously from the usefulness of this technique.⁵

In addition, the present study demonstrated that mechanical manipulation of the ocular motor nerves can induce EOG responses. In our experience, this type of response is not observed in EMG of extraocular muscles. Because the polarity of the multiple spiky waves of the mechanically induced EOG responses was opposite to that of the electrical stimulation-induced EOG responses, the former responses could represent transient cessation of function of the manipulated nerve rather than mechanical stimulation. It would not be surprising if EMG of extraocular muscles was unable to detect such an event. Although a definitive conclusion awaits further studies, this aspect may potentially represent another advantage of intraoperative EOG monitoring. Future investigations should focus on the relationship between postoperative deficit in the ocular movements and intraoperative changes in the EOG recordings.

REFERENCES

1. Daube JR. Intraoperative monitoring of cranial motor nerves. In Schramm J, Møller AR: *Intraoperative Neurophysiologic Monitoring in Neurosurgery*, Berlin: Springer-Verlag, 1991
2. Kawaguchi M, Ohnishi H, Sakamoto T, Shimizu K, Touho H, Monobe T, Karasawa J. Intraoperative electrophysiological monitoring of cranial motor nerves in skull base surgery. *Surg Neurol* 1995;43:177-181
3. Møller AR. Intraoperative monitoring of cranial motor nerves. In Møller AR: *Evoked Potentials in Intraoperative Monitoring*, Baltimore: Williams and Wilkins, 1988
4. Sekiya T, Hatayama T, Iwabuchi T, Maeda S. Technical note: A ring electrode to extraocular muscle activities during skull base surgery. *Acta Neurochir (Wien)* 1992;117:66-69
5. Sekiya T, Hatayama T, Iwabuchi T, Maeda S. Intraoperative recording of extraocular muscle activities to monitor ocular motor nerve function. *Neurosurgery* 1993;32:227-235
6. Fukaya C, Katayama Y, Kasai M, Kurihara J, Yamamoto T. Intraoperative monitoring of ocular motor nerve function for skull base surgery using electro-oculography. *J Neurosurg* 1999; 91:157-159
7. Marg E. Development of electro-oculography: Standing potential of the eye in registration of eye movement. *Arch Ophthalmol* 1951;45:169-185
8. Uemura T, Suzuki J, Hozawa J, Highstein SM. The methods of recording of eye movements. In Uemura T, Suzuki J, Hozawa J, Highstein SM: *Neuro-otological Examination*, Tokyo: Igaku-shoin, 1977
9. Daube JR, Harper CM. Surgical monitoring of cranial and peripheral nerves. In Desmedt JE: *Neuromonitoring in Surgery*, New York: Elsevier, 1989
10. Sekhar LN, Møller AR. Operative management of tumors involving the cavernous sinus. *J Neurosurg* 1986;64:876-889