

Research

Open Access

Patterns of cervical metastasis from carcinoma of the oral tongue

CS Nithya¹, Manoj Pandey^{*2}, BR Naik¹ and Iqbal M Ahamed²

Address: ¹Department of Oral and Maxillofacial Surgery, Government Dental College, Thiruvananthapuram, India and ²Surgical Oncology, Regional Cancer Centre, Thiruvananthapuram, India

Email: CS Nithya - oncosurgery@hotmail.com; Manoj Pandey* - manojpandey@rcctvm.org; BR Naik - oncosurgery@hotmail.com; Iqbal M Ahamed - oncosurgery@rcctvm.org

* Corresponding author

Published: 03 July 2003

Received: 16 January 2003

World Journal of Surgical Oncology 2003, 1:10

Accepted: 03 July 2003

This article is available from: <http://www.wjso.com/content/1/1/10>

© 2003 Nithya et al; licensee BioMed Central Ltd. This is an Open Access article: verbatim copying and redistribution of this article are permitted in all media for any purpose, provided this notice is preserved along with the article's original URL.

Abstract

Background: Cancer of the oral tongue is the second most common cancer among males in various parts of India. Despite advances in diagnosis and treatment the failure rates in cancer of the oral tongue are high and survival poor. Majority of these failures occur in untreated neck.

Method: A retrospective review of the records of 75 patients undergoing surgery for the treatment of squamous cell carcinoma of the oral tongue was carried out to ascertain the pattern of metastasis in the neck and to evaluate the sensitivity of clinical examination in predicting nodal spread.

Results: All the patients underwent primary surgery. Cervical lymph node metastasis was found in 35.6% of T₁ and T₂ tumours and 62.35% of T₃ and T₄ tumours. Sensitivity of clinical examination was found to be 54.5% and specificity of 61.9%. Level II was the most commonly involved (63.6%). Isolated level IV involvement was never found in clinically negative neck. Tumour stage and node status were found to have a significant impact on disease free survival in both univariate and multivariate analysis.

Conclusions: As the sensitivity and specificity of the clinical examination is low we suggest that methods like ultrasound or CT Scan of the neck should be regularly employed to improve the sensitivity and specificity of the examination. Furthermore as isolated level IV involvement is never found in our series, we suggest that a prophylactic supraomohyoid neck dissection should be carried out in all patients with a clinically node negative neck with cancer of oral tongue, to achieve a better disease free survival.

Introduction

Squamous cell carcinoma of the tongue is a common malignancy treated by surgeons. Incidence of tongue cancer in India is second highest in the world. Among males the age adjusted incidence rate is as high as 14/100,000

per/year in Ahmedabad while among females it is 7.4/100,000 in Mumbai [1]. In Trivandrum the incidence of tongue cancer is 5.2/100,000 among males and 2.4/100,000 among females [2].

Table 1: Surgical management of neck by pathological node status.

	pN ₀	pN ₁	pN _{2a}	pN _{2b}	pN _{2c}	pN ₃	Total	Percentage
Level I Clearance*	1	0	0	0	0	0	1	1.3
SOHND	15	4	0	3	0	0	22	29.3
MND	21	7	1	8	0	1	38	50.6
RND	0	1	1	4	0	0	6	8
B/L SOHND	1	0	0	0	0	0	1	1.3
I/L MND C/L SOHND	2	0	0	1	0	0	3	4
B/L MND	0	0	1	0	1	0	2	2.6
I/L MND C/L SOHND	1	0	0	0	0	0	1	1.3

SOHND – Supra omohyoid neck dissection; MND – Modified neck dissection; RND – Radical neck dissection; B/L – Bilateral; I/L – Ipsilateral; C/L – Contralateral. * patient had a cardiac arrest during surgery and the procedure was abandoned, this patient went on to develop neck node recurrence and was successfully salvaged by second surgery.

Tongue is a complex anatomical site and its form and function are crucial for efficient swallowing, speech and appreciation of taste. In past different methods of treatment have been employed but tongue has remained a difficult area to assess and treat. The survival in carcinoma of the tongue is poor compared to other subsites in oral cavity.

The distribution of cervical lymph node metastasis from squamous cell carcinoma at different subsites in the oral cavity has been described before [3–5]. However, there are very few studies from India, where the incidence of tongue cancer is high. The distribution of metastases suggests skip lesions and peppering [3,5,6]. Predicting the lymphatic spread from cancer of the oral tongue can help in choosing the appropriate surgical procedure and may also help in predicting the outcome. The purpose of the present study was to assess the pattern of cervical node metastasis from carcinoma of the oral tongue and to evaluate the impact of tumour status on survival.

Patients and Methods

A retrospective analysis of 75 patients undergoing primary surgical resection for squamous cell carcinoma of oral tongue between January 1997 and December 1998, in a single surgical unit, was carried out to evaluate the pattern of nodal metastasis and survival. The variables like age, sex, tumour size, grade, clinical TNM, pathological TNM and histopathological levels of involvement were extracted from case records. All the patients underwent evaluation under general anaesthesia before the surgery and clinical TNM was modified if indicated. The types of surgical procedures performed are detailed in table 1. Adjuvant radiotherapy (45 Gy/15 fraction) was given if the primary tumour was greater than 2 cm, had close margins or nodal involvement was present or there was extranodal involvement. Minimum duration of follow-up was two years following surgery. Survival analysis was car-

ried by Kaplan-Meier method and the curves were compared using log rank test. Multivariate analysis was carried out using Cox proportional hazard model.

Results

Age of the patients ranged from 22 to 75 years with a mean age of 52.6 years. The male, female ratio was 1.5:1 (Table 2). All the patients had undergone primary surgical resection.

At presentation, 44% of patients had T₂ tumour followed by T₃ in 20% (Table 2). Clinically 34 patients were found to be neck node positive of which 26 (34.7%) were cN₁, 6 (8%) were cN_{2b} and 2 (2.7%) were cN_{2c}. Histologically 33 cases were found to have positive neck nodes, of which majority (16; 21.3%) were pN_{2b}. The T and N stage distribution is detailed in table 2. Cervical lymph node metastasis was present in 47.1% of T₁ tumours, 24.13% of T₂ tumours, 63.6% of T₃ tumours and 61.1% of T₄ tumours (Table 3). Histologically 18 cases were true positive for nodal metastasis while 26 cases were true negative giving a sensitivity of 54.5% and specificity of 61.9% for clinical examination of the neck (Table 4). Synchronous discontinuous operations were performed in all cases. None of the patients had a positive resection margin, however the margin was close (2–5 mm) in 11 cases. Neck was managed by vein preserving neck dissection in 27 cases (36%) and supraomohyoid neck dissection in 22 cases (29.3%) (Table 1). It was observed that the nodal involvement in ipsilateral level II was highest (63.6%), followed by the involvement of level I (51.5%), level III (18.2%) and level IV (15.2%) (Table 1). Table 2 shows the distribution of nodes at different levels of the neck in varying combination. Skip metastasis to level III / III and IV occurred in 5 cases. On histopathological examination, only one patient had bilateral positive nodes. These nodes were located at level I bilaterally and the patient had undergone bilateral vein preserving neck dissection (Table 1). A total

Table 2: Frequency distribution of various parameters studied.

Variable	Frequency	Percentage
Sex		
Male	45	60
Female	30	40
Tumour Status:		
T ₁	13	17.3
T ₂	33	44
T ₃	15	20
T ₄	14	18.7
Clinical node status:		
cN ₀	41	54.7
cN ₁	26	34.7
cN _{2b}	6	8
cN _{2c}	2	2.7
Pathological node status:		
pN ₀	42	56
pN ₁	12	16
pN _{2a}	3	4
pN _{2b}	16	21.3
pN _{2c}	1	1.3
pN ₃	1	1.3
Pathological node distribution in the neck (33 cases)		
I	6	18.2
II	12	36.4
III	2	6.1
I, II	7	21.2
I, III	1	1.3
I, IV	1	1.3
II, III	0	0
II, IV	1	1.3
III, IV	2	6.1
I, II, III, IV	1	1.3

cN – clinical node status, pN – pathological node status.

of 59 patients received adjuvant radiotherapy, radiotherapy was given to 32/34 patients with N+ disease, or extranodal spread. Nine patients with T1N0 disease and 5 patients with T2N0 disease and one patient each with T1N1 and T2N1 disease did not receive adjuvant radiotherapy.

Over the two-year follow-up, 19 cases failed, the failure was nodal in 8, primary in 8, and both primary and nodal in 3 patients. The clinical TNM, pathological TNM and level of positive node are illustrated in additional table 1. The overall disease free survival (DFS) was found to be 78.4% at 1 – year and 68.4% at 2 – years (Table 5) (fig 1). Patients with T₄ tumours were found to have a significantly poor survival, with the disease free survival at the end of 2 – years being 36.6%. T₁ and T₂ tumours showed better prognosis with disease free survival of 76.2% and 83.5% respectively at the end of 2 – years (Table 5) (figure 2). Histopathological node negative cases had a DFS of 79% at the end of 2 – years whereas pathological N₁ (pN₁)

had survival of 72.7% and pN₂ of 39.5% (P = 0.03) (Table 5) (figure 3). No other parameter including use of adjuvant radiotherapy was found to have significant effect on disease free survival. On multivariate analysis the tumour size and nodal metastasis were found to be significant independent prognostic factors. The hazard ratio for failure was 1.0 for T₂, 1.7 for T₁, 1.72 for T₃ and 1.84 for T₄ tumours. Similarly hazard ratio for failure in N₀ disease was 1.0, it was 9.9 in N₁, 14.9 in N₂ and 21.2 in N₃ disease. Sex was also found to be an independent prognostic factor with hazard ratio for males being 1.4 however this difference was statistically not significant.

Discussion

Squamous cell carcinoma arising in oral tongue is curable if assessed and treated appropriately. Clinically undetectable nodal metastasis is the commonest cause of treatment failure. Incidence of neck metastasis in oral SCC is reported to be 34% to 50% [7,8]. In our series, level II was found to be the most commonly involved site (63.6%)

Table 3: Nodal metastasis by tumour stage.

	pN ₀	pN ₁	pN _{2a}	pN _{2b}	pN _{2c}	pN ₃	% of positive nodes
T ₁	9	4	1	2	1	0	47.05
T ₂	22	2	0	4	0	1	24.13
T ₃	4	2	2	3	0	0	63.6
T ₄	7	4	0	7	0	0	61.1

Table 4: Sensitivity and Specificity of clinical examination in predicting nodal metastasis from cancer of the oral tongue.

		Pathological +ve	-ve
Clinical	-ve	15	26
	+ve	18	16
Sensitivity :		54.5%	
Specificity :		61.9%	

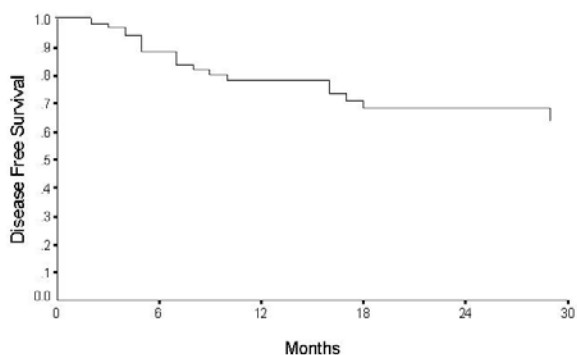


Figure 1
Overall disease free survival for carcinoma oral tongue

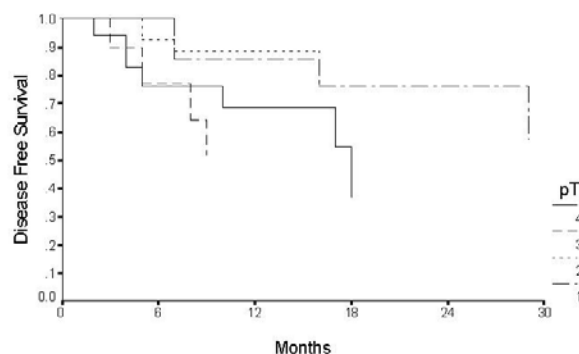


Figure 2
Disease free survival by tumour stage for patients with cancer of the oral tongue.

and level IV involvement was seen in 15.2 % patients. Isolated level IV involvement in absence of involvement of one of the higher levels (I, II or III) was not documented in any patient in the present study. Further, clinically node negative cases never showed level IV involvement. Shah et al (1990) [4] had documented similar results. Hence, a supraomohyoid neck dissection is justified when the neck is clinically negative. On the contrary Byers et al (1997) [3], found 16% of patients with

oral cancer, to have metastasis in level IV without nodes in level I, II or III.

It was seen that only 35.6% of T₁ and T₂ lesions showed nodal metastasis where as 62.3% of the larger tumours showed metastasis (Table 3). Previous studies [9,6] support our finding that tumour size is a predictor of lymph node metastasis though they propose that tumour thickness is a more reliable factor. This is further explained by

Table 5: Disease free survival (DFS) among patients with cancer of the oral tongue by various parameters

Variable	Total No. of cases	Survival 1 year	Survival 2 years	
Overall DFS	75	78.4%	68.42%	
Tumour status:				
T ₁	13	85.71%	76.2%	
T ₂	33	88.7%	83.5%	
T ₃	15	51.4%	51.4%	
T ₄	14	68.6%	36.6%	P = .03
Nodal status:				
pN ₀	42	87%	79%	
pN ₁	12	72.7%	72.7%	
pN ₂	20	61.4%	39.5%	
pN ₃	1	-	-	P = .03

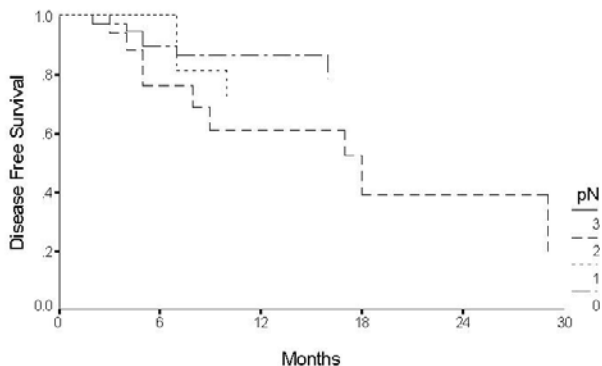


Figure 3
Disease free survival by nodal status for patients with cancer of the oral tongue.

DiTroia (1972) [10], who points to difficulty for the tumour emboli to form in small calibre lymphatics of the superficial areas, compared with wider lymphatic of deeper tissues. However, tumour thickness is a radiological or histological parameter, which cannot be assessed preoperatively by clinical examination or biopsy.

In our study, sensitivity and specificity of clinical examination was poor suggesting that clinical examination is of limited use in predicting cervical nodal metastasis. This is in accord with previous studies [5,6]. One option would be to look for a more reliable methods to asses the neck. Sajeeda et al (2000) [11] documented that ultrasonography is not only useful in detecting neck nodes but is also useful in assessing the nodal characteristic and the degree

of vascular invasion. Takashima et al (1997) [12] demonstrated ultrasound guided fine needle aspiration to have 93.7% diagnostic accuracy. Computed tomographic (CT) scanning too is very useful for the purpose of early detection of neck metastasis [13]. Magnetic resonance imaging (MRI) on the other hand has been found to have little advantage over clinical examination as the soft tissue contrast resolution reported by MRI is inadequate to detect minimal morphological changes in lymph nodes [14].

The technique of sentinel node biopsy is gaining popularity. Surgery on the primary tumour often modifies lymphatic drainage, so sentinel node biopsy is useful when primary tumour and neck are operated at the same time [15]. If the treatment decision has to be based on the present sensitivity and specificity of clinical examination, then a minimum selective neck dissection should be carried out for all node negative necks where primary is being treated by surgery as primary modality. Studies have documented that ipsilateral level I, II and III neck dissection is an adequate diagnostic procedure for staging of the clinically node negative neck in early oral tongue cancer [16,17]. Its diagnostic role cannot be replaced by preoperative radiological screening and intraoperative frozen section sampling.

T₁ and T₂ tumours show a similar, significantly higher disease free survival compared to T₃ and T₄ tumours, even though the number in the present study is small the conclusions can be drawn with conviction from these results as shown in earlier studies on smaller sample size [18]. Brown et al (1989) [19] too have shown similar results. Nodal metastases too significantly correlate with disease free survival as also documented by Woolgar et al (1999)[6]. Similar results were seen in the present study as well, where tumour size, nodal status and surgery as primary modality were found to be a significant predictor of disease free survival.

In the light of the present results showing a poor sensitivity and specificity of clinical examination in predicting nodal metastasis and infrequent involvement of level IV in the absence of involvement of higher levels, we suggest that a supraomohyoid neck dissection should be carried out in all patients of the oral tongue cancer with clinically node negative neck to achieve a better disease free survival.

References

1. Perkin DM, Whelan SL, Ferlay J, Raymond L, Young J and Eds: *Cancer incidence in five continents IARC Sci. Pub no. 143, Lyon, France 1995, VII.*
2. Varghese C and Vijayprasad B: *Population based cancer registry, Trivandrum, 1991–1995 Regional Cancer Centre, Trivandrum; 1999.*
3. Byers RM, Weber RS, Andrews T, McGill D, Kare R and Wolf P: **Frequency and therapeutic implications of "skip metastasis" in the neck from squamous carcinoma of the tongue** *Head Neck* 1997, **19**:14-19.
4. Shah JP, Candela FC and Poddar AK: **The pattern of cervical lymph node metastases from squamous carcinoma of the oral cavity** *Cancer* 1990, **66**:109-113.
5. Woolgar JA and Scott J: **Prediction of cervical lymph node metastasis in squamous cell carcinoma of the tongue/floor of mouth** *Head Neck* 1995, **17**:463-472.
6. Woolgar JA: **T₂ carcinoma of the tongue the histopathologist's perspective** *Br J of Oral Maxillofacial Surg* 1999, **37**:187-193.
7. Lee JG and Krause CJ: **Radical neck dissection: elective, therapeutic and secondary** *Arch Otolaryngol* 1975, **101**:656-659.
8. Woolgar JA, Rogers S, West CR, Errington RD, Brown JS and Vaughan ED: **Survival and patterns of recurrence in 200 oral cancer patients treated by radical surgery and neck dissection** *Oral Oncol* 1999, **35**:257-265.
9. Fukano H, Matsuura H, Hasegawa Y and Nakamura S: **Depth of invasion as a predictive factor for cervical lymph node metastasis in tongue carcinoma** *Head Neck* 1997, **19**:205-210.
10. DiTroia JF: **Nodal metastases and prognosis in carcinoma of the oral cavity** *Otolaryngol Clin N Am* 1972, **5**:333-342.
11. Sajeeda S, Panda N, Mann SB, Katariya S and Kalagara S: **The role of ultrasonography in the management of tumours of the neck** *Ear Nose Throat J* 2000, **79**:586-589.
12. Takashima S, Sone S, Nomura N, Tomiyama N, Kobayashi T and Nakamura H: **Nonpalpable lymph nodes of the neck. Assessment with US and US-guided Fine Needle Aspiration Biopsy** *J Clin Ultrasound* 1997, **25**:283-292.
13. Umeda M, Nishimatsu N, Teranobu O and Shimada K: **Criteria for diagnosing lymph node metastasis form squamous cell carcinoma of the oral cavity: A study of the relationship between computed tomographic and histologic findings and outcome** *J Oral Maxillofac Surg* 1998, **56**:585-593.
14. Feinmesser R, Freeman JL, Noyek AM, Brit D, Gullane P and Mullen JB: **MRI and neck metastases: a clinical, radiological, pathological correlative study** *J Otolaryngol* 1990, **19**:136-140.
15. Chiesa F, Mauri S, Grana C, Tradati N, Calabrese L and Ansarin M et al.: **Is there a role for sentinel node biopsy in early N₀ tongue tumours?** *Surgery* 2000, **128**:16-21.
16. Byers RM, Clayman GL, McGill D, Andrews T, Kare RP, Roberts DB and Gopfert H: **Selective neck dissections for squamous carcinoma of the upper aerodigestive tract: Patterns of regional failure** *Head Neck* 1999, **21**:499-505.
17. Yuen AP, Lam KY, Chan AC, Wei WI, Lam LK, Ho WK and Ho CM: **Clinico-pathological analysis of elective neck dissection for N₀ neck of early oral tongue carcinoma** *Am J Surg* 1999, **177**:90-92.
18. Mathew A, Pandey M and Murthy NS: **Survival analysis: Caveats and pitfall** *Eur J Surg Oncol* 1999, **25**:321-329.
19. Brown B, Barnes L, Mazariegos J, Taylor F, Johnson J and Wagner RL: **Prognostic factors in mobile tongue and floor of mouth carcinoma** *Cancer* 1989, **64**:1195-1202.

Publish with **BioMed Central** and every scientist can read your work free of charge

"BioMed Central will be the most significant development for disseminating the results of biomedical research in our lifetime."

Sir Paul Nurse, Cancer Research UK

Your research papers will be:

- available free of charge to the entire biomedical community
- peer reviewed and published immediately upon acceptance
- cited in PubMed and archived on PubMed Central
- yours — you keep the copyright

Submit your manuscript here:
http://www.biomedcentral.com/info/publishing_adv.asp

