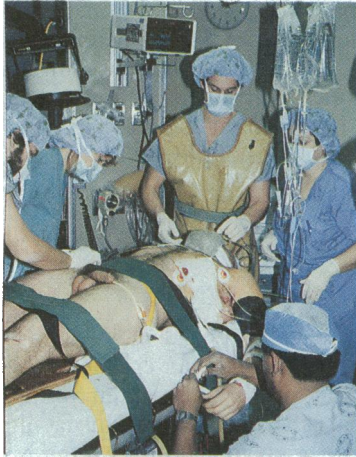


## THORACIC TRAUMA—I

Stephen Westaby, Nigel Brayley



Many patients with catastrophic intrathoracic visceral injury such as laceration of the heart, aorta, or major airways die at the site of incident. Those who reach hospital alive are a self selected group who should survive with early skilled intervention. Yet evidence suggests that most patients who die in hospital of thoracic trauma do so unnecessarily through lack of appropriate treatment. In practice, less than 15 per cent of patients with chest injuries require surgical intervention, pathology in the remainder being confined to the thoracic cage and underlying lung parenchyma. Multiple rib fractures with pulmonary contusion, haemothorax, or pneumothorax can be dealt with simply and effectively by insertion of a chest drain, pain relief, fluid restriction, and physiotherapy. When ignored, underestimated, or inadequately treated, however, such injuries may cause death during surgery for seemingly more important intracranial or abdominal haemorrhage. The basis for successful management of thoracic trauma is effective cardiopulmonary resuscitation followed by early detection and correction of life threatening injuries.

### Mechanisms and patterns of blunt thoracic trauma

Chest wall injuries	Possible thoracic visceral injuries	Common associated injuries
<i>High velocity impact (deceleration)</i>		
Chest wall often intact or fractured sternum or bilateral rib fractures with anterior flail (caused by steering wheel)	Ruptured aorta Cardiac contusion Major airways injury Ruptured diaphragm	Head and faciomaxillary injuries Fractured cervical spine Lacerated liver or spleen Long bone fractures
<i>Low velocity impact (direct blow)</i>		
Lateral—unilateral fractured ribs	Pulmonary contusion	Lacerated liver or spleen if ribs 6-12 are fractured
Anterior—fractured sternum	Cardiac contusion	
<i>Crush</i>		
Anteroposterior—bilateral rib fractures with or without anterior flail	Ruptured bronchus Cardiac contusion	Fractured thoracic spine Lacerated liver or spleen
Lateral—ipsilateral fractures with or without flail Possible contralateral fractures	Pulmonary contusion	Lacerated liver or spleen

Reception and general assessment of the multiply injured patient have been dealt with in previous articles in this series. It is imperative to determine within the first few minutes whether an immediately life threatening thoracic problem exists. The primary survey must take into account the mechanism of injury: there are distinct patterns of injury according to whether the patient has suffered high velocity, low velocity, crush, or penetrating trauma. Remember that the most serious intrathoracic injuries can occur without damage to the chest wall. Diagnosis may be difficult and should depend on prediction and exclusion rather than direct manifestation of injury.

### Immediately life threatening pathophysiological processes

- *Hypoxia and acidosis* secondary to major airway obstruction, haemopneumothorax, pulmonary contusion, or a major circulatory disorder. Is the patient blue, tachypnoeic, cerebrally obtunded, sweaty, or cold?
- *Low cardiac output* secondary to haemorrhage in the chest or abdomen, cardiac tamponade, or profound metabolic deterioration. Does the patient's colour, vital signs, and peripheral perfusion suggest this? Is there active bleeding?
- *Cardiac or vascular injury* that may prove fatal during resuscitation

When the thoracic cage and underlying lungs are injured hypoxia and acidosis caused by untreated haemopneumothorax compound the effects of a direct head injury and should be resolved quickly. Generally, major injuries such as aortic transection, major airways disruption, diaphragmatic rupture, and serious cardiac disruption are apparent in the plain chest radiograph. Such radiography should be undertaken as part of the primary survey and certainly before radiography of the abdomen or limbs. Remember that cardiac or major vascular lacerations with haemorrhage arrested by tamponade may rapidly become fatal during transfusion and raising of intracardiac or arterial pressures. If such injuries are not identified before full resuscitation the patient may bleed to death rapidly as normal blood pressure is restored.

Analysis of blood gas tensions and chest radiography should be undertaken within the first 10 minutes after hospital admission in any patient in whom an important chest injury is suspected.

### Clinical predictors of major chest injury

- Mechanism of injury
- Associated head and abdominal injuries
- Superficial evidence, including seatbelt marks, bruising on the chest, cyanosis, surgical emphysema, and swelling at the root of the neck
- Systemic evidence of major haemorrhage in the absence of abdominal swelling or multiple long bone injuries
- Specific clinical findings, including traumatic asphyxia, absent peripheral pulses, respiratory distress, cardiac tamponade, tracheal displacement, signs of tension haemopneumothorax or pneumothorax, paradoxical chest wall movement, and penetrating chest wounds

### Immediate thoracotomy in the accident and emergency department is restricted to moribund patients:

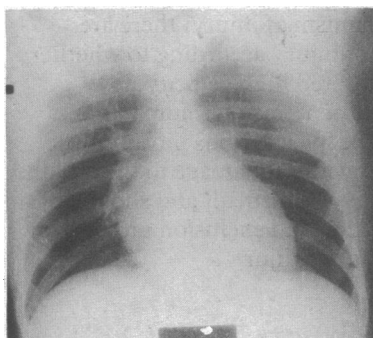
- With penetrating injury who cannot be resuscitated without control of haemorrhage or tamponade
- With blunt trauma, in whom cardiac herniation (through a lacerated pericardium) is suspected or internal cardiac massage is required for other reasons
- With flail or crushed chest with cardiopulmonary arrest
- With massive abdominal haemorrhage, in whom aortic cross clamping and intra-aortic transfusion facilitates preferential resuscitation of the brain and myocardium and arrests abdominal bleeding

Decide whether the clinical findings are those expected from the mechanism of injury. Determine whether the chest injury is more life threatening than associated head or abdominal injuries. From the physical examination determine whether the patient is in immediate danger or whether it is safe to proceed with computed tomography or further radiological assessment of other systems.

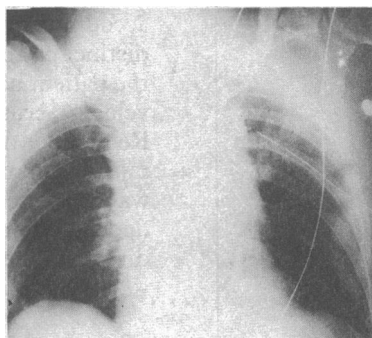
In multiply injured patients with head injury, haemothorax, and intra-abdominal bleeding it is imperative to resuscitate the brain and myocardium. Not infrequently the patient is moribund from cardiac tamponade, upper airways obstruction, tension haemopneumothorax, or profound haemorrhage. Securing the airway by endotracheal intubation or bronchoscopy, evacuation of haemopneumothorax by insertion of a chest drain, or, in the event of tamponade or torrential haemorrhage, immediate thoracotomy must be undertaken on the basis of physical findings.

In the absence of perceptible blood pressure left anterolateral thoracotomy through the fifth interspace can be undertaken to clamp the descending aorta and perform internal cardiac massage. This facilitates restoration of perfusion pressure to the brain and coronary arteries while arresting intra-abdominal haemorrhage. If present, cardiac tamponade can be relieved. With restoration of cardiac output to the upper part of body requirement for craniotomy must be determined rapidly, before performing abdominal surgery. Remember that in the presence of potentially lethal brain, cardiac, or aortic injury other injuries are of secondary importance.

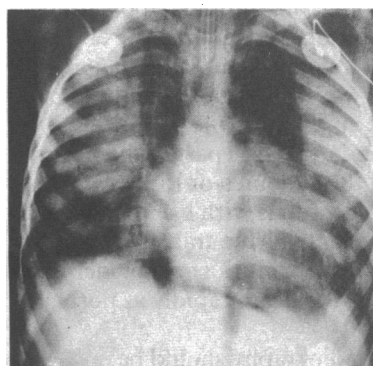
## The plain chest radiograph



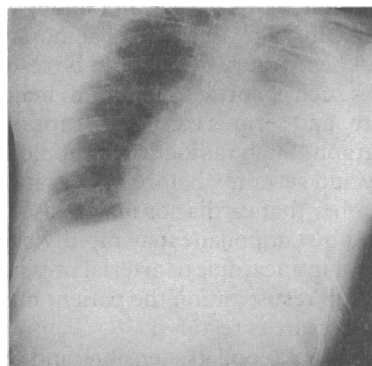
Cardiac tamponade caused by a left parasternal stab wound.



Aortic transection caused by a deceleration accident.



Free air in the mediastinum and beneath the deep cervical fascia owing to tracheal transection.



Ruptured left hemidiaphragm with haemothorax and stomach and ruptured spleen in left pleural cavity.

Plain chest radiography is the most important investigation in patients with thoracic trauma and should be undertaken with the patient erect or semi-erect if possible. This will enable the best assessment of the volume of free air or blood in the chest. In practice, patients with multiple injuries usually undergo radiography in a supine, semi-erect, or lateral decubitus position, with the x rays passing anteroposteriorly.

Most serious injuries, including cardiac tamponade, transected aorta, lacerated diaphragm, and major airways injury, can be diagnosed or ruled out on the basis of chest radiographs. Decide whether the radiological appearances are those expected from the physical signs and mechanism of injury. Are there unsuspected findings? Remember that in as many as 15 per cent of patients with fractured ribs, pulmonary contusion, and surgical emphysema but no pneumothorax the pleural cavity has been obliterated by previous pneumonic adhesions. Free air within the chest wall and haemopneumothorax usually indicate superficial pulmonary laceration by fractured ribs whereas air in the mediastinum (with or without pneumothorax), pneumopericardium, and air deep to the deep cervical fascia of the neck suggest tracheobronchial disruption. This is confirmed by bronchoscopy.

### Radiological features that suggest aortic rupture

- Widening of the superior mediastinum to  $\geq 8$  cm in a 100 cm anteroposterior supine radiograph
- Tracheal shift to the right
- Blurring of the aortic outline
- Obliteration of the medial aspect of the left upper lobe (pleural capping)
- Opacification of the angle between the aorta and left pulmonary artery
- Depression of the left main bronchus to an angle  $< 40^\circ$  with the trachea

A widened mediastinum with associated features suggests rupture of the aorta and the need for control of blood pressure and early aortography. A fractured sternum or thoracic spine also causes widening of the mediastinum, as may arterial or venous injuries at the root of the neck. A widened mediastinum together with extrapleural apical capping in both hemithoraces strongly suggests aortic transection. Widening of the cardiac silhouette or an abnormal globular appearance of the heart suggests an intrapericardial haematoma. In association with clinical signs of cardiac tamponade this may need urgent pericardiocentesis or preferably median sternotomy or thoracotomy if cardiac disruption is suspected.

A lacerated left hemidiaphragm can normally be recognised by identifying bowel gas within the left hemithorax, usually in association with haemothorax. An apparent raised right hemidiaphragm suggests right diaphragmatic rupture as paralysis of the phrenic nerve caused by trauma is extremely rare. The possibility of a subdiaphragmatic haematoma from a ruptured liver can be excluded by abdominal ultrasonography.

In the absence of clinical or radiological evidence of major intrathoracic injury requiring early surgery treatment should be concentrated on moderating the pathophysiological processes that result from chest wall disruption, pulmonary contusion, and intrathoracic bleeding.

## Resuscitation

### ABC principle of cardiopulmonary resuscitation for thoracic trauma

#### Establish a reliable Airway—

through an oropharyngeal airway; an endotracheal tube; a bronchoscope; tracheostomy

#### Restore the mechanics of Breathing—

by artificial respiration; evacuation of haempneumothorax; stabilisation of unstable chest wall; mechanical ventilation

#### Resuscitate the Cardiovascular system—

by intravenous infusion of crystalloid, colloid, or blood; restoring acid-base states and electrolyte concentrations; inotropic support; external or internal cardiac massage; immediate surgery to stem haemorrhage

Appropriate intervention in patients requiring resuscitation must be based on the immediately life threatening problem but usually follows the ABC of resuscitation principle, beginning with intubation and positive pressure ventilation if required. Securing a reliable airway may be particularly hazardous in patients who have sustained blunt or penetrating trauma to the root of the neck or upper chest. If laryngeal or tracheal disruption is suspected in a patient who is breathing spontaneously blind intubation may prove fatal and must give way to expert bronchoscopic negotiation of the airway. This is preferable to tracheostomy in advance of accurate definition of the nature of injury. With complete tracheal transection immediate collar incision with location of the distal trachea may be necessary.

Early correction of hypoxia and acidosis are of paramount importance, particularly in the presence of head injury or when urgent surgery for abdominal injuries must be undertaken. This can be done only on the basis of blood gas tensions and acid-base analyses. When hypoxia and acidosis are confirmed one or more of the following steps are necessary.

- Improve the mechanics of breathing by clearing major airways obstruction or draining a haempneumothorax. Alleviate pain from fractured ribs or undertake mechanical ventilation if the severity of chest wall disruption and pulmonary disruption so demands
- Improve oxygen transport by increasing the inspired oxygen content. Restrict the amount of clear fluid infused and restore the circulating oxygen carrying capacity by blood transfusion after profuse haemorrhage
- Improve the circulation and oxygen delivery by arresting haemorrhage, restoring circulating blood volume, relieving cardiac tamponade, and giving calcium or inotropes if necessary. Before restoring the systolic blood pressure to  $> 100$  mm Hg rule out potentially catastrophic cardiac or aortic laceration and potentially fatal secondary haemorrhage.

Accurate assessment and correction of acid-base balance, derangement of blood gas tensions, and the circulatory state require early insertion of central venous and radial arterial lines. Only then can improvement or deterioration in condition during the first hour of resuscitation be monitored sensibly and pharmacological intervention be assessed.

### Indications for early intervention in life threatening thoracic injuries

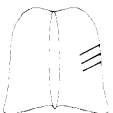
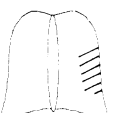
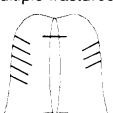
#### Common cause

#### Intervention

Cardiac or aortic laceration Bleeding from lung or chest wall	<i>Haemorrhage</i> Insert a chest drain to assess rate of bleeding; transfuse blood to maintain oxygen carrying capacity; measure venous pressure; perform immediate or early thoracotomy if necessary
Major airways injury or obstruction Disordered mechanics of breathing	<i>Profound hypoxia</i> Intubate and perform intermittent positive pressure ventilation; drain haempneumothorax; correct acid-base balance; operate to correct diaphragmatic rupture or damaged airway
Penetrating cardiac wound	<i>Cardiac tamponade</i> Perform immediate or early sternotomy or thoracotomy
Hypoxia and acidosis due to low cardiac output state, altered mechanics of breathing, ventilation/perfusion imbalance, or impaired gas transfer	<i>Cardiac arrest</i> Intubate and perform intermittent positive pressure ventilation; correct acid-base balance with bicarbonate; give internal or external cardiac massage; give calcium; defibrillate; give inotropic support as necessary

# Chest wall derangement

## Management of rib fractures

 <p>&lt; 5 Unilateral rib fractures</p> <p>Antipyretic oral or intravenous analgesia, physiotherapy Consider local intercostal nerve block or intrapleural bupivacaine</p> <p>Stable chest wall Normal blood gas tensions</p>	
 <p>Multiple unilateral rib fractures</p> <p>Thoracic epidural anaesthesia, physiotherapy, mini-tracheostomy to aspirate secretions Consider surgical chest wall fixation</p> <p>Stable or flail chest wall Poor blood gas tensions</p>	Transition depends on deterioration of blood gas tensions
 <p>Multiple fractures with deformity or bilateral fractures</p> <p>Ventilation, physiotherapy Consider surgical chest wall fixation and antibiotic prophylaxis</p> <p>Unstable chest wall Poor blood gas tensions</p>	

### Disadvantages of prolonged intermittent positive pressure ventilation

- The need for prolonged intubation with tracheostomy
- The need for prolonged sedation
- Inadequate nutrition
- Immobility with a risk of pressure sores
- Effective physiotherapy is difficult, and repeated passage of suction catheters traumatises the airway

## Chest drain insertion

### Indications for drainage of traumatic pneumothoraces

- If pneumothorax >1.5 cm (at level of third costochondral junction) whether intermittent positive pressure ventilation is required or not
- If pneumothorax <1.5 cm but intermittent positive pressure ventilation is required for surgery as there are bilateral pneumothoraces
- If pneumothorax <1.5 cm in patients with chronic obstructive airways disease, restrictive lung and chest wall disease, high spinal cord injury, or contralateral lung resection
- All tension pneumothoraces and haemothoraces

The two main types of serious chest wall derangement are a functionally important traumatic defect (sucking chest wound) and a flail segment. The most extensive disruption occurs in severe crush injuries in which multiple bilateral rib fractures and fractures of the sternum coexist. Each rib fracture is associated with a blood loss of about 150 ml. With multiple fractures blood loss may be substantial and is increased by laceration of the underlying lung by sharp edges. The damaged chest wall may be stable, so that with adequate pain relief breathing continues unhindered, or unstable, when the mechanics of breathing are compromised. The flail segment moves inwards on inspiration and consequently compromises ventilation by reducing tidal volume. Full expansion of the lung must be restored as soon as possible by covering a traumatic defect, stabilising a flail segment, and draining a haemopneumothorax. Further management is aimed not at the chest wall itself but at preserving respiratory function.

Pain causes decreased respiratory excursion and failure to ventilate the basal segments, resulting in atelectasis. Pain also inhibits cough so that secretions cannot be cleared from the bronchial tree, causing bronchial obstruction and acute respiratory failure. Pain relief is very important so that the most effective therapeutic option, physiotherapy, can be carried out frequently and with the patient's full cooperation.

Recent studies have shown decreased mortality in patients with extensive rib fractures with the conservative approach to pain relief compared with routine mechanical ventilation. This also applies to patients who have undergone surgery for concomitant abdominal or orthopaedic injuries, those with flail segments, and those with pulmonary or cardiac contusion as long as arterial  $PO_2$  is >50 mm Hg when 50% oxygen is being inspired and vital capacity is >10 ml/kg. Analgesia is planned to provide a central block at the dermatome area of pain up to the level of T4. Intubation and ventilation should be considered only if the arterial  $PO_2$  falls below 50 mm Hg with supplementary oxygen or if there is an increase in respiratory rate to 40 breaths/min with an inability to cough.

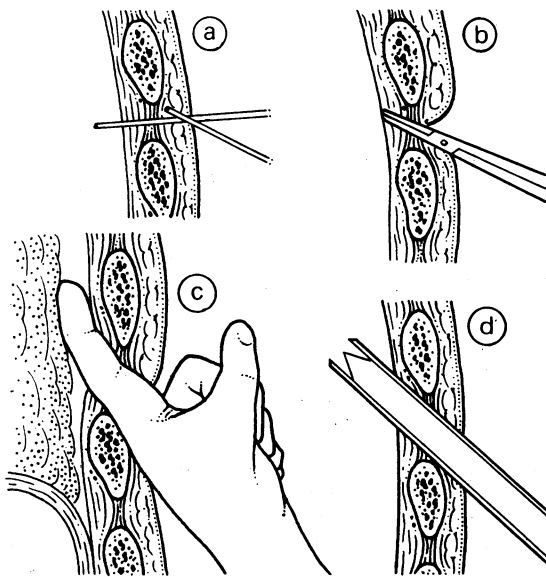
Mechanical ventilation is important in unconscious and uncooperative patients with severe or worsening respiratory failure despite adequate analgesia and clearance of secretions by physiotherapy. A flail segment in itself is not an indication for mechanical ventilation; the functional rather than the anatomical consequences of injury determine the necessity for ventilatory support. Surgical intervention is only rarely indicated for fixing sternal fractures, correcting serious deformities, and evacuating an extensive clotted haemothorax or haemostasis in a severely lacerated lung.

One, and occasionally more than one, chest drain should be inserted to clear blood or air from the pleural cavity. Except under dire circumstances with tension pneumothorax a plain chest radiograph should be taken first. Surgical emphysema in the chest wall in the absence of a pneumothorax is not an indication for chest drain insertion, and drains should never be inserted prophylactically as damage to the underlying lung in patients with an obliterated pleural cavity may prove fatal.

In practice, drains are usually inserted for combined haemopneumothoraces. There are several simple steps to follow.

- (1) Make certain that either blood or air is interposed between the chest wall and the lung. In about 15% of patients postpneumonic fibrous intrapleural adhesions obliterate the pleural space and result in the drain transfixing the lung
- (2) Choose the site carefully: it will usually be between the fourth and seventh intercostal spaces, between the midaxillary and anterior axillary lines. The level at which the anterior axillary fold meets the chest wall is a useful guide. Consult the chest radiograph unless the drain is to be inserted as an absolute emergency. There is no contraindication to inserting the drain through an area of injury, but if there is possibility of a ruptured diaphragm with viscera in the chest the drain should be inserted high.



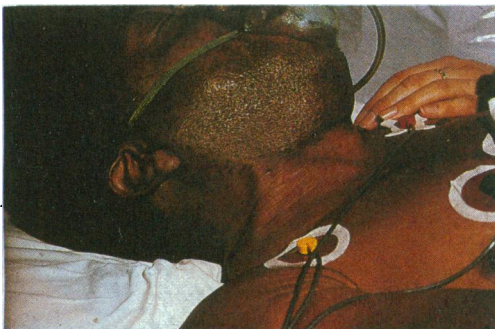

Chest drain insertion. (a) Penetration of the skin, muscle, and pleura. (b) Blunt dissection of the parietal pleura. (c) Exploration of the pleural cavities. (d) Tube directed posteriorly and superiorly.

#### Indications for elective thoracotomy

- Initial chest drain insertion yields >1250 ml of blood immediately or >1000 ml plus 250 ml in the first hour or if 250 ml is drained in three consecutive hours with no decreasing trend
- Cardiac tamponade, even if pericardiocentesis relieves symptoms
- Massive air leak when pneumothorax persists despite adequate drainage, suggesting major bronchial or tracheal injury. Bronchoscopy is performed to confirm the diagnosis and clear blood and secretions
- All transmediastinal wounds
- Chest wall defects and diaphragmatic lacerations
- Clotted haemothorax (to expand the underlying lung and prevent empyema or fibrothorax); consider after 48 to 72 hours' drainage. (Enzymatic clot lysis is seldom successful)
- Combined thoracic and abdominal wounds before laparotomy except where entry and exit wounds preclude heart or great vessel injury or when the source of major haemorrhage is abdominal

## Pericardiocentesis



Patient with a cardiac stab wound and tamponade. The neck veins are greatly distended despite blood loss.

The illustration of chest drain insertion was prepared by the department of education and medical illustration services at St Bartholomew's Hospital.

Mr Stephen Westaby, FRCS, is consultant cardiothoracic surgeon, John Radcliffe Hospital, Oxford, and Mr Nigel Brayley, FRCS, is registrar in accident and emergency medicine, Northampton General Hospital.

The ABC of Major Trauma has been edited by Mr David Skinner, FRCS; Mr Peter Driscoll, FRCS; and Mr Richard Earlam, FRCS.

Avoid the anterior approach in the second interspace as this transfixes the two major accessory respiratory muscles—the pectoralis major and minor. If an apical drain is required because of intrapleural adhesions towards the base then the true apical approach above the scapula and into the first interspace posteriorly is preferred. It is a fallacy that the drain must be in a basal position to drain blood and in an apical position to drain air.

(3) Choose a size 28 or 32 Argyle chest drain—smaller drains will rapidly occlude with blood clot. An established haemothorax will not drain and requires surgical evacuation.

(4) In conscious patients use between 10 and 15 ml of 1% lignocaine and infiltrate the periosteum on the upper border of the rib at the chosen interspace. Advancing the needle above the rib, the pleura should be infiltrated, and passage of the needle into the pleural cavity confirms the presence of free air or blood on aspiration. The needle can be left in situ so that the precise area of anaesthetic infiltration is not lost when the skin is cleansed with povidone-iodine solution.

(5) Use a scalpel to incise the chest wall about 2 cm beneath the proposed site of pleural incision, so that the drain track leads the drain to the apex of the pleural cavity. The scalpel should find the rib below the interspace to be breached, then the remainder of the track be completed through to the pleural cavity with artery forceps. This route avoids the intercostal nerve and, more importantly, the vessels that are protected underneath the ribs. The drain slides easily through the track and into the pleural cavity, when blood or air will flash-fill the tube. Do not be concerned about allowing air to enter along the drains; this will be evacuated immediately when the lung expands and there is underwater sealed drainage.

(6) When the drain is in position it is sutured with at least a zero gauge silk or propylene suture to prevent displacement. A pursestring suture is applied around the site.

(7) Always apply negative pressure to chest drains to ensure evacuation of continued haemorrhage or air leak. Never clamp the drain in the presence of a brisk air leak. A Thompson or Tubbs-Barrett suction machine is necessary to ensure large volume suction at a negative pressure of 15–20 cm H<sub>2</sub>O. The Roberts suction pump should not be used as it will take only a small volume and may constitute an obstruction in the case of rapid air leak.

(8) Check the position and effect of the drain in a plain chest radiograph. Note the initial volume of blood evacuated and the continued rate of drainage on suction. Assess the volume of air leak. The need for thoracotomy is determined by the rate of bleeding or air leak through the drain during suction. In most patients the intercostal drain is the definitive intervention.

Pericardiocentesis is of little therapeutic value and has caused death through cardiac laceration. In cardiac tamponade there is a fine balance between internal and external cardiac pressures that prevents exsanguination. The blood within the pericardium is usually clotted and cannot be aspirated. If the patient is moribund immediate thoracotomy is more important than attempted pericardial aspiration. Such aspiration may sometimes be undertaken on diagnostic grounds when two dimensional echocardiography is not immediately available. A transdiaphragmatic approach is undertaken by inserting a wide bore needle of at least 15 cm length from a site between the xiphisternum and left costal margin, aiming the tip of the needle cautiously towards the base of the pericardium along the line of the left sternal margin. The syringe is carefully aspirated during the course of inserting the needle until either altered blood rapidly fills it or the myocardium can be felt on the tip of the needle. Serious laceration of the right or left ventricles is unusual, though damage to the posterior descending branch of the right coronary artery is possible. To increase appreciably the stroke volume in cardiac tamponade at least 100 ml of blood should be aspirated. This may cause further fatal haemorrhage by raising the intracardiac pressure and disrupting the tamponade effect. Cardiac disruption caused by either blunt or penetrating trauma requires urgent surgical repair.