Cancer Imaging (2005) **5,** S102–S106
DOI: 10.1102/1470-7330.2005.0037

MULTIDISCIPLINARY SYMPOSIUM: HAEMATOLOGICAL MALIGNANCIES

Wednesday 5 October 2005, 08:30–10:00

Quantitative CT analysis for assessing response in lymphoma (Cheson's criteria)

Alain Rahmouni*, Alain Luciani* and Emmanuel Itti†

*Departments of *Radiology and †Nuclear Medicine, Centre Hospitalo-Universitaire Henri Mondor, 51 Avenue du Marechal de Lattre de Tassigny, 94010 Créteil, France*

Corresponding address: Alain Rahmouni, MD, Imagerie Medicale, CHU Henri Mondor, 51, avenue du Maréchal de Lattre de Tassigny, 94010 Créteil cedex, France. E-mail: alain.rahmouni@hmn.aphp.fr

Abstract

Standardized CT-based criteria used for lymphoma staging and follow-up and the current role of FDG-PET are reviewed. The current CT-based International Workshop Criteria (IWC) still have the main advantage of representing standardized criteria allowing comparability of clinical trials in patients with lymphoma. However, functional imaging with integrated IWC and FDG-PET provide more accurate response assessment, and challenge the current paradigm. Although integration of FDG-PET in IWC requires validation in a prospective trial with a large number of patients, new long-term clinical and therapeutic trials probably need to be designed using these new and hopefully standardized functional criteria. This potentially could allow a more risk-adapted approach to the treatment of aggressive lymphoma: intensive (reinforced) therapies for non-responders vs. less intensive therapies for good responders with the main goal of improved clinical outcome.

Keywords: *Lymphoma; CT analysis; Cheson's criteria.*

Introduction

Since 1999, the International Workshop Criteria (IWC) have been widely accepted for response assessment in patients with non-Hodgkin's lymphoma (NHL). IWC also ensure comparability among clinical trials[1]. Multi-agent chemotherapy regimen have transformed aggressive lymphoma from a fatal disease to a potentially curable one, but no more than half of all patients are cured[2]. More aggressive, but also potentially more toxic treatments are now available. At diagnosis, the therapeutic regimen will be chosen in part according to the International Prognostic Index, a well established predictor of outcome, including the performance status according to the Eastern Cooperative Oncology Group scale, the patient's age, serum lactate dehydrogenase level, Ann Arbor stage (Table 1) (reflecting the anatomic extent and the tumoral mass primarily obtained by CT and bone marrow biopsy), and finally the number of extranodal sites[3]. In order to assess response to treatment, the IWC are primarily based on computed tomography (CT) although bone marrow biopsy (BMB) and clinical and biochemical information are also taken into account; IWC should also discriminate rapid responders to standard induction likely to show better and more durable response, from non-responders who could benefit from an early change of therapeutic orientation[4]. The inability of CT to differentiate between viable tumour, necrosis, or fibrosis in residual mass(es) in patients with otherwise complete clinical response has led to only CT-based size changes after treatment being considered to assign a response designation in the IWC[1]. Functional imaging, particularly using fluorodeoxyglucose positron emission tomography (FDG-PET) has been shown to provide additional metabolic information such as tumour viability in residual masses[5]. Gallium citrate and magnetic resonance (MR) imaging have also been used for this purpose in patients with lymphoma[6–8].

© 2005 International Cancer Imaging Society

Table 1 Ann Arbor staging classification of thoracic lymphoma

Stage	Area of involvement
I	A single lymph node region or a single localised involvement of an extralymphatic site
II	Two or more lymph node regions on the same side of the diaphragm
III	Lymph node regions on both sides of the diaphragm
IV	Diffuse involvement of one or more extranodal organs with or without lymph node involvement
Additional qualifiers	
A	Absence of systemic symptoms
B	Presence of systemic symptoms
S	Involvement of spleen
E	Localised extralymphatic site involvement
H	Involvement of liver
M	Diffuse involvement of bone marrow

International Workshop Criteria (IWC)

The standardized criteria for response assessment, proposed by Cheson and colleagues, include five designations[1,9]:

(1) Complete response (CR) is the complete disappearance of all detectable evidence of disease on CT, and all disease-related symptoms, and normalization of biochemical abnormalities, and normal bone marrow biopsy (BMB). Previously involved nodes on CT more than 1.5 cm in their greatest axial diameter must regress to less than 1.5 cm, and previously measured nodes of 1.1–1.5 cm must decrease to less than 1 cm.

(2) CRu (uncertain) corresponds to CR criteria but with a residual mass more than 1.5 cm in greatest axial diameter that has regressed by more than 75%.

(3) Partial response (PR) is at least 50% reduction in the sum of the product of the greatest diameters (SPD) of the six largest nodes with no increase in the size of other nodes and no new sites of disease. Splenic and hepatic nodules must regress by at least 50% in the SPD. BMB is irrelevant for determination of PR.

(4) Stable disease (SD) is less than a PR but is not progressive disease. Progressive disease (PD) is more than 50% increase in the sum of the product of the greatest diameters of any previously abnormal node, or appearance of any new lesions during or at the end of therapy.

(5) Relapsed disease (RD) is the appearance of any new lesion or increase in size of more than 50% of previously involved sites or nodes in patients who achieved CR or CRu.

Main limitations of CT-based IWC

At staging, assessment of nodal involvement by CT is limited by its low specificity in the case of small nodes, especially less than 1.5 cm in diameter[9]. Spleen involvement by CT is based on an enlarged spleen and/or hypodense nodules. However, spleen size can vary with age and other associated diseases. Detection of spleen nodules will depend upon CT technical parameters including contrast injection rate and timing. When isolated, a spleen nodule can be difficult to characterize by CT alone. In young patients, when upper range measurements of the normal thymus according to age are obtained, involvement by lymphoma can be difficult to assess with certainty.

Extranodal sites of involvement can be difficult to detect by CT. Bone marrow involvement is usually not identified unless a lytic bone lesion is present. CT appearance of a small pulmonary nodule can be non-specific. Subtle changes in gastrointestinal wall thickness can be difficult to assess on CT[10,11].

At CT follow-up of nodal masses, a residual mass is present in approximately 40% of NHL patients treated by chemotherapy and/or radiation. This led to the concept of ‘complete remission uncertain’ (CRu) which reflects the unknown significance of persistent CT abnormalities in patients who otherwise seem to be in CR. Previous studies showing that only 10%–20% of such patients have evidence of disease in these residual masses, considerably limits the value of CT for prediction of clinical outcome of NHL[11–13]. Due to its good spatial resolution, CT is also able to detect nodes less than 1 cm but these nodes are considered normal although residual disease cannot theoretically be ruled out.

In the case of extranodal involvement, residual masses can also be seen in cases of gastrointestinal involvement; size changes of wall thickness are also difficult to estimate[11]. In the case of a lytic bone involvement, bone remodelling is usually delayed with no ad integrum recovery. Pulmonary involvement can be difficult to assess during treatment due to drug-related and/or infectious complications.

Although IWC have been useful to standardize response to treatment, functional imaging has been shown to improve detection of sites of involvement, and to provide metabolic tissue characterization[14].

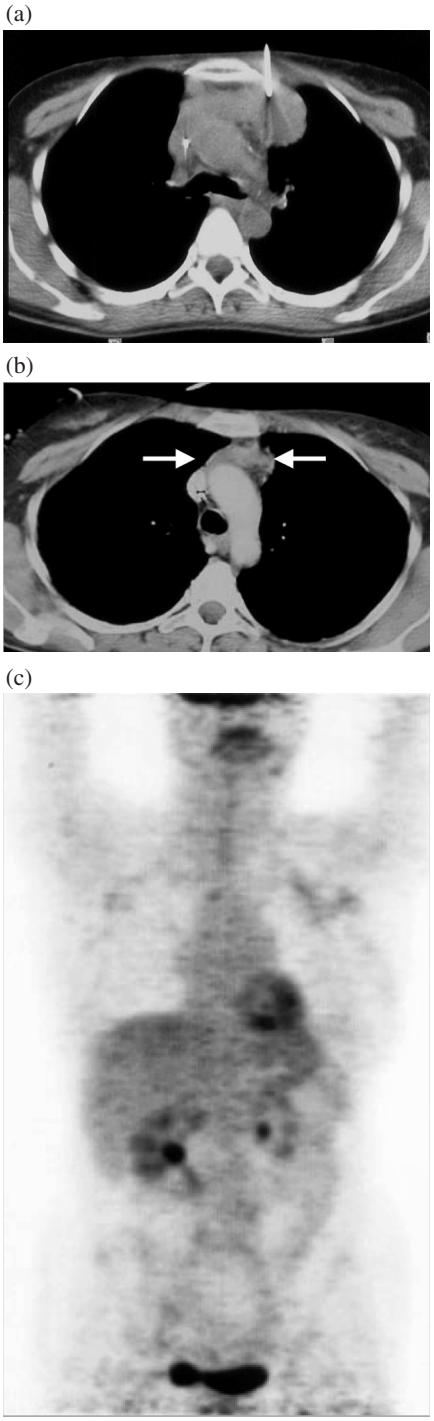

Figure 1 **A 32-year-old woman with aggressive non-Hodgkin's lymphoma. (a) Unenhanced CT scan of the thorax performed during percutaneous biopsy showing a 7 × 4 cm large anterior mediastinal mass. (b) Based on sole CT follow-up findings, the patient was classified as complete response (uncertain) (CRu) according to IWC after 3 months of treatment with a 3 × 2 cm large residual mass consistent with ≥75% decrease in size (arrows). (c) FDG-PET performed 3 days after CT did not show any significant residual uptake within the mass allowing the reclassification of the response to treatment as complete response (CR).**

The emergence of fluoro-2-deoxy-D-glucose positron emission tomography (FDG-PET) in the clinical armamentarium and its increasing availability have recently provided an alternative to gallium-citrate scan and MR imaging, which were previously employed to detect active disease.

Integrated IWC and FDG-PET

Compared to CT staging, Moog *et al.* have reported more accurate staging by FDG-PET in NHL[15]; 8% of patients were up-staged at diagnosis because of the identification of additional disease sites. After treatment, several studies have demonstrated that persistence of an increased glycolytic activity on FDG-PET was associated with a high relapse rate, while the latter was low in the case of a negative scan[5,16]. Only one recent report has shown that a response classification based on integration of FDG-PET results into IWC should provide a more accurate response assessment than IWC alone in patients with lymphoma. In a retrospective study of 54 patients with aggressive NHL, Juweid *et al.* showed that only 61% had concordant response designations between integrated IWC including FDG-PET results vs. IWC alone[9]. The most pronounced discordance was observed in the CRu by IWC designation, in which all CRu patients were reclassified as CR in case of no FDG uptake or PR in case of FDG uptake. All patients reclassified as CR remained progression free at a median of more than 32 months. An example of a residual mass detected by CT but with no FDG uptake on PET is shown in Fig. 1. The other major discordance was found in the PR by IWC designation in which half the patients were reclassified as CR by integrated IWC and FDG-PET. All but one of these reclassified CR patients remained without evidence of disease progression at a median of more than 32 months. In contrast, only two of nine patients with concordant PR designation by IWC and integrated FDG-PET, and IWC alone were progression free at follow-up. Based on the Kaplan–Meier method, this study demonstrated that integrated IWC and FDG-PET was a statistically significant independent predictor for progression-free survival.

Using FDG-PET results at follow-up will substantially increase the proportion of CR designation by IWC, and probably cancel the CRu designation. It will also show two distinct subgroups within the PR by IWC: a subgroup of PET-positive patients with poor outcome and another of PET-negative patients with excellent outcome. The biological explanation is likely related to the fact that the residual CT abnormalities represent necrosis and/or fibrosis in the majority of the PET-negative patients, whereas the abnormalities represent active tumour in the majority of the PET-positive patients.

One must, however, take into account that owing to its high spatial resolution, CT can identify extranodal

involvement sometimes not apparent on PET, thus triggering the need for combined PET/CT, and for combined radiological and nuclear medicine workout of image interpretation, as illustrated by Fig. 2.

(a)

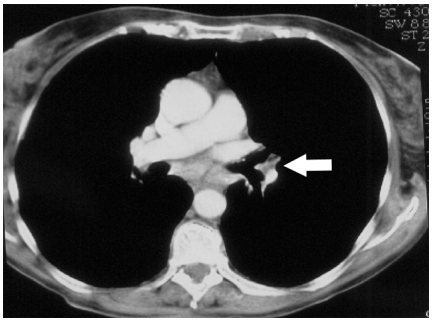

(b)

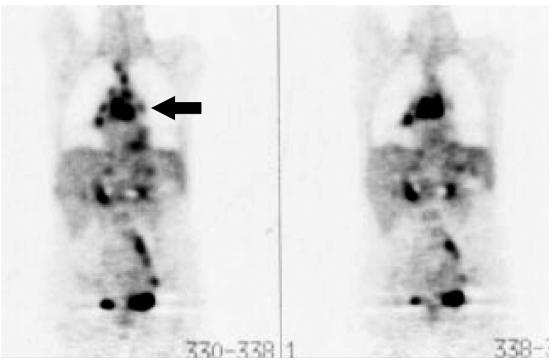

(c)

Figure 2 **A 25-year-old male patient with aggressive non-Hodgkin's lymphoma. (a) Enhanced CT scan of the thorax showed a small 1 cm large left hilar node (arrow), and multiple subcareneal enlarged lymph nodes. (b) FDG-PET showed increased uptake of all nodes detected by CT including the centimetric hilar node (arrow). However, FDG-PET failed to identify multiple disseminated lung nodules consistent with pulmonary involvement as confirmed by the disappearance of these CT findings after completion of the first line of treatment.**

Conclusion

Current CT-based IWC still has the main advantage of representing standardized criteria allowing comparability of clinical trials in patients with lymphoma. However, functional imaging with integrated IWC and FDG-PET provide more accurate response assessment, and challenge the current paradigm. As FDG-PET combined with visual correlation with a contrast-enhanced CT accurately predicts progression-free survival, fused FDG-PET and CT images acquired during the same examination will yield similar or superior results. Although integration of FDG-PET in IWC requires validation in a prospective trial with a large number of patients, new long-term clinical and therapeutic trials probably need to be designed using these new and hopefully standardized functional criteria. This potentially could allow a more risk-adapted approach to treatment of aggressive lymphoma: intensive (reinforced) therapies for non-responders vs. less intensive therapies for good responders with the main goal of improved clinical outcome.

References

[1] Cheson BD, Horning SJ, Coiffier B *et al*. Report of an international workshop to standardize response criteria for non-Hodgkin's lymphomas. NCI Sponsored International Working Group. J Clin Oncol 1999; 17: 1244.

[2] Vose JM. Current approaches to the management of non-Hodgkin's lymphoma. Semin Oncol 1998; 25: 483–91.

[3] Shipp M, Harrington D, Anderson J *et al*. A predictive model for aggressive non-Hodgkin's lymphoma. The International Non-Hodgkin's Lymphoma Prognostic Factors Project. N Engl J Med 1993; 329: 987–94.

[4] Haioun C, Itti E, Rahmouni A *et al*. [^{18}F]Fluoro-2-deoxy-D-glucose positron emission tomography (FDG-PET) in aggressive lymphoma: an early prognostic tool for predicting patient outcome. Blood 2005; prepublished online April 28, 2005 (DOI 10.1182/blood-2005-01-0272).

[5] Jerusalem G, Beguin Y, Fassotte MF *et al*. Whole-body positron emission tomography using 18F-fluorodeoxyglucose for posttreatment evaluation in Hodgkin's disease and non-Hodgkin's lymphoma has higher diagnostic and prognostic value than classical computed tomography scan imaging. Blood 1999; 94: 429–33.

[6] Israel O, Mor M, Epelbaum R *et al*. Clinical pretreatment risk factors and Ga-67 scintigraphy early during treatment for prediction of outcome of patients with aggressive non-Hodgkin lymphoma. Cancer 2002; 94: 873–8.

[7] Rahmouni A, Divine M, Lepage E *et al*. Mediastinal lymphoma: quantitative changes in gadolinium enhancement at MR imaging after treatment. Radiology 2001; 219: 621–8.

[8] Janicek M, Kaplan W, Neuberg D, Canellos GP, Shulman LN, Shipp MA. Early restaging gallium scans predict outcome in poor-prognosis patients with aggressive non-Hodgkin's lymphoma treated with high-dose CHOP chemotherapy. J Clin Oncol 1997; 15: 1631–7.

[9] Juweid ME, Wiseman GA, Vose JM *et al*. Response assessment of aggressive non-Hodgkin's lymphoma by integrated International Workshop Criteria and fluorine-18-fluorodeoxyglucose positron emission tomography. J Clin Oncol 2005; 23: 4652–61.

[10] Kumar R, Xiu Y, Potenta S *et al*. 18F-FDG PET for evaluation of the treatment response in patients with gastrointestinal tract lymphomas. J Nucl Med 2004; 45: 1796–1803.
[11] Surbone A, Longo DL, DeVita Jr VT *et al*. Residual abdominal masses in aggressive non-Hodgkin's lymphoma after combination chemotherapy: significance and management. J Clin Oncol 1988; 6: 1832–7.
[12] Fuks JZ, Aisner J, Wiernik PH. Restaging laparotomy in the management of the non-Hodgkin lymphomas. Med Pediatr Oncol 1982; 10: 429–38.
[13] Coiffier B, Lepage E. Prognosis of aggressive lymphomas: a study of five prognostic models with patients included in the LNH-84 regimen. Blood 1989; 74: 558–64.
[14] Juweid ME, Cheson BD. Role of positron emission tomography in lymphoma. J Clin Oncol 2005; 23: 4577–80.
[15] Moog F, Bangerter M, Diederichs CG *et al*. Extranodal malignant lymphoma: detection with FDG PET versus CT. Radiology 1998; 206: 475–81.
[16] Mikhaeel NG, Timothy AR, O'Doherty MJ, Hain S, Maisey MN. 18-FDG-PET as a prognostic indicator in the treatment of aggressive non-Hodgkin's lymphoma—comparison with CT. Leuk Lymphoma 2000; 39: 543–53.

Cancer Imaging (2005) **5,** S106–S112 DOI: 10.1102/1470-7330.2005.0038

MRI and PET in monitoring response in lymphoma

Alain Rahmouni*, Alain Luciani* and Emmanuel Itti†

*Departments of *Radiology and †Nuclear Medicine, Centre Hospitalo-Universitaire Henri Mondor, 51 Avenue du Marechal de Lattre de Tassigny, 94010 Créteil, France*

Corresponding address: Alain Rahmouni, MD, Imagerie Medicale, CHU Henri Mondor, 51, avenue du Maréchal de Lattre de Tassigny, 94010 Créteil cedex, France. E-mail: alain.rahmouni@hmn.aphp.fr

Abstract

The potential of FDG-PET and MRI in monitoring response to treatment in lymphoma is reviewed. Both FDG-PET and MRI can provide whole body imaging. Both also share the advantage of combining functional and anatomical information. At present, hybrid FDG-PET and MDCT is the best technique for monitoring response to treatment, especially early response to treatment. Early assessment of response to treatment has the potential to tailor therapy. MR imaging is useful especially in assessing bone marrow and central nervous system involvement.

Keywords: *MRI; FDG-PET; monitoring response; lymphoma.*

Introduction

So-called 'functional imaging' has been used in the evaluation of lymphoma to supplement the information obtained from computed tomography (CT). The main limitations of CT-based International Workshop Criteria (ICW) are: (1) the limited accuracy of CT at initial staging for assessing lymphoma in small nodes (<1 to 1.5 cm), bone marrow, or various extranodal sites; (2) the inability of CT to differentiate active disease within a residual mass; and (3) the limited ability of CT to assess early response to treatment although more aggressive, but also potentially more toxic treatments are now available[1]. CT, however, remains the method of choice for initial measurements of involved sites and detection of complications such as adjacent organ compression. During follow-up, CT monitors size changes, and is useful for diagnosing treatment complications. Moreover, CT can also be seen as a potential 'functional' imaging. Dugdale *et al.* showed that perfusion values measured at CT decrease when lymphoma masses become inactive (Fig. 1)[2]. To date, however, no study has confirmed these preliminary data. Other functional imaging tools are used for the evaluation of residual masses. Gallium imaging is not an accurate technique for detecting sites of involvement at diagnosis, with frequent false-negative results compared to CT, and also false-positive para-hilar uptake[3]. However, when an initial nodal site is gallium avid at diagnosis, follow-up gallium scans assess tumour activity during treatment. Janicek *et al.* demonstrated that early restaging gallium scans delineate patients who are likely to have prolonged disease-free survival from those who fail to respond to intensive therapy[4]. Patients whose tumours remain Ga-positive midway through chemotherapy have a poor outcome[4]. However, gallium imaging is a complex

technique with several disadvantages when compared to [^{18}F]fluorodeoxyglucose positron emission tomography (FDG-PET) including: lower contrast and resolution, the need to perform acquisition 48 h after gallium citrate injection, higher dosimetry, and longer scanning time. Furthermore, gallium binds to plasma transferrin after which it binds to receptors on the surface of lymphoma cells leading to potentially false negative results. FDG uptake reflects a general metabolic process common to most malignant tissues with therefore probably less false negative results. The objective of this paper is to review the potential of FDG-PET and magnetic resonance imaging (MRI) in monitoring response to treatment in lymphoma.

FDG-PET

Briefly, FDG is transported into viable cells by glucose transporter molecules, where it is phosphorylated by hexokinase into FDG-6-phosphate, just as glucose is normally phosphorylated into glucose-6-phosphate. Unlike glucose-6-phosphate, however, FDG-6-phosphate undergoes no further metabolism within the cell. Moreover, its dephosphorylation by glucose-6-phosphatase is a relatively slow process in comparison to that of glucose-6-phosphatase. This, combined with the fact that FDG-6-phosphate cannot easily cross the cell membrane, results in entrapment of FDG-6-phosphate within viable cells. Malignant cells have an increased rate of aerobic glycolysis, compared to normal tissue. They also have a greater number of glucose transport molecules at the cell surface and a lower level of glucose-6-phosphatase.

Fluorine-18 is a positron emitter. The emitted positron penetrates only a few millimetres into tissues before combining with an electron. The particle pair then annihilates and its mass is entirely converted into energy. This energy takes the form of two 511 keV annihilation photons, emitted at approximately 180° from each other. Detection of both photons is termed coincidence detection, and this is the principle by which PET operates. Fluorine-18 has a half-life of 110 min, allowing acquisition of images over 30–120 min.

The biodistribution of FDG can be affected by various physiologic factors[5]. Blood glucose levels have an impact on FDG uptake through (a) competitive displacement of FDG by plasma glucose, and (b) patients being asked to fast for 6 h prior to imaging. Good control of blood glucose is essential; a level of less than 150 mg/dl is desirable. Because the primary route of FDG excretion is renal, good hydration is required. Muscle relaxants may be used to reduce muscle uptake. Patients are asked to remain silent after injection. The usual dose of FDG is 10–15 mCi. To our knowledge, there is no contra-indication for FDG administration. PET imaging is initiated approximately 60 min following the injection of FDG.

Hybrid FDG-PET/CT

Hybrid PET/CT scanners combine a PET and a CT machine housed back-to-back. This enables image acquisition in the same position with PET and CT, thus enabling the precise combination of the anatomic information provided by CT and the functional data provided by FDG-PET. Although most centres acquire unenhanced CT images, other centres perform single phase enhanced CT with orally administered water-soluble iodinated contrast media[6]. This could allow optimal CT images as multidetector CT (MDCT) is now standard in new hybrid PET/CT devices.

Monitoring response to treatment with FDG-PET

Staging of lymphoma

The accuracy of FDG-PET as an imaging tool for primary staging of lymphoma suffers from the absence of a systematic pathological correlation (Fig. 2). In our experience, PET alone is concordant with conventional imaging and bone marrow biopsy (BMB) in only 80% of cases[7], better than conventional imaging and BMB in 8% and worse in 12%. Among these latter cases, one-third account for bone marrow involvement undetected by PET. Other studies have reported similar results[8]. Moog *et al.* showed that FDG-PET was more accurate for detecting nodal lymphoma than CT[8]. Seven lymph node regions unremarkable on conventional CT showed increased uptake of FDG. Staging was changed in the 4/60 patients with these seven confirmed additional PET findings: from stage I to II in one patient, and from stage II to III in three patients. The clinically relevant question of how PET impacts on the staging of lymphoma and above all, whether or not up- or down-staging leads to changes in therapeutic strategies, has been addressed in some studies with variable results. For Shöder *et al.* PET-FDG could contribute to changes in clinical stage in 44% and changes in treatment in more than 60% of cases[9].

FDG-PET: significance of positive findings

Several limitations of FDG-PET have been reported: physiologic muscles may take up the radiotracer and show increased activity on the PET images (Fig. 2)[6]; This muscle uptake is easily identified when compared to CT images. Similarly, physiologic uptake by the kidneys, bowel and liver can be distinguished on combined CT images. Physiologic FDG uptake has also been reported in brown fat[10]. Other false-positive findings of FDG-PET, more difficult to recognize, include inflammatory changes caused by infectious or inflammatory processes such as viral infections, bronchitis, aspergilloma, sarcoidosis, etc.[10,11]

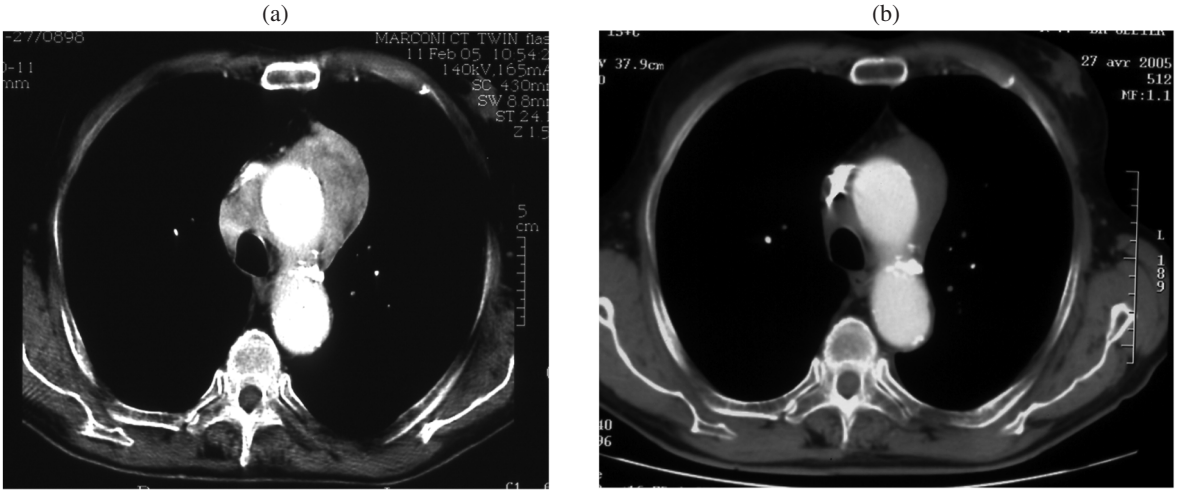

Figure 1 **A 78-year-old patient with mediastinal NHL. (a) Enhanced baseline CT scan showed an enhancing 7 × 4 cm large mediastinal mass. (b) After three cycles of chemotherapy, enhanced CT scan of the mediastinum demonstrated partial response, but with decreased enhancement of the residual mass. After completion of treatment, the patient was considered in complete response (uncertain).**

Response to treatment

PET is able to distinguish between active tumour and inactive residual masses often present following treatment (Fig. 3)[12–14]. This use is probably the most important especially in aggressive NHL and Hodgkin's lymphoma. False-positive findings at the site of residual masses may be seen, however, due to rebound thymic hyperplasia or post-therapy inflammatory changes especially following radiotherapy as well as infectious or inflammatory processes outside the site of residual masses[14]. The diffusely increased bone marrow uptake often observed during treatment and related to the administration of growth factor is usually linked to bone marrow hyperplasia and should not be misinterpreted as specific involvement (Fig. 3). FDG-PET results after treatment can predict therapy outcomes[15]. However, a negative PET scan cannot rule out the presence of minimal residual disease[5].

Early response to first-line treatment

The clinical parameters incorporated in the International Prognostic Index (IPI) grossly reflect the biological heterogeneity of lymphoma. In this respect, the duration of a complete remission might be significantly more influenced by the chemosensitivity than by the initial IPI factors[7]. Consequently, an early evaluation during treatment leading to an alternative treatment might improve outcome. Several studies have established that interim FDG-PET scans after 1–3 cycles of chemotherapy provide valuable information regarding early assessment of response and survival. Conventional chemotherapy can induce a rapid decrease of FDG uptake as soon as 7 days after treatment[16]. Spaepen *et al.* have shown the important prognostic value of mid-treatment FDG-PET in monitoring 70 cases of aggressive NHL[17]. Thirty-three patients showed persistence of abnormal FDG uptake and none of them achieved a durable complete remission, whereas 37 showed a negative scan. Out of the 37 patients, 31 remained in compete remission. More recently, we have confirmed the early (after two cycles) prognostic impact of FDG-PET in terms of response and survival[16]. At mid-induction, 'early PET' was considered negative in 54 patients and positive in 36. The outcome differed significantly between PET-negative and PET-positive groups; the predictive value of 'early PET' was observed in both the lower-risk and higher-risk groups, indicating prognostic independence from IPI. Therefore, FDG-PET should guide first-line strategies in lymphoma. The role of PET scanning for post-therapy surveillance without clinical or biochemical or CT evidence of disease (complete remission status) remains controversial primarily because of the potential for a disproportionate fraction of false-positive findings potentially resulting in increased cost without proven benefit from early PET detection of disease compared with standard conventional methods[18]. Large prospective studies are therefore needed to determine whether routine surveillance by PET results in meaningful changes in patient management[14].

MRI

T2 signal

The signal intensity of lymphoma at MR imaging changes during the course of the disease[19]. Active untreated

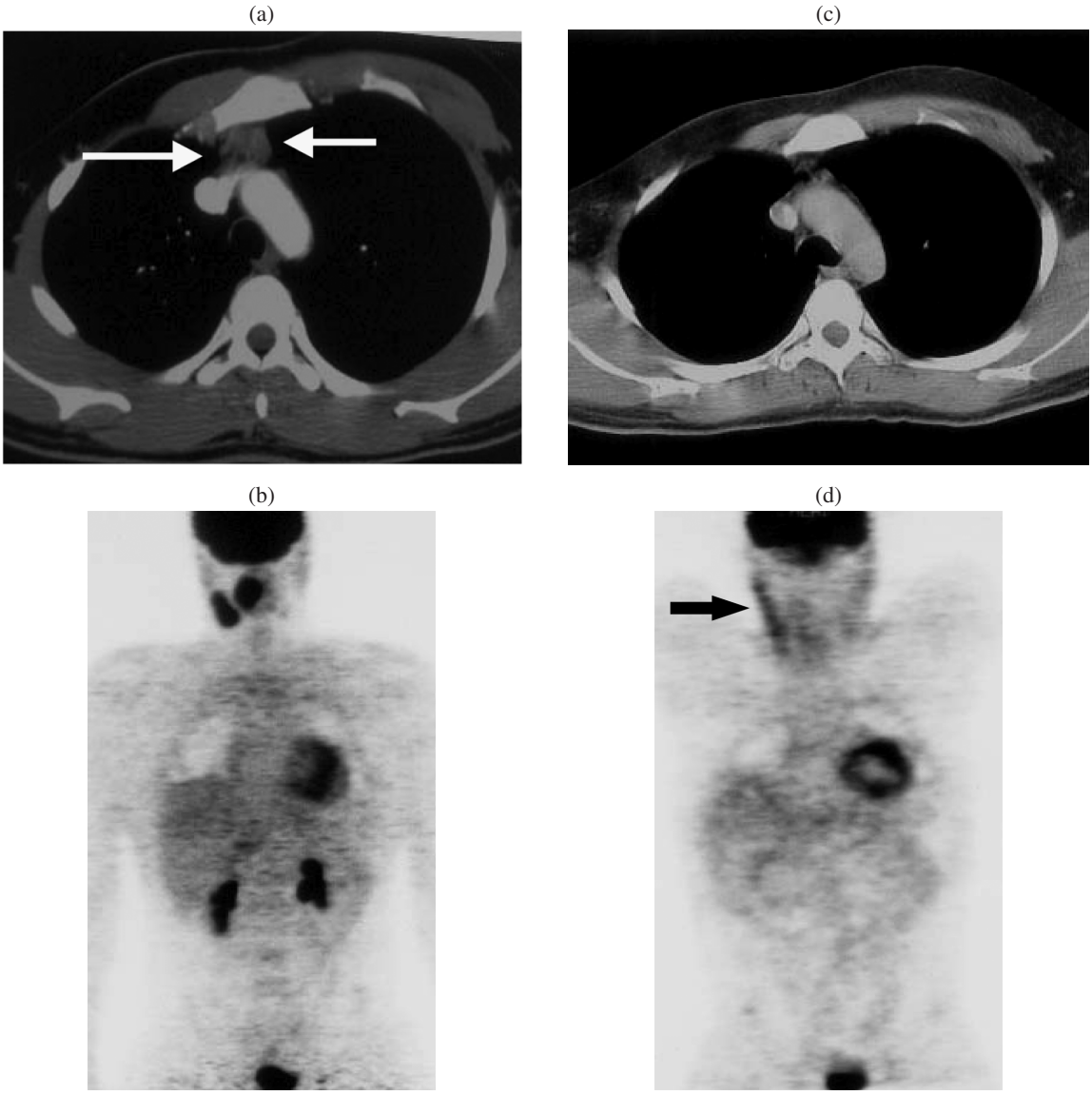

Figure 2 **A 41-year-old patient presenting with cervical enlarged lymph nodes with NHL involvement. (a) CT scan of the upper mediastinum showed an anterior mediastinal mass (arrows), without FDG uptake on PET. (b) This mass could correspond to an enlarged thymus. (c) Post-treatment CT scan performed 3 months later showed that the anterior mass was no longer present. (d) FDG-PET was normal; the linear cervical uptake (arrow) corresponded to physiologic muscle uptake. This case demonstrates the potential discordances between CT and FDG-PET due to the absence of pathological examination of the anterior mediastinal mass.**

tumour tissue contains an excess of free water which increases the signal intensity on T2 WI. With successful treatment, cellular elements and the water content of the tumour are reduced while the collagen and fibrotic stroma of the original tumour account for the main component of the signal[20]. These factors reduce the signal intensity of the residual mass on T2 WI and have been used for predicting relapse in a residual mass. However, the sensitivity of MR imaging in the prediction of relapse in a residual mass ranges from 45% to 90%, with a specificity ranging from 80% to 90%[21,22]. Low sensitivity is mainly due to necrosis, immature fibrotic tissue, oedema and inflammation that can simulate the high T2 SI of a viable tumour.

Gadolinium injection

Gadolinum (Gd) enhancement of lymphoma of the mediastinum changes during the course of the disease. The mean Gd enhancement of residual masses after treatment is substantially weaker than that observed

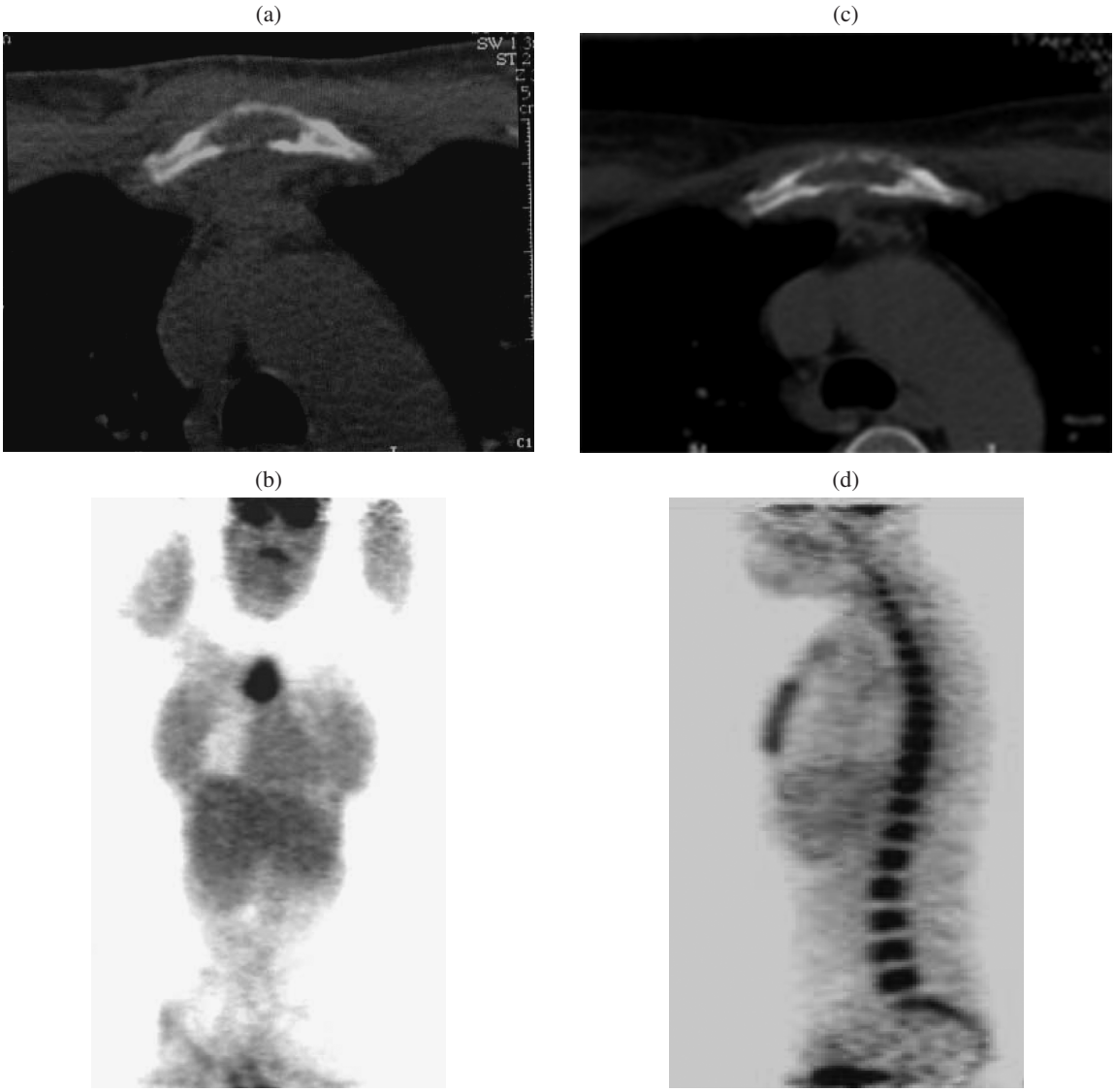

Figure 3 **A 25-year-old patient with NHL presenting with a soft tissue sternal mass associated with lytic sternal bone on CT (a) and increased isolated uptake on FDG-PET (b) concordant with CT findings. (c) After treatment, CT showed decrease of the soft tissue mass, but the lytic lesion of the sternum remained unchanged. The designation of response to treatment was difficult on CT. (d) FDG-PET showed no residual uptake in the previously involved sternum, but diffuse uptake of the whole bone marrow consistent with marrow regeneration due to growth factor treatment.**

before treatment in patients in complete remission. Enhancement of these inactive residual masses decreases markedly to the same level as that of muscle[23]. This may be explained by a higher degree of vascularization and a larger extracellular compartment in the active cellular tumour compared with dense immature fibrotic tissue. Due to different enhancement of lymphomatous masses at diagnosis, MR evaluation of residual masses requires a pre-treatment baseline MR study for comparison. Further studies with more recent MR techniques of perfusion analysis are required for comparison with FDG-PET. MR imaging suffers from limited field of view analysis compared to MDCT and PET. Furthermore, various impairments such as motion artefacts alter the overall image analysis especially in the mediastinum.

Potential of MRI

Preliminary studies have suggested a potential role of diffusion MR imaging in oncologic patients by allowing the detection of water motion over small distances[24]. The development of body MR using multi-channel phased array surface coils combined with parallel imaging techniques could enable whole body MR diffusion imaging in cancer patients. No study has yet

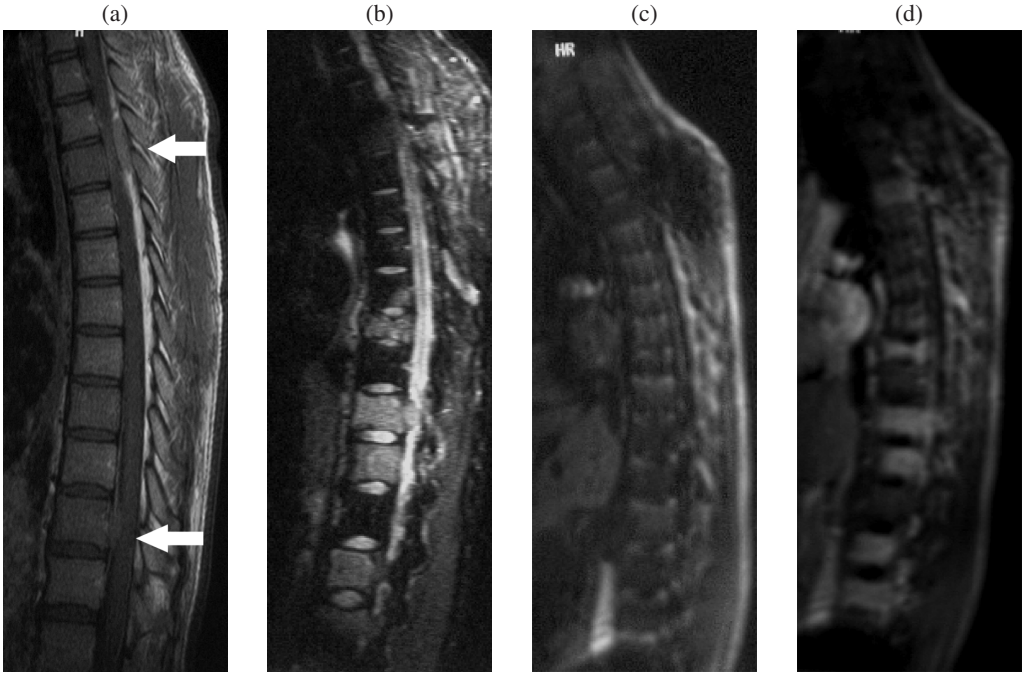

Figure 4 **A 28-year-old patient with NHL with spine and epidural involvement. (a) T1 WI showed two epidural masses (arrows). The bone marrow signal is consistent with the young age of the patient or with diffuse involvement. (b) Fat suppressed T2 WI demonstrated multiple focal bone marrow lesions. (c) T1 GE WI before injection and (d) 35 s after Gd-chelates injection showed early enhancement of focal lesions without enhancement of the remaining marrow. Bone marrow biopsy in the iliac crest was normal.**

been published assessing the impact of such techniques in staging and monitoring lymphoma.

New contrast agents taken up by the reticulo-endothelial system are now available, such as super-paramagnetic iron oxides (USPIO). USPIO are taken up by normal and hypercellular bone marrow, but not by neoplastic lesions, thereby providing significantly different enhancement patterns on T2-weighted MR images[25]. USPIO could therefore help in differentiating normal from lymphomatous bone marrow.

MRI in bone marrow involvement

In patients with lymphoma, MR identification of focal lesions within the bone marrow is important for patient staging according to the Ann Arbor classification. BMB remains the gold standard in this setting, but its sensitivity is sub-optimal as the biopsy site may not reflect the entire bone marrow compartment. Bilateral iliac crest BMB usually increases the sensitivity of unilateral BMB. Early during bone marrow infiltration, tumour cells do not displace bone marrow fat cells; the amount of fat cells remains normal. Subsequently, replacement of normal marrow by tumour cells leads to a reduction in T1 SI and an increase in T2 SI. Focal lesions are easily detected when using appropriate MR techniques such as fat suppressed T2 WI before treatment. Several studies have shown that NHL induces angiogenesis[26]. Dynamic contrast-enhanced MR images can demonstrate increased bone marrow enhancement in patients with lymphoproliferative diseases and marrow involvement (Fig. 4)[27,28]. Contrast enhancement decreases after treatment in good responders.

Conclusion

Both FDG-PET and MRI can provide whole body imaging. Both also share the advantage of combining functional and anatomical information. Hybrid FDG-PET and MDCT is the best technique for monitoring response to treatment, especially early response to treatment. Early assessment of response to treatment has the potential to tailor therapy. MR imaging is especially useful in assessing bone marrow and central nervous system involvement.

References

[1] Haioun C, Lepage E, Gisselbrecht C *et al*. High-dose therapy followed by stem cell transplantation in partial response after first-line induction therapy for aggressive non-Hodgkin's lymphoma. Ann Oncol 1998; 9 (Suppl 1): S5–8.

[2] Dugdale PE, Miles KA, Bunce I, Kelley BB, Leggett DA. CT measurement of perfusion and permeability within lymphoma masses and its ability to assess grade,

activity, and chemotherapeutic response. J Comput Assist Tomogr 1999; 23: 540–7.

[3] Bar-Shalom R, Yefremov N, Haim N *et al*. Camera-based FDG PET and 67Ga SPECT in evaluation of lymphoma: comparative study. Radiology 2003; 227: 353–60.

[4] Janicek M, Kaplan W, Neuberg D, Canellos GP, Shulman LN, Shipp MA. Early restaging gallium scans predict outcome in poor-prognosis patients with aggressive non-Hodgkin's lymphoma treated with high-dose CHOP chemotherapy. J Clin Oncol 1997; 15: 1631–7.

[5] Kazama T, Faria SC, Varavithya V, Phongkitkarun S, Ito H, Macapinlac HA. FDG PET in the evaluation of treatment for lymphoma: clinical usefulness and pitfalls. Radiographics 2005; 25: 191–207.

[6] Kapoor V, McCook BM, Torok FS. An introduction to PET-CT imaging. Radiographics 2004; 24: 523–43.

[7] Haioun C, Itti E, Rahmouni A, Meignan M, Reyes F. PET scan in the therapeutic strategy. Hematol J 2004; 5 (Suppl 3): S149–53.

[8] Moog F, Bangerter M, Diederichs CG *et al*. Lymphoma: role of whole-body 2-deoxy-2-[F-18]fluoro-D-glucose (FDG) PET in nodal staging. Radiology 1997; 203: 795–800.

[9] Schoder H, Meta J, Yap C *et al*. Effect of whole-body (18)F-FDG PET imaging on clinical staging and management of patients with malignant lymphoma. J Nucl Med 2001; 42: 1139–43.

[10] Castellucci P, Nanni C, Farsad M *et al*. Potential pitfalls of 18F-FDG PET in a large series of patients treated for malignant lymphoma: prevalence and scan interpretation. Nucl Med Commun 2005; 26: 689–94.

[11] Castellucci P, Zinzani P, Pourdehnad M *et al*. (18)F-FDG PET in malignant lymphoma: significance of positive findings. Eur J Nucl Med Mol Imaging 2005 (Epub ahead of print).

[12] Jerusalem G, Beguin Y, Fassotte MF *et al*. Whole-body positron emission tomography using ^{18}F-fluorodeoxyglucose for posttreatment evaluation in Hodgkin's disease and non-Hodgkin's lymphoma has higher diagnostic and prognostic value than classical computed tomography scan imaging. Blood 1999; 94: 429–33.

[13] Spaepen K, Stroobants S, Dupont P *et al*. Prognostic value of positron emission tomography (PET) with fluorine-18 fluorodeoxyglucose ([^{18}F]FDG) after first-line chemotherapy in non-Hodgkin's lymphoma: is [^{18}F]FDG-PET a valid alternative to conventional diagnostic methods? J Clin Oncol 2001; 19: 414–19.

[14] Juweid ME, Cheson BD. Role of positron emission tomography in lymphoma. J Clin Oncol 2005; 23: 4577–80.

[15] Juweid ME, Wiseman GA, Vose JM *et al*. Response assessment of aggressive non-Hodgkin's lymphoma by integrated International Workshop Criteria and fluorine-18-fluorodeoxyglucose positron emission tomography. J Clin Oncol 2005; 23: 4652–61.

[16] Haioun C, Itti E, Rahmouni A *et al*. [^{18}F]Fluoro-2-deoxy-D-glucose positron emission tomography (FDG-PET) in aggressive lymphoma: an early prognostic tool for predicting patient outcome. Blood 2005 (Epub ahead of print).

[17] Spaepen K, Stroobants S, Dupont P *et al*. Early restaging positron emission tomography with (18)F-fluorodeoxyglucose predicts outcome in patients with aggressive non-Hodgkin's lymphoma. Ann Oncol 2002; 13: 1356–63.

[18] Jerusalem G, Beguin Y, Fassotte MF *et al*. Early detection of relapse by whole-body positron emission tomography in the follow-up of patients with Hodgkin's disease. Ann Oncol 2003; 14: 123–30.

[19] Rahmouni A, Tempany C, Jones R, Mann R, Yang A, Zerhouni E. Lymphoma: monitoring tumor size and signal intensity with MR imaging. Radiology 1993; 188: 445–51.

[20] Nyman RS, Rehn SM, Glimelius BL, Hagberg HE, Hemmingsson AL, Sundstrom CJ. Residual mediastinal masses in Hodgkin disease: prediction of size with MR imaging. Radiology 1989; 170: 435–40.

[21] Gasparini MD, Balzarini L, Castellani MR *et al*. Current role of gallium scan and magnetic resonance imaging in the management of mediastinal Hodgkin lymphoma. Cancer 1993; 72: 577–82.

[22] Devizzi L, Maffioli L, Bonfante V *et al*. Comparison of gallium scan, computed tomography, and magnetic resonance in patients with mediastinal Hodgkin's disease. Ann Oncol 1997; 8 (Suppl 1): 53–6.

[23] Forsgren G, Nyman R, Glimelius B, Hagberg H, Rehn S, Hemmingsson A. Gd-DTPA-enhanced MR imaging in mediastinal Hodgkin's disease. Acta Radiol 1994; 35: 564–9.

[24] Sato C, Naganawa S, Nakamura T *et al*. Differentiation of noncancerous tissue and cancer lesions by apparent diffusion coefficient values in transition and peripheral zones of the prostate. J Magn Reson Imaging 2005; 21: 258–62.

[25] Daldrup-Link HE, Rummeny EJ, Ihssen B, Kienast J, Link TM. Iron-oxide-enhanced MR imaging of bone marrow in patients with non-Hodgkin's lymphoma: differentiation between tumor infiltration and hypercellular bone marrow. Eur Radiol 2002; 12: 1557–66.

[26] Ribatti D, Vacca A, Nico B, Fanelli M, Roncali L, Dammacco F. Angiogenesis spectrum in the stroma of B-cell non-Hodgkin's lymphomas. An immunohistochemical and ultrastructural study. Eur J Haematol 1996; 56: 45–53.

[27] Montazel JL, Divine M, Lepage E, Kobeiter H, Breil S, Rahmouni A. Normal spinal bone marrow in adults: dynamic gadolinium-enhanced MR imaging. Radiology 2003; 229: 703–9.

[28] Rahmouni A, Montazel JL, Divine M *et al*. Bone marrow with diffuse tumor infiltration in patients with lymphoproliferative diseases: dynamic gadolinium-enhanced MR imaging. Radiology 2003; 229: 710–17.

Cancer Imaging (2005) **5,** S113–S119 DOI: 10.1102/1470-7330.2005.0032

Role of imaging to choose treatment

Christophe Fermé*, Daniel Vanel†, Vincent Ribrag* and Théo Girinski‡

*Departments of *Medicine, †Radiology and ‡Radiation Therapy, Institut Gustave Roussy, 39 rue Camille Desmoulins, 94805 Villejuif, France*

Corresponding address: Daniel Vanel, Department of Radiology, Institut Gustave Roussy, 39 rue Camille Desmoulins, 94805 Villejuif, France. E-mail: vanel@igr.fr

Abstract

Radiologists perform various examinations at every step of lymphomas. The role of imaging is atypical for a 'classical' oncologic radiologist, as multiple non-radiological criteria are combined to decide on treatments. A good knowledge of the practical use of the results helps the radiologist to seek the useful pieces of information. In treatment evaluation, uncertain complete response is only used in lymphomas. Imaging is changing, with the emergence of PET and whole body MRI but CT remains the key examination today. The WHO criteria are the only ones used to evaluate treatment results on CT, even though the use of PET is increasingly used, with better and better results.

Keywords: *Lymphoma; CT; staging; treatment evaluation.*

Introduction

The management of lymphomas is quite different from the rest of oncology. A good understanding of the practical consequences of imaging findings helps the radiologist to be efficient. Histology is by far the main prognostic factor, and has the highest impact on treatment choices. A follicular lymphoma, even with multiple lesions, may not require any treatment, whereas a limited high grade lymphoma will require very aggressive treatment. Then multiple other criteria, including imaging, are involved in the choice of treatment. Computed tomography (CT) is the main imaging modality, as it is reproducible and widely available. Magnetic resonance (MR) imaging is especially efficient to evaluate bone marrow. Positron emission tomography (PET) has increasing value in the initial staging and evaluation of early effectiveness of treatment.

Definition of criteria for radiologic evaluation

Radiologic pre-treatment evaluation procedures include chest radiographs (posteroanterior and lateral) and CT of the thorax, abdomen, and pelvis. These investigations are needed to define a number of parameters that are of importance in terms of prognosis, and should be taken into consideration when planning treatment.

Extent of disease

The extent of disease is evaluated according to the Ann Arbor staging classification and Cotswolds' revision (Table 1)[1] or St Jude staging system used for childhood non-Hodgkin's lymphoma and adult patients with Burkitt's lymphoma (Table 2).

Among the criteria are:

- The number of peripheral nodal sites involved. Peripheral nodal sites are defined as cervical (one or several anatomic groups), axillary, inguinal or femoral right and left.

- Tumour volume. A mediastinal mass is defined as bulky on a posteroanterior chest radiograph when the maximum width is equal to or greater than one-third of the internal transverse diameter of the thorax at the level of the T5–T6 interspace[2]. A large mediastinal mass is defined as MT ratio $\geq$0.35. This criterion is mainly used for Hodgkin's lymphoma. According to Cotswolds' modifications of the Ann Arbor classification, a palpable lymph node or conglomerate node mass must be 10 cm or greater in largest diameter to be recorded as bulky. The nodal and extranodal targets defined for assessment of response are measured bidimensionally according to the WHO criteria[3]. RECIST criteria cannot be used.

Prognostic index and score

A number of prognostic scores are used to define prognosis and to make medical decisions for different entities according to the WHO classification of malignant lymphoma[4].

(a)

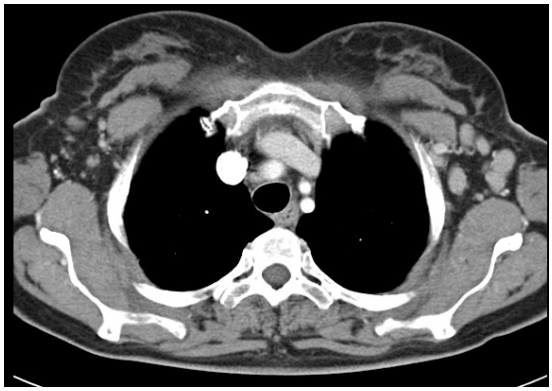

(b)

Figure 1 **Follicular lymphoma. Although there are multiple enlarged nodes in the axilla (a) and pelvis (b), no three masses are more than 3 cm in different locations, so imaging results alone are not an indication to treat.**

Hodgkin's lymphoma

Treatment of Hodgkin's lymphoma depends on stage and prognostic factors. For early stage supradiaphragmatic Hodgkin's lymphoma, the European Organization for Research and Treatment of Cancer (EORTC) Lymphoma Cooperative Group have defined prognostic factors and prognostic subgroups[5,6] for clinical trials since 1988 and adopted by the Groupe d'Etudes de Lymphomes de l'Adulte (GELA) since 1993 (Table 3). The International Prognostic Score (IPS) for advanced stage Hodgkin's lymphoma is used to stratify patients with advanced stage disease in ongoing trials. The IPS is based on seven factors: age $\geq$45 years, male gender, stage IV, white blood count (WBC) $\geq 15 \times 10^9$/l, lymphocytes count $<0.6 \times 10^9$/l or <8% WBC, albumin <4 g/dl, haemoglobin <10.5 g/dl[7]. Extranodal involvement is the only factor on radiologic evaluation. The German Hodgkin Lymphoma Study Group (GHSG) adopted very similar prognostic factors to define early and intermediate stages, but does not apply the International Prognostic Score (Table 3). Radiological staging represents only one of the many prognostic factors. It is a little disappointing for the radiologist to represent only one criterion, of no more value than one of the clinical or biological criteria.

(a)

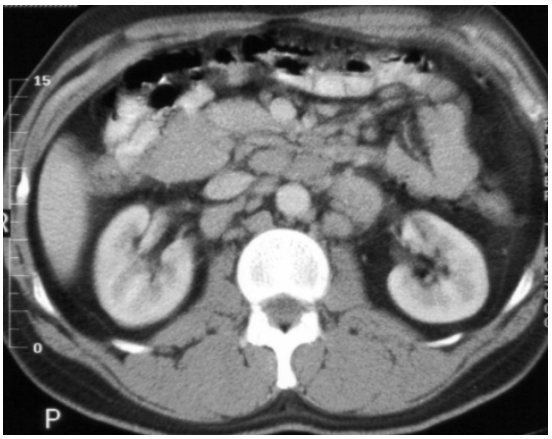

(b)

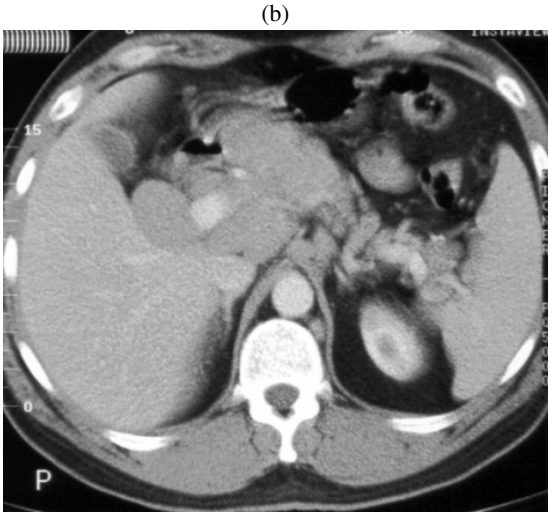

Figure 2 **Follicular lymphoma. Multiple diffuse nodes on CT (a). The mesenteric mass, measuring more than 7 cm in diameter, is an indication to treat.**

Follicular lymphoma

The Groupe d'Etudes des Lymphomes Folliculaires (GELF) criteria have been defined from studies of the GELA[8] as parameters to initiate treatment in patients with untreated follicular lymphoma grade 1, 2 or 3a and were chosen for the Primary Rituximab and Maintenance (PRIMA) ongoing trial (a multicentre, phase III, open-label, randomized study in patients with advanced follicular lymphoma evaluating the benefit of maintenance therapy with rituximab (MabThera®) after induction of response with chemotherapy plus rituximab in comparison with no maintenance therapy.

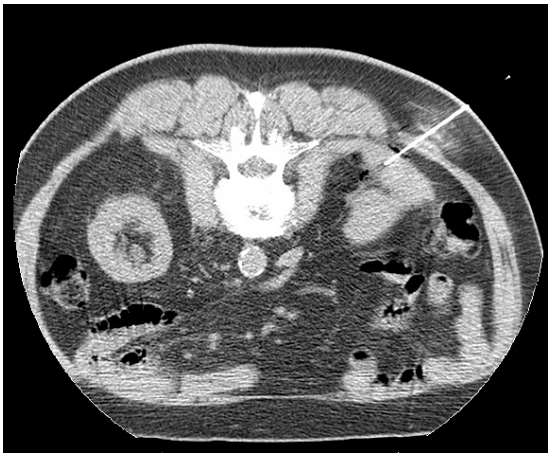

Figure 3 **Retro renal mass appeared in a patient presenting with a low grade lymphoma. CT guided biopsy was performed to look for a higher grade transformation of the lymphoma (in this case, everything actually remained low grade).**

Bulky disease is defined by the presence of one criterion:

- a nodal or extranodal mass ≥7 cm in its greater diameter
- or B symptoms
- or increased lactate dehydrogenase (LDH) and $\beta 2$ microglobulinemia
- or involvement of at least three nodal sites (each with a diameter greater than 3 cm)
- or splenic enlargement
- or compression syndrome
- or pleural/peritoneal effusion.

One of these criteria justifies treatment (and in their absence, no treatment is given) (Figs 1 and 2).

The Follicular Lymphoma International Prognostic Index (FLIPI Score) has been defined after retrospective analysis of different trials[9]. Five independent adverse prognostic factors were selected after multivariate analysis:

1. Age (>60 vs. ≤60)
2. Ann Arbor stage (III–IV vs. I–II)
3. Haemoglobin level (<12 g/dl vs. ≤12 g/dl)
4. Number of nodal areas (>4 vs. ≤4)
5. Serum LDH level (> normal vs. ≤ normal)

The nodal areas involved are enumerated for each patient and defined as follows: cervical (pre-auricular, upper cervical, median or lower cervical, posterior cervical or supraclavicular), axillary, mediastinal (paratracheal, mediastinal, hilar), mesenteric (celiac, splenic hilar, hepatic hilar, portal, mesenteric), para aortic (para aortic, common iliac, external iliac), inguinal (inguinal, femoral), and other (epitrochlear, popliteal). Three risk groups were defined: low risk (0–1 adverse factor), intermediate risk (2 adverse factors), and poor risk (≥3 adverse factors).

(a)

(b)

Figure 4 **Whole body MRI performed in the initial evaluation of a lymphoma. T1-weighted images. Chest (a) and pelvis (b) images. Bone marrow involvement of the right proximal humerus and left sacral wing are easily detected.**

Aggressive non-Hodgkin lymphomas

The International Non-Hodgkin's Lymphoma Prognostic Factors Project has identified a predictive model for outcome that has established five independent

prognostic factors: age (>60 years adverse), stage I–II vs. III–IV (III–IV adverse), number of extranodal sites (>1 adverse), performance status (low status Eastern Cooperative Oncology Group (ECOG) >2 adverse), serum LDH (elevated level adverse)[10]. The age-adjusted International Prognostic Index (stage, performance status, serum LDH) is applied worldwide to stratify patients into prognostic subgroups.

Burkitt's lymphoma

The Ann Arbor staging system is not well suited to patients with Burkitt's lymphoma, which is predominantly extranodal (bone marrow and/or central nervous system involvement not always accompanied by nodal involvement). The most widely used classification is the St Jude staging system used for childhood non-Hodgkin's lymphoma (Table 2). Staging procedures should be done within 24–48 h because of the rapidity of tumour growth. Peritoneal or pleural effusions are particularly helpful for the diagnosis and should be documented with cytogenetics, immunophenotyping and genotyping. Tumour burden is a prognostic factor and evaluation of tumour size is necessary for restaging under treatment. Magnetic resonance imaging of the head and neck, chest, abdomen, skeleton, and central nervous system (CNS) may be indicated in some circumstances but is not used routinely.

Impact of radiologic evaluation on treatment decision

Initial staging at diagnosis

Hodgkin's lymphoma

In early stage supradiaphragmatic Hodgkin's lymphoma, the standard treatment is a combination of chemotherapy followed by radiotherapy. The number of cycles of chemotherapy (ABVD regimen (adriamycin, bleomycin, vinblastine, dacarbazine) as standard) depends on prognostic subgroups, three cycles for favourable groups and four cycles for unfavourable groups. Radiotherapy is delivered to responding patients and limited to initially involved areas: 'involved fields' radiation therapy.

As the treatment subgroups (unfavourable and favourable) are defined by adverse prognostic factors, a careful evaluation of the extent of disease and tumour size is a condition for a risk adapted strategy: number of cycles of chemotherapy, radiotherapy delivered to all initially involved areas (evaluation of axillary areas on chest CT), and planned doses of radiotherapy delivered according to the response to chemotherapy.

In advanced stage Hodgkin's lymphoma, the standard treatment is chemotherapy alone with ABVD regimen, eight cycles if a complete response or complete response uncertain is achieved after 6 cycles.

Tumour volume as a large mediastinal mass has no impact on the choice of first line chemotherapy, however, the tumour size is measured for the evaluation of response to initial chemotherapy (first evaluation recommended after four cycles).

Follicular lymphoma

The initial evaluation is of importance to identify patients with a small tumour burden and a slow progression of disease for whom a watch and wait policy is recommended by the majority of centres and those with adverse risk factors as previously described who need to be treated. Chemotherapy (cyclophosphamide, vincristine and prednisolone (CVP), CHOP regimen or Fludarabine-based regimens) plus rituximab (MabThera®), a chimeric/human monoclonal antibody that is directed specifically against the B-cell antigen CD20, is considered in many countries as the standard for first-line treatment of patients with follicular lymphoma.

Diffuse large-B-cell lymphoma

The CHOP regimen (cyclophosphamide, doxorubicin, vincristine, prednisone) combined with rituximab given in eight cycles is the standard of care for elderly patients (≥60 years old) with diffuse large-B-cell lymphoma[11].

Evaluation of the Ann Arbor stage is the main parameter evaluated on imaging with an impact on the definition of initial treatment based on the age-adjusted International Prognostic Index (Fig. 4).

Burkitt's lymphoma

Treatment protocols based on combination chemotherapy regimens designed for children, consisting of intensive doses of alkylating agents given in combination with methotrexate, vincristine, cytarabine, have been shown to be highly effective for patients with Burkitt's lymphoma, whether adults or children. CNS prophylaxis including intrathecal methotrexate and cytarabine is an essential component of therapy. Treatment subgroups are defined on the basis of bone marrow and/or CNS involvement at diagnosis: patients without bone marrow and/or CNS involvement (stages 1–3 of the St Jude staging system) and patients with bone marrow and/or CNS involvement who are stratified according to age and CNS involvement because of the toxicity of methotrexate and cytarabine. Appropriate measures for the prevention of tumour lysis syndrome are highly recommended. The role of rituximab is being evaluated in prospective trials.

Table 1 Ann Arbor staging classification and Cotswolds revision

Stage I	I	Involvement of a single lymph node region.
	IE	Localized involvement of a single extralymphatic organ or site.
Stage II	II	Involvement of two or more lymph node regions on the same side of the diaphragm.
	IIE	Localized involvement of a single associated extralymphatic organ or site and of one or more lymph node regions on the same side of the diaphragm.
		Right and left hilum: one area each, independent of mediastinum; number of anatomic nodal areas to be indicated by a subscript (II_4).
Stage III	III	Involvement of lymph node regions on both sides of the diaphragm.
	III_1	Upper abdomen (splenic, hilar, celiac, or portal nodes).
	III_2	Lower abdomen (paraaortic, iliac, mesenteric nodes).
	IIIE	Involvement of lymph node regions on both sides of the diaphragm accompanied by localized involvement of an extralymphatic organ or site[a].
Stage IV	IV	Disseminated (multifocal) involvement of one or more extralymphatic sites with or without associated lymph node involvement or isolated extralymphatic organ involvement with distant (non-regional) nodal involvement.
		The absence or presence of fever >38 °C, drenching sweats during the last month, and/or weight loss of 10% or more of body weight in 6 months are to be noted in all cases by the suffix letters A or B, respectively.
	X	Bulky disease, >1/3 widening of mediastinum at T5–T6 level, or >10 cm maximum dimension of nodal mass.
	CR(u)	Unconfirmed/uncertain complete remission (residual imaging abnormality).

[a]In FLIPPI, spleen involvement is categorized as stage IV.

Table 2 St Jude staging system used for childhood non-Hodgkin's lymphoma[a]

Stage	Definition
I	Single tumour (extranodal)
	Single anatomic area (nodal)
	Excluding mediastinum or abdomen
II	Single tumour (extranodal) with regional node involvement
	Primary gastrointestinal tumour with or without involvement of associated mesenteric nodes only, grossly completely resected
	On same side of diaphragm:
	Two or more nodal areas
	Two single (extranodal) tumours with or without regional node involvement
III	On both sides of the diaphragm:
	Two single tumours (extranodal)
	Two or more nodal areas
	All primary intrathoracic tumours (mediastinal, pleural, thymic)
	All extensive primary intra-abdominal disease
	All primary paraspinal or epidural tumours regardless of other sites
IV	Any of the above with initial central nervous system or bone marrow involvement (<25%)

[a]Patients with more than 25% of blast cells in the bone marrow are considered to have acute-B-cell leukaemia.

Response assessments during and after treatment

Response is classified as complete response (CR), complete response unconfirmed (CRu), partial response (PR), stable disease or progressive disease, according to standardized response criteria[12] (Table 4).

The impact of response assessment depends on the planned treatment for the different types of lymphomas.

Hodgkin's lymphoma

In early stage supradiaphragmatic Hodgkin's lymphoma, response is evaluated after initial chemotherapy and before radiation therapy, to confirm the planned radiotherapy for responding patients and the doses of radiation therapy to initially involved areas. Patients with stable disease or progression are treated with salvage therapy.

In advanced stage Hodgkin's lymphoma, an intermediate response evaluation is recommended at the end of the 4th and 6th cycles. Patients who achieve at least a PR at the end of the 4th cycle continue the chemotherapy and are restaged after six cycles. Patients who achieve a CR/Cru after six cycles usually receive consolidation chemotherapy. Patients with a partial response after initial chemotherapy, are submitted to additional investigations (PET scan, MRI, biopsy of mediastinal or infradiaphragmatic node or mass) in order to define if a salvage treatment is indicated. Response is evaluated after eight cycles, patients with a partial response and documented active disease are candidates for additional treatment (radiation therapy in the case of localized nodal disease).

Table 3 Hodgkin's lymphoma, risk factors according to cooperative treatment groups[a]

	EORTC	GHSG	Canada
Risk factors (RF)	(A) Mediastinal mass MT ≥0.35	(A) Mediastinal mass MT ≥0.35	
	(B) Age ≥50 years	(B) Extra nodal site E	(B) Age >40 years
	(C) (A) and ESR ≥50 or (B) and ESR ≥30	(C) ESR ≥50 mm without or ≥30 mm with (B) symptoms	(C) ESR >50
	(D) ≥4 nodal areas	(D) >3 nodal areas	(D) ≥3 sites
Stage			
Favourable (F)	I–II without RF	I–II without RF	I–II without RF
Unfavourable (UF)	I–II with 1 or +RF	I–IIA with 1 or +RF	I–II with RF
Or intermediate advanced	III–IV	IIB with A/B; III–IV	

[a]GHSG, German Hodgkin's Lymphoma Study Group; EORTC, European Organisation for Research and Treatment of Cancer; GELA, Groupe d'Etudes des Lymphomes de l'Adulte; ESR, erythrocyte sedimentation rate; MT ratio, ratio of the largest transverse diameter of the mass to the transverse diameter of the thorax at the level of T5–T6.

Table 4 Response criteria for non-Hodgkin's lymphoma: International Working Group recommendations [12]

Response category	Physical examination	Lymph nodes	Lymph node masses	Bone marrow
CR	Normal	Normal	Normal	Normal
CRu	Normal	Normal	Normal	Indeterminate
	Normal	Normal	≥75% decrease	Normal or indeterminate
PR	Normal	Normal	Normal	Positive
	Normal	≥50% decrease	≥50% decrease	Irrelevant
	Decrease in liver/spleen	≥50% decrease	≥50% decrease	Irrelevant
Relapse/progression	Enlarging liver/spleen; new sites	New or increased	New or increased	Reappearance

Follicular lymphomas

The PRIMA study has been designed to compare the maintenance schedule of one infusion of rituximab every 2 months for 24 months vs. observation until progression, relapse, death or institution of new treatment for follicular lymphoma in patients responding to an induction standard regimen of rituximab plus chemotherapy (CVP, CHOP, fludarabine, cyclophosphamide, mitoxantrone (FCM)). After induction treatment (six or eight cycles of chemotherapy combined with eight infusions of rituximab), responding patients (complete response CR or partial response PR will be randomized to maintenance therapy vs. no further treatment (observation). Patients with stable or progressive disease will be discontinued from study treatment.

Diffuse large B cell lymphomas

The treatment is delivered according to two phases, an induction phase and a consolidation phase. Evaluation of response after the induction phase is performed to identify the responding patients (CR or PR) for whom the consolidation phase is confirmed and patients with stable disease or progression for whom a new treatment is necessary. After the completion of the planned treatment, a final restaging is performed, usually within 4 weeks of the last treatment, to define patients with CR or CRu who are submitted to the follow-up evaluation, and patients with partial response who are submitted to disease documentation (PET scan and/or histological), in order to decide a new anti-lymphoma therapy (Fig. 3).

Burkitt's lymphoma

Response to the initial cyclophosphamide, vincristine, prednisone (COP) regimen is a prognostic factor and needs to be evaluated early at day 7 by clinical examination and ultrasonography of an abdominal mass. Response must be evaluated further after the first cycle of consolidative chemotherapy. Surgical resection is indicated for patients with residual mass after consolidative chemotherapy, in order to define salvage treatment with intensive chemotherapy and autologous stem cell transplant for patients with documented partial response.

Conclusion

Treating lymphoma combines multiple criteria based on years of trials. Although they may look very strange, they are probably efficient. Radiology plays a well-defined role among those criteria. Their extensive knowledge will allow the radiologist to be an active and useful part of the team in charge of the patient.

References

[1] Lister TA, Crowther D, Sutcliffe SB *et al*. Report of a committee convened to discuss the evaluation and staging

of patients with Hodgkin's disease: Cotswolds Meeting. J Clin Oncol 1989; 7: 1630.
[2] Lee CKK, Bloomfield CD, Goldman AI, Levitt SH. Prognostic significance of mediastinal involvement in Hodgkin's disease treated with curative radiotherapy. Cancer 1980; 46: 2403–9.
[3] WHO. Handbook for Reporting Results of Cancer Treatment, Geneva: World Health Organization, Offset Publication, 1979: 48.
[4] Jaffe ES, Harris NL, Stein H, Vardiman JW, eds. World Health Organization Classification of Tumours: Pathology and Genetics of Tumours of Haematopoietic and Lymphoid Tissues. Lyon, France: International Agency for Research on Cancer, 2001.
[5] Tubiana M, Henry-Amar M, Carde P *et al*. Toward comprehensive management tailored to prognostic factors of patients with clinical stages I and II in Hodgkin's disease. The EORTC Lymphoma Group controlled clinical trials: 1964–1987. Blood 1989; 73: 47–56.
[6] Noordijk E, Carde P, Mandard A *et al*. Preliminary results of the EORTC-GPMC controlled clinical trial H7 in early stage Hodgkin's disease. Ann Oncol 1994; 5: 107–112.
[7] Hasenclever D, Diehl V. For the International Prognostic factors project on advanced Hodgkin's disease. A prognostic score to predict tumor control in advanced Hodgkin's disease. N Engl J Med 1998; 339: 1506–15.
[8] Solal-Celigny P, Lepage E, Brousse N *et al*. For the Groupe d'Etude des Lymphomes de l'Adulte. N Engl J Med 1993; 329: 1608–14.
[9] Solal-Celigny P, Roy P, Colombat P *et al*. Follicular lymphoma international prognostic index. Blood 2004; 104: 1258.
[10] Shipp M, Harrington D, Anderson J *et al*. A predictive model for aggressive non-Hodgkin's lymphoma: the international NHL prognostic factors project. N Engl J Med 1993; 329: 987–94.
[11] Coiffier B, Lepage E, Briere J *et al*. CHOP chemotherapy plus rituximab compared with CHOP alone in elderly patients with diffuse large-B-cell lymphoma. N Engl J Med 2002; 346: 235–42.
[12] Cheson BD, Horning SJ, Coiffier B *et al*. Report of an international workshop to standardize response criteria for non-Hodgkin's lymphomas. J Clin Oncol 1999; 17: 1244–53.

Cancer Imaging (2005) **4,** S119–S126 DOI: 10.1102/1470-7330.2005.0033

Problems monitoring response in multiple myeloma

Conor D Collins

St Vincent's University Hospital, Dublin, Ireland

Corresponding address: St Vincent's University Hospital, Dublin 4, Ireland
E-mail: c.collins@st-vincents.ie

Abstract

There has been a revolution in the treatment of multiple myeloma over the past decade. This article seeks to correlate advances in imaging with advances in treatment and to highlight how proper understanding of both is necessary for optimum management.

Keywords: *Multiple myeloma; imaging; treatment.*

Introduction

Multiple myeloma is the second most common form of haematological malignancy in the Western World after non-Hodgkin's lymphoma, accounting for approximately 10% of haematological malignancies and 1% of all malignancies. It is a disease of later life with 98% of patients aged 40 or older. The aetiology is unknown though there is an increased risk in those who have a past history of radiation exposure.

Multiple myeloma is characterised by uncontrolled proliferation of plasma cells within the marrow (mature antibody producing B cells). This leads to disruption of the subtle balance between osteoblastosis and osteoclastosis within bone by overproduction of tumour necrosis factor-related induced cytokine (TRANCE) and inactivation of osteoprotegerin resulting in unrestricted osteoclastic activity manifest as lytic deposits. An unwanted secondary effect is the promotion of further clonal proliferation of myeloma cells further augmenting the disease process[1].

Diagnosis is based on laboratory and radiographic findings and depends on three abnormal results:

- bone marrow containing more than 10% plasma cells (normally no more than 4% of the cells in the bone marrow are plasma cells)

- generalised osteopaenia and/or lytic bone deposits on plain film radiography
- blood serum and/or urine containing an abnormal protein.

In about 75% of all cases of multiple myeloma the paraprotein present (M protein) will correspond with one type of immunoglobulin. In about 60% of cases an abnormal protein, known as Bence–Jones protein may also be found in the urine. Measuring the amount of paraprotein in the blood or urine is of value in the diagnosis of myeloma and in monitoring the response to treatment.

Staging

The clinical staging system devised by Durie and Salmon distinguishes different patient subgroups in terms of tumour mass and disease aggression and still often determines management[2]. Patients with at least two lytic foci are classified in advanced disease subgroups and aggressive systemic treatment is usually indicated. However, this staging system has recently been replaced by one based entirely on serum $\beta 2$ microglobulin and serum albumin levels[3] (Table 1). Although patient outcome is affected by abnormalities of chromosome 13 it does not add to the prognostic power of the new international staging system[3,4].

Table 1 New international staging system[3]

Stage I	Serum $\beta 2$ microglobulin <3.5 mg/l
	Serum albumin ≥ 3.5 g/dl
Stage II	Not I or III[a]
Stage III	Serum $\beta 2$ microglobulin ≥ 5.5 mg/l

[a]There are two categories for stage II: serum $\beta 2$ microglobulin <3.5 mg/l but serum albumin <3.5 g/dl or serum $\beta 2$ microglobulin 3.5–5.5 mg/l irrespective of the serum albumin level.

Therapy

The International Myeloma Foundation and UK Myeloma Forum (with the support of the British Committee for Standards in Haematology) should be regarded as the preferred source of detailed guidance on treatment[5,6]. Treatment strategy is directed towards adequate analgesia, rehydration, management of hypercalcaemia and renal impairment, and treatment of infection. The response categories (complete, near complete, partial, minimal, stable and progressive) are determined primarily by the level of M protein present. M protein is the level of monoclonal protein measured by protein electrophoresis in serum or 24 h urine. Changes in M protein should be supported with other evidence of treatment benefit to confirm response[5].

Chemotherapy is indicated for management of symptomatic myeloma. High dose therapy using melphalan and prednisolone can produce complete remission in up to 75% of patients[7,8]. In recent years thalidomide (and its more potent immunomodulatory analogue lenalidomide) has been recognised as a valuable drug for the treatment of myeloma[9,10]. Other new agents entering clinical trials include conventional drugs (Doxil), cytokines (Avastin), biological agents (Betathine) and agents such as arsenic trioxide[10–12].

The most serious morbidity in these patients arises from destructive bone deposits which cause severe intractable pain and pathological fractures often resulting in deformity and disability. Vertebroplasty and kyphoplasty have been performed to alleviate bone pain from collapsed vertebrae and restore vertebral body height[13–15]. The introduction of the bisphosphonate group of drugs has transformed this aspect of the disease. They bind to bone at sites of active bone remodelling and can therefore inhibit myelomatous bone damage arresting the destructive cycle described above[16,17]. These agents (used in conjunction with cytotoxic chemotherapy) have been found to be superior to chemotherapy alone in decreasing the incidence of pathological fractures and bone pain and may lead to prolonged survival[18–21].

Autologous transplantation has an established place in the treatment of myeloma. It is the treatment of choice for patients aged under 65 and can be considered in older age groups (with good performance status) carrying a procedure related mortality of less than 5%[10,22,23]. At present the added benefit of double or tandem transplantation versus a single autologous transplant is not known.

Radiation therapy is reserved for patients with spinal cord compression secondary to vertebral body collapse associated with a soft tissue mass or pathological fractures elsewhere associated with a soft tissue mass. It can be very effective but permanently destroys normal bone marrow stem cells in the treatment field.

Myeloma is generally considered incurable. It is a slowly progressing disease with long periods of relative inactivity. Relapse occurs in virtually all cases. On current treatment regimens patients younger than 70 years can expect a median survival of 5 years (depending on stage)[7,12]. Death results from bacterial infection, renal insufficiency and thromboembolism.

Side effects of therapy and complications: the role of radiology

Drug therapy

Infection is the single most dangerous complication for myeloma patients with the patient most at risk in the first 3 months of front-line therapy[5]. Myeloma is associated with a higher incidence of infective discitis and cerebritis in part due to cytotoxic therapy induced immunosuppression associated with corticosteroid therapy[24–26]. Central venous catheters represent a potential source

of bacteraemia[27]. Magnetic resonance imaging (MRI) enables early identification followed by percutaneous needle aspirate using computed tomography (CT) to confirm the diagnosis and provide information regarding choice of antibiotic[28]. Melphalan is associated with increased pancytopaenia, mucositis and pulmonary complications[29–32]. Plain film radiography and CT scanning are the appropriate imaging investigations. High doses of corticosteroids may cause spinal fractures and avascular necrosis of the femoral heads (amongst other bones). MRI is useful for assessing both these conditions. When thalidomide is used in combination with dexamethasone it carries a 16% incidence of deep vein thrombosis (DVT)[33,34]. Abdominal discomfort resulting from constipation is also a well-recognised side effect of thalidomide and can be readily assessed radiologically using a supine plain radiograph of the abdomen. A recently reported side-effect is interstitial pneumonitis which can be identified on high resolution CT[35]. The newer class of drug Bortezomib (a proteasome inhibitor reserved for relapsed disease) is associated with cytopaenia and a decrease in platelet count to $<50\,000$ mm^3 occurs in almost 30% of patients increasing the risk of haemorrhage[36]. This drug has not been associated with an increased incidence of DVT in trials conducted to date[12]. Chronic bisphosphonate use is associated with renal damage (monitored with regular serum creatinine levels) and osteonecrosis of the mandible[37,38]. Regular dental check-ups in association with an orthopantomogram enable early diagnosis of the latter.

Marrow transplantation

Allogeneic transplant is a high risk procedure with reported mortality of 15%–20% in the best centres due primarily to infection and graft vs. host disease[39,40]. Encephalopathic changes (which are reversible) may develop as a result of cyclosporin therapy[41]. In patients undergoing non-myeloablative or 'mini' allogeneic transplants there is a high risk of acute (32%–39%) and chronic (32%–46%) graft versus host disease in reported series[10]. Imaging depends on symptomatology and consists of plain film radiography, CT and MRI as required.

Complications

Spinal cord compression resulting from vertebral body collapse may occur in up to 25% of patients and has been described as the presenting feature in 12% of patients[42–44]. Early recognition of back pain and neurological symptoms is essential. Magnetic resonance is the imaging investigation of choice. Pathological fractures are common, occurring in 50% of patients[45]. Fractures of the tubular bones heal readily with normal amounts of callus but extensive fractures may require insertion of intramedullary nails. Myelofibrosis manifest by diffuse low signal on both T1 weighted (T1W) and short tau inversion recovery (STIR) sequences and amyloidosis manifest by focal areas of decreased signal on T1W and STIR sequences are other recognised complications[46].

Renal impairment is common in myeloma and affects up to half of all patients at some stage in their illness. This is usually a consequence of amyloidosis rather than plasma cell infiltration[47]. Other possible causes include hypercalcaemia, dehydration, hyperuricaemia, infection or the action of nephrotoxic drugs. Unfortunately several of the drugs that are used to treat myeloma have an adverse effect on kidney function. Secondary amyloid occurs in approximately 10% of cases and in the early stages ultrasound demonstrates enlarged kidneys with increased cortical reflectivity. Amyloid protein is deposited mainly in the cortex so that corticomedullary differentiation is preserved and the pyramids are normal in size[48]. Radiolabelled serum amyloid P component scintigraphy is a non-invasive and quantitative method for imaging amyloid deposits though it is less effective in myeloma associated amyloid than other forms of amyloid[49].

Radiology of responding/relapsing disease

The role of radiology in the assessment of treatment response is limited and sequential quantification of biological markers of disease (monoclonal protein levels and bone marrow plasmacytosis) are usually sufficient to assess response to chemotherapy.

Anatomical imaging

Plain film radiography

Almost 80% of patients with multiple myeloma will have radiological evidence of skeletal involvement at diagnosis manifest in four different appearances: solitary deposit (plasmacytoma); diffuse skeletal involvement (myelomatosis); generalised osteopaenia; and sclerosing myeloma[46]. The most common sites include the vertebrae, ribs, skull and pelvis, whereas involvement of the distal bones is unusual. In early stage disease the role of the plain radiograph is limited with myeloma deposits often not visualised[50,51]. Myeloma lesions are sharply defined, small lytic areas (average size 20 mm) of bone destruction with no reactive bone formation. At post mortem these lesions are due to nodular replacement of marrow and bone by plasma cells. Although myeloma arises within the medulla, disease progression may produce infiltration of the cortex, invasion of the periosteum and large extraosseous soft tissue masses. The pattern of destruction may be geographic, moth

eaten or permeated. Generalised osteopaenia may be the only bone manifestation of myeloma in up to 15% of patients. Vertebral body collapse is the usual manifestation of this subtype which should not be confused with non-myelomatous osteoporosis which occurs in many older patients. On plain film radiography shrinking or sclerosing deposits indicate a response to chemotherapy and/or radiation therapy. The addition of bisphosphonate compounds as antiosteoclast agents leads to bone strengthening which further accentuates these features. Persistence of radiological abnormalities should not be considered evidence of active disease, since they may represent residual osteolysis in the absence of plasma cell proliferation.

Computed tomography

A wide range of findings have been described in CT of myeloma. These include sharp, lytic foci of small and relatively homogenous size with no sclerotic rim, diffuse faint osteolysis, an angioma-like appearance due to the presence of thickened vertical trabeculae and expansile deposits[52]. Myelomatous marrow often shows an abnormally high attenuation value compared with normal marrow. Discrete interruption of the cortical contour may be seen. CT can accurately depict the extent of associated soft tissue masses and can direct needle biopsy for histological diagnosis. In treated lytic deposits disappearance of soft tissue masses and reappearance of a continuous cortical contour and of a fatty marrow content may be observed. The advent of multidetector CT (MDCT) provides more detailed information on the risk of vertebral fractures compared with plain film radiography and MRI[53]. In patients who are severely disabled or who are unable to undergo MRI examination this is a useful alternative imaging technique[54].

Magnetic resonance imaging

MRI is used routinely due to its high sensitivity and its ability to directly visualise bone marrow. The imaging patterns in multiple myeloma can be classified as normal, focal, diffuse and variegated[55,56]. A more detailed discussion on the MRI patterns is presented elsewhere[57]. The lack of specificity of the MRI patterns should be noted. The focal and diffuse patterns may be observed in both metastatic disease from primary solid tumours and in other haematological malignancies, especially lymphoma and leukaemia. Differentiation between red marrow hyperplasia secondary to anaemia, infection, malignant or treated marrow infiltration can be extremely difficult. Normal marrow heterogeneities may mimic the variegated pattern although in most cases high signal intensity on T2 weighted images and contrast enhancement help distinguish relevant small marrow abnormalities from normal haematopoietic foci that generally show intermediate signal intensity on T2 weighted images and no contrast enhancement on T1 weighted images.

Several criteria exist for differentiating benign from malignant vertebral body compression fractures[58,59]. However, these should be applied with caution to patients with multiple myeloma as normal signal intensity within a compressed vertebral body on spinal MR images does not preclude the diagnosis of multiple myeloma. In a study of 224 vertebral fractures in patients with known multiple myeloma Lecouvet *et al.* found that 67% appeared benign on MRI and 38% of their 37 patients had benign fractures only at diagnosis[60]. In patients with osteoporotic or post traumatic vertebral compression of recent onset MRI will usually show signal alteration that parallels one of the end plates, involves less than half of the vertebral body, does not extend to the pedicles and enhances homogenously following intravenous contrast. Diffusion weighted MRI may also prove to be a useful method to apply to the differential diagnosis of compression fractures[61].

Patients being treated for multiple myeloma may suffer acute back pain secondary to vertebral body collapse even after effective chemotherapy. This is due to resolution of the tumour mass that was supporting the bony cortex. Thirty-five new vertebral compression fractures were discovered on post-treatment MR images of 29 patients with multiple myeloma in remission[62]. In another study, 131 vertebral compression fractures appeared in 37 patients with multiple myeloma after the onset of therapy[61]. Conversely, progression of disease may also be responsible for a new compression fracture and MRI may be useful in differentiating between these two clinical settings. It has been shown that patients with either normal marrow appearance or less than ten focal lesions on pre-treatment MR images had significantly longer fracture free survival than patients with more than 10 focal lesions or with diffuse patterns on pre-treatment MR images[63].

Interpretation of post treatment MRI changes can be difficult as there is a wide spectrum of possible treatment induced changes on MRI depending on the pattern of bone marrow infiltration. There has also been little long-term follow-up of these patients. Although MRI is more sensitive than the skeletal survey it is often difficult to differentiate inactive from active disease. Changes in contrast enhancement between the pre and post treatment MR examinations have been studied. The lack of lesion enhancement or only a peripheral rim enhancement seen after treatment can be indicative of responsive deposits. Focal marrow lesions may remain identical or decrease in size[62,64,65]. Local radiation therapy of focal complex deposits induces a rapid decrease in the soft tissue extension and appearance of presumably necrotic, avascular central areas within the deposit on T1 weighted images with a later decrease in lesion size[66]. In diffuse marrow abnormalities, increased marrow signal is usually observed on post treatment T1 weighted

images due to reappearance of fat cells within more hydrated cellular components. Conversion of a diffuse to a focal or variegated pattern is also frequent[62]. Post treatment MRI of the bone marrow may provide important information for patients with equivocal clinical and laboratory results as well as for patients with non-secretory myeloma.

In patients with advanced disease stages treated with conventional chemotherapy, patients with normal MR findings at diagnosis have better response to treatment and a longer survival than those with focal or diffuse marrow abnormalities at MR imaging[67]. This feature has not yet been assessed in patients treated with marrow transplantation. Patients undergoing therapy with thalidomide have more favourable outcomes (better overall survival rate and prolonged event free survival) with a normal post-treatment MRI than those with persistent focal deposits[9].

After bone marrow transplantation, bone marrow generally has a high signal on T1 weighted images but focal residual deposits are frequent[68]. The prognostic significance of these abnormalities is uncertain as patients with these residual abnormalities did not have a poorer outcome than those with normal post transplantation MRI scans[69]. Increased marrow cellularity due to marrow stimulating factors and decreased signal due to marrow haemosiderosis resulting from repeated transfusions may also be present on post-transplantation MR images. Despite the superiority of MRI over radiographs for spinal and pelvic lesion detection, an MRI survey limited to these areas may be less sensitive than the conventional skeletal survey which may detect deposits in the skull and rib[70].

In patients with clinical relapse new focal deposits or an increase in size of deposits previously present can be identified with MRI. Conversion of a normal or variegated pattern to a diffuse pattern indicates severe relapse on follow-up MRI scans. MRI is also useful in assessing status of leptomeninges as abnormal enhancement representing tumour spread has been reported in 18 out of 1856 treated patients in one series[71]. In patients with a solitary bone plasmacytoma MR screening of the spine and pelvis will usually reveal radiographically unsuspected deposits in up to 80% of patients thus suggesting true myeloma from the outset. This finding is associated with a poor response to localised radiotherapy and an earlier development of systemic disease than in patients with a negative MRI survey[72].

High levels of serum beta 2 microglobulin correlate with a poor prognosis and remain the single most powerful determinant of outcome[73]. No correlation between this finding and appearances on MRI has yet been demonstrated. Long term prospective studies are required to establish the significance and prognostic value of the different MRI patterns of marrow involvement and their correlation with various laboratory values particularly in patients undergoing transplantation.

Functional imaging

Conventional scintigraphy

Although abnormal tracer uptake has been shown to indicate residual activity on conventional skeletal scintigraphy, osteoblastic activity due to healing vertebral body fractures, fractures elsewhere in bony skeleton and drug therapy (particularly bisphosphonates) will also give rise to increased isotope uptake[16,17,74]. ^{99m}Technetium methoxyisobutylisonitrile (^{99m}Tc-MIBI) has been shown to be superior to plain film radiography and skeletal scintigraphy in detecting bone and bone marrow involvement[75–78]. Different patterns of ^{99m}Tc-MIBI uptake have been described with multiple myeloma (negative, diffuse, focal, combined focal and diffuse) and semiquantitative evaluation of these patterns showed a significant correlation with clinical status and stage of the disease[79]. A negative scan in a patient with multiple myeloma indicates early stage disease or post treatment remission while the presence of focal uptake and/or intense diffuse bone marrow uptake suggests an advanced stage of active disease. A subsequent follow-up study involving 22 patients showed a significant correlation between the scintigraphic findings and clinical status post chemotherapy[80]. However, evaluation of the treated patient using this tracer may be compromised if drug resistance is present. If this is manifest as Pgp expression, dual phase imaging (at 10 min and 4 h following injection) helps differentiate but if Bcl-2 is expressed correlation with other imaging is necessary[81].

FDG-PET

Positron emission tomography (PET) using the glucose analogue fluorine-18 fluorodeoxyglucose has also proved useful. In one series comprising 28 patients FDG-PET was true positive in almost 93% of the radiographically documented osteolytic deposits and demonstrated a greater extent of disease than plain film radiography in 61% of patients[82]. Other studies have demonstrated its reliability in detecting active myeloma both within bone and at extramedullary sites and its ability to differentiate between new active disease and inactive (treated) sites[83–85]. In a recent study involving 13 patients using FDG-PET, nine of whom had undergone therapy, PET proved superior to anatomical imaging in identifying sites of active residual disease[86]. Patients showing no abnormal or decreased FDG uptake demonstrated clinical improvement. False negative results may occur due to limitations with spatial resolution resulting in deposits less than 0.5 cm not being detected. False positive results may arise from inflammatory changes associated with radiation or chemotherapy so at least 2 months should elapse post therapy before this study is performed. FDG-PET is also accurate in assessing

disease status in patients with extraosseous myeloma (5% of all myeloma patients)[84,87,88]. Although no study has been published to date using integrated PET/CT imaging this technique is likely to be complementary to plain film radiography and/or MRI as anatomical assessment of myeloma deposits will still be necessary. Interestingly, a recent study comparing MIBI with PET indicated that MIBI identified more disease sites[89].

Conclusion

The wide variety of options now available for treating multiple myeloma means that the radiologist has to be ever more alert in differentiating imaging features due to side-effects and complications of therapy from those related to responding/relapsing disease. There is still an important role for the skeletal survey with MRI/MDCT being reserved for bones that require closer evaluation. The benefits of bisphosphonate therapy can be assessed using dual energy X-ray absortiometry (DEXA) scanning. The increasing availability of metabolic imaging means that FDG-PET/CT is likely to play an increasing role particularly in assessing status of extramedullary disease.

References

[1] Tricot G. New insights into role of microenvironment in multiple myeloma. Lancet 2000; 355: 248–50.

[2] Durie BG, Salmon SE. A clinical staging system for multiple myeloma. Correlation of measured myeloma cell mass with presenting clinical features, response to treatment, and survival. Cancer 1975; 36: 842–54.

[3] Greipp PR, San Miguel J, Durie BG *et al*. International staging system for myeloma. J Clin Oncol 2005; 23: 3412–20.

[4] Facon T, Avel-Loiseau H, Guillarin G *et al*. Intergroupe Francophone du Myeloma. Chromosome 13 abnormalities identified by FISH analysis and serum B2 microglobulin produce a powerful myeloma staging system for patients receiving high dose therapy. Blood 2001; 97: 1566–71.

[5] Durie BGM, Kyle RA, Belch A *et al*. Myeloma management guidelines, a consensus report from the Scientific Advisors of the International Myeloma Foundation. Haematol J 2003; 4: 379–98.

[6] UK Myeloma Forum. The diagnosis and management of multiple myeloma. Br J Haematol 2001; 115: 522–40.

[7] Sirohi B, Powles R. Multiple myeloma. Lancet 2004; 363: 875–87.

[8] Barlogie B, Shaughnessy J, Tricot G *et al*. Treatment of multiple myeloma. Blood 2004; 103: 20–32.

[9] Barlogie B, Zangari M, Spencer T *et al*. Thalidomide in the management of multiple myeloma. Semin Hematol 2001; 38: 250–9.

[10] Harousseau JL, Shaughnessy Jr J, Richardson P. Multiple myeloma. Hematology (Am Soc Hematol Educ Program) 2004; 237–56.

[11] Bruno B, Rotta M, Giaccone L. New drugs for treatment of multiple myeloma. Lancet Oncol 2004; 5: 1–16.

[12] Morgan GJ, Davies FE. Evolving treatment strategies for myeloma. Br J Cancer 2005; 92: 217–21.

[13] Cotten A, Dewatre F, Cortet B *et al*. Percutaneous vertebroplasty for osteolytic metastases and myeloma: effects of the percentage of lesion filling and the leakage of methyl methacrylate at clinical follow-up. Radiology 1996; 200: 525–30.

[14] Theodorou DJ, Theodorou SJ, Sartoris DJ. Treatment of osteoporosis: current status and recent advances. Compr Ther 2002; 28: 109–22.

[15] Dudeney S, Lieberman IH, Reinhardt MK, Hussein M. Kyphoplasty in the treatment of osteolytic vertebral compression fractures as a result of multiple myeloma. J Clin Oncol 2002; 20: 2382–7.

[16] Conte P, Coleman R. Bisphosphonates in the treatment of skeletal metastases. Semin Oncol 2004; 31: 59–63.

[17] Lipton A. Pathophysiology of bone metastases: how this knowledge may lead to therapeutic intervention. J Support Oncol 2004; 2: 205–13 (discussion 213–4, 216–7, 219–20).

[18] Kanis JA, McCloskey EV. Bisphosphonates in multiple myeloma. Cancer 2000; 88: 3022–32.

[19] Theriault RL, Hortobagyi GN. The evolving role of bisphosphonates. Semin Oncol 2001; 28: 284–90.

[20] Berenson JR, Hillner BE, Kyle RA *et al*. American Society of Clinical Oncology clinical practice guidelines: the role of bisphosphonates in multiple myeloma. J Clin Oncol 2002; 20: 3719–36.

[21] Durie BGM, Jacobson J, Barlogie B, Crowley J. Magnitude of response with myeloma frontline therapy does not predict outcome: importance of time to progression in Southwest Oncology Group Chemotherapy Trials. J Clin Oncol 2004; 22: 1857–63.

[22] Barlogie B, Jagannath S, Vesole DH *et al*. Superiority of tandem autologous transplantation over standard therapy for previously untreated multiple myeloma. Blood 1997; 89: 789–93.

[23] Zaidi AA, Vesole DH. Multiple myeloma: an old disease with new hope for the future. CA: Cancer J Clin 2001; 51: 273–85.

[24] Burton CH, Fairham SA, Millet B, DasGupta R, Sivakumaran M. Unusual aetiology of persistent back pain in a patient with multiple myeloma: infectious discitis. J Clin Pathol 1998; 51: 633–4.

[25] Tung GA, Rogg JM. Diffusion-weighted imaging of cerebritis. AJNR Am J Neuroradiol 2003; 24: 1110–3.

[26] Desikan R, Barlogie B, Sawyer J *et al*. Results of high-dose therapy for 1000 patients with multiple myeloma: durable complete remissions and superior survival in the absence of chromosome 13 abnormalities. Blood 2000; 95: 4008–10.

[27] Bucher E, Trampuz A, Donati L, Zimmerli W. Spondylodiscitis associated with bacteraemia due to coagulase-negative staphylococci. Eur J Clin Microbiol Infect Dis 2000; 19: 118–20.

[28] Chew FS, Kline MJ. Diagnostic yield of CT-guided percutaneous aspiration procedures in suspected spontaneous infectious diskitis. Radiology 2001; 218: 211–4.

[29] Williams L, Beveridge RA, Rifkin RM *et al*. Increased pulmonary toxicity results from a 1-day versus 2-day

schedule of administration of high-dose melphalan. Biol Blood Marrow Transplant 2002; 8: 334–5.
[30] Srkalovic G, Elson P, Trebisky B, Karam MA, Hussein MA. Use of melphalan, thalidomide, and dexamethasone in treatment of refractory and relapsed multiple myeloma. Med Oncol 2002; 19: 219–26.
[31] Palumbo A, Bringhen S, Bertola A *et al*. Multiple myeloma: comparison of two dose-intensive melphalan regimens (100 versus 200 mg/m(2)). Leukemia 2004; 18: 133–8.
[32] Carlson K, Hjorth M, Knudsen LM. Toxicity in standard melphalan-prednisone therapy among myeloma patients with renal failure—a retrospective analysis and recommendations for dose adjustment. Br J Haematol 2005; 128: 631–5.
[33] Osman K, Comenzo R, Rajkumar SV. Deep venous thrombosis and thalidomide therapy for multiple myeloma. N Engl J Med 2001; 344: 1951–2.
[34] Rajkumar SV. Thalidomide: tragic past and promising future. Mayo Clin Proc 2004; 79: 899–903.
[35] Onozawa M, Hashino S, Sogabe S *et al*. Side effects and good effects from new chemotherapeutic agents. Case 2. Thalidomide-induced interstitial pneumonitis. J Clin Oncol 2005; 23: 2425–6.
[36] Kyle RA, Rajkumar SV. Multiple myeloma. N Engl J Med 2004; 351: 1860–73.
[37] Lugassy G, Shaham R, Nemets A, Ben-Dor D, Nahlieli O. Severe osteomyelitis of the jaw in long-term survivors of multiple myeloma: a new clinical entity. Am J Med 2004; 117: 440–1.
[38] Vannucchi AM, Ficarra G, Antonioli E, Bosi A. Osteonecrosis of the jaw associated with zoledronate therapy in a patient with multiple myeloma. Br J Haematol 2005; 128: 738.
[39] Bensinger W, Buckner C, Anasetti C *et al*. Allogeneic marrow transplantation for multiple myeloma: an analysis of risk factors on outcome. Blood 1996; 88: 2787–93.
[40] Gahrton G. Progress in allogeneic haematopoietic stem cell transplantation for multiple myeloma. Bone Marrow Transplant 2000; 25 (suppl 1): S54.
[41] Aydin K, Donmez F, Tuzun U, Minareci O, Atamer T. Diffusion MR findings in cyclosporin-A induced encephalopathy. Neuroradiology 2004; 46: 822–4.
[42] Woo E, Yu Y, Ng M, Huang C, Todd D. Spinal cord compression in multiple myeloma. Who gets it? Aust NZ J Med 1986; 16: 671–5.
[43] Spiess JL, Adelstein DJ, Hines JD. Multiple myeloma presenting with spinal cord compression. Oncology 1988; 45: 88–92.
[44] Loughrey GJ, Collins CD, Todd SM, Brown NM, Johnson RJ. MRI in the management of suspected spinal canal disease in patients with known malignancy. Clin Radiol 2000; 55: 849–55.
[45] Kapadia SB. Multiple myeloma: a clinicopathologic study of 62 consecutively autopsied cases. Medicine (Baltimore) 1980; 59: 380–92.
[46] Angtuaco EJC, Fassas ABT, Walker R, Sethi R, Barlogie B. Multiple myeloma: clinical review and diagnostic imaging. Radiology 2004; 231: 11–23.
[47] Kyle R. Multiple myeloma: review of 869 cases. Mayo Clin Proc 1975; 50: 29–40.
[48] Subramanyam BR. Renal amyloidosis in juvenile rheumatoid arthritis: sonographic features. AJR Am J Roentgenol 1981; 136: 411–2.
[49] Hawkins P. Serum amyloid P component scintigraphy for diagnosis and monitoring amyloidosis. Curr Opin Nephrol Hypertension 2002; 11: 649–55.
[50] Moulopoulos LA, Dimopoulos MA, Smith TL *et al*. Prognostic significance of magnetic resonance imaging in patients with asymptomatic multiple myeloma. J Clin Oncol 1995; 13: 251–6.
[51] Mariette X, Zagdanski AM, Guermazi A *et al*. Prognostic value of vertebral lesions detected by magnetic resonance imaging in patients with stage I multiple myeloma. Br J Haematol 1999; 104: 723–9.
[52] Helms CA, Genant H. Computed tomography in the early detection of skeletal involvement with multiple myeloma. JAMA 1982; 248: 2886–7.
[53] Mahnken AH, Wildberger JE, Gehbauer G *et al*. Multidetector CT of the spine in multiple myeloma: comparison with MR imaging and radiography. Am J Roentgenol 2002; 178: 1429–36.
[54] Horger M, Claussen CD, Bross-Bach U *et al*. Whole-body low-dose multidetector row-CT in the diagnosis of multiple myeloma: an alternative to conventional radiography. Eur J Radiol 2005; 54: 289–97.
[55] Dimopoulos MA, Moulopoulos LA, Datseris I *et al*. Imaging of myeloma bone disease. Acta Oncol 2000; 39: 823–7.
[56] Lecouvet FE, Vande Berg BC, Malghem J, Maldague BE. Magnetic resonance and computed tomography imaging in multiple myeloma. Semin Musculoskelet Radiol 2001; 5: 43–55.
[57] Collins CD. Multiple myeloma. Cancer Imaging 2004; 4: 47–53.
[58] Cuenod CA, Laredo JD, Chevret S *et al*. Acute vertebral collapse due to osteoporosis or malignancy: appearances on unenhanced and gadolinium-enhanced MR images. Radiology 1996; 199: 541–9.
[59] Uetani M, Hashmi R, Hayashi K. Malignant and benign compression fractures: differentiation and diagnostic pitfalls on MRI. Clin Radiol 2004; 59: 124–31.
[60] Lecouvet FE, Vande Berg BC, Maldague BE *et al*. Vertebral compression fractures in multiple myeloma. Part I. Distribution and appearance at MR imaging. Radiology 1997; 204: 195–9.
[61] Baur A, Stabler A, Bruning R *et al*. Diffusion weighted MR imaging of bone marrow: differentiation of benign versus pathologic compression fractures. Radiology 1998; 207: 349–56.
[62] Moulopoulos LA, Dimopoulos MA, Alexanian R, Leeds NE, Libshitz HI. MR patterns of response to treatment. Radiology 1994; 193: 441–6.
[63] Lecouvet FE, Malghem J, Michaux L *et al*. Vertebral compression fractures in multiple myeloma. Part II. Assessment of fracture risk with MR imaging of spinal bone marrow. Radiology 1997; 204: 201–5.
[64] Rahmouni A, Divine M, Mathieu D *et al*. MR appearance of multiple myeloma of the spine before and after treatment. Am J Roentgenol 1993; 160: 1053–7.
[65] Lecouvet FE, De Nayer P, Garber C *et al*. Treated plasma cell lesions of bone with MRI signs of response to treatment: unexpected pathological findings. Skeletal

Radiol 1998; 27.

[66] Lecouvet FE, Richard F, Vande Berg BC *et al*. Long term effects of localised spinal radiation therapy on vertebral fractures and focal lesions: appearance in patients with multiple myeloma. Br J Haematol 1997; 96: 743–5.

[67] Lecouvet FE, Vande Berg BC, Michaux L *et al*. Stage III multiple myeloma: clinical and prognostic value of spinal bone marrow MR imaging. Radiology 1998; 209: 653–60.

[68] Agren B, Reidberg U, Isberg B, Svensson L, Aspelin P. MR imaging of multiple myeloma patients with bone marrow transplants. Acta Radiol 1998; 39: 36–42.

[69] Lecouvet FE, Dechambre S, Malghem J, Ferrant A, Vande Berg BC, Maldague B. Bone marrow transplantation in patients with multiple myeloma: prognostic significance of MR imaging. Am J Roentgenol 2001; 176: 91–6.

[70] Lecouvet FE, Malghem J, Michaux L *et al*. Skeletal survey in multiple myeloma: radiographic versus MR imaging survey. Br J Haematol 1999; 106: 35–9.

[71] Fassas AB, Muwalla F, Berryman T *et al*. Myeloma of the central nervous system: association with high-risk chromosomal abnormalities, plasmablastic morphology and extramedullary manifestations. Br J Haematol 2002; 117: 103–8.

[72] Moulopoulos LA, Dimopoulos MA, Weber D, Fuller L, Libshitz HI, Alexanian R. Magnetic resonance imaging in the staging of solitary plasmacytoma of bone. J Clin Oncol 1993; 11: 1311–5.

[73] Sezer O, Niemoller K, Jakob C *et al*. Relationship between bone marrow angiogenesis and plasma cell infiltration and serum beta 2 microglobulin levels in patients with multiple myeloma. Ann Haematol 2001; 80: 598–601.

[74] Bataille R, Chevalier J, Rossi M, Sany J. Bone scintigraphy in plasma-cell myeloma. A prospective study of 70 patients. Radiology 1982; 145: 801–4.

[75] Catalano L, Pace L, Califano C *et al*. Detection of focal myeloma lesions by Tc-99m sestaMIBI scintigraphy. Haematologica 1999; 84: 119–24.

[76] Fonti R, Del Vecchio S, Zannetti A *et al*. Bone marrow uptake of Tc-99m MIBI in patients with multiple myeloma. Eur J Nucl Med 2001; 25: 714–20.

[77] Alexandrakis MG, Kyriakou DS, Passam F, Koukouraki S, Karkavitsas N. Value of Tc-99m sestamibi scintigraphy in the detection of bone lesions in multiple myeloma. Ann Haematol 2001; 80: 349–63.

[78] Alper E, Gurel M, Evrensel T, Ozkocaman V, Akbunar T, Demiray M. 99mTc-MIBI scintigraphy in untreated stage III multiple myeloma: comparison with X-ray skeletal survey and bone scintigraphy. Nucl Med Commun 2003; 24: 537–42.

[79] Pace L, Catalano L, Pinto AM *et al*. Different patterns of technetium 99m-sestamibi uptake in multiple myeloma. Eur J Nucl Med 1998; 25: 714–20.

[80] Pace L, Catalano L, Del Vecchio S *et al*. Predictive value of technetium-99m sestamibi in patients with multiple myeloma and potential role in follow-up. Eur J Nucl Med 2001; 28: 304–12.

[81] Pace L, Del Vecchio S, Salvatore M. Technetium 99m sestamibi in multiple myeloma. Radiology 2005; 234: 312–3.

[82] Schirrmeister H, Bommer L, Buck AK *et al*. Initial results in the assessment of multiple myeloma using 18F-FDG PET. Eur J Nucl Med Mol Imaging 2002; 29: 361–6.

[83] Jadvar H, Conti PS. Diagnostic utility of FDG PET in multiple myeloma. Skeletal Radiol 2002; 31: 690–4.

[84] Durie BGM, Waxman AD, D'Agnolo A, Williams CM. Whole body 18F-FDG PET identifies high risk myeloma. J Nucl Med 2002; 43: 1457–63.

[85] Orchard K, Barrington S, Buscombe J, Hilson A, Prentice HG, Mehta A. Fluorodeoxyglucose positron emission tomography imaging for the detection of occult disease in multiple myeloma. Br J Haematol 2002; 117: 133–5.

[86] Bredella MA, Steinbach L, Caputo G, Segall G, Hawkins R. Value of FDG PET in the assessment of patients with multiple myeloma. Am J Roentgenol 2005; 184: 1199–204.

[87] Kato T, Tsukamoto E, Nishioka T *et al*. Early detection of bone marrow involvement in extramedullary plasmacytoma by whole-body F-18 FDG positron emission tomography. Clin Nucl Med 2000; 25: 870–3.

[88] Patlas M, Hadas-Halpern I, Libson E. Imaging findings of extraosseous multiple myeloma. Cancer Imaging 2002; 2: 120–2.

[89] Mileshkin L, Blum R, Seymour JF, Patrikeos A, Hicks RJ, Prince HM. A comparison of fluorine-18 fluoro-deoxyglucose PET and technetium-99m sestamibi in assessing patients with multiple myeloma. Eur J Haematol 2004; 72: 32–7.