

recommend that the PaO<sub>2</sub> should be checked about two hours after starting the first period of therapy and the flow rate adjusted accordingly. Follow-up of patients for up to two years has shown that they are still asymptomatic and free of disease (P. Forgacs, personal communication).

For many years the aetiology of pneumatosis coli has been a matter for debate. The introduction of oxygen as a successful form of therapy leads us to suggest that the cysts are created and maintained by a fastidious anaerobic gas-forming organism which produces gas at a rate which exceeds the rate of absorption until an equilibrium is reached. The high tissue PaO<sub>2</sub> achieved with oxygen therapy kills the organisms and the gas is then reabsorbed in the same way as gas contained within any natural or artificially created space in the body. Hence, the cysts do not recur. We are currently undertaking studies with the electron microscope in an attempt to substantiate this hypothesis.

We thank Mr. J. O. Robinson for permission to report this case and Dr. A. G. Stansfield, Mr. P. Crocker, and Mrs. P. Tisbury for their help and encouragement in the preparation of this paper.

### References

- Forgacs, P., Wright, P. H., and Wyatt, A. P. (1973). *Lancet*, 1, 579.  
 Hughes, D. T. D., et al. (1966). *Gut*, 7, 553.  
 Kenny, J. G. (1963). *Clinical Radiology*, 14, 71.  
 Leigh, J. M. (1970). *Anaesthesia*, 25, 210.  
 Morson, B. C., and Dawson, I. P. (1972). *Gastrointestinal Pathology*, p. 691. Oxford, Blackwell Scientific.  
 O'Reilly, K. (1973). *Australian and New Zealand Journal of Surgery*, 43, 144.  
 Pemberton, H. W., Smith, W. G., and Holman, C. B. (1957). *American Journal of Surgery*, 94, 472.  
 Pratt, P. C. (1965). *Annals of the New York Academy of Sciences*, 121, 809.  
 Smith, W. G., Anderson, M. J., and Pemberton, H. W. (1958). *Gastroenterology*, 35, 528.  
 Varno, V. J., and Bonnano, C. A. (1973). *American Journal of Gastroenterology*, 59, 353.  
 Wyatt, A. P. (1972). *Proceedings of the Royal Society of Medicine*, 65, 780.

## Acute Disseminated Encephalomyelitis in Typhoid Fever

S. RAMACHANDRAN, H. R. WICKREMESINGHE,  
M. V. F. PERERA

*British Medical Journal*, 1975, 1, 494-495

Encephalopathy with focal neurological signs and altered consciousness is a rare complication of typhoid fever and carries a high mortality (Roger and Gastaut, 1945; Pohowalla and Ghai, 1957; Zellweger and Idriss, 1960; Aita, 1972). The pathological changes in the brains of such patients, however, are poorly documented in the literature.

We report a case of symptomatic typhoid fever in which encephalopathy with clinical features of brain-stem involvement was found to be due to acute disseminated encephalomyelitis (perivenous demyelinating leucoencephalitis) of the midbrain and pons.

### Case Report

A 25-year-old man was admitted to hospital with intermittent fever of one month's duration. A clinical diagnosis of typhoid fever was made. There was a good response to co-trimoxazole with disappearance of the toxæmia and abdominal signs. Widal's reaction with *Salmonella typhi* H gave a titre of 1/250, O-negative, and with *S. paratyphi* A-H 1/50. Blood culture was sterile.

On the 11th day the fever returned with mild toxæmia and confusion. The patient appeared ill and blood culture grew *S. typhi*. Widal's reaction remained unaltered. The fever and toxæmia subsided over the next 48 to 72 hours and there was clinical improvement. Next day, however, he rapidly lapsed into deep coma with fixed, semi-dilated pupils, tachycardia, hyperpnoea, quadriplegia, and spasticity of all four limbs with exaggerated reflexes and bilateral extensor plantar responses. There were intermittent spasms of extensor rigidity and clonic fits in the arms. A clinical diagnosis of typhoid encephalopathy was made and he was given dexamethasone, hydrocortisone, hypertonic dextrose, and intramuscular chloramphenicol. The ocular fundi were normal. The C.S.F. was clear and not under tension and contained sugar

3 mmol/l (54 mg/100 ml), protein 0.25 g/l, and chloride 1040 mmol (mEq) and had a cell count of  $2 \times 10^6$  lymphocytes per l. C.S.F. culture was sterile and the Widal reaction remained unaltered. During the next seven hours he developed an axillary temperature of 38°C and his pupils became small and non-reacting. The tachycardia persisted and over the next few hours he ran a temperature of 41.1°C and had stertorous breathing. He died within 24 hours of the onset of the neurological manifestations.

Necropsy, five hours after death, showed congestion and superficial ulceration of the terminal 20 to 25 cm of the ileum with enlargement of the mesenteric lymph nodes. The spleen was not enlarged and the brain appeared normal. Histologically there was thinning of the mucosa of the terminal ileum with loss of villi and partial loss of glands. There was congestion of the submucosal vessels and cellular infiltration of the submucosa by lymphocytes. The mesenteric lymph nodes showed a marked histiocytic cellular proliferation in the subcapsular, cortical, and medullary sinuses with generalized congestion, as is characteristically seen in typhoid fever. In the brain the lesions were confined to the midbrain and pons. There was demyelination in an eccentric zone around the small vessels and microglial cells with pleomorphic nuclei surrounding the veins. Perivascular cuffing of small vessels by lymphocytes was seen. The appearance was of an acute disseminated encephalomyelitis with demyelination of the midbrain and pons (figs. 1 and 2).

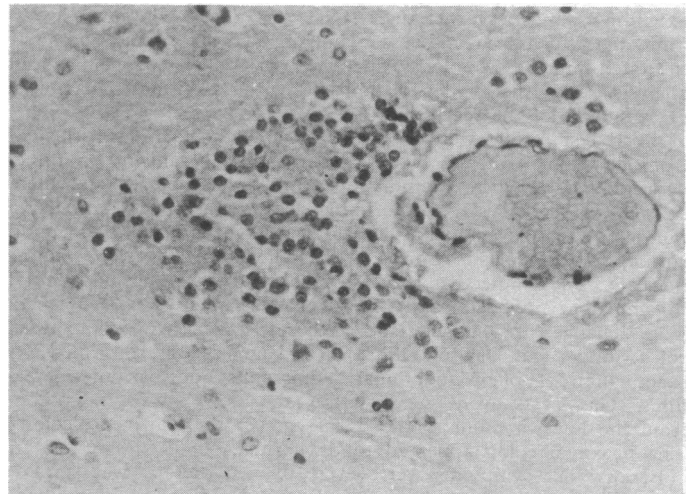


FIG. 1—Histological section of brain showing dense eccentric infiltration by phagocytic cells to left of a venous channel. (H. and E.  $\times 350$ .)

### Comment

The pathological process in the brain causing typhoid encephalopathy in this patient was an acute disseminated encephalomyelitis characteristically observed in viral infections such as chickenpox, mumps, and measles and after prophylactic

Colombo North General Hospital, Ragama, Sri Lanka

S. RAMACHANDRAN, M.D., M.R.C.P., Physician  
M. V. F. PERERA, M.B., M.R.C.P., Pathologist

Colombo General Hospital, Colombo 8, Sri Lanka

H. R. WICKREMESINGHE, M.B., D.PATH., Neuropathologist

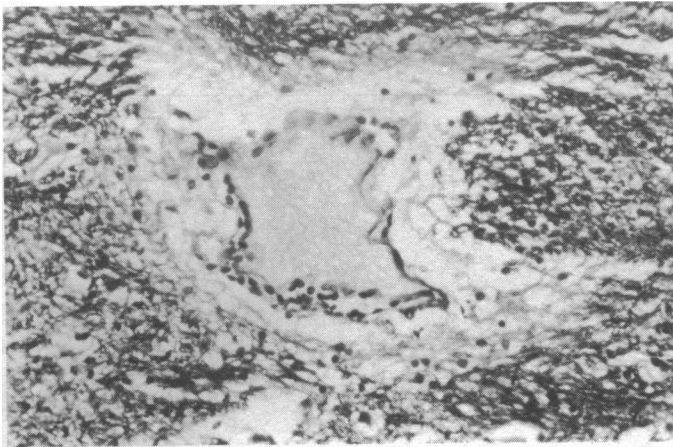


FIG. 2—Histological section of brain showing perivenous demyelination with cellular infiltration. (Loyez myelin preparation.  $\square \times 350$ ).

vaccination against smallpox (Brain and Walton, 1969). This type of lesion when due to viral infections and prophylactic vaccination appears to have an allergic basis (Miller *et al.*, 1956; Greenfield and Norman, 1963). There is evidence that the inflammatory reaction with oedema and perivascular cuffing results from a combination of Coombs's type 2, 3, and 4 reactions (Webb, 1969). Peripheral neuropathy, probably of an allergic origin, has been documented after preventive inoculation against typhoid fever (Greenfield and Norman, 1963). Thus the acute encephalomyelitis in this patient, like the occurrence of a Guillain-Barré syndrome as a complication of typhoid fever (Chanmugam and Waniganetti, 1969), probably

resulted from an allergic process in the nervous system due to infection with *S. typhi*.

Studies on viral encephalitis have indicated that severe viraemia and the late appearance of antibodies, resulting in an excess of antigen over antibody, may be of importance in the pathogenesis of the disease (Webb, 1969). Interestingly our patient had a septicaemia late in the course of his clinical illness with a poor antibody response.

Though metabolic disturbances, toxæmia, hyperpyrexia, vitamin deficiency, and non-specific cerebral changes such as oedema and vascular lesions have been postulated as the pathogenesis of the neurological complications in typhoid fever (Wilson and Bruce, 1954; Aita, 1972) there appears to be little doubt that in some cases acute disseminated encephalomyelitis could be the cause. The present case also illustrates that bacterial infections, like viral infections, can produce neurological manifestations due to the occurrence of an acute disseminated encephalomyelitis.

## References

- Aita, J. A. (1972). *Neurologic Manifestations of General Diseases*, 2nd edn. Springfield, Illinois, Thomas.
- Brain, R., and Walton, J. N. (1969). *Brain's Diseases of the Nervous System*, 7th edn. London, Oxford University Press.
- Chanmugam, D., and Waniganetti, A. (1969). *British Medical Journal*, 1, 95.
- Greenfield, J. G., and Norman, R. M. (1963). *Greenfield's Neuropathology*, 2nd edn. London, Arnold.
- Miller, H. G., Stanton, J. B., and Gibbons, J. L. (1956). *Quarterly Journal of Medicine*, 25, 427.
- Pohowalla, J. N., and Ghai, O. P. (1957). *Indian Journal of Pediatrics*, 24, 137.
- Roger, H., and Gastaut, H. (1945). Cited by Zellweger and Idriss (1960).
- Webb, H. E. (1969). In *Fifth Symposium on Advanced Medicine*, Royal College of Physicians of London, ed. R. Williams, p. 307. London, Pitman.
- Wilson, K. S. A., and Bruce, N. K. (1954). *Neurology*, vol. 1. London, Butterworth.
- Zellweger, H., and Idriss, H. (1960). *American Journal of Diseases of Children*, 99, 770.

## Hypofibrinogenaemia as a Cause of Bleeding in Chronic Myeloid Leukaemia

J. A. WHITTAKER, M. KHURSHID

*British Medical Journal*, 1975, 1, 495-496

Hypofibrinogenaemia is an occasional, well-documented complication of acute leukaemia (Rosenthal, 1963; Didisheim *et al.*, 1964; Hirsh *et al.*, 1967; Rand *et al.*, 1969; Goldman, 1974) and is seen most characteristically in patients with acute promyelocytic leukaemia. Excessive fibrinolysis was originally postulated as a cause of hypofibrinogenaemia but recent evidence has shown that fibrinogen utilization is secondarily increased as part of the process of disseminated intravascular coagulation.

We report here the first example of hypofibrinogenaemia secondary to chronic myeloid leukaemia.

### Methods

Standard haematological investigations were carried out using a Coulter S electronic blood cell counter or by the methods of

Dacie and Lewis (1968). Additional coagulation tests included estimation of the kaolin cephalin clotting time (Proctor and Rapaport, 1961), factor V assay (Kappeler, 1955), factor VIII assay (Pool and Robinson, 1959), fibrinogen titre and fibrinolysis estimation (Sharp *et al.*, 1958), and assay of fibrinogen degradation products (Pitcher, 1971). Studies of fibrinogen turnover using  $^{125}\text{I}$ -labelled fibrinogen were performed by the method of Jeyasingh *et al.* (1970).

Platelet aggregation studies were performed by the method of Born (1962) using adenosine diphosphate (ADP) at a final concentration of 5 mg/l, adrenaline at 5 mg/l, and thrombin at 500 U/l. Collagen was prepared by extracting 750 mg equine collagen (Sigma Chemicals Ltd.) with 10 ml 0.15M sodium chloride. A 0.1-ml sample of the extract was added to 1 ml platelet-rich plasma.

The Philadelphia chromosome was identified by using the method of Woodliff (1971).

### Case History

A 69-year-old woman was admitted to this hospital in January 1973 complaining of spontaneous skin bruising and nose bleeds for eight weeks. Examination showed massive confluent bruising over her abdomen, chest, back, and limbs with multiple bilateral flame-shaped fundal haemorrhages. The liver was palpable 6 cm below the right costal margin and the spleen was enlarged 22 cm from the left costal margin. Her temperature was normal and there were no signs of infection. Haemoglobin concentration was 5.7 g/dl, W.B.C.  $216 \times 10^9/l$ . (polymorphs 51%, basophils 8%, metamyelocytes 8%, myelocytes 17%, promyelocytes 7%, myeloblasts 2%), and platelet count  $490 \times 10^9/l$ . Bone marrow aspiration showed a cellular marrow with an excess of myelocytes and metamyelocytes but without an excess of myeloblasts (< 5%). Myeloblasts were negative for periodic-acid Schiff and Sudan black and contained no Auer rods. Promyelocytes (8%) were present in slight excess and most showed heavy cytoplasmic granulation. The Philadelphia

Department of Haematology, University Hospital of Wales and Welsh National School of Medicine, Cardiff CF4 4XW

J. A. WHITTAKER, M.D., M.R.C.P., Senior Lecturer and Honorary Consultant  
M. KHURSHID, M.B., M.R.C.PATH., Senior Registrar