

hydroxyproline excretion and change of treatment on clinical grounds.

In the two hypercalcaemic patients hydroxyproline excretion changed rapidly in parallel with changes in serum calcium. This suggests that the test was monitoring changes in bone destruction in relation to tumour treatment and encourages the hypothesis that estimation of hydroxyproline excretion in the first few days of therapy may be useful for early detection of hormone-sensitive tumours and early prediction of response to therapy.

We thank Dr. J. W. Baker Dr. H. T. Ford Mr. J. C. Gazet Mr. A. McKinna, and Mr. A. York Mason for their very close clinical co-operation with the department of medicine which made it possible for these patients to be studied.

This study was supported by the Ludwig Institute of Cancer Research and the Medical Research Council.

## References

- <sup>1</sup> Cuschieri, A., *British Journal of Surgery*, 1973, 60, 800.
- <sup>2</sup> Sumner, D. S., *et al.*, *British Journal of Surgery*, 1973, 60, 306.
- <sup>3</sup> Dull, T. A., and Henneman, P. H., *New England Journal of Medicine*, 1963, 268, 132.
- <sup>4</sup> Lindstedt, S., and Prockop, D. J., *Journal of Biological Chemistry*, 1961, 236, 1399.
- <sup>5</sup> Prockop, D. J., *Journal of Clinical Investigation*, 1964, 43, 453.
- <sup>6</sup> Powles, T. J., *et al.*, *British Journal of Cancer*, 1973, 28, 316.
- <sup>7</sup> Prockop, D. J., and Udenfriend, S. A., *Analytical Biochemistry*, 1960, 1, 228.
- <sup>8</sup> Katz, F. H., and Kappas, A., *Journal of Laboratory and Clinical Medicine*, 1968, 71, 65.
- <sup>9</sup> Ziff, M., *et al.*, *Journal of Clinical Investigation*, 1956, 35, 579.

# Occult Pulmonary Haemorrhage in Leukaemia

DAVID W. GOLDE, W. LAWRENCE DREW, HARVEY Z. KLEIN, THEODORE N. FINLEY, MARTIN J. CLINE

*British Medical Journal*, 1975, 2, 166-168

## Summary

**Though bleeding into the lung parenchyma is responsible for morbidity and mortality in patients with leukaemia pulmonary haemorrhage is seldom diagnosed during life. We diagnosed occult pulmonary haemorrhage in five leukaemic patients with unexplained infiltrates on chest roentgenograms by examining alveolar macrophages retrieved by bronchopulmonary lavage. Macrophage haemosiderin content was greatly increased in the patients with pulmonary haemorrhage as compared to normal and thrombocytopenic control subjects. Haemoglobin and intact erythrocytes in alveolar macrophages were taken as evidence of recent haemorrhage. Intrapulmonary bleeding may occur often in patients with leukaemia, and bronchopulmonary lavage offers a safe approach to diagnosis and allows for concomitant identification of pulmonary infection.**

## Introduction

In patients with leukaemia pulmonary infiltrates visible on chest roentgenograms are often difficult to evaluate. Infection, particularly by "opportunistic pathogens," is a common cause of pulmonary disease in leukaemic patients,<sup>1-3</sup> and leukaemic infiltration of the lung parenchyma is often considered in making a diagnosis.<sup>2</sup> Pulmonary haemorrhage associated with thrombocytopenia, however, is not often diagnosed clinically and the possibility of uncontrolled bleeding makes invasive diagnostic procedures such as lung biopsy and bronchial brushing hazardous.<sup>4-5</sup>

We describe here five leukaemic patients with unexplained pulmonary infiltrates on their chest films in whom intrapulmonary haemorrhage was diagnosed.

## Patients

**Case 1.**—A 12-year-old black boy with acute myelogenous leukaemia presented with anaemia, bleeding of the gums, and profound thrombocytopenia. He was treated with a combination of cyclophosphamide, vincristine, cytarabine, and prednisone (COAP),<sup>6</sup> then daunorubicin. A partial remission was achieved and he remained at home until he was readmitted for a nonproductive cough and fever. A chest roentgenogram showed a right basilar infiltrate. Haemoglobin was 5.5 g/dl and the platelets  $5 \times 10^9/l$ . A sputum culture grew normal oral flora. He was given red-cell and platelet transfusions and treated with a combination of cephalothin, gentamicin, and cleomycin. The chest film showed gradual clearing of the right lower lobe process over the next few days. On the seventh day in hospital, however, new infiltrates appeared in both upper lobes. Pulmonary lavage was performed. The lavage fluid was grossly bloody and no infectious agent was identified on direct smear or by culture. The pulmonary infiltrates subsequently cleared without further antibiotic treatment. One month later the patient died with diffuse bleeding and fulminant leukaemia.

**Case 2.**—A 54-year-old man with acute myelogenous leukaemia was initially treated with COAP and then with cytarabine, thioguanine, and daunorubicin. His remission was short-lived. He developed fever and petechial haemorrhages of the skin, and diffuse nodular infiltrates were seen on a chest film. The platelet count was  $14 \times 10^9/l$ . There was no haemoptysis. Pulmonary lavage was performed and a non-pathogenic fungus, thought to be a contaminant, was cultured from the blood-tinged lavage fluid.

**Case 3.**—A 50-year-old woman with acute myelogenous leukaemia achieved a remission with COAP therapy. The disease subsequently relapsed and was treated with thioguanine. During treatment the patient became febrile and was severely leucopenic and thrombocytopenic. Diffuse bilateral nodular infiltrates were seen on a chest roentgenogram and pulmonary lavage was performed. The lavage fluid was pink and sterile on culture. The patient subsequently died with uncontrolled leukaemia, bleeding, and staphylococcal septicaemia.

**Case 4.**—A 12-year-old Latin American boy with acute myelogenous leukaemia was treated initially with COAP, then daunorubicin, and later cytarabine and thioguanine. A remission was not achieved. Pulmonary lavage was performed to evaluate a persistent pulmonary infiltrate. At this time the patient had uncontrolled leukaemia with a peripheral white count of  $176 \times 10^9/l$ . *Bacillus cereus* was cultured from the bloody lavage fluid, but this was thought to be a contaminant. The patient was maintained on antibiotics and treated with platelet

Division of Haematology and Oncology, U.C.L.A. School of Medicine, Los Angeles, California, U.S.A.

DAVID W. GOLDE, M.D., F.A.C.P., Assistant Professor of Medicine  
MARTIN J. CLINE, M.D., F.A.C.P., Bowyer Professor of Medical Oncology

Mount Zion Hospital, San Francisco, California, U.S.A.

W. LAWRENCE DREW, M.D., PH.D., Director of Clinical Microbiology  
HARVEY Z. KLEIN, M.D., Director of Tissue Pathology  
THEODORE N. FINLEY, M.D., Professor of Medicine

transfusions because of bleeding into the skin and gums. The pulmonary infiltrates persisted for several weeks and then resolved.

**Case 5.**—A 66-year-old man with chronic lymphocytic leukaemia was under treatment with cyclophosphamide, prednisone, and vincristine. He had been admitted to hospital twice before for anaemia, fever, and pulmonary infiltrates. Extensive investigation, including fiberoptic bronchoscopy and bronchial brush biopsy, failed to show a cause for the pulmonary findings. The chest roentgenographic abnormalities resolved spontaneously, but he was readmitted six months later because of cough, fever, and bilateral lower lobe infiltrates. The haemoglobin was 8.3 g/dl, platelets  $83 \times 10^9/l$ , and white cell count  $99 \times 10^9/l$  with mostly lymphoid cells. He was treated empirically with antibiotics but respiratory distress increased. Bronchopulmonary lavage was performed with the catheter in the left lower lobe. The bloody lavage fluid was sterile on culture and no opportunistic organisms were found. Subsequently, his condition deteriorated rapidly and he died with increasing pulmonary insufficiency.

Necropsy showed diffuse intra-alveolar haemorrhage in both lungs (fig. 1). There was no evidence of pulmonary vascular disease, significant heart disease, or pulmonary emboli. Special stains for fungi and *Pneumocystis carinii* were negative.

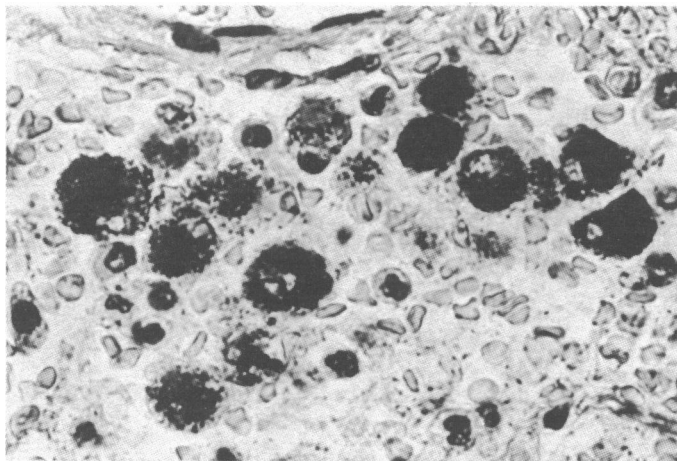


FIG. 1—Case 5. Section of lung at necropsy showing diffuse haemorrhage and macrophages filled with haemosiderin and haemoglobin.

## Methods and Results

Bronchopulmonary lavage was performed as described.<sup>7</sup> Aliquots of the lavage effluent were submitted for smears (Gram, acid-fast, and methenamine silver stains), wet mount, and viral, bacteriological, and fungal culture. Some of the fluid was processed for cytological and histological examination as described.<sup>4</sup> The remainder was centrifuged at 150 g for seven minutes. The cell pellet was resuspended in Hanks's balanced salt solution with 15% fetal calf serum.<sup>8</sup> Cytocentrifuge preparations (Shandon Inc.) were made and stained for haemosiderin with the ferrocyanide reagent<sup>9</sup> and for haemoglobin with benzidine. Differential counts were performed on Giemsa-stained slides. Macrophage identification was also based on electron microscopy, histochemical reaction for  $\alpha$ -naphthyl butyrase, and functional capacity including phagocytosis and tests for cell surface receptors for immunoglobulin.<sup>10 11</sup>

The haemosiderin content of pulmonary macrophages was measured as follows: 200–300 macrophages were counted, and each cell was graded for haemosiderin on a scale of 0–4: 0 = no blue colour, 1 = faint blue staining in cytoplasm, 2 = dense blue colour in minor portion of cytoplasm or medium colour intensity throughout cell, 3 = deep blue staining in most of cytoplasm, 4 = cell filled with haemosiderin; dark blue throughout cytoplasm. A mean score for 100 cells was calculated, zero being the minimum and 400 the maximum score.

Seven healthy volunteers, five of them cigarette smokers, served as controls. Two thrombocytopenic patients with leukaemia and lymphoma, in whom the diagnosis of *Pneumocystis carinii* pneumonia was made by bronchopulmonary lavage<sup>4</sup> were further controls.

As previously reported, macrophages were present and retrievable in the lavage fluid from the leukaemia patients.<sup>11</sup> Haemosiderin scores

## Pulmonary Macrophage Haemosiderin Scores

Case no.	1	2	3	4	5	Normal controls	Pneumonia controls
Score	75	178	165	210	230	11 ± 14 (S.E.)	0

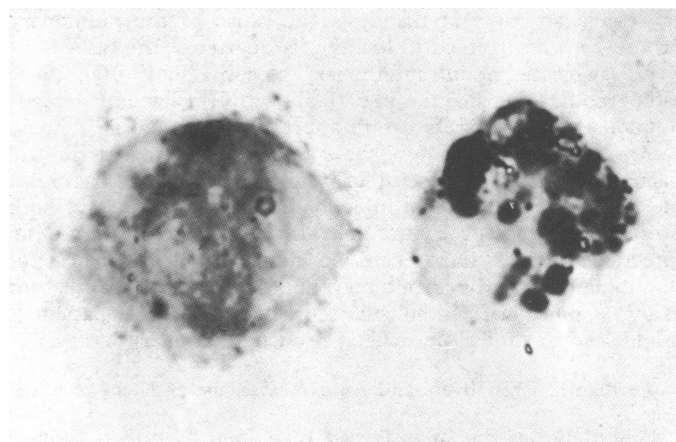


FIG. 2—Case 4. Macrophages retrieved by pulmonary lavage stained for haemosiderin. Left cell scored 2 and right cell 3. These macrophages also contained some free haemoglobin.

are given in the table. The haemosiderin content of the alveolar macrophages was greatly increased in the five leukaemic patients (fig. 2). Also, many of the cells contained haemoglobin which had not yet been degraded. A presumptive diagnosis of pulmonary haemorrhage was based on these findings.

## Discussion

Patients with leukaemia often develop pulmonary conditions which result in the appearance of infiltrates on chest roentgenograms. These patients are often febrile and have impaired immunological and microbicidal defense as well as considerable bleeding tendencies.<sup>1 3</sup> Gram-negative bacterial pneumonia, opportunistic fungal and viral disease, and *Pneumocystis carinii* infection may be present. It is usually necessary to identify the aetiological agent to give appropriate treatment. Diagnosis may require needle or open-lung biopsy or bronchial brushing, which may be dangerous in severely thrombocytopenic patients and are contraindicated when the suspected underlying condition is pulmonary haemorrhage.

We established the diagnosis of intrapulmonary bleeding in five patients by bronchopulmonary lavage. In one patient the diagnosis was confirmed at necropsy. The presence of blood in the lavage fluid was not in itself diagnostic as bleeding might have been related to the trauma of the procedure, and pulmonary haemorrhage was diagnosed more on the large increases in the haemosiderin content of alveolar macrophages. The macrophage is a highly phagocytic cell which rapidly ingests erythrocytes present in the alveolar spaces. Haemoglobin is then converted to haemosiderin in the phagocyte.

In one patient (case 1) the haemosiderin score was not greatly raised, but the pulmonary macrophages were filled with haemoglobin and intact red cells, which suggested that bleeding was quite recent and that there was insufficient time for release of stainable iron from haem. In the two patients with *Pneumocystis carinii* pneumonia and severe thrombocytopenia the macrophage haemosiderin was not increased.

Extensive haemorrhage into the lung has not often been reported in patients with leukaemia. In a review of 246 patients with leukaemia or lymphoma 15 cases of massive pulmonary haemorrhage were found.<sup>13</sup> These patients, like ours, did not show haemoptysis. Bodey *et al.*<sup>1</sup> found severe pulmonary haemorrhage in three out of 50 consecutive necropsied cases of

acute leukaemia, but some intrapulmonary bleeding was identified in half. They reported also that one-third of all fatal haemorrhages in leukaemia occurred in the lungs.<sup>13</sup> Leach<sup>14</sup> found that pulmonary haemorrhage was the direct cause of death in three out of 157 cases of acute leukaemia. Pulmonary infiltrates and associated symptoms were observed in over 30% of a large series of children with acute lymphocytic leukaemia. Despite aggressive attempts at diagnosis the cause of the pulmonary process was determined in less than a quarter of the cases.<sup>15</sup>

We suggest that intrapulmonary bleeding may often cause radiographic abnormalities in patients with leukaemia. Bronchopulmonary lavage offers a safe approach to diagnosis in these cases, and alveolar macrophage staining for haemosiderin and haemoglobin may be useful in determining whether a recent bleed has occurred. When infection and haemorrhage are both present the lavage procedure may also allow identification of an infectious agent. The technique may provide evidence for pulmonary haemorrhage but may not delineate the cause. For example, pulmonary embolism occurring in leukaemic patients<sup>16</sup> might lead to similar findings at bronchopulmonary lavage.

We thank Lisken Byers and Ann Sullivan for excellent technical help.

This study was supported in part by a grant from the California Lung Association, United States Public Health Service grant CA 15688, and a grant from Brown and Williamson Tobacco Corporation,

Philip Morris Incorporated, R. J. Reynolds Tobacco Company, U.S. Tobacco Company, and Tobacco Associates, Incorporated.

Requests for reprints should be addressed to Dr. David W. Golde.

## References

- <sup>1</sup> Bodey, G. P., *et al.*, *Cancer*, 1966, 19, 781.
- <sup>2</sup> Sickles, E. A., *et al.*, *Annals of Internal Medicine*, 1973, 79, 528.
- <sup>3</sup> Levine, A. S., *et al.*, *Seminars in Hematology*, 1974, 11, 141.
- <sup>4</sup> Drew, W. L., *et al.*, *Journal of the American Medical Association*, 1974, 230, 713.
- <sup>5</sup> Fennessy, J. J., and Kittle, C. F., *Journal of Thoracic and Cardiovascular Surgery*, 1973, 66, 541.
- <sup>6</sup> Whitecar, J. P., jun., *et al.*, *Cancer Chemotherapy Reports*, pt. I, 1972, 56, 543.
- <sup>7</sup> Finley, T. N., and Ladman, A. J., *New England Journal of Medicine*, 1972, 286, 223.
- <sup>8</sup> Golde, D. W., Finley, T. N., and Cline, M. J., *Lancet*, 1972, 2, 1397.
- <sup>9</sup> Bowling, M. C., *Histopathology Laboratory Procedures of the Pathologic Anatomy Branch of the National Cancer Institute*. Public Health Service Publication No. 1595, Washington, U.S. Government Printing Office, 1967.
- <sup>10</sup> Golde, D. W., Byers, L. A., and Finley, T. N., *Nature*, 1974, 247, 373.
- <sup>11</sup> Golde, D. W., Finley, T. N., and Cline, M. J., *New England Journal of Medicine*, 1974, 290, 875.
- <sup>12</sup> Blank, N., Castellino, R. A., and Shah, V., *Radiologic Clinics of North America*, 1973, 11, 175.
- <sup>13</sup> Hersh, E. M., *et al.*, *Journal of the American Medical Association*, 1965, 193, 105.
- <sup>14</sup> Leach, W. B., *Canadian Medical Association Journal*, 1961, 85, 345.
- <sup>15</sup> Siegel, S. E., Bachner, R., and Nesbit, M., *American Society of Hematology Seventeenth Annual Meeting*, 1974, Abstract no. 378, p. 171.
- <sup>16</sup> Wiernik, P. H., and Serpick, A. A., *Cancer*, 1969, 24, 581.

# Gastro-oesophageal Reflux Complicating Highly Selective Vagotomy

J. G. TEMPLE, JOHN MCFARLAND

*British Medical Journal*, 1975, 2, 168-169

## Summary

**An unacceptably high incidence of gastro-oesophageal reflux was observed in a small series of patients with duodenal ulcer who had been treated by highly selective vagotomy. Possibly this is due to an altered angle of entry of the oesophagus into the stomach, and we now routinely narrow this angle at operation.**

## Introduction

Highly selective vagotomy (H.S.V.) without drainage is rapidly gaining acceptance in the treatment of uncomplicated chronic duodenal ulceration. It is claimed that a more normal pattern of gastric emptying is preserved and that the incidence of post-vagotomy sequelae, such as dumping, diarrhoea, and bilious vomiting, is greatly reduced.<sup>1,2</sup> Furthermore, an exhaustive review<sup>3</sup> has shown that in the Leeds and Copenhagen series side effects, such as dysphagia, flatulence, and heartburn, were no more common after H.S.V. than after vagotomy with a drainage procedure.

We encountered severe and persistent oesophageal reflux in five of a small series of patients with chronic duodenal ulceration who were treated by H.S.V. without drainage in our unit.

## Patients and Methods

Twenty patients with chronic duodenal ulceration and no clinical or radiological evidence of pyloric stenosis, gastro-oesophageal reflux, or hiatus hernia underwent H.S.V. At operation the diagnosis was confirmed and pyloric stenosis and hiatus hernia excluded. All the operations were performed by one of us (J.M.). The surgical technique was standard,<sup>4</sup> the denervation being started at a point just to the left of the terminal branches of the nerves of Latarjet (6-7 cm from the pyloroduodenal junction). All the patients were followed up regularly for at least two years. Acid-output studies were performed before and three months after the operation. Interpretation of the insulin response was based on Hollander's<sup>5</sup> original criteria with the addition of a second one-hour collection period. The results were classified as negative, early positive (0-60 min), and late positive (60-120 min).

## Results

Though only 20 patients were treated in this pilot series we were disturbed to find that five developed persistent symptoms of gastro-oesophageal reflux. The typical features of gastro-oesophageal reflux—heartburn, retrosternal discomfort, and regurgitation, accompanied by increased flatulence—developed shortly after surgery in three of the patients and between six to 12 months after in the other two (see table). A postoperative barium meal examination showed gastro-oesophageal reflux in four of the patients, with evidence of a hiatus hernia in three. Though reflux could not be shown radiologically in the other patient a

Royal Southern Hospital, Liverpool L8 5SH

J. G. TEMPLE, M.B., F.R.C.S., Senior Registrar in Surgery (Present appointment: Senior Lecturer in Surgery, Manchester University, Hope Hospital, Salford)

J. B. MCFARLAND, CH.M., F.R.C.S., Consultant Surgeon