

Thallium poisoning

Diagnosis may be elusive but alopecia is the clue

Thallium is a heavy metal whose salts are used in some rodent poisons and in the manufacture of optical lenses, semiconductors, scintillation counters, low temperature thermometers and switching devices, green coloured fireworks, and imitation jewellery, and as chemical catalysts. In clinical practice thallium isotopes are used in cardiac scanning,^{1,2} but the use of thallium salts to treat scalp ringworm was abandoned earlier this century because of their toxicity. The sale of thallium in Britain is strictly licensed because of its toxicity and potential for use in murder, which is helped by the fact that thallosalts are colourless, tasteless, and odourless. The more water soluble salts (such as thallium sulphate, acetate, or carbonate) have higher toxicity, and although the toxic dose is variable most deaths occur after the ingestion of 10-15 mg/kg of soluble salt. Most cases of thallium toxicity occur after oral ingestion but severe toxicity has been reported after inhalation of contaminated dust from pyrite burners, in zinc and lead smelting, and in the manufacture of cadmium, after dermal absorption through protective rubber gloves,³ and after snorting what was thought to be cocaine.⁴ The elimination half time of thallium is between 1.7 and 30 days^{2,5} depending on the time since, and chronicity of, ingestion. The elimination time phases are apparent and because of the long terminal elimination half time thallium may act as a cumulative poison. We present two cases of thallium poisoning with intent to kill.

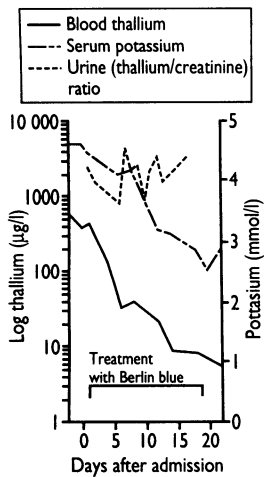


FIG 1—Alopecia in 42 year old man four weeks after thallium poisoning

Poisons Unit, Guy's Hospital, London SE1 9RT

Case presented by:
David Moore, registrar
Ivan House, analyst
Alison Dixon, physiotherapist

Chairman:
Gwyn Williams, professor of medicine

Discussion group:
Glyn Volans, consultant physician
John Henry, consultant physician
RAC Hughes, professor of neurological sciences
GM Cochrane, consultant physician
PL Atkinson, senior registrar
Heather Milburn, senior registrar

Case histories

Two men were invited for morning tea at a colleague's home in northern Iraq according to Middle Eastern tradition. About 10 minutes after drinking the tea the first patient, a 42 year old man, experienced severe abdominal cramp, chest tightness, and aching muscles. He attended his doctor who referred him to hospital, where he was admitted to the intensive therapy unit with suspected myocardial infarction. Thrombolysis was considered but not performed. Other diagnoses considered were gall stones and pancreatitis. The second man, aged 38 years, also developed abdominal pains about one hour after drinking the tea. He was seen by his family doctor who admitted him to the same hospital with a diagnosis of gastroenteritis. The condition of both patients deteriorated; they had increasing difficulty in walking, and started losing hair about two weeks after admission. Poisoning was suspected, and in the third week both patients were admitted to Damascus University Hospital where thallium poisoning was tentatively diagnosed. Our poisons unit was contacted and thallium poisoning was confirmed by laboratory analysis. The patients were transferred here about four weeks after initial presentation, having received only activated charcoal as treatment.

On arrival the first man complained of blurred vision, difficulty in walking, inability to rise from a prone to a sitting position, chest tightness, weight loss, alopecia, and anxiety. Examination and investigations showed alopecia (fig 1), weakness of the proximal lower

limb girdle, and decreased visual acuity (6/18 in the right eye and 6/12 in the left). The optic discs were normal. Goldmann visual field examination confirmed bilateral central scotomata and visual evoked responses were delayed at >110 ms bilaterally. Sensory conduction was normal throughout as was upper limb motor conduction. Evoked muscle action potentials were small or absent (left abductor hallucis 40 µV peak to peak 170 ms) and there was collateral sprouting in leg and forearm muscle suggesting motor axonal neuropathy.

Electrocardiography showed a sinus tachycardia of about 110-120 beats/minute. Single white transverse lines on the nails (Mee's lines) were noted just before discharge some three weeks later.

The second man complained of muscle tenderness, numbness and tingling in the feet, parotid enlargement, dysuria, weakness, anorexia, weight loss, dizziness, and hair loss. On examination he had alopecia, parotid enlargement, and myalgia with generalised weakness in all muscle groups. The assessment was limited because he had severe pain. Electrocardiography and visual field, visual evoked potentials, and nerve conduction tests all gave normal results. Both patients were started on physiotherapy, being given objectives such as chair sitting, correct sitting and standing techniques, independent transfer from bed to chair, and coping with stairs independently.

THALLIUM TOXICITY AND TREATMENT

The normal total blood thallium concentration is under 2 µg/l and concentrations greater than 100 µg/l are toxic. Urine thallium concentrations greater than 200 µg/l are also toxic. Figure 2 illustrates thallium distribution and excretion. The toxicokinetics of thallium in humans are described by a three compartment model.⁶ The first phase, which lasts about four hours, represents intravascular distribution. The second phase lasts 4-48 hours during which thallium is distributed into the central nervous system. In general the distribution phase is completed within about 24 hours. The elimination phase starts about 24 hours after ingestion and its duration depends on the therapeutic intervention used.^{7,8} Thallos ions are secreted into the small and large bowel⁹ but there is some enteral reabsorption.¹⁰ Intestinal secretion of thallium is the primary mechanism of thallium elimination with minimal secretion occurring in the bile.¹¹ Renal excretion mirrors the total body thallium

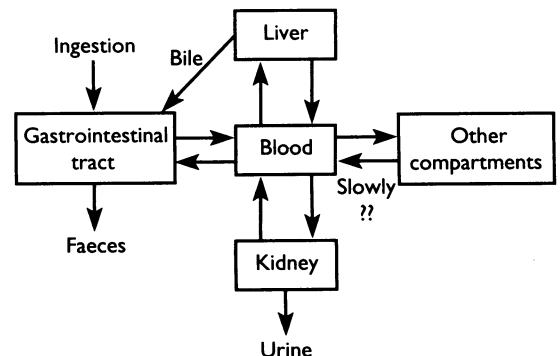


FIG 2—Diagram showing distribution and excretion of thallium

load. The faecal to urinary excretion ratio of thallium is about 2:1.¹⁰

The antidote for thallium poisoning is Berlin (formerly Prussian) blue or potassium ferric hexacyanoferrate (II)^{10 12 13} (colour index No 77520) in a dose of 250 mg/kg/day (three to four divided doses daily). Supplies were obtained from British Drug Houses (BDH) as microscopy grade material and suspended in distilled water for administration through a fine bore nasogastric tube. No adverse effects have been recorded from Berlin blue therapy. The dye does not cross the gut mucosa and the release of cyanide ions is negligible.¹⁴

Berlin blue forms insoluble complexes in the gut lumen, with thallium ions exchanging for potassium ions in the molecular lattices. This effectively reduces enteric reabsorption of thallium, thus enhancing faecal excretion. The elimination half life of thallium without treatment is about eight days^{15 16} and about three days with Berlin blue. Charcoal haemoperfusion and haemodialysis may be helpful if given within 48 hours after ingesting thallium as these treatments act only in the distribution phase. Elimination half times of 1.4 days have been obtained with such therapy.¹⁷ Other chelating agents such as dimercaprol, EDTA, and penicillamine are not effective and dithiocarbamate is contraindicated since it exacerbates thallium encephalopathy by enhancing redistribution of thallium into the central nervous system.

Thallium distributes in the same way as potassium because it has a similar charge and ionic radius. This similarity to potassium also accounts for the large volume of distribution of thallium, which has been estimated to be about 11.2 l/kg body weight.¹⁰ Potassium supplementation may be required during treatment to eliminate thallium, to replace thallium ions lost from tissue sites. Potassium supplementation may also increase the rate of loss of thallium from body compartments.¹⁸ Early potassium supplementation is probably not indicated since this is thought paradoxically to raise intracellular free thallium ion concentrations resulting in hyperexcitability and restlessness.¹⁹ Figure 3 shows the biphasic elimination time course in

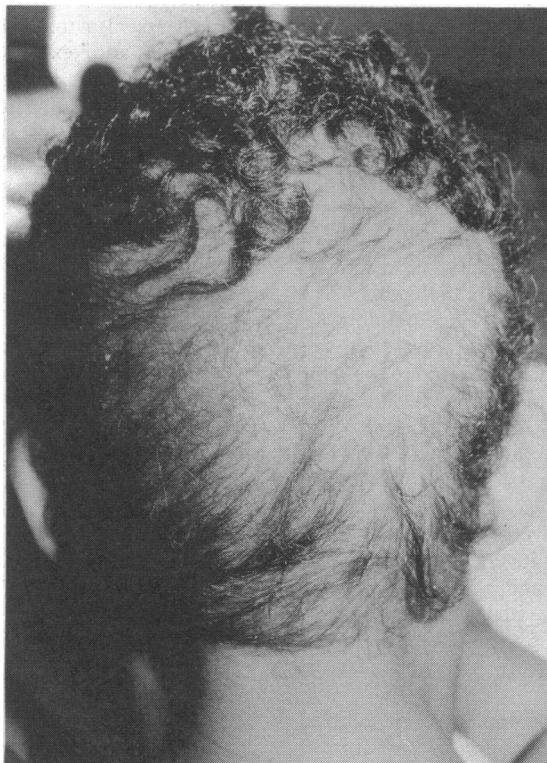

FIG 3—Blood thallium and serum potassium concentrations and urinary thallium:creatinine ratio in 42 year old man with thallium poisoning

the first man before and after starting treatment with Berlin blue. A similar elimination time course was found in the second man. Thallium was measured by atomic absorption spectroscopy. The urinary thallium:creatinine ratio rose slightly after stopping treatment. The much higher body load of thallium in the first man was reflected by this patient's symptoms and signs, which were more severe than those of the second man.

At follow up examination six weeks after treatment the first man was mobile but dependent on sticks. His muscle mass was reduced, especially the quadriceps femoris, despite having had intensive physiotherapy and rehabilitation. His visual acuity had recovered to 6/12 in the right eye and 6/6 in the left. Temporal pallor of both optic discs had developed consistent with the diagnosis of toxic optic neuropathy. The second man was independently mobile, the only notable feature being a reported diminished exercise reserve.

Comment

The exact mechanism of toxicity of thallium is unclear but it may disrupt sulphhydryl groups on the mitochondrial membrane and interfere with the function of sodium-potassium ATPase, for which thallium has a 10 times higher affinity than potassium. A further possible toxic mechanism is interference in riboflavin homeostasis by forming insoluble complexes and intracellular sequestration of riboflavin.²⁰ Deficiency of this vitamin is known to result in dermatitis, alopecia, and neuropathy. Skin lesions similar to those occurring in riboflavin deficiency have been described in thallium poisoning.²¹

Thallium poisoning usually presents (within 12-48 hours after exposure) as nausea, vomiting, diarrhoea, gastritis, duodenitis, paralytic ileus, and parotid and pancreatic damage.^{22 23} The effect of thallium on the parotid is one cause of sialadenosis. Neurological effects^{24 25} may be delayed for two to five days with paraesthesiae, hyperaesthesia (especially of the soles of the feet), headaches, ptosis, strabismus, optic neuropathy²⁶ and atrophy, myalgia, myopathy,²⁷ convulsions, coma, delirium, acute motor neuropathy, dementia, and psychosis. Autonomic neuropathy may occur, predisposing the patient to cardiac arrhythmias and sudden death for many weeks after the initial insult. Cardiac arrhythmias may also result from direct myocardiotoxicity and disruption of pacemaker function^{28 29} while sinus tachycardia probably results from increased secretion of adrenal catecholamines secondary to the effect of thallium on chromaffin cellular ATP.³⁰ Hair loss does not usually occur until after two to three weeks.

If the patient presents within four hours of ingesting thallium, gastric lavage and instillation of Berlin blue are warranted. In general, however, treatment is oral Berlin blue to facilitate thallium excretion in the stool and supportive care. Paralytic ileus may complicate treatment by reducing the throughput of the dye. This may be countered by combining Berlin blue with 5-10% mannitol. Thallium concentrations in the blood and urine should probably be measured initially thrice weekly. Attention should be paid to mouth hygiene since a severe stomatitis may occur, which is exacerbated by tooth brushing. Mouthwash and gargles should be provided instead. If adequately explained, shaving the patient's head may reduce the stress of tractional hair loss and facilitate subsequent hair growth. It may also improve the patient's morale. Physiotherapy is pivotal to successful rehabilitation. It prevents muscle contractures and may help recover muscle power. Apart from dealing with psychological complications resulting directly from thallium toxicity, psychotherapy is also important to deal with unresolved fears secondary to the toxic insult. Patients should be

reassured that recovery from the acute episode is the rule once the diagnosis has been made and medical care started. Recovery may, however, take a long time, and patients may not fully return to their previous functional level.

Discussion

GW: Could you tell us when during the course of the illness the diagnosis was actually made?

GV: I received a clinical inquiry from the Middle East two to three weeks after the onset of symptoms when the patients were described as being very weak, unable to stand, and having started to lose their hair. This prompted a tentative diagnosis of thallium poisoning, which was supported by the time course and progression of the clinical signs. Shortly afterwards the unit was formally approached and samples were sent for analytical confirmation of the diagnosis. Obtaining supplies of Berlin blue was also problematic in Damascus.

HM: How common is thallium poisoning?

JH: In the past two years we have seen five cases excluding these patients. All were attempted murders. There has been a steady trickle of cases in recent years.

GW: It is interesting that although the patients' muscles were very weak, the neurophysiological investigations were of so little help in localising the site of toxic damage.

RACH: It was difficult to assess the degree of weakness in these two patients because pain and anxiety interfered with muscle function. In the first man results of nerve conduction studies were consistent with a motor axonal neuropathy, which is well recognised in thallium poisoning. The cause of the pain is unclear but it might be explained by an effect on the small sensory nerve fibres, this could have been established by sural nerve biopsy, but this procedure would not have been ethically justified.

GMC: I saw these patients several times and was astounded by the very odd colour adjustment on the first patient's television set. Could this have been accounted for by his ocular insult?

PLA: Indeed, this is probable as he had a bilateral optic neuropathy with reduced visual acuity, central scotomata, and reduced colour vision, which could have caused him to increase the colour saturation on his television set.

GW: For how long are the patients at risk of some of the complications which have been discussed?

JH: Sudden cardiac death has been noted secondary to cardiac arrhythmias up to two months after ingestion.

GW: What conditions might enter the differential diagnosis?

JH: In the case of non-toxicological conditions, disorders such as Guillain-Barré syndrome (however the sensory signs of thallium are more localised),

systemic lupus erythematosus due to scarlet skin eruption, diabetic polyneuritis, and more rarely acute intermittent porphyria. Toxic agents which should be included in the differential diagnosis are alcohol, arsenic, lead, gold, carbon monoxide, and organophosphates.

- Lynch GR, Lond MB, Scovell JMS. The toxicology of thallium. *Lancet* 1930;ii:1340-4.
- Saddique A, Peterson CD. Thallium poisoning: a review. *Vet Hum Toxicol* 1983;25:16-22.
- Reed D, Crawley J, Faro S, Pieper S, Kurland L. Thallotoxicosis, acute manifestations and sequelae. *JAMA* 1963;183:516-22.
- Insley BM, Grufferman S, Ayliffe A. Thallium poisoning in cocaine abusers. *Am J Emerg Med* 1986;4:545-8.
- Baselt RC, Cravey RH. *Disposition of toxic drugs and chemicals in man*. 2nd ed. Davis, CA: Biomedical Publications, 1982.
- van Kesteren RG, Rauws AG, de Groot G, van Heijst ANP. Thallium intoxication. An evaluation of therapy. *Intensive Med* 1980;17:293-7.
- Hollogginas C, Ullicci P, Dricoll J, Gauerholz J, Martin H. Thallium elimination kinetics in acute thallotoxicosis. *J Anal Toxicol* 1980;4:68-73.
- Groot de G, van Heijst ANP, van Kesteren RG, Maes RAA. An evaluation of the efficacy of charcoal haemoperfusion in the treatment of three cases of acute thallium poisoning. *Arch Toxicol* 1985;57:61-6.
- Forth W, Henning CH. Thallium-Vergiftung und ihre Behandlung. *Deutsche Arzteblatt* 1979;43:2803-7.
- Rauws AG. Thallium pharmacokinetics and its modification by Prussian blue. *Arch Pharmacol* 1974;284:295-306.
- Schafer SG, Forth W. Excretion of metal into rat intestine. *Biol Trace Elem Res* 1983;5:205-17.
- Lehman PA, Favare L. Parameters for the absorption of thallium ions by activated charcoal and Prussian blue. *Clin Toxicol* 1984;22:331-9.
- Stevens W, van Peteghem C, Heyndrickx A, Barbier F. Eleven cases of thallium intoxication treated with Prussian blue. *Int J Clin Pharmacol* 1974;10:1-22.
- Dvorak P, Günther M, Zorn U, Catsch A. Metabolisches Verhalten von kolloidalem Ferrihexacyanoferrate (II). *Naunyn-Schmiedeberg Arch Pharmacol* 1971;269:48-56.
- Barclay RK, Peacock WC, Karnovsky DA. Distribution and excretion of radioactive thallium in the chick embryo, rat and man. *J Pharm Pharmacol* 1953;107:178-87.
- Fretwurst F, Lochmann FW. Akute Thalliumvergiftung. *Arch Toxicol* 1955;15:327-33.
- Groot de G, van Heijst ANP. Toxicokinetic aspects of thallium poisoning, methods of treatment by toxin elimination. *Sci Total Environ* 1988;71:411-8.
- Papp JP, Gay PC, Dodson VN, Pollard HM. Potassium chloride treatment of thallotoxicosis. *Ann Intern Med* 1969;71:119-23.
- Bank WJ, Pleasure DE, Suzuki J, Nigro M, Katz R. Thallium poisoning. *Arch Neurol* 1972;26:456.
- Cavanagh JB. What have we learnt from Graham Frederick Young? Reflections on the mechanism of thallium neurotoxicity. *Neuropathol Appl Neurobiol* 1991;17:3-9.
- Heyl T, Barlow RJ. Thallium poisoning: a dermatological perspective. *Br J Dermatol* 1989;121:787-91.
- Villanueva E, Hernandez-Cueto C, Lachica E, Ramos R, Ramos V. Poisoning by thallium: a study of five cases. *Drug Safety* 1990;5:384-9.
- Wainwright AP, Kox WJ, House IM, Henry JA, Heaton R, Seed WA. Clinical features and therapy of acute thallium poisoning. *Q J Med* 1988;69:939-44.
- Davis LE, Standefer JC, Kornfeld M, Abercrombie DM, Butler C. Acute thallium poisoning: toxicological and morphological studies of the nervous system. *Ann Neurol* 1981;10:38-44.
- Dumitru D, Kalantri A. Electrophysiological investigation of thallium poisoning. *Muscle Nerve* 1990;13:433-7.
- Grant WM. *Toxicology of the eye*. 3rd ed. Springfield, IL: Charles C Thomas, 1986.
- Limos LC, Ohnishi A, Suzuki N, Kojima N, Yoshimura T, Goto I, Kuroiwa Y. Axonal degeneration, focal muscle fiber necrosis in human thallotoxicosis: histopathological studies of nerve and muscle. *Muscle Nerve* 1982;5:698-706.
- Prick JGG, Sillevs-Smitt WG, Muller L. *Thallium poisoning*. Amsterdam: Elsevier Publishing, 1955.
- Hughes MN, Man WK, Whaler BC. The toxicity of thallium (I) to cardiac and skeletal muscle. *Chem Biol Interact* 1978;28:85-97.
- Grisham CM, Cupra RK, Barnett RE, Mildvan AS. Thallium-205 nuclear relation and kinetic studies of sodium and potassium ion-activated triphosphatase. *J Biol Chem* 1974;249:6738-44.

(Accepted 23 March 1993)

ONE HUNDRED YEARS AGO

POST-GRADUATE STUDY.

LONDON.

Powerful as is the British Medical Association as a means of knitting together the divided units of the medical profession, and influential as the JOURNAL is in giving voice to its aspirations, it may be doubted whether this, which may be called the political aspect of medical journalism, is what is most appreciated by the great mass of our readers. To thousands of men dotted over the globe, in distant villages and up-country stations, the JOURNAL is their one link with all that is progressive in medical science, and no one who has often to meet men in out of

the way country places, knowing what their life is and seeing how up to date they often are, can for a moment doubt either the enormous influence for good exerted by the JOURNAL, of the thirst for knowledge constantly present among the members of our profession. This love of knowledge is, however, insatiable, and notwithstanding the flood of lectures, papers, and clinical reports poured out upon the world by the enterprise of medical journalism, nay, possibly in consequence of the taste thereby encouraged, the number of those who wish not only to read but see, and who, for all that they are qualified, wish for the nonce again to become students, increases year by year.

(*BMJ* 1893;ii:537.)