

## Site of principal metabolic defect in idiopathic haemochromatosis: insights from transplantation of an affected organ

Paul L Dabkowski, Peter W Angus,  
Richard A Smallwood, John Ireton,  
Robert M Jones

**Victorian Liver Transplant Unit, Austin Hospital, Heidelberg, Australia 3084**  
Paul L Dabkowski, *fellow in hepatology*  
Peter W Angus, *physician*  
Richard A Smallwood, *physician*  
John Ireton, *pathologist*  
Robert M Jones, *director*

Correspondence to:  
Dr Angus.

BMJ 1993;306:1726

Idiopathic haemochromatosis is an inherited defect of iron metabolism characterised by excessive iron absorption and deposition in the tissues leading to damage in the liver and other organs.<sup>1</sup> The nature of the fundamental metabolic abnormality remains unknown, but the liver and the gut have both been proposed as the principal site of expression of the metabolic defect.<sup>1</sup>

We recently had the opportunity to study this question when a liver was transplanted from a donor who subsequently proved to have had presymptomatic idiopathic haemochromatosis into a young woman with normal iron metabolism. We describe here the changes in iron status observed in our patient in the first 29 months after liver transplantation.

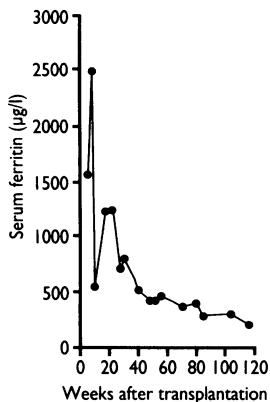
### Patient, methods, and results

A 16 year old girl underwent orthotopic liver transplantation for subacute hepatic failure caused by presumed non A, non B viral hepatitis. Extensive investigation had shown no specific cause.

A liver biopsy performed on the donor organ after reperfusion showed grade 3 stainable iron within hepatocytes without significant fibrosis. Further needle biopsies in the next six weeks confirmed grade 3 or 4 hepatocyte iron staining with only a small amount of iron seen in macrophages and sinusoidal cells. The hepatic iron concentration on day 42 was 152  $\mu\text{mol/g}$  dry weight (normal 5-40), and the hepatic iron index (donor age 48 years) was 3.17. These findings suggested idiopathic haemochromatosis.

The donor was a 48 year old woman who drank virtually no alcohol and who had no history of liver disease, anaemia, or blood transfusions. The donor's HLA haplotype included the A3 allele, which is known to be strongly associated with idiopathic haemochromatosis.<sup>1</sup> In addition, two siblings of the donor were found to have significantly raised serum ferritin concentrations and on liver biopsy showed greatly increased iron stores, confirming the diagnosis of idiopathic haemochromatosis in the donor family.

Findings on the recipient's iron studies before operation were as follows: iron 33  $\mu\text{mol/l}$  (normal 13-30), total iron binding capacity 38  $\mu\text{mol/l}$  (45-73), and serum ferritin 106  $\mu\text{g/l}$  (9-190). The serum ferritin



Serum ferritin concentrations after transplantation

concentration was measured regularly as a guide to iron stores, and by the 42nd day after transplantation, it had risen to 1585  $\mu\text{g/l}$ . It subsequently fell progressively, until by 29 months it was normal (figure). At this point the serum iron concentration had fallen to 14  $\mu\text{mol/l}$ . Four estimates of dry weight liver iron showed a progressive reduction from 152  $\mu\text{mol/g}$  immediately after transplantation to normal (30  $\mu\text{mol/g}$ ) at 29 months. The iron indices returned to normal in the absence of abnormal blood losses.

### Comment

Intuitively it seems reasonable to seek the expression of the metabolic defect of idiopathic haemochromatosis in the gut since increased assimilation of dietary iron is the major abnormality leading to increased body iron stores.<sup>1</sup> In patients with idiopathic haemochromatosis a larger than normal proportion of the iron taken up by the enterocyte is transferred into the body.<sup>2</sup> Further support for the epithelial cell as the site of the defect comes from immunohistochemical findings; these show a failure of downregulation of the enterocyte transferrin receptor by iron overload in patients with idiopathic haemochromatosis.<sup>3</sup>

Some evidence exists for hepatic control of iron metabolism, however, and hence of tissue iron accumulation in haemochromatosis. Patients with idiopathic haemochromatosis who have been "de-ironed" have a significantly higher hepatic iron uptake after intravenous infusion than controls.<sup>4</sup> The influence of the liver on iron absorption has been shown in a study in rats,<sup>5</sup> in which the transplanting of iron loaded livers into normal animals significantly reduced iron absorption in the graft recipients.

In our study, in which a liver from a patient with idiopathic haemochromatosis was transplanted into a recipient with normal iron metabolism, liver iron concentrations and serum ferritin concentrations returned to normal in the absence of any abnormal source of iron loss. This case provides strong evidence against a primary hepatic defect in idiopathic haemochromatosis.

We thank Dr J W Halliday for performing liver iron estimations and Drs S Fairley and M Malone for assisting with the investigation of the donor family.

- 1 Bothwell TH, Charlton RW, Motusky AG. Hemochromatosis. In: Scriver CR, Beaudet AL, Sly WS, Valle D, eds. *The metabolic basis of inherited disease*. 6th ed. New York: McGraw-Hill, 1989:1433-62.
- 2 Powell LW, Campbell CB, Wilson E. Intestinal mucosal uptake of iron and iron retention in idiopathic haemochromatosis as evidence for a mucosal abnormality. *Gut* 1970;11:727-31.
- 3 Lombard M, Bomford AB, Polson RJ, Bellingham AJ, Williams R. Differential expression of transferrin receptor in duodenal mucosa in iron overload. *Gastroenterology* 1990;98:976-84.
- 4 Batey RG, Petit JE, Nicholas AW, Sherlock S, Hoffbrand AV. Hepatic iron clearance from serum in treated haemochromatosis. *Gastroenterology* 1978;75: 856-9.
- 5 Adams PC, Stuart Reece A, Powell LW, Halliday JW. Hepatic iron in the control of iron absorption in a rat liver transplantation model. *Transplantation* 1989;48:19-21.

(Accepted 29 April 1993)

## Increased concentrations of serum lipoprotein (a) in response to growth hormone treatment

Hans Olivecrona, Sverker Ericsson,  
Lars Berglund, Bo Angelin

Premature death from cardiovascular disease has been reported in patients with adult growth hormone deficiency.<sup>1</sup> The treatment of such patients with

growth hormone lowers serum cholesterol concentrations and has positive effects on body fat distribution.<sup>2</sup> We recently reported that treating patients with gall stone disease with growth hormone stimulates hepatic low density lipoprotein receptors while at the same time reducing serum low density lipoprotein cholesterol concentrations.<sup>3</sup> In light of interest in expanding the indications for growth hormone treatment beyond that of growth retardation in childhood<sup>2</sup> it is important to evaluate the effects of growth hormone treatment on lipoprotein metabolism.

A high serum concentration of lipoprotein (a), especially combined with raised concentrations of low

Correspondence to:  
Dr Angelin.

BMJ 1993;306:1726-7