

SHORT REPORTS

Acquired coarctation of the aorta— a long-term complication of irradiation

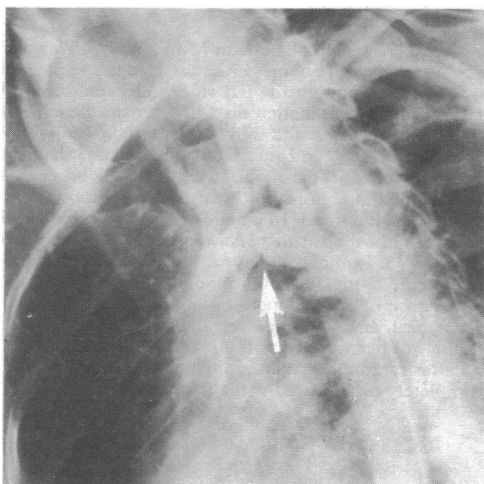
Many cardiac complications of mediastinal irradiation have been described.^{1,2} Lesions of the great vessels are very much less common as they have higher resistance; nevertheless, in animal studies³ damage has been confined to the irradiated area.³ This article describes an unreported vascular long-term complication of irradiation in man.

Case report

A 35-year-old man with viral pericarditis, confirmed by serial viral studies, was referred for an opinion on a widely heard murmur. The only cardiovascular abnormalities were a widely heard ejection systolic murmur, maximal in the aortic area (with associated thrill), radiating to the neck, apex, and widely over the posterior chest, and blood pressures of 140/60 mm in the right arm and 120/60 mm in the left, with no femoral delay.

The medical history was of Hodgkin's disease at the age of 16, of nodular sclerosing type (clinical stage IIa), which had been treated by mantle irradiation of 3000 rads. Hilar regression and upper lobe fibrosis had been seen over two months; the patient had remained disease-free for 15 years; and had been discharged from follow-up. No murmurs were heard during follow-up or in subsequent medical examinations.

Cardiac catheterisation and arch aortography showed normal right and left heart pressure with no aortic valve gradient. There was a 20 mm peak systolic gradient across the aortic arch on withdrawal of the catheter. Arch aortography (see figure) showed irregularity of the aortic arch between the origins of the left carotid and subclavian arteries, with notching of the inferior surface at that point (arrowed). When seen three months after catheterisation the patient was developing early obstruction of the superior vena cava.



Aortogram showing irregularity of aortic arch between origins of left carotid and subclavian arteries with notching of inferior surface (arrowed).

Discussion

Though several cardiac and pulmonary complications of mediastinal irradiation have been reported, the effects on the great vessels are seen rarely. In one case of aortic irradiation damage⁴ features were localised to the irradiated area but had produced no signs or symptoms during life. The histological features were similar to those produced experimentally. Damage to other major vessels has occasionally been reported,⁵ sometimes with many years before presentation.

In this case thickening and fibrosis of the aortic arch, with subsequent buckling, were probably the major factors in producing the clinical and haemodynamic findings. Possibly with the current

extended survival of patients with Hodgkin's disease treated by irradiation this complication may be met with more frequently in future.

I would like to thank Professor J M Evanson and Dr C L Bray, Dr R S Crosson, and Dr D C Beton for permission to describe the case and for their advice and help.

¹ Stewart, J R, *et al*, *Radiology*, 1967, **89**, 302.

² Kaplan, H S, and Stewart, J R, *National Cancer Institute Monographs*, 1973, **36**, 439.

³ Rubin, P, and Cassarett, G W, *Clinical Radiation Pathology*, pp 427-92. Philadelphia, Saunders, 1968.

⁴ Thomas, E, and Forbus, W D, *Archives of Pathology*, 1959, **67**, 256.

⁵ Benson, E P, *Radiology*, 1973, **106**, 195.

Wythenshawe Hospital, Manchester M23 9LT

L P ORMEROD, BSC, MB, senior house officer in cardiothoracic medicine (now senior house officer in general medicine, Withington Hospital, Manchester)

Malignant hypertension secondary to idiopathic arteritis of the aorta

Arterial disease in the tropics assumes a different pattern from that seen in the West. Unlike the degenerative disease of developed countries, the most common pathological process appears to be inflammatory and of unknown and possibly varying aetiology.

Case history

A 16-year-old Zambian boy was admitted with a two-month history of throbbing headaches, latterly associated with vomiting, increased urinary frequency with nocturia, and progressive visual deterioration. He denied haematuria, loin pain, or abdominal trauma. He was well nourished, with blood pressure 240/130 mm Hg in each arm; 230/130 mm Hg in each leg. There was a high-pitched bruit over the epigastrium, a bruit over the left femoral artery, and the pedal pulses were palpable only with difficulty. There was definite accentuation of the aortic second sound, but no enlargement of the heart. The fundi showed grade IV hypertensive changes, with acuity on the right of 6/9, and on the left of 6/60, with macular exudates. Investigations showed repeatedly normal haemoglobin; white cell count; urine examination; and serum concentrations of urea, electrolytes, creatinine, cholesterol, serum proteins, alkaline phosphatase, creatinine clearance, and urinary vanillyl mandelic acid. Haemoglobin electrophoresis was AA. The results of serological tests for antinuclear factor, rheumatoid factor, and syphilis were negative. Antistreptolysin-O titre, chest x-ray film, and electrocardiogram were within normal limits. Mantoux test was positive 1-1000. Erythrocyte sedimentation rate ranged between 25 and 37 mm per hour. An abdominal x-ray film showed a well-demarcated area of calcification overlying the body of the second lumbar vertebra. An intravenous pyelogram showed delayed nephrogram phase and loss of cortical volume at the left upper pole, with the right kidney measuring 12.5 cm and the left kidney 10.5 cm. Aortography confirmed aortic disease and showed the lower pole of the left kidney being supplied by an accessory vessel.

Surgical exploration showed calcification and patchy narrowing and dilatation of the aorta from 5 cm above the origin of the renal vessels to its bifurcation. The left kidney was supplied by two distinct polar arteries. That supplying the upper pole appeared fibrosed, while the lower polar vessel was widely patent. The upper pole of the kidney was atrophic. The right kidney and its blood supply were normal. Left nephrectomy was performed. Two months postoperatively his blood pressure remains controlled at 120/80 mm Hg on a "loop" diuretic alone. Fundoscopy changes regressed with residual exudates only. Histological examination confirmed an ischaemic left upper pole. The left lower pole and a right renal biopsy were normal. The upper polar artery showed degeneration and fibrosis in the media, with diffuse thickening of the intima secondary to connective tissue proliferation.