

---

# The clinical and functional measurement of cortical (in)activity in the visual brain, with special reference to the two subdivisions (V4 and V4 $\alpha$ ) of the human colour centre

---

S. Zeki\* and A. Bartels

*Wellcome Department of Cognitive Neurology, Institute of Neurology, University College London, Gower Street, London WC1E 6BT, UK*

We argue below that, at least in studying the visual brain, the old and simple methods of detailed clinical assessment and perimetric measurement still yield important insights into the organization of the visual brain as a whole, as well as the organization of the individual areas within it. To demonstrate our point, we rely especially on the motion and colour systems, emphasizing in particular how clinical observations predicted an important feature of the organization of the colour centre in the human brain. With the use of data from functional magnetic resonance imaging analysed by statistical parametric mapping and independent component analysis, we show that the colour centre is composed of two subdivisions, V4 and V4 $\alpha$ , the two together constituting the V4 complex of the human brain. These two subdivisions are intimately linked anatomically and act cooperatively. The new evidence about the architecture of the colour centre might help to explain why the syndrome, cerebral achromatopsia, produced by lesions in it is so variable.

**Keywords:** achromatopsia; independent component analysis (ICA); perimetry; colour vision

## 1. INTRODUCTION

The present confidence and euphoria in charting the involvement of various parts of the human brain in different and distinct activities is well justified. Never before in human history have we been able to explore with such assurance activities that, like language, are distinctly human, or to begin to probe with such hope what has commonly been regarded as subjective mental states such as emotion. Yet whatever bright promise the methods of functional imaging might hold for the future, the measurement of brain activity or inactivity must ultimately rely on other disciplines as well. In this article we emphasize one other discipline, clinical observation, and show that this relatively crude and time-honoured method can still contribute in significant ways to detecting and unravelling, and even measuring, cortical activity in ways no less important and informative than the relatively sophisticated techniques of functional imaging alone. We choose vision, and especially colour vision, as a vehicle for this view, but there is little doubt that other functions could serve as well.

## 2. MEASURING CORTICAL (IN)ACTIVITY THROUGH PERIMETRY

The method of visual perimetry, i.e. the method of determining blind parts of the field of view, has been one of the most outstanding in charting damage to the visual

brain and therefore measuring indirectly those parts of the brain that are inactive. It is not often remembered that Henschen and his successors in Japan and England (Henschen 1893; Inouye 1909; Holmes 1918) had charted with considerable accuracy the representation of the visual field in the primary visual cortex, area V1 (calcarine cortex in humans), long before physiologists did so with their more sophisticated invasive techniques in monkeys (Daniel & Whitteridge 1961). The detection of a congruous scotoma, or a blind part of the field of view at the same location for the two eyes, is a sure way of localizing a lesion to the postgeniculate level, i.e. probably to areas V1 or V2 of the cerebral cortex. One can make a fairly good guess as to whether it is on the upper or lower bank of the calcarine sulcus and how far antero-posteriorly it is located by noting the position of the scotoma in the field of view. The details of this procedure, and the reliability with which the damage can be located, are so well-documented that we need not dwell on it in any detail here, except to say that the method continues to provide new and interesting information about the organization of other visual areas. For example, Horton & Hoyt (1991) have used the perimetric method to show how a well-circumscribed lower quadrantanopia in patients can be used to explain the nature of visual field representation within two visual areas, V2 and V3, of human occipital cortex. The special feature of the two patients that they examined was that, in each, the lesions were outside the calcarine cortex and had produced quadrantanopias with a sharp cut-off at the horizontal meridian. Relying on the known retinotopic organization

\* Author for correspondence (s.zeki@ucl.ac.uk).

of areas V2 and V3 in the macaque monkey (Cragg 1969; Zeki 1969), they have argued convincingly that, because the upper and lower quadrants in V2 and V3 are separate and because the horizontal meridian forms the boundary between the two, it follows that a scotoma whose characteristic is a quadrant with a cut-off at the horizontal meridian must be due to a lesion of V2 and V3 rather than V1. Apart from the use to which such perimetry was put to give insights into the manner in which the retina is mapped in these two areas, this work is additionally important in showing that lesions confined at least to area V2, and possibly V3, also result in scotomas. Interestingly, despite the completely intact visual pathways up to and including area V1, these patients did not have conscious percepts of the kind of stimulus thought to be processed by V1 within their scotomas. This suggests that activity in V1 alone is not sufficient to create a conscious percept, which is consistent with what has been proposed on other grounds (Crick & Koch 1995). We suggest here that lesions in a certain area will only lead to visual defects for the attribute and for the level of processing that the area is specialized for (Bartels & Zeki 1998*b*). If the organization of human visual cortex is similar to that of monkey, it is likely that lesions in V2 will cause scotomas involving the perception of edges, local motion and wavelengths, which are all processed in V2 (Hubel & Livingstone 1987; DeYoe & Van Essen 1988; Zeki & Shipp 1988); however, global motion is likely to continue to be perceived even within the scotoma because the motion area (V5) does not rely entirely on input from V2 (see below). In contrast, V3 is more specialized, at least in the monkey (Zeki 1978), and hence lesions in it are less likely to cause global scotomas or hemianopias.

The above are examples in which perimetry is, in a sense, measuring inactivity in the cortex, or rather detecting damaged and therefore inactive areas. However, perimetry has also been instrumental in detecting active areas of the brain. For example, by using dynamic perimetry, Riddoch (1917) had shown that patients blinded by lesions in area V1 could nevertheless detect motion, consciously, in their field of view. He provided a somewhat doubtful explanation for this, supposing that it was due to the sparing of those parts of V1 that are specialized for the detection of motion. This is why Sir Gordon Holmes found it so easy to dismiss Riddoch's findings: it seemed improbable that gunshot wounds would selectively spare motion-detecting cells whose distribution in V1 was in any case unknown at that time (reviewed by Zeki 1991). Although it is perhaps unwise to give too much credit retrospectively for findings whose true significance was not so explicitly recognized by their authors, it is worth recording that, in spite of this improbable explanation, the contribution that Riddoch made through his relatively crude methods of detection is writ large in the title of his paper: 'Dissociations of visual perceptions due to occipital injuries', a concept that was only to be taken seriously over 70 years later, once anatomical and electrophysiological evidence had established the presence of separate systems dedicated to processing different attributes of the visual world. In addition, Riddoch was led by his simple methods to conclude that 'Movement may be recognized as a special visual perception' (Riddoch 1917), an insight ignored by the neuro-

logical world until the discovery of visual areas specialized for processing visual motion (reviewed by Zeki 1991). However, Riddoch's simple methods and accurate observations resulted in more than is of topical importance for imaging studies. He wrote that his 'blind' patients were 'conscious' of having seen the motion within their blind fields, a term he used repeatedly in describing the results of his perimetric studies, almost certainly without realizing the true significance of his description. It was to take physiological and imaging experiments some 75 years to find a valid anatomical and physiological explanation for this phenomenon of conscious vision for motion, in subjects blinded by lesions to V1. This was done by showing (i) that the cells of area V5 in the macaque maintain their directional selectivity to motion when disconnected from V1 (Rodman *et al.* 1989; Girard *et al.* 1992); (ii) that, in humans, signals from fast-moving stimuli reach area V5 before they reach V1 (Beckers & Zeki 1995; ffytche *et al.* 1995); and (iii) that there is significant activity in V5, without parallel activity in V1, when blind (hemianopic) patients experience consciously fast motion in their 'blind' field (Zeki & ffytche 1998). It is somewhat unfortunate that Riddoch's observations disappeared, quite literally, from the medical literature for at least half a century (reviewed by Zeki 1993*b*). Riddoch was, in a sense, detecting and measuring physiological activity in the brain long before modern sophisticated techniques were able to demonstrate it; indeed there is no insight that has been derived from modern imaging techniques that could be considered to be intellectually equivalent to Riddoch's insight, had his findings been accepted. The general point that we are making here is that the simple techniques of clinical observation, and perimetry in particular, are valid and important tools for measuring cortical activity.

### 3. THE DETECTION OF CORTICAL ACTIVITY IN COLOUR VISION

Acquired cerebral achromatopsia provides an even more compelling reason for a serious reliance on the old techniques of perimetry and clinical observation in general. Cerebral achromatopsia is a syndrome in which, after cortical damage to a specific part of the human brain, namely the colour centre in the fusiform gyrus (see below), the patient is unable to see the world in colour but only in 'dirty' shades of grey. The damage causing the syndrome was first located with relative precision by Verrey (1888), in an article interestingly entitled 'Hémiachromatopsie droite absolue' and confirmed by MacKay & Dunlop (1899). Both articles, like that of Riddoch, were dismissed and relegated to oblivion for many years (reviewed by Zeki 1990). However, the use of the term 'hemiachromatopsia', derived from clinical observation alone, should have given powerful hints about the organization of the visual brain, and of the colour centre in particular, which at least some of the more recent sophisticated imaging studies have ignored at their peril. It is not clear that Verrey himself understood the real significance of the term, or indeed of his more general finding (see Zeki 1993*a*). His discovery indicated to him that the primary visual receptive centre (the 'cortical retina' of Henschen, which we now call V1) was much larger than

that envisaged by Henschen and Holmes and was not confined to striate cortex but included the cortex of the lingual and fusiform gyri. This supposition, which is in fact inaccurate, is one reason why his findings were dismissed, especially by Henschen, who wrote, apparently with some irritation, 'The two cases of achromatopsia published by Verrier and Machay [*sic*] do not demonstrate, in my opinion, what these authors wanted to demonstrate' (Henschen 1893).

#### 4. WHAT CLINICAL HEMIACHROMATOPSIA REVEALS ABOUT THE ORGANIZATION OF THE HUMAN COLOUR CENTRE

In fact, it was left to other clinicians to understand the real significance of the term hemiachromatopsia, long before the scientists got around to measuring the cortical activity produced by viewing colours. Damasio *et al.* (1980) wrote '... one single area in each hemisphere controls color processing for the *entire* hemifield. This is so regardless of the fact that such an area is eccentrically located, in the lower visual association cortex, classically related to *upper quadrant* processing only. . . . The classic concept of concentrically organized visual association cortex no longer appears tenable' (original emphasis). The conclusion derived from clinical detection and measurement seemed compelling and final. There was little reason to doubt it, especially because physiological evidence had shown that, in the monkey, an eccentrically located visual area situated in the upper occipital cortex, area V3A, has a representation of both upper and lower fields within it (Van Essen & Zeki 1978). Thus our early colour-imaging studies (Lueck *et al.* 1989; Zeki *et al.* 1991) paid scant attention to the problem of quadrantic representation; instead, they tried to detect the cerebral activity produced by viewing full-field multi-coloured Mondrian stimuli compared with viewing the same scenes achromatically. Our results located the colour centre to a single region, which we called area V4, in the posterior part of the fusiform gyrus.

Were our relatively simple visual stimuli the best ones to use? Was our method, of detecting blood flow changes in the cerebral cortex by the technique of positron emission tomography (PET) or blood-oxygen-level-dependent (BOLD) changes detected by functional magnetic resonance imaging (fMRI), the best way of measuring cortical activity in response to our stimuli? An apparently remarkable technique, that of phase-encoded retinal stimulation, developed by Engel *et al.* (1994), suggested an alternative way. Here the response phases of individual voxels in the visual cortex are related to the position of a rotating wedge or expanding ring stimulus. Put simply, that part of the visual field which is mapped in a given brain region is given by the retinal location of the stimulating wedge at the time of the region's maximal response, taking into account the time-delay of the response. A reversal in response phase is of particular interest as it marks the transition from one retinotopic map to another. This method is therefore really based strictly on detecting the retinotopic organization of the visual areas. Its use, linked to an analysis of BOLD signals, revealed an area that was named 'V4v' (Serenio *et al.* 1995; DeYoe *et al.* 1996). The use of the term 'V4v' implied a similarity

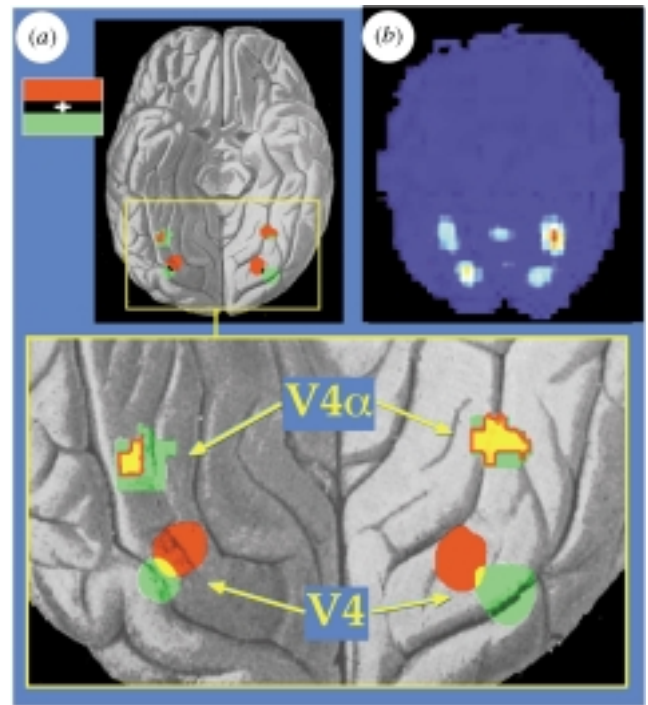


Figure 1. The two components of the V4 complex, the posterior, retinotopically organized area V4 and the anterior area V4 $\alpha$ , as revealed by the reanalysis of the V4 mapping study by McKeefry & Zeki (1997). (a) Projection of the activity obtained by either upper-field (in red) or lower-field (in green) with colour and with achromatic stimuli on to a ventral view of a human brain (yellow represents the overlap between red and green). For V4 (bottom), the statistical parametric map of the following comparison is projected onto the drawing: superior coloured compared with (superior achromatic plus inferior coloured plus inferior achromatic). Simpler comparisons revealed the same retinotopic organization of V4, but this comparison revealed it most clearly (group of four subjects; threshold  $Z = 4.81$ ,  $p < 0.05$  corrected for multiple comparisons; equivalent to  $p < 0.000001$  uncorrected). Coordinates for V4 were as follows (brains were normalized to the echo-planar imaging (EPI) template provided in SPM, which is similar to the average of 305 brains provided by the Montreal Neurological Institute; the  $Z$ -score is given for each hottest voxel): representation of upper visual field (in red), left,  $(-22, -72, -12)$ ,  $Z > 7.31$ ; right,  $(20, -72, -10)$ ,  $Z > 8.46$ ; representation of lower visual field (in green), left,  $(-30, -76, -8)$ ,  $Z > 8.13$ ; right,  $(32, -76, -10)$ ,  $Z > 5.52$ . For V4 $\alpha$  (top), statistical parametric maps of a comparison of colour and achromatic stimuli within the corresponding hemifield is projected on to the drawing (threshold,  $Z = 3.09$ ;  $p < 0.001$  uncorrected). V4 $\alpha$  withstood the corrected threshold for the comparison of colour with achromatic stimulus for the whole visual field. Coordinates for V4 $\alpha$  were as follows: left,  $(-34, -54, -14)$ ,  $Z > 5.18$ ; right,  $(30, -50, -20)$ ,  $Z > 5.36$ . (b) An ICA separates spatially independent maps of brain activity without *a priori* knowledge of the stimulus conditions. ICA isolated the complete V4 complex, including the posterior (V4, bottom) and the anterior (V4 $\alpha$ ) subdivisions in both hemispheres, shown here in the glass-brain view of a single subject's brain. This indicates that activity in the complete V4 complex is independent of activity in other cortical areas, and that V4 and V4 $\alpha$  are cooperatively activated in this colour task.

between it and area V4, a similarity emphasized by one of the above studies, which, referring to our studies, reported that 'The location of V4v corresponds to some of the locations identified in positron emission tomography studies as having color selective responses' (DeYoe *et al.* 1996); the addition of 'v' was intended to indicate that it was nevertheless only the isolated ventral part of a much larger V4, in which the upper quadrant alone is mapped, that had been charted (the dorsal part, representing the lower quadrant, and thought to be located dorso-laterally in the occipital cortex, has yet to be charted) (Tootell *et al.* 1996). This itself is cause for concern because it is difficult to imagine why the same method of stimulation and analysis can chart one-half of an area but not the other. This seemed somewhat surprising because the clinical evidence has shown that both the upper and lower fields are mapped eccentrically in the colour centre, located in ventral occipital cortex (see above). Either we and the clinical evidence had been wrong, or the new stimulus technique used for detecting cortical activity by phase encoding was inadequate, or the results that it yielded had been misinterpreted because the method had actually revealed a novel area posterior to the colour-selective region including V4, without detecting V4 at all. The phase-encoding method itself is new and not above suspicion, at least for the present. Although it works in theory, recent evidence suggests that it might not be quite so reliable in practice. Studies with simple visual stimuli that span the whole visual field and are turned on and off with a period of *ca.* 1 min show that similarly considerable variations in cortical response phase are present even when the stimulus is not changing in retinotopic position (i.e. not expanding or rotating) (Guy *et al.* 1999). At the very least, these 'physiological' phase variations, which reflect inherent and varying response delays across the cortex, might contaminate phase-encoding methods. At worst, they might lead to artefactual retinotopic maps. The dazzling visual presentation of the results obtained by this method, achieved through considerable graphic post-processing, might lull one into a sense of security. In fact, it is important to consider these maps in comparison with those obtained by the standard approach, and with some caution. In the human ventral extrastriate cortex, the novel phase-encoding method has so far only confirmed what had been described before with standard techniques, and it failed to detect even the retinotopic organization of V4 until this had already been detected by more pedestrian methods (McKeefry & Zeki 1997); it was obviously not designed to detect the presence of non-retinotopically organized visual areas such as V4 $\alpha$  (see below). It is perhaps a little disconcerting that groups such as ours and others (Kastner *et al.* 1998), using the standard techniques, have not been able to confirm the existence of area 'V4v'. The fact that none of the studies using this novel phase-encoding technique attach any statistical values to the significance of the presented maps—a basic and stringent requirement for the standard approach—makes it difficult to judge its reliability and the results that deviate from those obtained by standard techniques. It is also somewhat surprising to find that successive maps from the same group have significant, but uncommented on, differences (compare Sereno *et al.* 1995; Tootell *et al.* 1997*a,b*; Hadjikhani *et al.* 1998).

The notion that, in spite of the clinical evidence, only one-half of V4, representing upper visual fields only, might be located in the fusiform gyrus within the ventral occipital cortex drove us to reinvestigate the problem of the visual field representation within V4, using the same multi-coloured Mondrian stimuli but this time restricted to stimulation of upper or lower hemifields and detecting BOLD changes with fMRI. Our results (McKeefry & Zeki 1997) showed that upper and lower quadrants are mapped separately within V4, the colour centre (figure 1*a*); this not only confirmed the clinical conclusions about the nature of visual field representation within V4, but also showed that the apparent sophistication of new stimulation methods, and indeed of all new methods, must be regarded with caution. Before the study of McKeefry & Zeki (1997), the phase-encoded retinal stimulation method had suggested that there is no colour centre in the ventral occipital lobe of the brain with a complete representation of the contralateral field of view. Our results, derived from the simpler stimulation method, subsequently led to a re-examination by Hadjikhani *et al.* (1998) of the activity produced by colour stimuli, using phase-encoded retinal stimulation. They identified the same area as our V4, in terms of Talairach coordinates, and confirmed that both upper and lower quadrants are separately and contiguously mapped within it. However, by describing their area as being 'previously undifferentiated' and attaching a new name, 'V8', to it, they gave the misleading impression of having discovered a new area; in fact, it is the same area as our V4 and accepted as such in a personal communication by R. B. H. Tootell and N. Hadjikhani with their statement that 'We assume that the cortical area described by McKeefry & Zeki (1997) is equivalent to our area V8, ...' (Hadjikhani *et al.* 1998; Tootell & Hadjikhani 1998; Zeki *et al.* 1998) (see figure 2). It therefore does not provide any more hope than our earlier discoveries that the cortical processes underlying the conscious perception of colour will be understood better now, as supposed by Heywood & Cowey (1998), than when we first described the location of the colour centre in the human brain a decade ago.

The fact that clinicians should have reached, through their observations, conclusions about the nature of the visual field representation within the colour centre long before scanners were put to use to measure cerebral blood flow as a measure of cortical activity, is perhaps the most eloquent testimony of all of the importance and primacy of simple clinical observation in detecting and measuring brain activity.

## 5. THE CLINICAL FATE OF CEREBRAL ACHROMATOPSIA

Clinical evidence has emphasized that cerebral achromatopsia is a complex syndrome (Rizzo *et al.* 1993). In this complexity lies perhaps another cautionary lesson for measuring the brain activity produced by colour with sophisticated new techniques. There are two issues to consider here, first the nature of the syndrome itself and next the extent of recovery from it, the two being linked.

There is no simple and straightforward condition characterizing achromatopsia. This is shown by the fact that, whereas in some cases (the true achromatopsias)

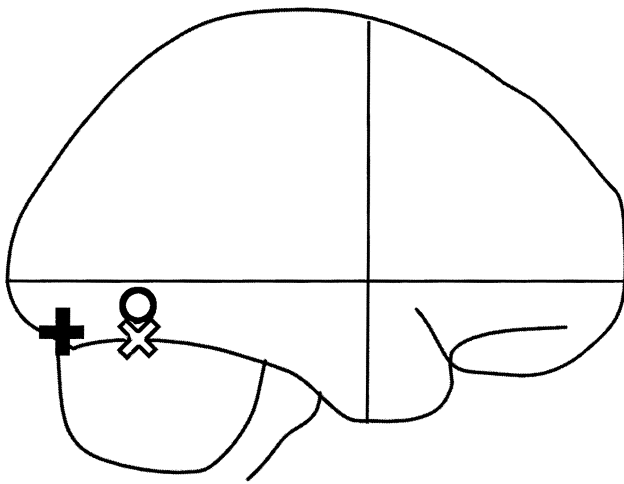


Figure 2. The locations of three areas discussed in the text are shown, in a glass-brain projection. The areas were located by using the Talairach coordinates of the three areas given by Hadjikhani *et al.* (1998): the circle corresponds to area V4 defined by Lueck *et al.* (1989), Zeki *et al.* (1991) and McKeefry & Zeki (1997); X corresponds to the 'new' area 'V8' of Hadjikhani *et al.* (1998) and the cross corresponds to the area V4v defined by Sereno *et al.* (1995).

the world is entirely devoid of colour and is reported only in terms of 'dirty' shades of grey (see, for example, Verrey 1888; Young *et al.* 1980), in others (the dyschromatopsias) the defect is less severe; here the perception of some colours can be more affected than others. As examples, the patients of Pearlman *et al.* (1979) and of Victor *et al.* (1989) had a greater loss of blues and greens, and a relative sparing of reds (see also Rizzo *et al.* 1993). Allied to this variability is the variability in the degree of recovery. The following examples illustrate this: Ogden (1993), Kölmel (1988) and Paulson *et al.* (1994) reported no recovery in six years, two years and ten months, respectively, after onset, whereas Bornstein & Kidron (1959) reported a recovery after a few days. Albert *et al.* (1975) reported a return of colour vision to one rather than both hemifields, and hence a recovery in one hemisphere rather than both. Moreover, recovery is not invariably uniform: patients often recover their ability to perceive some colours more than others (see, for example, Jaeger *et al.* 1989). This might be the consequence of incomplete lesions (Zeki 1990); Damasio (1985) has suggested that the more a lesion extends posteriorly in the fusiform gyrus, the more severe is the defect and the less likely a recovery from achromatopsia. These are of course merely hints and guesses, but our argument in this paper is that hints and guesses derived from clinical evidence are especially worthy of note, and must be critically considered in all measurements of brain activity. Evidence that damage to the fusiform gyrus leads to different severities of acquired cortical colour blindness might be merely reflecting the fact that, in some cases, the damage is more extensive than in others; the observation that the syndrome might be characterized by a greater imperception for some colours than for others raises the possibility of subdivisions within the colour centre. The part of the fusiform gyrus activated by colour studies is relatively large and it

Table 1. The Talairach coordinates and statistical significance ( $Z$ -scores) of the most active voxels in our previous colour activation studies (Lueck *et al.* 1989; Zeki *et al.* 1991; McKeefry & Zeki 1997)

study and area	$x$	$y$	$z$	$Z$ -score
Lueck <i>et al.</i> (1989) (PET)				
left	-27	-56	-5	—
right	24	-58	-7	—
McKeefry & Zeki (1997) (fMRI)				
left mean	-29	-68	-14	—
superior field left	-24	-76	-14	4.61
inferior field left	-32	-76	-12	4.71
right mean	30	-75	-19	—
superior field right	28	-72	-12	4.59
inferior field right	38	-74	-20	4.71
Zeki <i>et al.</i> (1991) (PET)				
left	-26	-68	-8	—
right	20	-66	-4	—

therefore becomes interesting, in the light of the above clinical observations, to learn whether it is a single uniform area or whether it has subdivisions.

## 6. V4 AND V4 $\alpha$ AS TWO COMPONENTS OF THE COLOUR CENTRE

An examination of the distribution of the most active voxels in our own previous studies of colour activation (table 1) shows a variability. We note here that the figures given in table 1 refer to the centre points of activity, which covers more extended areas; in fact, the large zone of activation obtained in our first colour study on humans (Lueck *et al.* 1989) included all the zones revealed in the subsequent two (Zeki *et al.* 1991; McKeefry & Zeki 1997) and that reported here.

We have since undertaken other experiments, to be reported in more detail elsewhere, to study the cortical sites involved in colour vision. These experiments were not actually inspired by the clinical evidence referred to above, but rather by other experimental and clinical evidence (Walsh *et al.* 1993; Kennard *et al.* 1995) that area V4, in man as in monkey, is important for the single most important attribute of the colour system, namely colour constancy. By this we mean the ability of the colour system to 'discount the illuminant' (Helmholtz 1911) in which a surface is viewed, because the wavelength composition of the light reflected from a surface changes substantially when it is viewed in light of different illuminants, whereas the perceived colour remains constant (see also Land 1974). Whatever the inspiration for our recent experiments, the results gain added weight in the light of the clinical evidence on the variability in the syndrome of achromatopsia. In these new studies of brain activity related to colour vision, instead of comparing the brain activity produced by a multicoloured Mondrian with its equiluminous achromatic counterpart, we tried to simulate more nearly a condition in which the Mondrian is viewed while the spectral composition of the illuminating light changes continually, much as would happen when one views a coloured object or surface on a cloudy day

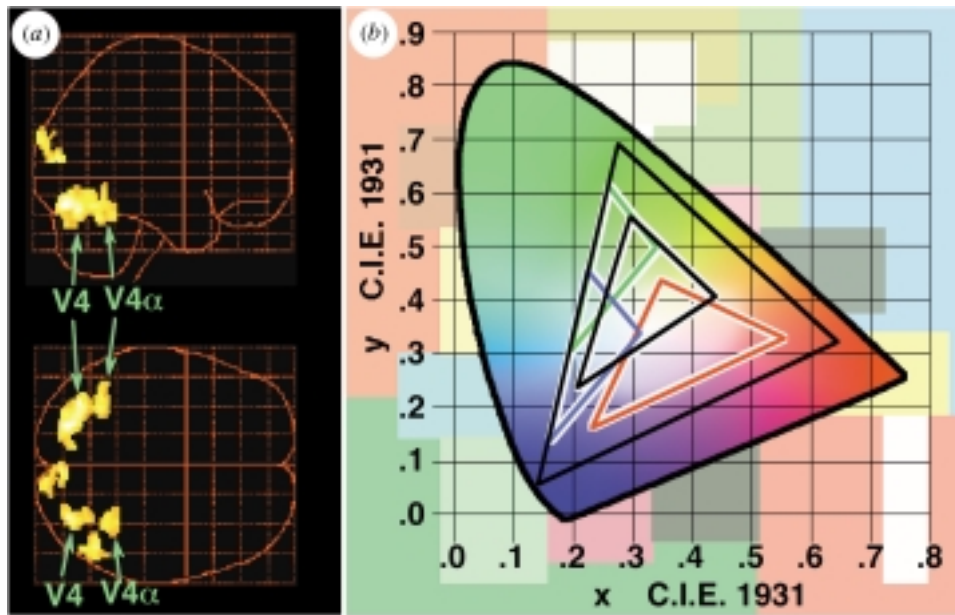


Figure 3. Brain activity elicited when subjects maintain colour constancy while viewing a dynamically changing Mondrian stimulus; that is, one in which the wavelength composition or intensity (or both) of the light coming from every square changes continuously. (a) The statistical parametric map of brain activity for the comparison of the varying luminance and the changing wavelength composition mode compared with the static mode in a coloured Mondrian, viewed as a glass-brain, shows the two subdivisions of the V4 complex: V4 and V4 $\alpha$  (group of six subjects, threshold:  $Z=3.72$ ,  $p < 0.0001$ ). Tailarach coordinates for V4 were as follows (the  $Z$ -score is given for each hottest voxel): left (two peaks),  $(-34, -68, -18)$ ,  $Z > 7.25$ , and  $(-22, -76, -16)$ ,  $Z > 6.97$ ; right,  $(34, -74, -16)$ ,  $Z > 6.90$ . Coordinates for V4 $\alpha$  were as follows: left,  $(-28, -54, -18)$ ,  $Z > 5.39$ ; right,  $(28, -50, -16)$ ,  $Z > 7.18$ . There was also very weak activity in the V1/V2 region and lateral to the V4 complex. (b) The Mondrian stimulus used is shown in the background. The CIE (Commission Internationale de l'Éclairage) colour flowchart (ellipsoid envelope) is in the foreground. The three inner coloured triangles show the range of the CIE colour space that three Mondrian patches of the corresponding colour would have occupied during the changing wavelength condition had they been viewed on their own (the black triangle depicts the same for the white patch). In the experiment, the perceived colour of each patch remained constant because it was surrounded by other patches and was therefore viewed in context. The black outer triangle depicts the range of colours that our projection screen is capable of displaying.

with sunny patches, or when viewing coloured surfaces successively in light of different illuminants, such as sunlight and tungsten light. We therefore asked subjects to view a coloured Mondrian in three modes. In the first, static mode, the wavelength composition of light coming from every patch in the display remained constant throughout the viewing period; in the second, varying intensity mode, the Mondrian was viewed in 'white light' whose intensity changed continuously, mimicking what would happen if an observer were to view a scene in one illuminant whose intensity varied. Here the total flux at any given wavelength, reflected from every patch, increased or decreased, without altering the wavelength composition, although this would of course necessitate a reassessment of ratios of lights of different wavebands reflected from different patches of the Mondrian. In the third, varying wavelength composition mode, we simulated a condition in which the Mondrian is viewed in illuminants whose wavelength composition changes continuously, entailing a change in both flux and wavelength composition of light coming from each square of the Mondrian, without affecting the ratio of light of any given waveband reflected from any two patches and without affecting their perceived colour. We suppose that ratios have to be taken in both the static and dynamic modes, but that the dynamic versions might be the computationally

more demanding ones. A comparison of the brain areas activated by viewing the dynamic and static versions of the Mondrian by using statistical parametric mapping (SPM) (Friston *et al.* 1995) highlighted the region shown in figure 3, known from our previous studies to be colour selective, although without involving nearly as much parallel activation of V1 and V2 as in our previous colour studies. However, our dynamic stimuli consistently activated two separate regions within this zone, a larger posterior zone with coordinates very similar to those given earlier by us for the human colour centre and a smaller anterior one, not described before (figure 3). We group both, which are separated by *ca.* 20 mm in the  $y$ -axis, in the V4 complex, distinguishing V4 proper from the more anterior V4 $\alpha$ . We note that in a report that appeared just as the first version of this paper was completed, Kastner *et al.* (1998), in a study of the cortical mechanisms involved in attention, have alluded briefly to much the same organization of the human V4 complex that we describe here, although they use the term TEO for V4 $\alpha$ . It would therefore seem that the colour centre of the human brain actually consists of two subdivisions, both of which are in some unknown way involved in colour computations. In the future, the complexity of the colour centre as revealed by these relatively new experiments might be one step in accounting for the variability of the syndrome of achromatopsia.

## 7. REANALYSIS OF EARLIER EVIDENCE

The antero-posterior extent of activation within the fusiform gyrus seen in our earlier studies made us re-examine the earlier evidence. Functional imaging data currently require a minimal spatial smoothing with a full-width-at-half-maximum filter of approximately twice the resolution of the acquired images to obtain an acceptable signal-to-noise ratio. The exact choice of the width for filtering the imaging data is more or less arbitrary, but must be guided by reason. There is no conclusive criterion, such as a cortical region positively labelled by the enzyme horseradish peroxidase in anatomical studies, or the certain attribution of a recording site by means of a small lesion passed at the end of a recording session. This creates a special problem for those who use imaging techniques: do they reveal the full extent of an area or is an area, as revealed, composed of two or more areas? Broader filters can improve the statistical significance of the results (and in multi-subject analyses eliminate variations between subjects); narrower filters improve the spatial resolution but decrease the signal-to-noise ratio, with the potential cost of missing out on activations that do not reach significant statistical values with such filters. The study reported here, in which we used the minimum filter described above, shows two separate sites of activation (figure 3) within the larger activated zone revealed by our previous studies, which used broader filters. Reason dictates that if the same colour-sensitive areas were activated in all these studies, then a reanalysis that uses less spatial smoothing (with full-width-at-half-maximum twice the image resolution) should reveal both zones also in the previous studies. Because of our new discovery, we reanalysed the earlier results of McKeefry & Zeki (1997) with the use of less spatial smoothing; this reanalysis revealed two colour-selective subdivisions (the activations were significant at  $p < 0.05$ , corrected for multiple comparisons ( $Z > 4.8$ ), which corresponds to  $p < 0.000001$ , uncorrected) and also showed that, whereas the posterior subdivision (V4) is topographically organized, the anterior (V4 $\alpha$ ) is not (figure 1a). The results also showed that the inferior fields are more strongly represented in V4 $\alpha$ , because a comparison of the superior colour stimulation versus superior achromatic stimulation with the inferior colour stimulation versus inferior achromatic stimulation did not result in an activation of V4 $\alpha$ , although the reverse comparison did. We conclude that, in addition to occupying different positions, the two zones of the V4 complex can be distinguished from one another by the presence of a distinct retinotopic map in V4 and its absence in V4 $\alpha$  (figure 1a). However, the fact that the inferior fields seem to be more strongly represented in V4 $\alpha$  suggests that it might be organized on different principles. Indeed, a survey of the published clinical literature based on colour perimetry (Kölmel 1988) would have told us that the two quadrants must be separately mapped within the V4 complex because of cases, for example Kölmel's patient 1, who had an achromatopsia restricted to one quadrant alone. This is yet another example of perimetric measurement as an indicator of the functional organization of the visual brain.

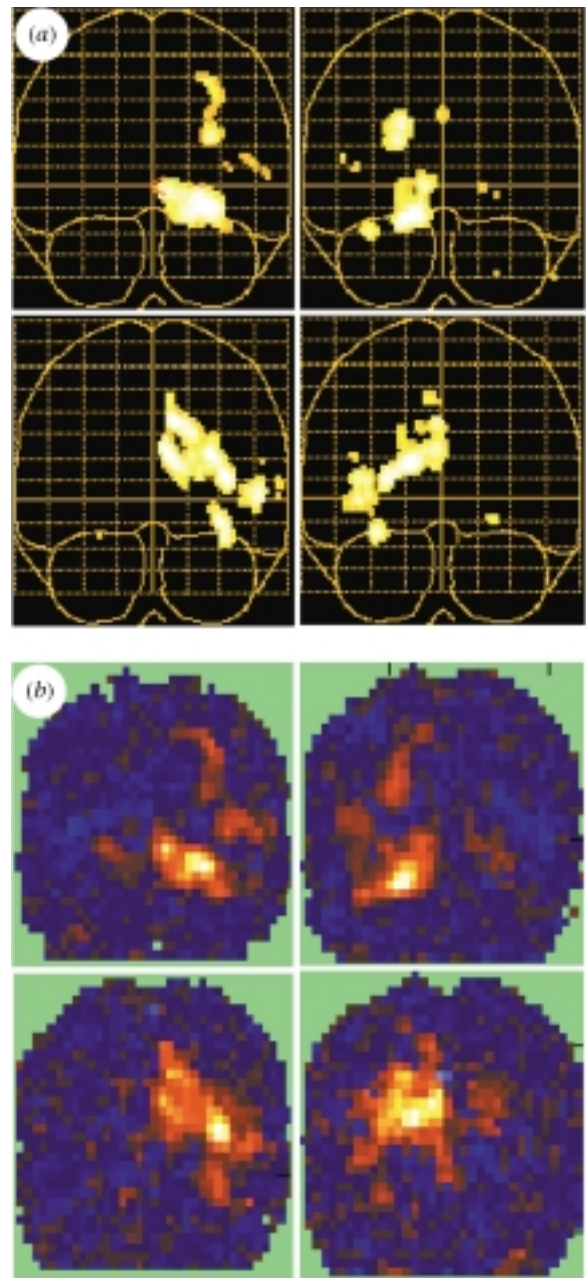


Figure 4. Analysis of data by SPM and ICA revealed that attention to the different quadrants of the visual field co-activated several visual areas in a retinotopic fashion. Coronal views are shown of glass-brain projections derived from (a) an SPM analysis in one subject, the comparison being (attention to colour and motion in one quadrant compared with attention to both attributes in the remaining three quadrants), thresholded at  $p < 0.05$  and corrected for multiple comparisons, and (b) an ICA of data from the same subject; the components are those whose time-courses correlated most closely with the conditions in which the subject paid attention to colour and motion in the respective quadrants. The brains are arranged such that the one depicting attention to the top right is located in the top right, and so on. Almost identical results were obtained in the other four subjects taking part in this study (not shown).

The arrangement of the human V4 complex that we describe here is similar to that found in the V4 complex of the macaque, an issue that does not fall within the purview of this article, and that we shall discuss in

greater detail elsewhere. It is worth emphasizing here that the two subdivisions of the V4 complex were revealed by relatively simple stimulation techniques. The more sophisticated techniques of phase reversal revealed the topographic organization of V4 itself only after it had been revealed by our technique, and so far they have failed to reveal the anterior subdivision of the V4 complex, area V4 $\alpha$ , probably because it lacks a retinotopic organization.

## 8. THE DETECTION AND MEASUREMENT OF COOPERATIVE ACTIVITY BY USING INDEPENDENT COMPONENT ANALYSIS

In the macaque monkey, the colour pathways leading to the V4 complex are relatively well charted. They include areas V1 and V2; similar pathways have been found in the human brain, any one of which could be involved in the ratio-taking operations that are critical for the generation and construction of colours. The reciprocal connections between these areas (Zeki & Shipp 1989; Nakamura *et al.* 1993; Rockland *et al.* 1994) make it equally likely that the operation is a cooperative one involving all these areas; this is especially so because, in monkeys, the wavelength-selective cells of V1 are indifferent to the colour of the stimulus but sensitive to changes in the wavelength composition of the light reflected from their receptive fields (Zeki 1983). A distributed ratio-taking process would mean that the results of the operations undertaken at different sites are reported to the perceptual site, area V4, damage to which causes the syndrome of cerebral colour blindness or achromatopsia. In fact, we were surprised to see so little activity in V1 and V2 in response to our dynamic stimuli. Our results therefore suggest that the ratio-taking process that is at the heart of the colour-generating mechanism is localized to the V4 complex, the key area that, when damaged, leads to cerebral achromatopsia, with the implication that the processing and perceptual sites for colour vision are one and the same (see also Bartels & Zeki 1998a; Zeki & Bartels 1999).

This raises an important problem of measurement. Our imaging evidence, in seemingly excluding V1 and V2 from the ratio-taking operation, gave us a counter-intuitive result. However, it also emphasized the importance of trying to map cooperative activity in a system that is itself cooperative or is at least inferred to be so from the richness of its reciprocal anatomical connections. Every area of the cortex has multiple inputs and outputs; the results of the operations performed by each must therefore be of interest to several others. However, not all these recipient areas are necessarily interested in the result of every operation performed by a given sending area. A very recently developed method, independent component analysis (ICA) (Bell & Sejnowski 1995) (see also Makeig *et al.*, this issue), can be used to isolate spatially independent maps of brain activity (McKeown *et al.* 1998). This algorithm, which is based on information theory, has the advantage that it is capable of decomposing or unmixing a signal that is a mixture of several other independent signals without any knowledge about the nature of the signal or its sources; it can therefore be used to isolate spatially independent

maps of brain activation without *a priori* knowledge about the stimulation. In fMRI experiments, one would assume the total brain activity to consist of a mixture of different maps, each fluctuating in a different manner over time, some caused by transient or consistent task-related activity, others by task-unrelated activity, noise and artefacts. If two brain areas are cooperating and therefore give rise to a consistent spatial activity pattern within or throughout the scanning period, one would expect ICA to separate them from other activity patterns; if a third area is activated with them only during some periods, ICA would isolate both the doublet and the triplet of areas as two independent activity patterns, representing two different activity maps of the brain. Naturally, one cannot assume different sites of activity within a single brain to be truly independent of each other, and the poor temporal resolution of image acquisition of 4 s and inherent differential response delays of the BOLD contrast impose further restrictions. It was therefore gratifying that, among the areas isolated by ICA in six out of ten subjects, V4 and V4 $\alpha$  were the only ones that occurred as pairs in the ventral occipital cortex, suggesting that they can function cooperatively as a single unit, without the involvement of other areas (figure 1b). That ICA did not isolate areas V1 and V2 together with V4 and show them to be cooperatively involved in the ratio-taking process nevertheless remains a puzzle, given the anatomical and physiological organization of the pathways leading to V4, at least in the monkey. Similarly surprisingly, SPM showed that activity in V2 and V1 correlated only minimally with the more demanding ratio-taking tasks (the dynamic conditions) that activated the V4 complex so intensely (figure 3a). It is therefore worth asking whether ICA is capable of always isolating areas that are cooperatively involved.

A simple check on this is to study another colour task and learn whether there is any hint of a cooperative involvement of V1–V2 on the one hand and V4 on the other that can be detected by ICA. Selective attention to colour or to motion selectively activates the centres specialized for those attributes, the V4 complex or the V5 complex, respectively (Corbetta *et al.* 1991). We wished to learn whether attention modulates the entirety of an area devoted to the attribute being attended to, or whether there is a retinotopy of attentional modulation. Moreover, we wished to learn whether early visual areas such as V1 and V2 would be modulated by attention as well, especially because earlier hypotheses, based on strictly anatomical and physiological criteria, had posited a crucial ‘window of attention’ role for the topographically organized area V2 (Shipp & Zeki 1989). The details of our attentional experiments are to be described elsewhere; in brief, they involved subjects fixating a central cross on a TV monitor while four squares, each containing both colour and motion and arranged so as to stimulate each of the four quadrants of the visual field separately but simultaneously, appeared on the screen. The subjects’ task was to attend to one attribute, namely colour or motion, in one of the quadrants of the visual field while fixating the central cross. The statistical analysis using SPM shows that several visual areas, including areas V2 and V4, are activated in a retinotopic fashion, when comparing brain activities obtained by



attention to the different locations (figure 4a). ICA isolated very similar maps of activation whose time-courses correlated with attention to different quadrants (figure 4b). With attention to colour, SPM showed that both the V4 complex and V2 significantly covary with the task (figure 5a), and ICA isolated an independent activity map in which the V4 complex is cooperatively active together with area V2 (whose time-course correlates with the corresponding task) (figure 5b). A comparison, with the use of SPM, of the cortical activity produced by attention to the upper and the lower field, respectively, showed that attention does not activate the whole of V4 but only those parts of V4 that represent the part of the field of view attended to; there is consequently a retinotopic modulation of V4 by attention (figure 5c,d). Thus our failure to detect any significant activity within V1 and V2 in imaging studies that were designed to detect the cortical site of the ratio-taking operations in colour vision cannot be due to an inadequacy of the use of SPM or ICA. Whatever the explanation is for the co-activation of V2 and the V4 complex in some visual tasks and the absence of such co-activation in others, we believe that the results given not only open up a new field of enquiry into the precise roles of areas V1 and V2 in colour vision (see below), but also show that seemingly subjective experiences such as attention, which enhance the percept of given attributes at given locations, can be mapped on the cortex, and thus measured, with an unimagined precision, given the strong association of attentional mechanisms to attributes and, apparently, to topographic location as well. We emphasize that the determination of cooperative activity is likely to become of increasing importance (Büchel *et al.* 1999) and we therefore hope that our study is only a prelude to further, more intensive, studies of the organization of the cerebral cortex. We emphasize, too, that SPM and ICA have revealed subdivisions that sophisticated techniques of stimulation and analysis with phase reversal and the presentation on unfolded cortices have failed to show.

## 9. THE RESIDUAL COLOUR VISION OF CARBON MONOXIDE-POISONED PATIENTS

Clinical evidence has reported another remarkable phenomenon, namely the relative sparing of colour vision in carbon monoxide-poisoned patients. The first such evidence was reported by Wechsler (1933) and, so improbable were his conclusions, that his findings too were relegated to oblivion for many years, although they have been confirmed several times over since then (reviewed by Zeki 1993b). Wechsler based his conclusions on an observation of a 13-year-old boy of high intelligence who had been admitted to hospital after being overcome by smoke during a fire at his home that had claimed the lives of five members of his family. He had been unconscious for 2 h when admitted. On recovery, he was found to be mentally retarded and severely impaired visually. 'The patient could not recognize small objects, such as a coin, key, pen or watch, and large objects, such as a book, newspaper or telephone, he could distinguish with difficulty.' His depth vision might also have been affected, for '[he] groped in trying to grasp objects, and sometimes

collided with persons and things, apparently because he could not estimate distance and probably as a result of a defect in visual spatial discrimination. . . . Color perception, on the other hand, was quick and accurate. He recognized not only all primary colors, but such shades as brown and pink. He knew at once the colors of small objects which he could neither name nor tell the form of. He picked out colors on command.'

How is one to account for this bizarre syndrome? Wechsler wrote:

'If color vision resides in the cortex and the surface of the brain was destroyed by the pathologic process, color vision should have been lost and not retained. The most probable answer is that either certain parts of the cortex or the layers presumed to perceive and elaborate color vision escaped destruction or they recovered while the visual areas did not. It is barely possible that there are special color-conducting fibers, but all evidence at hand points to the cortex as the seat of color vision. In any event, the case herein presented warrants the statement that color vision and visual acuity can be dissociated in such a way that the former is preserved while the latter is impaired'.

The observation is an interesting one and needs to be accounted for in terms of the organization of the visual brain. One suggestion (Zeki 1990) is that the divisions of V1 that are rich in wavelength-selective cells, the blobs, are known to be much more richly vascularized (Zheng *et al.* 1991) and are therefore more protected from the effects of hypoxia. The suggestion is not entirely satisfactory, if only because there are examples of reversible vascular insufficiency that are selectively accompanied by muscular weakness and reversible achromatopsia (Lapresle *et al.* 1977). Whatever the explanation, the condition is sufficiently interesting to merit further study. If the above suggestion has any validity, there are two possibilities. One is that the cells within blobs, being protected from the effects of hypoxia, have outward projections; these relay to V2 and to the V4 complex more or less normally, thus enabling the latter to undertake its task of constructing colours more or less normally. The other possibility is that area V4 is also damaged, with the consequence that the colour vision of such patients is wavelength-based, because the responses of cells within the blobs of area V1 and within the thin stripes of area V2 depend on wavelength composition and therefore do not correlate with perceived colour (Zeki 1983). If the latter explanation is correct, such a patient would not exhibit the phenomenon of colour constancy. In fact a recent clinical examination of a patient with a syndrome identical to that described by Wechsler but produced by a prolonged cardiac arrest (Humphrey *et al.* 1995) revealed that his colour vision was indeed very much wavelength-based in that, for example, a green surface that reflected a great deal more long-wavelength light appeared red or white to him, not green as it appears to normals (S. Zeki, S. Aglioti, D. McKeefry and G. Berlucchi, unpublished data). A study of the brain areas activated when this patient viewed coloured squares on the screen, compared with conditions under which he viewed their achromatic counterparts, revealed that the

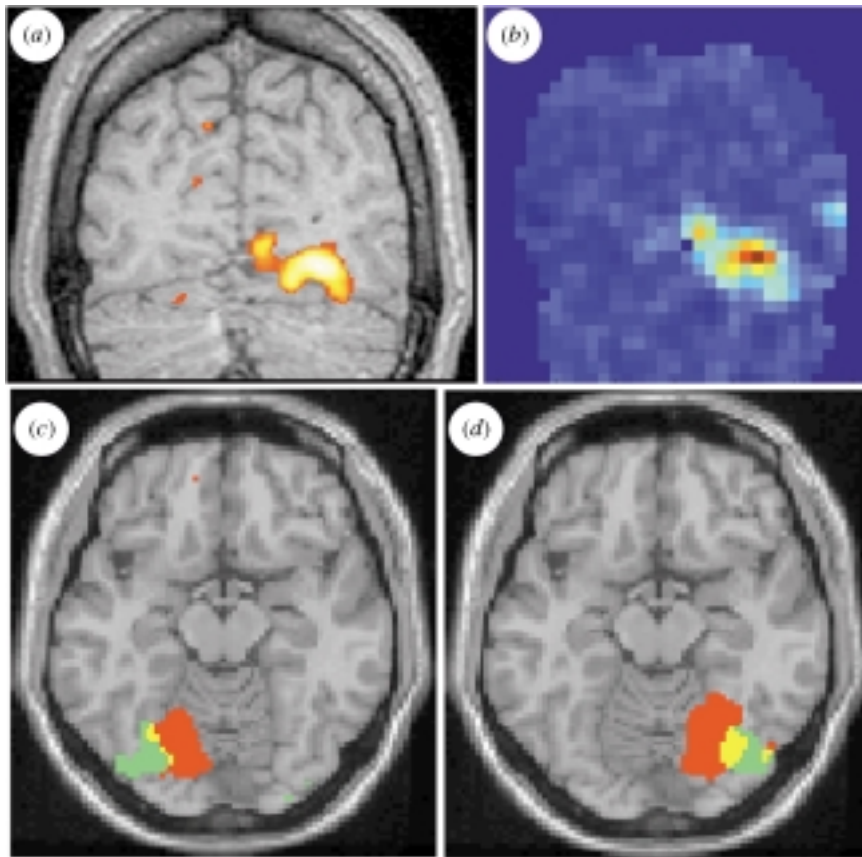


Figure 5. Cooperative activity in areas V4 and V2 and the retinotopic modulation of activity in V4 evoked by attention to quadrants in the upper and lower fields of view. (a) A coronal slice taken through an SPM, superimposed on a structural image of a single subject at  $y = -72$  mm (coordinates are as described in the legend to figure 3) for the comparison (attention to colour in the top left compared with attention to motion in all four quadrants) and thresholded at  $p < 0.001$ , uncorrected. V2 is medial; V4 is more lateral. (b) ICA isolated the same pattern of co-activation between areas V2 and V4 as revealed by SPM. The slice is taken at the same depth in the same subject for the independent component whose time-course correlated most closely with the condition in which the subject paid attention to colour in the top left quadrant. (c, d) Retinotopic modulation of V4 by attention to quadrants in the upper and lower hemifields. Horizontal slices were taken through SPMs at  $z = -14$  mm for the contrasts (attention to both colour and motion in one quadrant compared with attention to both attributes in the remaining three quadrants) (five subjects,  $p < 0.001$ , uncorrected; red, top quadrant; green, bottom quadrant) for quadrants within the right (c) or left (d) hemifields. Note the distinctly topographic organization of the activity produced, which respects the topography of V4 as determined in previous studies (McKeefry & Zeki 1997). The medial part of the red patches almost certainly includes area V2, which, at this ventral level, represents the upper quadrant (see (a) and (b)).

activity was localized to the calcarine cortex, presumably area V1. The absence of activity in V4 points to another weakness of imaging studies, in that we still do not have a clear idea of what measure of cortical activity to take as significant. However, the imaging of activity in a patient suffering from a syndrome described over 60 years ago has important consequences for deciding whether, and to what extent, activity in area V1 can contribute directly to conscious visual experience (Kulikowski *et al.* 1994; Crick & Koch 1995; Zeki & Bartels 1999). This problem is rendered even more emphatic by other clinical studies that show that patients rendered achromatopsic by lesions to V4 can discriminate remarkably well between lights of different wavelengths, although without being able to attribute colours to them (Victor *et al.* 1989; Vaina 1994). In this, V4-damaged patients differ markedly from patients suffering from carbon monoxide poisoning, who can discriminate between and name colours, even if for them the colours are very much wavelength-based. The point that we are making is that simple clinical measure-

ments and observations are a rich source of material to guide the measurement of brain activity with more sophisticated methods.

## 10. CONCLUSION

We have tried, in this article, to emphasize a point that seems to be important to us: that despite an increasing sophistication in the instruments that are able to detect and measure cortical activity, a high and honourable place must still be reserved for a much simpler and older technique, that of clinical observation. Ignorance of clinical findings can lead to misconceptions, as in the supposition that the lower occipital cortex can only represent upper visual fields. It is evident that no degree of measuring sophistication can guarantee a corrective to such misconceptions. However, acquaintance with the clinical literature can lead to more searching questions, to which instrumentation must always be subservient.

We thank Dominic ffytche for helpful discussions. This work is supported by the Wellcome Trust, London. A.B. is supported by the Swiss National Science Foundation.

## REFERENCES

- Albert, M. L., Reches, A. & Silverberg, R. 1975 Hemianopic colour blindness. *J. Neurol. Neurosurg. Psychiat.* **38**, 546–549.
- Bartels, A. & Zeki, S. 1998a The cortical site for the ratio-taking operations of the colour system. *Neurosci. Abst.* **24**, 1977.
- Bartels, A. & Zeki, S. 1998b The theory of multi-stage integration in the visual brain. *Proc. R. Soc. Lond. B* **265**, 2327–2332.
- Beckers, G. & Zeki, S. 1995 The consequences of inactivating areas V1 and V5 on visual-motion perception. *Brain* **118**, 49–60.
- Bell, A. J. & Sejnowski, T. J. 1995 An information maximization approach to blind separation and blind deconvolution. *Neural Comput.* **7**, 1129–1159.
- Bornstein, B. & Kidron, D. P. 1959 Prosopagnosia. *J. Neurol. Neurosurg. Psychiat.* **22**, 124–131.
- Büchel, C., Coull, J. T. & Friston, K. J. 1999 The predictive value of changes in effective connectivity for human learning. *Science* **283**, 1538–1541.
- Corbetta, M., Miezin, F., Dobmeyer, S., Shulman, G. L. & Petersen, S. E. 1991 Selective and divided attention during visual discriminations of shape, color, and speed: functional anatomy by positron emission tomography. *J. Neurosci.* **11**, 2383–2402.
- Cragg, B. G. 1969 The topography of the afferent projections in circumstriate visual cortex studied by the Nauta method. *Vision Res.* **9**, 733–747.
- Crick, F. & Koch, C. 1995 Are we aware of neural activity in primary visual cortex? *Nature* **375**, 121–123.
- Damasio, A. R. 1985 Disorders of complex visual processing agnosias, achromatopsia, Balint's syndrome, and related difficulties of orientation and construction. In *Principles of behavioural neurology* (ed. M. M. Mesulam), pp. 259–288. Philadelphia, PA: Davis.
- Damasio, A., Yamada, T., Damasio, H., Corbett, J. & McKee, J. 1980 Central achromatopsia: behavioural, anatomic, and physiologic aspects. *Neurology* **30**, 1064–1071.
- Daniel, P. M. & Whitteridge, D. 1961 The representation of the visual field on the cerebral cortex in monkeys. *J. Physiol. (Lond.)* **159**, 203–221.
- DeYoe, E. A. & Van Essen, D. C. 1988 Concurrent processing streams in monkey visual cortex. *Trends Neurosci.* **11**, 219–226.
- DeYoe, E. A., Carman, G. J., Bandettini, P., Glickman, S., Wieser, J., Cox, R., Miller, D. & Neitz, J. 1996 Mapping striate and extrastriate visual areas in human cerebral cortex. *Proc. Natl Acad. Sci. USA* **93**, 2382–2386.
- Engel, S. A., Rummelhart, D. E., Wandell, B. A., Lee, A. H., Glover, G. H., Chichilnisky, E.-J. & Shadlen, M. N. 1994 fMRI of human visual cortex. *Nature* **369**, 525.
- ffytche, D. H., Guy, C. N. & Zeki, S. 1995 The parallel visual motion inputs into areas V1 and V5 of human cerebral cortex. *Brain* **118**, 1375–1394.
- Friston, K. J., Holmes, A. P., Poline, J. B., Grasby, P. J., Williams, S. C. R., Frackowiak, R. S. J. & Turner, R. 1995 Analysis of fMRI time-series revisited. *NeuroImage* **2**, 45–53.
- Girard, P., Salin, P. A. & Bullier, J. 1992 Response selectivity of neurons in area MT of the macaque monkey during reversible inactivation of area V1. *J. Neurophysiol.* **67**, 1437–1446.
- Guy, C. M., ffytche, D. H., Brovelli, A. & Chumillas, J. 1999 fMRI and EEG responses to periodic visual stimulation. *NeuroImage*. (In the press.)
- Hadjikhani, N., Liu, A. K., Dale, A., Cavanagh, P. & Tootell, R. B. H. 1998 Retinotopy and color sensitivity in human visual cortical area V8. *Nature Neurosci.* **1**, 235–241.
- Helmholtz, H. v. 1911 *Handbuch der Physiologischen Optik*. Hamburg: Leopold Voss.
- Henschen, S. E. 1893 On the visual path and centre. *Brain* **16**, 170–180.
- Heywood, C. & Cowey, A. 1998 With color in mind. *Nature Neurosci.* **1**, 171–173.
- Holmes, G. 1918 Disturbances of vision caused by cerebral lesions. *Br. J. Ophthalmol.* **2**, 353–384.
- Horton, J. C. & Hoyt, W. F. 1991 Quadrantic visual field defects: a hallmark of lesions in extrastriate (V2/V3) cortex. *Brain* **114**, 1703–1718.
- Hubel, D. H. & Livingstone, M. S. 1987 Segregation of form, color and stereopsis in primate area 18. *J. Neurosci.* **7**, 3378–3415.
- Humphrey, G. K., Goodale, M. A., Corbetta, M. & Aglioti, S. 1995 The McCollough effect reveals orientation discrimination in a case of cortical blindness. *Curr. Biol.* **5**, 545–551.
- Inouye, T. 1909 *Die Sehstörungen bei Schussverletzungen der Körtikalen Sehphäre, nach Beobachtungen an Verwundeten der letzten japanischen Kriege*. Leipzig: W. Engelmann.
- Jaeger, W., Krastel, H. & Braun, S. 1989 Cerebrale Achromatopsie. *Klin. Mbl. Augenheilk.* **194**, 32–36.
- Kastner, S., DeWeerd, P., Desimone, R. & Ungerleider, L. C. 1998 Mechanisms of directed attention in the human extrastriate cortex as revealed by functional MRI. *Science* **282**, 108–111.
- Kennard, C., Lawden, M., Moreland, A. B. & Ruddock, K. H. 1995 Colour identification and colour constancy are impaired in a patient with incomplete achromatopsia associated with prestriate cortical lesions. *Proc. R. Soc. Lond. B* **260**, 169–175.
- Kölmel, H. W. 1988 Pure homonymous hemiachromatopsia: findings with neuro-ophthalmologic examination and imaging procedures. *Eur. Arch. Psychiatr. Neurol. Sci.* **237**, 237–243.
- Kulikowski, J. J., Walsh, V., McKeefrey, D., Butler, S. R. & Carden, D. 1994 The electrophysiological basis of colour processing in macaques with V4 lesions. *Behav. Brain Res.* **60**, 73–78.
- Land, E. 1974 The retinex theory of colour vision. *Proc. R. Inst. G. Br.* **47**, 23–58.
- Lapesle, J., Metreau, R. & Annabi, A. 1977 Transient achromatopsia in vertebrobasilar insufficiency. *J. Neurol.* **215**, 155–158.
- Lueck, C. J., Zeki, S., Friston, K. J., Deiber, M. P., Cope, P., Cunningham, V. J., Lammertsma, A. A., Kennard, C. & Frackowiak, R. S. 1989 The colour centre in the cerebral cortex of man. *Nature* **340**, 386–389.
- MacKay, G. & Dunlop, J. C. 1899 The cerebral lesions in a case of complete acquired colour blindness. *Scott. Med. Surg. J.* **5**, 503–512.
- McKeefrey, D. & Zeki, S. 1997 The position and topography of the human colour centre as revealed by functional magnetic resonance imaging. *Brain* **120**, 2229–2242.
- McKeown, M. J., Makeig, S., Brown, G. G., Jung, T. P., Kindermann, S. S., Bell, A. J. & Sejnowski, T. S. 1998 Analysis of fMRI data by blind separation into independent spatial components. *Hum. Brain Mapp.* **6**, 160–188.
- Nakamura, M., Gattass, R., Desimone, R. & Ungerleider, L. G. 1993 The modular organization of projections from areas V1 and V2 to areas V4 and TEO in macaques. *J. Neurosci.* **13**, 3681–3691.
- Ogden, J. A. 1993 Visual object agnosia, prosopagnosia, achromatopsia, loss of visual imagery, and autobiographical amnesia following recovery from cortical blindness: case M.H. *Neuropsychologia* **31**, 571–589.
- Paulson, H. L., Galetta, S. L., Grossman, M. & Alavi, A. 1994 Hemiachromatopsia of unilateral occipitotemporal infarcts. *Am. J. Ophthalmol.* **118**, 518–523.

- Pearlman, A., Birch, J. & Meadows, J. C. 1979 Cerebral color blindness: an acquired defect in hue discrimination. *Ann. Neurol.* **5**, 253–261.
- Riddoch, G. 1917 Dissociations of visual perception due to occipital injuries, with especial reference to appreciation of movement. *Brain* **40**, 15–57.
- Rizzo, M., Smith, V., Pokorný, J. & Damasio, A. R. 1993 Colour perception profiles in central achromatopsia. *Neurology* **43**, 995–1001.
- Rockland, K. S., Saleem, K. S. & Tanaka, K. 1994 Divergent feedback connections from area V4 and TEO in the macaque. *Visual Neurosci.* **11**, 579–600.
- Rodman, R., Gross, C. G. & Albright, T. D. 1989 Afferent basis of visual response properties in area MT of the macaque. I. Effects of striate cortex removal. *J. Neurosci.* **9**, 2033–2050.
- Sereno, M. I., Dale, A. M., Reppas, J. B., Kwong, K. K., Belliveau, J. W., Brady, T. J., Rosen, B. R. & Tootell, R. B. H. 1995 Borders of multiple visual areas in humans revealed by functional magnetic resonance imaging. *Science* **268**, 889–893.
- Shipp, S. & Zeki, S. 1989 The organization of connections between areas V5 and V2 in macaque monkey visual cortex. *Eur. J. Neurosci.* **1**, 333–354.
- Tootell, R. B. H. & Hadjikhani, N. 1998 Has a new color area been discovered?—Reply. *Nature Neurosci.* **1**, 335–336.
- Tootell, R. B., Dale, A. M., Sereno, M. I. & Malach, R. 1996 New images from human visual cortex. *Trends Neurosci.* **19**, 481–489.
- Tootell, R. B. H., Dale, A. M., Mendola, J. D., Hadjikhani, N. & Brandt, S. A. 1997a Functional organization of human visual cortex revealed by fMRI. *Invest. Ophthalmol. Vis. Sci.* **38**, S493 (abstract no. 2273).
- Tootell, R. B. H., Mendola, J. D., Hadjikhani, N. K., Ledden, P. J., Liu, A. K., Reppas, J. B., Sereno, M. I. & Dale, A. M. 1997b Functional analysis of V3A and related areas in human visual cortex. *J. Neurosci.* **17**, 7060–7078.
- Vaina, L. M. 1994 Functional segregation of color and motion processing in the human visual cortex: clinical evidence. *Cerebr. Cortex* **4**, 555–572.
- Van Essen, D. C. & Zeki, S. M. 1978 The topographic organization of rhesus monkey prestriate cortex. *J. Physiol. (Lond.)* **277**, 193–226.
- Verrey, D. 1888 Hémichromatopsie droite absolue. Conservation partielle de la perception lumineuse et des formes. Ancien kyste hémorragique de la partie inférieure du lobe occipital gauche. *Arch. d'Ophthalmol. (Paris)* **8**, 289–300.
- Victor, J. D., Maiese, K., Shapley, R., Sidtis, J. & Gazzaniga, M. S. 1989 Acquired central dyschromatopsia—analysis of a case with preservation of color discrimination. *Clin. Vis. Sci.* **4**, 183–196.
- Walsh, V., Carden, D., Butler, S. R. & Kulikowski, J. J. 1993 The effects of V4 lesions on the visual abilities of macaques: hue discrimination and colour constancy. *Behav. Brain Res.* **53**, 51–62.
- Wechsler, I. S. 1933 Partial cortical blindness with preservation of colour vision: report of a case following asphyxia (carbon monoxide poisoning?). *Arch. Ophthalmol.* **9**, 957–965.
- Young, R. S. L., Fishman, G. A. & Chen, F. 1980 Traumatically acquired color vision defect. *Invest. Ophthalmol. Vis. Sci.* **19**, 545–549.
- Zeki, S. M. 1969 Representation of central visual fields in prestriate cortex of monkey. *Brain Res.* **14**, 271–291.
- Zeki, S. M. 1978 Uniformity and diversity of structure and function in rhesus monkey prestriate visual cortex. *J. Physiol. (Lond.)* **277**, 273–290.
- Zeki, S. 1983 Colour coding in the cerebral cortex: the reaction of cells in monkey visual cortex to wavelengths and colours. *Neuroscience* **9**, 741–765.
- Zeki, S. 1990 A century of cerebral achromatopsia. *Brain* **113**, 1721–1777.
- Zeki, S. 1991 Cerebral akinetopsia (visual motion blindness). A review. *Brain* **114**, 811–824.
- Zeki, S. 1993a The mystery of Louis Verrey (1854–1916). *Gesnerus* **50**, 96–112.
- Zeki, S. 1993b *A vision of the brain*. Oxford: Blackwell.
- Zeki, S. & Bartels, A. 1999 Toward a theory of visual consciousness. *Consc. Cogn.* (In the press.)
- Zeki, S. & fytche, D. 1998 The Riddoch syndrome: insights into the neurobiology of conscious vision. *Brain* **121**, 25–45.
- Zeki, S. & Shipp, S. 1988 The functional logic of cortical connections. *Nature* **335**, 311–317.
- Zeki, S. & Shipp, S. 1989 Modular connections between areas V2 and V4 of macaque monkey visual cortex. *Eur. J. Neurosci.* **1**, 494–506.
- Zeki, S., Watson, J. D. G., Lueck, C. J., Friston, K. J., Kennard, C. & Frackowiak, R. S. J. 1991 A direct demonstration of functional specialization in human visual cortex. *J. Neurosci.* **11**, 641–649.
- Zeki, S., McKeefry, D. J., Bartels, A. & Frackowiak, R. S. J. 1998 Has a new color area been discovered? *Nature Neurosci.* **1**, 335.
- Zheng, D., LaMantia, A. S. & Purves, D. 1991 Specialized vascularization of the primate visual cortex. *J. Neurosci.* **11**, 2622–2629.