

INFECTIOUS THROMBOEMBOLIC MENINGOENCEPHALITIS:
LITERATURE REVIEW AND OCCURRENCE IN ALBERTA, 1969-71

D. W. MacDonald, R. G. Christian and G. A. Chalmers*

INFECTIOUS THROMBOEMBOLIC MENINGOENCEPHALITIS (ITEME) is an acute septicemia and encephalitis, reported only in feeder cattle and characterized by fever, incoordination, posterior paresis, lateral recumbency and death. The causative agent is a Gram-negative rod described as *Actinobacillus actinoides*-like (2), an *Hemophilus*-like organism (8), or as *Hemophilus somnus* (3).

HISTORICAL REVIEW

The disease was reported in Colorado as early as 1956 when it was suggested that the condition was secondary to a variety of primary conditions (6).

The clinical and pathological description of an infectious meningoencephalitis in cattle and the experimental reproduction of the disease using a bacterium identified as "*Hemophilus*-like" (8), were reported from California in 1960. ITEMME was reported to be one of the three most common causes of bovine neurologic disease in feedlots in Minnesota in 1963 (9). In 1966, Bailie who described the condition in feedlot steers and heifers in Kansas, reported that a presumptive diagnosis could be made on the basis of history, gross lesions and early clinical signs, with a final diagnosis based on microscopic examination of the brain (2).

Pancier, Dahlgren and Rinker described the disease in cattle in the feeding areas of Oklahoma and the Texas Panhandle dating from 1963 (10).

The syndrome was first described in Canada in 1970 Ontario feedlot cattle (11).

Clinical Findings

ITEMME has previously been reported to affect cattle one to three years of age weighing 750 to 1100 pounds after they have been on feed approximately six weeks (2, 11). The disease is a septicemia which leads to vasculitis and thrombosis (10), and may be expressed in several syndromes; peracute and neurologic, acute and respiratory, subacute to chronic and arthritic or an amalgam (11).

Often the first sign of the disease is the finding of dead cattle. Early clinical signs are slight lameness, reluctance to move and stiffness with "knuckling" at the fetlocks. Rectal temperature may be as high as 107°F (2). This prodromal state may last up to 12 hours followed by incoordination and paresis. (Kennedy, P.C. Personal communication 1970.) Cattle tend to hold their heads in a peculiar up and out position. Circling may occur in some and blindness, if present, may be present in one or both eyes. Abnormal eye movements such as strabismus and nystagmus occur. Cattle in lateral recumbency will display opisthotonus, muscular tremors and paddling movements. Death occurs in recumbent cattle in a few hours; a few have been known to live for as long as two weeks (2).

Mortality rates are as high as 1% in some feedlots, based on a full year's volume of cattle. Mortality in cattle which have developed signs of the disease is over 95% (2).

Gross Lesions

The pertinent gross lesions are usually confined to the brain. Characteristically there is flattening of the cerebral gyri with the presence of small dark soft red depressions on the surface of the cerebral hemispheres. Small dark soft red areas may be observed on the

*Alberta Department of Agriculture, Veterinary Services Division, Edmonton Laboratory (MacDonald and Christian); Lethbridge Laboratory (Chalmers).

Presented to the Alberta Veterinary Medical Association's Mid Winter Conference at Red Deer, Alta., Feb. 12, 1972.

cut surface in all areas of the brain but are most obvious at the junctions of the gray and white matter of the cerebral cortex. The lesions are bilateral but not necessarily symmetrical in distribution (11). Sterile brain abscesses may result if treatment is given and the duration of the disease extended (7).

Arthritis affecting the stifle, carpal and tarsal joints was reported from Ontario (11). Other lesions, including polyarthritis involving nearly all the diarthrodial joints, pseudomembranous laryngitis, petechial hemorrhages on serous surfaces and on various visceral organs and regional or generalized lymphadenitis characterized by congestion, edema and hemorrhage have been reported in the United States (10).

Focal retinal hemorrhages and several "cotton spots" suggestive of edema were the gross ocular lesions reported in feedlot cattle in Ontario (5).

Microscopic Lesions

Intense vasculitis, thrombosis with or without infarction, and a cellular exudate composed entirely of neutrophils typify the host's response to the infection. These lesions occur in many organs but are present consistently in the brain and in the cerebral meninges. In some areas the inflammatory process is limited to the vascular wall and the immediate perivascular area, in which instance, vascular adventitial cells are hypertrophied with histiocytes occupying Virchow-Robin spaces. In other areas, thrombosis, hemorrhage and infarction are common and in these areas the inflammatory process extends into the surrounding neuropil where the cellular reaction is almost entirely neutrophilic. Fibrinopurulent meningitis usually accompanies the encephalitis and occasionally constitutes the major lesion in the central nervous system (10).

Thrombosis of pulmonary veins and capillaries resulting in an embolic pneumonia has been observed (11). The laryngeal lamina propria and submucosa were predominantly affected but occasional lesions extend deeply to involve the intrinsic musculature and perichondrium. The laryngeal mucosa was intact over much of the affected submucosa but in areas where thrombosis was especially prevalent, ulceration occurred (10).

Renal lesions consisting of hyaline thrombi and bacterial emboli in capillaries of glomerular tufts and in interstitial blood vessels at the cortico-medullary junction were observed in one animal. Focal areas of tubular necrosis with neutrophilic and mononuclear cellular

reactions were evident around thrombosed capillaries at the cortico-medullary junction (11).

Focal or diffuse inflammation marked by capillary thrombosis and neutrophilic infiltration in the peritoneum, hepatic capsule, pleura, and pericardium were noted in some cases. Overlying mesothelial cells were swollen or denuded, and a fibrinous or fibrinopurulent exudate adhered to the affected serosal surfaces (10).

Changes in synovial membranes and tendon sheaths during the acute phase included congestion and edema, swelling of endothelial cells, aggregation and margination of intravascular neutrophils, and exudation of neutrophils into the loose connective tissue and the synovial cell layer (10).

Foci of vasculitis, thrombosis and attendant parenchymal inflammation or infarction were frequent in the myocardium, kidney, liver, mucosa of the urinary bladder, lung, skeletal muscle and thymus (10).

Superficial retinal hemorrhage, thrombosis and focal areas of necrosis containing aggregations of neutrophils have been described in the eyes of feedlot cattle (5).

Clinical Treatment

Treatment with large doses of streptomycin or broad spectrum antibiotics in the very early stages was highly effective, but animals with advanced signs responded poorly (2). Withdrawal of excess cerebrospinal fluid and injection of an antibiotic may be of value in advanced cases (4). The chronic course may be extremely prolonged with antibiotic therapy but a recumbent animal rarely becomes ambulatory again although it may survive and regain its appetite (9).

Bacteriology

The causative organism was cultured successfully on 5% citrated bovine blood in trypticase soy agar base and on chocolate agar from brains stored for one month at -20°C . Cultures were incubated for 48 hours at 37°C both aerobically and in an atmosphere of 5 to 10% CO_2 (11). Organisms have been isolated from blood (8), cerebrospinal fluid, pericardial, and synovial fluids of naturally occurring cases (10).

The organism isolated from a California outbreak was sensitive *in vitro* to chloramphenicol, dihydrostreptomycin, penicillin, polymyxin B, oxytetracycline and erythromycin (8).

MATERIALS AND METHODS

For the present report, the records of 33 submissions¹ were examined to determine the yearly prevalence of disease and distribution of the affected premises.

Except for the submission of a few carcasses, post mortem examinations were confined to the brains of affected animals submitted by practitioners. Tissues were fixed in 10% neutral buffered formalin, sectioned at six microns and stained with hematoxylin and eosin.

Tissues were cultured on bovine blood, cystine heart and chocolate agar and incubated at 37°C both aerobically and in an atmosphere of 5 to 10% CO₂.

Occurrence in Alberta

The disease was diagnosed initially from the formalized brain of a nine month old steer from Central Alberta in January 1969. Diagnosis was based on the characteristic histopathological changes (1). A diagnosis of ITEMÉ was made in two laboratory accessions in 1969, two in 1970 and 29 in 1971. Losses in southern Alberta were generally small, but at least 35 of 400 died of ITEMÉ in one herd. ITEMÉ appeared to be confined to central and southern Alberta prior to 1971. During 1971, an apparent increase and an apparent spread of the disease to northern and northeastern Alberta occurred (Figure 1).

Clinical Signs

Clinical signs reported by practitioners included lethargy, frothing at the mouth, "knuckling" of the hind limbs, lameness, convulsions, coma and death. The condition in Alberta usually affected feedlot animals six to nine months of age.

Gross Lesions

Gross examinations of several entire carcasses did not reveal visible lesions in the organs of the thoracic or abdominal cavities; however, in some cases, there was mild to moderate splenic enlargement. Gross lesions were not observed in any of several joints examined.

Fibrinous cerebrospinal meningitis involving the brain and spinal cord was a common finding. In one case, there was marked fibrinous reaction surrounding the lumbo-sacral area of the spinal cord, including the cauda equina. Gross lesions similar to those described in the literature review were usually evident in vari-

¹Alberta Department of Agriculture, Veterinary Services Division, Edmonton and Lethbridge Diagnostic Laboratories.

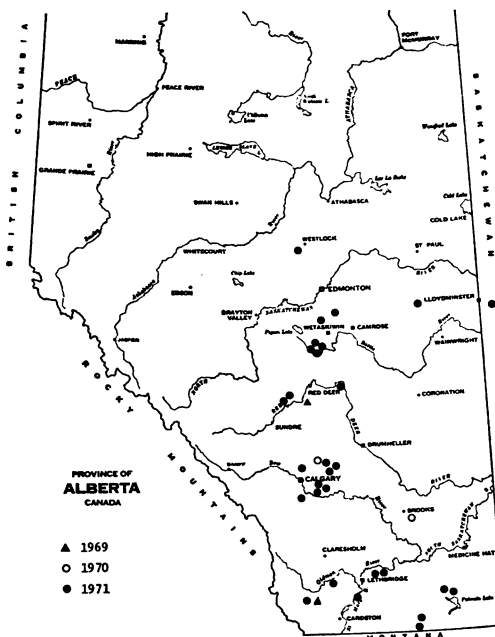


FIGURE 1. Laboratory diagnoses of ITEMÉ in Alberta cattle 1969-71.

ous areas of the brain and were occasionally marked in the spinal cord as well. In several animals, turbid cerebrospinal fluid containing fibrin tags was seen in the lateral ventricles. In a minority of cases gross lesions were not observed but lesions typical of ITEMÉ were obvious on histopathological examination of the brains.

Microscopic Lesions

Acute vasculitis, with or without thrombosis and involving many vessels of the brain, was a prominent feature of the disease (Figure 2). Bilateral but not symmetrical lesions characterized by focal hemorrhages, meningitis and focal inflammation with a cellular exudate composed almost entirely of neutrophils were observed in all areas of the brain, but were most common at the junction of the gray and white matter of the cerebral cortex.

Acute vasculitis with thrombosis was noted in the lung of one animal.

Bacteriological Examinations

The causative organism was isolated from 11 of the 33 laboratory accessions in which the disease was diagnosed. The organism was isolated in some from fresh brains using both cystine heart agar and chocolate agar incubated at 37°C in 5 to 10% CO₂. The initial isolation in some cases was made on bovine

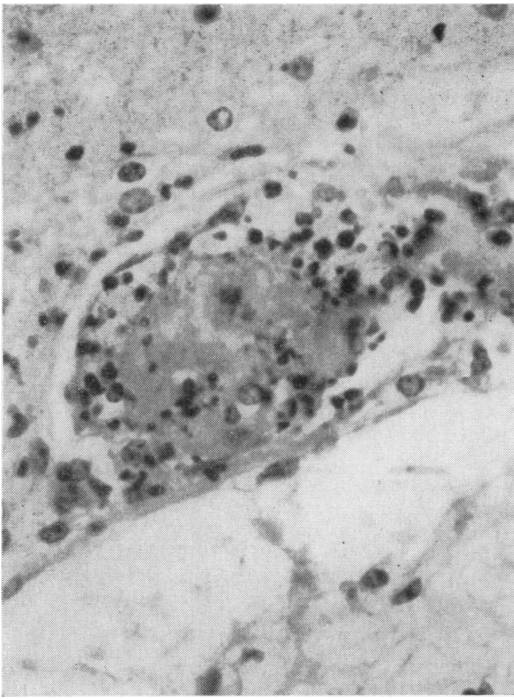


FIGURE 2. Vasculitis and thrombosis in a cerebral vessel. Cerebrum $\times 500$.

or ovine blood agar incubated in a 10% CO₂ atmosphere. The organisms would not grow initially under aerobic conditions but usually would adapt after two weeks or more incubation under CO₂.

Acid was usually produced in glucose, maltose, and trehalose with 1% bovine serum occurring after isolates were adapted to aerobic conditions. Dulcitol, inositol, raffinose, adonitol, salacin and melibiose gave consistently negative results. Variable acid production was obtained in arabinose, mannitol, xylose, lactose, sucrose, mannose, levulose and galactose. Results varied for the production of indole, oxidase and catalase.

The organism was not resistant to any of the standard antibiotics and antibiotic testing *in vitro* of two different isolates revealed that it was sensitive to penicillin, erythromycin, chloramphenicol, Furacin, ampicillin, sulfathiazole, tetracyclines and lincomycin.

Differential Diagnosis

The disease must be differentiated from polyoencephalomalacia, listeriosis, other types of bacterial meningoencephalitis and any poisoning which can cause sudden death, such as heavy metals, chlorinated hydrocarbons, organophosphates and urea (11). In fact, any

disease causing "sudden death" should be considered in the differential diagnosis of this disease. The lesions are not always visible on gross examination which emphasizes the need for histopathological and bacteriological examination of brains from feeder cattle which die suddenly without premonitory signs.

The disease is most likely to be confused clinically with polyoencephalomalacia. Polyoencephalomalacia produces less temperature elevation, the course is usually longer, and most animals show hyperesthesia, nystagmus, opisthotonus, and convulsions before death (11). Good response to treatment early in the course of ITEMÉ has been reported (4) but in the experience of the authors, it seldom effects clinical recovery. Two characteristics of polyoencephalomalacia which may assist in differentiating it from ITEMÉ are response to thiamin therapy and constant blindness. In addition, examination of cerebrospinal fluid (CSF) may assist in the diagnosis. In ITEMÉ, the fluid may be clear or turbid; a direct smear invariably reveals an increased number of cells, predominantly neutrophils. In polyoencephalomalacia there are fewer total cells, and neutrophils never dominate (9).

DISCUSSION

From 1969 to 1971, ITEMÉ was diagnosed in a total of 33 laboratory accessions in Alberta. Conversations with practitioners suggested that the disease is probably more common than the numbers of laboratory diagnoses indicated.

Limited experience would indicate that the disease was encountered generally in younger feedlot animals (six to nine months of age) in Alberta than in the American midwest (2). Necropsies performed on a limited number of entire carcasses failed to demonstrate arthritis. The increase in the number of laboratory diagnoses suggest an increased incidence in 1971 as well as perhaps greater awareness of its existence, and an apparent spread from southern and central Alberta to northern and northeastern Alberta.

SUMMARY

Diagnoses of infectious thromboembolic meningoencephalitis were made in a total of 33 laboratory accessions in the years 1969-71 in cattle from Alberta. Diagnoses were based chiefly on histopathological and/or bacteriological examination of brains of affected animals. The disease was encountered in young feedlot animals. An increase in prevalence and

apparent spread of the disease to the north and northeast areas of the province was noted.

RÉSUMÉ

De 1969 à 1971, les auteurs ont diagnostiqué 33 cas de méningo-encéphalite thrombo-embolique infectieuse, chez des bovins de l'Alberta. Leur diagnostic s'appuyait surtout sur l'examen histopathologique et/ou bactériologique du cerveau des animaux atteints. La maladie affectait des jeunes sujets de parcs d'engraissement. Les auteurs ont aussi remarqué une augmentation de la fréquence de cette maladie et sa propagation apparente jusqu'au nord et au nord-est de la province.

ACKNOWLEDGEMENTS

The authors wish to acknowledge the assistance of Mr. Jim Letal and Mrs. Shirley Rawluk in the bacteriological characterization of the organisms isolated. The assistance of Drs. F. E. Graesser and John Howell in the photography is gratefully acknowledged.

REFERENCES

1. ANNUAL REPORT of the Veterinary Services Branch. p. 26. Edmonton: Dept. of Agriculture for the Province of Alberta. 1969.
2. BAILIE, W. E., H. D. ANTHONY and K. D. WEIDE. Infectious thromboembolic meningo-encephalomyelitis (Sleepers Syndrome) in feedlot cattle. J. Am. vet. med. Ass. 148: 162-166. 1966.
3. BAILIE, W. E. Characterization of *Haemophilus somnus* (new species), a micro-organism isolated from infectious thromboembolic meningoencephalomyelitis of cattle. Thesis. Kansas State University. 1969.
4. BLOOD, D. C. and J. A. HENDERSON. Veterinary Medicine. Third Edition. pp. 386-387. London: Baillière, Tindall and Cassell. 1968.
5. DUKES, T. W. The ocular lesions in thromboembolic meningoencephalitis (ITEME) of cattle. Can. vet. J. 12: 180-182. 1971.
6. GRINER, L. A., R. JENSEN and W. W. BROWN. Infectious embolic meningo-encephalitis in cattle. J. Am. vet. med. Ass. 129: 417-421. 1956.
7. JUBB, K. V. F. and P. C. KENNEDY. Pathology of Domestic Animals. Second Edition. Vol. 2. p. 410. New York: Academic Press. 1970.
8. KENNEDY, P. C., L. BIBERSTEIN, J. A. HOWARTH, L. M. FRASIER and D. L. DUNGWORTH. Infectious meningo-encephalitis in cattle caused by *Haemophilus*-like organism. Am. J. vet. Res. 21: 403-409. 1960.
9. LITTLE, P. B. and D. K. SORENSEN. Bovine polioencephalomalacia, infectious embolic meningoencephalitis and acute lead poisoning in feedlot cattle. J. Am. vet. med. Ass. 155: 1892-1903. 1969.
10. PANCIERA, R. J., R. R. DAHLGREN and H. B. RINKER. Observations on a septicaemia of cattle caused by a *Haemophilus*-like organism. Pathologia vet. 5: 212-226. 1968.
11. VAN DREUMEL, A. A., R. A. CURTIS and H. L. RUHNKE. Infectious thromboembolic meningoencephalitis in Ontario feedlot cattle. Can. vet. J. 11: 125-130. 1970.

ABSTRACT

Breese, S. S., Jr. & McCollum, Wm. H. Equine arteritis virus: ferritin-tagging and determination of ribonucleic acid core. - Archiv für die gesamte Virusforschung (1971) 35 No. 2/3, 290-295. (USDA Plum Island Anim. Dis. Lab., PO Box 848, Greenport, Long Island, New York 11944).

was identified in infected cultures of equine dermis cells by both direct and indirect ferritin tagged antibody systems. Differential cytochemical staining in both glycolmethacrylate and 'Epon'-embedded thin sections showed that EAV has RNA core.

Equine arteritis virus (EAV), Bucyrus strain,

Reprinted from "The Veterinary Bulletin", Vol. 42, No. 4, April, 1972.