

## CASE REPORT

### NATURAL INFECTION AND TREATMENT OF A DOG WITH *MESOCESTOIDES* TAPEWORMS

G. SPECKMANN AND W. A. WEBSTER\*

#### Introduction

Infections due to *Mesocestoides* spp. are infrequently encountered in domestic carnivores in North America and information on anthelmintic control measures is scant. The present communication reports the natural occurrence of *Mesocestoides* in a dog from Ontario and the anthelmintic therapy employed.

#### History and Clinical Findings

In October 1973 the owner of an eight-week-old female miniature poodle requested an oral anthelmintic without submitting a fecal sample for examination. The dog, living in a rural area, was described as being inappetent with slight loss of weight. The owner had observed whitish "worms" in the feces. Assuming that ascarids were the problem, a three-day dose of piperazine tartrate tablets was dispensed. The condition of the dog did not change during the week following treatment. Since there was occasional vomiting and nausea, treatment was repeated, with identical results. Fecal material was examined and tapeworm segments of approximately  $3 \times 1$  mm in size were detected grossly.

#### Treatment

The dog underwent treatment with Yomesan<sup>1</sup> per os at the recommended dosage of 500 mg/3 kg body weight (4). The dog's appetite increased noticeably during the following days and no worm segments were observed for three days. They recurred, however, on the fourth day and the treatment was repeated. Again, segment expulsion ceased for three days. Recurring segments were microscopically identified as *Mesocestoides* spp. After approximately

one week without medication the dog then received one dose every third morning thereafter using the recommended dosage for Yomesan for a total of four treatments. Pablum mixed with milk was given in small quantities simultaneously to avoid vomiting. No segments have been noted to date (six months).

#### Discussion

Although adult *Mesocestoides* spp. are found in North American wild carnivores (10), there are few reports of members of this genus causing natural infections in dogs. Coatney (3) found *M. lineatus* in a dog in Nebraska and Honess (7) examined slides of *M. lineatus* from two dogs from Colorado. The taxonomy of the various species which have been assigned to the genus *Mesocestoides* is still confusing and variations due to abnormal host relations may account for discrepancies in morphological features of examined specimens and published reports (14). In the case presented here, no attempt was made to identify the species involved.

The life cycle of *Mesocestoides* spp. is incompletely known. For the completion of the cycle, two intermediate hosts are required. The first larval stage (oncosphere) probably develops in an arthropod (oribatid mites have been incriminated (13)). The second stage (tetrathyridium) is found in various vertebrates such as mature forms of amphibians, reptiles, birds (including chickens, guinea fowl or partridges) and small mammals (1, 5, 9). These tetrathyridia may survive for months (11). They are ingested by the final host and complete their development in the intestine. The intestinal wall can be penetrated and the larvae enter the peritoneal cavity and organs. Tetrathyridia may multiply asexually by splitting scolices in intermediate or paratenic hosts as well as in the definitive host (12).

Infection with *Mesocestoides* can result in peritonitis and ascites (5). However, intestinal infections have usually been considered harmless. While human infection (2, 6, 8) often involves persistent diarrhea, this was not evident in the present case reported. The source of this infection remains undetermined.

\*Greenbank Veterinary Clinic, Greenbank Road, Box 3043, R.R. 3, Ottawa, Ontario K2C 3H2 (Speckmann) and Animal Pathology Division, Health of Animals Branch, Agriculture Canada, Animal Diseases Research Institute, Box 11300, Postal Station H, Ottawa, Ontario K2H 8P9 (Webster).

<sup>1</sup>500 mg Niclosamide (2', 5 Dichloro-4'-nitrosalicylanilide), Chemagro Limited, Mississauga, Ontario.

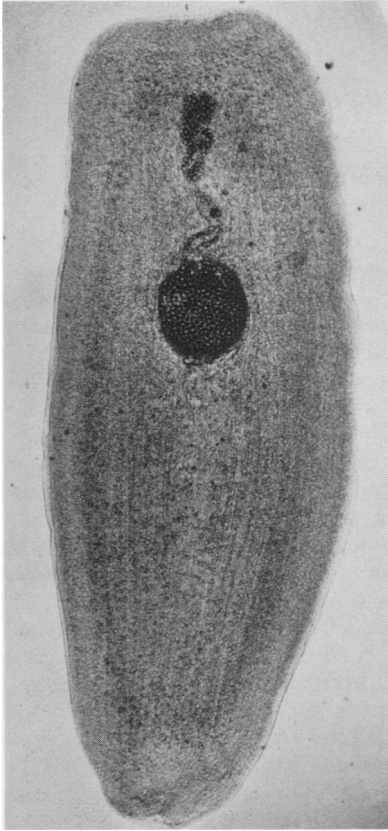


FIGURE 1. Wet mount of segment of *Mesocestoides* sp. cleared in phenol alcohol.  $\times 100$ .

Gravid segments of *Taenia*, *Dipylidium*, *Mesocestoides* and *Diphyllobothrium* species can be differentiated from each other by the following: *Taenia* segments have a single, lateral, usually obvious genital pore, a single set of reproductive organs, and eggs contained in a median longitudinal uterus with lateral branches; *Dipylidium* segments (cucumber-seed shaped) have double, lateral, usually obvious genital pores, a double set of reproductive organs, and eggs in capsules (up to 20 eggs per capsule); *Mesocestoides* segments have a single median, inconspicuous genital pore, and with eggs in a large, conspicuous parauterine organ (Figure 1). Gravid segments of *Diphyllobothrium* are usually not found in feces but when they do occur, can be distinguished from *Mesocestoides* by the appearance of the eggs in a sinuous uterus rather than the rounded, compact uterine capsule.

Two treatments with Yomesan given four days apart at the dosage recommended by the manufacturer were not completely effective. A total of four doses, applied over a period of ten days provided effective results.

### Summary

A natural infection of an eight-week-old poodle with the genus *Mesocestoides* was successfully treated with Yomesan.

### Résumé

Le Yomesan s'est avéré efficace pour traiter une chienne caniche âgée de huit semaines, parasitée par un cestode du genre *Mesocestoides*.

### References

1. BUTLER, J. M. and A. W. GRUNDMANN. The intestinal helminths of the coyote, *Canis latrans* Say, in Utah. *J. Parasit.* 40: 440-443. 1954.
2. CHANDLER, A. C. First record of a case of human infection with tapeworms of the genus *Mesocestoides*. *Am. J. trop. Med. Hyg.* 22: 493. 1942.
3. COATNEY, G. R. Some notes on cestodes from Nebraska. *J. Parasit.* 22: 409. 1936.
4. COX, D. D. and M. T. MULLEE. Anthelmintic activity of Yomesan against *Taenia* spp. in dogs. *J. Parasit.* 51 (Supplement): 30. 1965.
5. ECKERT, J., T. VON BRAND and M. VOGEL. Asexual multiplication of *Mesocestoides corti* (Cestoda) in the intestine of dogs and skunks. *J. Parasit.* 55: 241-249. 1969.
6. GLEASON, N. N. and G. R. HEALEY. Report of a case of *Mesocestoides* (Cestoda) in a child in Missouri. *J. Parasit.* 53: 83-84. 1967.
7. HONESS, R. F. A note on *Mesocestoides lineatus* (Goeze, 1782) from dogs in Colorado. *Proc. helminth Soc. Wash.* 29: 147. 1962.
8. ITO, J., J. HONDA and M. ISHIGURO. The second record of a case of human infection with *M. lineatus* in Japan (Cestoda). *Jap. J. Parasit.* 11: 71-75. 1962.
9. JAMES, H. A. and M. J. ULMER. New amphibian host records for *Mesocestoides* sp. (Cestoda: Cyclophyllidae). *J. Parasit.* 53: 59. 1967.
10. LEIBY, P. D. and W. G. DYER. Cyclophyllidean tapeworms of wild carnivora. In *Parasitic Diseases of Wild Mammals*. J. W. Davis and R. C. Anderson, Eds. pp. 174-234. Ames: Iowa State U. Press. 1971.
11. MUELLER, J. F. Survival and longevity of *Mesocestoides* tetrathyridia under adverse condition. *J. Parasit.* 58: 228. 1972.
12. NOVAK, M. Quantitative studies on the growth and multiplication of tetrathyridia of *Mesocestoides corti* Hoeppli, 1925 (Cestoda: Cyclophyllidae) in rodents. *Can. J. Zool.* 50: 1189-1196. 1972.
13. SOLDATOVA, A. P. [A contribution to the study of the development cycle in the cestode *M. lineatus* (Goeze, 1782), parasitic of carnivorous mammals.] *C. R. (Doklady) Acad. Sci. U.R.S.S.* 45: 310-312. 1944.
14. VOGEL, M. North American cestodes of the genus *Mesocestoides*. *U. Calif. Publ. Zool.* 59: 125-156. 1955.