

CASE REPORT

JUVENILE FAMILIAL ENDOCRINOPATHY

M. I. DRURY, DEBORAH M. KEELAN,
F. J. TIMONEY AND W. J. IRVINE

*Mater Misericordiae Hospital, Dublin; Endocrine Department,
Royal Infirmary, and M.R.C. Clinical Endocrinology Unit, Edinburgh*

(Received 7 January 1970)

SUMMARY

A case of primary hypothyroidism, idiopathic Addison's disease, idiopathic hypoparathyroidism (with preceding moniliasis), Addisonian pernicious anaemia and primary ovarian failure is described. She died at the age of 24 years following an illness compatible with adrenal crisis. At post-mortem there was no recognizable adrenal or ovarian tissue; there was only a minute portion of probable parathyroid tissue and the uterus was infantile. Her serum contained antibodies reactive with adrenal cortex, steroid-producing cells in the gonads, placental trophoblasts and thyroid epithelial cytoplasm and intrinsic factor.

Her brother, who was known to have gluten enteropathy, died aged 11 years following an illness compatible with adrenal crisis. His adrenal glands were grossly atrophic at autopsy.

The parents were consanguinous and both showed either clinical or serological evidence of organ specific autoimmune disease.

INTRODUCTION

The following two cases and family study are described in view of the rarity of adrenal insufficiency in siblings and to record the details of a case of primary ovarian failure associated with ovarian autoimmunity with streak ovaries and with polyendocrinopathy.

Case 1

History

M.L., female, born 12 January 1945. Her birth weight was 8½ lb. (3·7 kg), the outcome of a normal pregnancy and delivery. Her growth and development progressed normally to the age of 5 years, when she first developed patchy alopecia with depilation of the eyebrows and eyelashes. At 7 years, she spent 10 months in a fever hospital with suspected tuberculous meningitis, which was never proven. On discharge from hospital, she was underweight and the alopecia had become complete. Except for one year, at about the age of 9 years, when there was some regrowth of hair, the alopecia remained unchanged. Finger-nail dystrophy was first noted during her stay in the fever hospital and persisted thereafter.

Correspondence: Dr M. I. Drury, Mater Misericordiae Hospital, Dublin, Ireland.

In 1960, at the age of 15 years, she was referred to the Endocrine Clinic of the Mater Misericordiae Hospital, Dublin, by Dr J. Barnes of the Dermatology Department. She was of small stature [49½ in. (124 cm) in height; 61 lb. (27 kg) in weight]. Her skin was dry and cold. She had a red, raw tongue, showing patches of moniliasis. There was marked moniliasis of the finger nails and alopecia totalis.

There was no history of tetany or steatorrhoea. The menarche had not occurred. The external genitalia were infantile and there was no breast development. The systolic blood pressure (BP) was 92 mmHg.

The haemoglobin was 62% (9 g/100ml), the total white cell count and differential count and urinalysis were normal. There was no excess of fat in the stools. Her bone age was only 8 years in contrast to her chronological age of 15 years, but there was no evidence of osteoporosis. The serum cholesterol was 288 mg/100 ml and an ECG showed low voltage and prolongation of the QT interval consistent with hypothyroidism. She was considered to have primary hypothyroidism and treatment was begun with dried thyroid extract 2 g (130 mg) per day. This was later replaced by 1-thyroxine 0.2 mg day.

TABLE 1. Summary of the main clinical features of patient M.L.

Normal delivery and birth weight	
Alopecia at:	7 years
Moniliasis at:	7 years
Primary hypothyroidism at:	15 years
Primary adrenocortical failure (probably idiopathic) at:	15 years
Primary hypoparathyroidism at:	16 years
Addisonian pernicious anaemia at:	22 years
Complete failure of menstruation with no menarche and no secondary sex characteristics at:	23 years

In September 1960, the 24 hour urinary 17-ketosteroid and 17-ketogenic steroid excretion was 1.5 mg and 0.8 mg, respectively. At about this time she had an episode of collapse with BP = 60/45 mmHg, blood sugar = 44mg/100ml and serum sodium = 120 mEq/l. She responded to intravenous dextrose and the blood pressure rose to 100/65 mmHg. A diagnosis of primary idiopathic adrenal insufficiency was made and her general health was much improved by the addition of steroid replacement therapy.

In December 1961, she had her first episode of tetany (serum calcium = 5.4 mg/100 ml). The response to intravenous calcium gluconate was rapid. Steatorrhoea was again excluded by stool analysis, *d*-xylose test and jejunal biopsy. She was considered to have primary hypoparathyroidism. Calcium lactate and vitamin D were added to her therapy.

In October 1962 (at the age of 17 years) her bone age was 13 years, height 56 in. (142 cm) and weight 72 lb. (32 kg). Serum calcium = 10.7 mg/100 ml, phosphorus = 4.3 mg/100 ml, alkaline phosphatase = 11 KA units, haemoglobin = 84% (12.2 g/100 ml). The total 24-hr urinary gonadotrophins estimated by the mouse uterus test was between 26 and 52 mouse units. The subsequent progress was complicated by a rise in the serum calcium to 12.1 mg/100 ml and the development of a ureteric calculus which was passed spontaneously. The dosages of calcium and vitamin D were adjusted.

In September 1966 a macrocytic anaemia and histamine-fast achlorhydria were demonstrated. The serum vitamin B₁₂ was 100 pg/ml and the Schilling test was 0.05% rising to 23% when repeated with oral intrinsic factor.

TABLE 2. Serological results for patient M.L.

Tissue	*Staining pattern	Method	
		Immunofluorescence	Other
Ovary	Clumpy	neg	
Human corpus luteum	Confluent	neg	
	Patchy	+	
	Theca cells	++	
	Follicular phase		
	Granulosa cells/theca	++	
	Ova	±	
Rabbit ovary	Granulosa cells/theca	++	
	Hyperplastic interstitial cells	neg	
	Ova	neg	
Testis			
Human	Interstitial cells	+	
	Spermatids	neg	
Rabbit	Interstitial cells	++	
	Spermatids	neg	
Placenta			
Human	Trophoblasts	+	
Adrenal			
Human	Glomerulosa	neg	} CFT = 8
	Fasiculata	++	
	Reticularis	++	
Parathyroid			
Human adenoma		neg	
Thyroid			
Human	Cytoplasm	++	CFT = 16
	Thyroglobulin		TCH = 250
Stomach			
Body of human stomach	Parietal cells	neg	CFT = neg
Human gastric juice			Radioimmunoassay for intrinsic factor antibody I = 880 ng units/ml
Miscellaneous			
Rat liver	Mitochondria	neg	
Rat kidney	Nuclei	neg	

CFT = complement fixation test;

TCH = tanned cell haemagglutinin test for antibody to thyroglobulin

* As described in Irvine *et al.* (1969).

In 1968, at the age of 23 years [height 61 in. (154 cm), weight 81 lb (36 kg), bone age = 15 years] she had never menstruated and there was no palpable breast tissue. Gynaecological examination was refused. She was Barr positive on buccal smear and chromosome studies by lymphocyte culture gave normal results, 46XX (Dr Patricia Jacobs, M.R.C. Clinical and Population Cytogenic Unit, Edinburgh).

Her clinical history is summarised in Table 1. This patient is patient B in the paper by Irvine *et al.* (1968) and patient No. 3 of Table 4 and No. 2 of Table 5 in Irvine (1970a).

Serological findings. The results of her antibody studies on serum obtained in 1966 and subsequently are shown in Table 2. The details of the serological techniques employed were as previously described (Irvine, Stewart & Scarth, 1967; Irvine, Chan & Scarth, 1969) using undiluted serum and anti-human IgG-FITC conjugate in the immunofluorescence technique and 2 MHD of complement and 50% haemolysis as end-point in the complement fixation test.

Autopsy

While on holiday in the West of Ireland in August 1969 the patient complained of pyrexia, vomiting and diarrhoea with cramp-like abdominal pain. These symptoms worsened over the following 12 hr and she lapsed into unconsciousness and died in the ambulance on the way to the Mater Misericordiae Hospital.

Macroscopic findings. The body was completely devoid of hair and the finger-nails were thickened, longitudinally ridged and reduced to approximately one-third in area. Some pigmentation was noted at the margins of the tongue and on the gums. The thyroid weighed 4g and the thymus 7 g. The adrenals could not be detected macroscopically, the spleen was absent and rudimentary ovaries and uterus were identified. Other structures were grossly normal.

Histology

Pituitary gland: normal, with abundant cells in the anterior pituitary of normal appearance and variety, using H & E stains.

Thyroid: the glandular tissue was almost totally replaced by acellular fibrotic tissue. Numerous small foci of surviving thyroid glandular tissue were evident throughout the fibrotic mass. These foci were surrounded and infiltrated by an intense localized lymphocytic infiltrate similar to that seen in Hashimoto thyroiditis.

Parathyroids: only one small focus (2 mm) of probable parathyroid tissue was identified after a careful search.

Adrenal glands: no recognizable adrenal tissue was detectable in multiple sections from the fatty tissue of both adrenal areas. A focus of old haemorrhage in the form of haemosiderin deposit was found in the right adrenal area.

Ovaries: represented by thin plaques of fibrotic tissue in which follicles were not found.

Uterus: the cavity was lined by columnar epithelium resembling the normal endo-cervical type mucosa. No formed endometrium was detected.

Thymus: normal with reasonable cortico-medullary differentiation and no conspicuous germinal centre formation in the medulla.

Pancreas: normal with normal islet tissue.

Kidneys: normal apart from some small foci of calcification present in the epithelium of occasional tubules.

Case 2

History

S.L., male, born 1947, brother of Case 1. He was investigated at 7 years of age for coeliac disease and moniliasis of the finger-nails and mouth. His height then was 47 in. (118 cm) and weight 34 lb (15 kg). Streatorrhoea was confirmed and a gluten-free diet was started with symptomatic improvement.

At the age of 11 years, patchy alopecia of the scalp was noted. Later the same year, he was admitted to hospital with vomiting and diarrhoea of 2 days duration. He was underweight with monilial infection of the popliteal fossa of the right leg, of both hands including the nails, and

of the mouth. The tongue was bald and red. The serum calcium was 8.5 mg/100 ml and the phosphorus was 4.5 mg/100 ml. The faeces again contained a large excess of free fatty acid and occasional globules of neutral fat. His condition improved on a strict gluten-free diet and the serum calcium levels rose to 10.4 mg/100 ml and 10.8 mg/100 ml. Six months later he was re-admitted to hospital with a history of intermittent abdominal pain and vomiting of 10 days duration. There was no diarrhoea on this occasion. He collapsed suddenly and died within 1 hr of admission to hospital.

Autopsy

At post-mortem, moniliasis as described was noted. Both adrenal glands were extremely thin and atrophic. The thyroid and pituitary glands were macroscopically normal and the parathyroids could not be identified. There was marked enlargement of the mesenteric lymph nodes. Histology of these tissue was not available.

Family History

The parents of M.L. and S.L. were first cousins. They had two other children, one of whom was reputed to be in excellent health. The other died in childhood of gastro-enteritis during an epidemic in 1946.

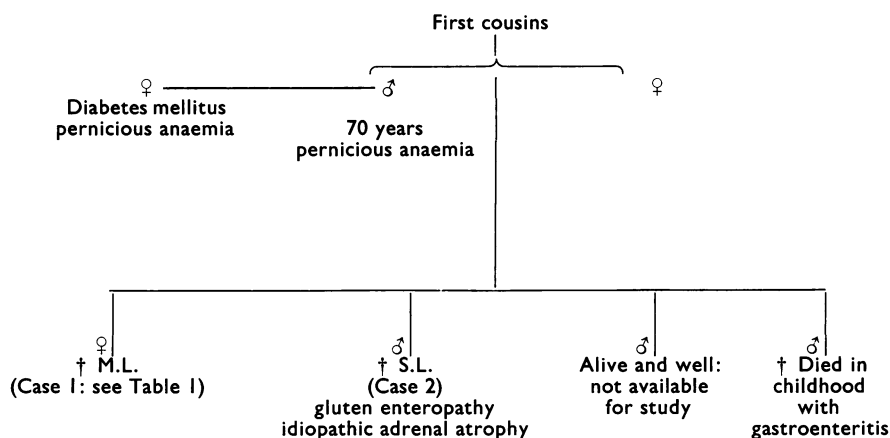


FIG. 1. Summary of family history.

The sera of both parents contained gastric parietal-cell antibodies by the indirect immunofluorescence test, and the serum of the mother (but not the father) was weakly positive for intrinsic factor antibody I (5.5 mg units/ml). Both sera were negative for thyroid cytoplasmic antibodies and for thyroglobulin antibodies and were also negative for antibodies reactive with adrenal cortex, ovary (graafian follicles and corpus luteum), testis, placenta, mitochondria and nuclei.

The surviving sibling had emigrated and was not available for clinical or serological assessment.

In March 1968 the father (aged 70 years) was found to have a macrocytic anaemia and achlorhydria and an abnormal Schilling test indicative of vitamin B₁₂ malabsorption. His general condition improved rapidly with parenteral vitamin B₁₂ therapy.

The father's sister attends the Mater Misericordiae Hospital with diabetes mellitus and Addisonian pernicious anaemia.

The available data concerning this family are summarized in Fig. 1.

DISCUSSION

In spite of the absence of more precise modern methods of investigation of adrenal function, there can be little doubt of the diagnosis of idiopathic adrenal insufficiency in the case of M.L. and of S.L. In M.L. primary adrenal atrophy and primary thyroid atrophy (with lymphocytic infiltration) were shown unequivocally at autopsy. Such severe atrophy would not be produced simply by replacement doses of oral steroids or of thyroxine. The fact that only remnants of parathyroid tissue could be found after a careful search at autopsy (both macroscopically and microscopically) confirmed the clinical diagnosis of idiopathic hypoparathyroidism. In her brother S.L. the severe atrophy of the adrenals noted at autopsy was in keeping with the clinical diagnosis of primary adrenal insufficiency.

The association of alopecia, moniliasis, primary hypothyroidism, primary hypoparathyroidism and Addisonian pernicious anaemia with idiopathic adrenal failure has been documented and reviewed (Carpenter *et al.*, 1964; Blizzard, Chee & Davis, 1967; Irvine *et al.*, 1967; Irvine, 1968, 1970a, b). The association of malabsorptive disease with idiopathic Addison's disease has been described by Craig, Schiff & Boone (1955), Whitaker *et al.* (1956), Morse, Cochrane & Landrisan (1961) and Goudie *et al.* (1969). The association of ovarian failure with idiopathic Addison's disease has been described clinically by Turkington & Lebovitz (1967) and both clinically and immunologically by Irvine *et al.* (1968, 1969) and by Irvine (1970a, b). A phenomenon that is shared by many of these conditions is the occurrence of autoantibodies in the sera that are specific for constituents of the organ that is the site of the disease (e.g. thyroid, parathyroid, gastric mucosa and adrenal cortex). The situation regarding the ovary is different in that there is a sharing of antigen between the steroid-producing cells of the ovary and the steroid-producing cells of the adrenal cortex (Irvine *et al.*, 1969). Patients that develop an immune response to steroid cell antigens that are present in the adrenals and also in the gonads are liable to have combined adrenal and ovarian failure, whereas patients that develop an immune response to steroid cell antigens that are only present in the adrenals do not develop ovarian failure in addition to adrenal atrophy. Extra-adrenal steroid cell antibodies are generally absent from the sera of patients with ovarian failure alone and without idiopathic Addison's disease (Irvine, 1970b). An attractive hypothesis is that the association of clinical disease described above (and exemplified particularly in Case M.L. of the present paper) is accounted for by a genetically determined disorder of immunological tolerance (Irvine, 1964; Irvine *et al.*, 1967).

Patient M.L. of the present paper with idiopathic Addison's disease and antibodies in the serum reactive with ovarian steroid-producing cells is now the second case in the literature in whom ovarian failure has been shown unequivocally to be associated with streak ovaries. Both patients were normal Barr positive on buccal smear and both had normal chromosome patterns on lymphocyte culture. The other case was described by Irvine *et al.* (1968) and by Kolb *et al.* (1970). While the possibility of mosaicism cannot be entirely excluded, it would seem likely that the destruction or failure of development of the ovary in these cases may be due to the development of autoimmunity (humoral and cellular) to ovary at an early age, i.e. before puberty. In patient M.L., and also in Dr Felix Kolb's patient, there was abundant clinical evidence that frank autoimmune disease had developed before puberty and it is, therefore, probable that the ovary may have been implicated at that time. These two cases, together with the finding that the sera of forty-nine patients with gonadal dysgenesis and chromosomal defects but without associated Addison's disease were all

negative for steroid cell antibodies (Price & Irvine, 1969), should suffice to question whether streak ovaries are always associated with chromosome abnormalities. In some instances streak ovaries may perhaps result from autoimmune mechanisms at an early age.

In patients with idiopathic Addison's disease and ovarian failure (with adrenal and extra-adrenal steroid cell antibodies) but in whom a menarche has occurred, the ovarian histology is characterized by lymphocytic infiltration in relation to the developing ovarian follicles (Irvine *et al.*, 1968; Bayliss & Irvine, 1970).

The combination of idiopathic Addison's disease with hypothyroidism (Schmidt's syndrome) is sometimes familial and is thought to be an autosomal recessive character (Carpenter *et al.*, 1964; Beaven *et al.*, 1959). Dunlop (1963) has stated that all cases of familial Addison's disease have so far proved to be idiopathic if autopsy was performed. Idiopathic Addison's disease has been described in two pairs of identical twins (Smith, Gough & Galpin, 1963; Heggarty, 1968). Familial aspects of Addison's disease have also been reported by Hung, Migeon & Parrot (1963) and by Meechen & Jones (1967). Spinner, Blizzard & Childs (1968) made an analysis of the history from 140 families containing patients with idiopathic Addison's disease without idiopathic hypoparathyroidism, Addison's disease with hypoparathyroidism and hypoparathyroidism alone. They demonstrated a significantly greater similarity of clinical and other attributes among affected persons within the families than among unrelated persons. Some cases were apparently genetically determined and the distribution of affected persons within the family was compatible with an autosomal recessive pattern. Other cases did not fit any Mendelian pattern even although their families contained more than one affected person.

The present family would be compatible with a genetic tendency to autoimmunity with both parents carrying the trait as evidenced by clinical pernicious anaemia in the father and his sister, and the presence of parietal cell antibodies in the serum of both the father and mother. The fact that both parents carried the trait may explain why the manifestations of autoimmunity were so pronounced and occurred so early in their children. The fact that the parents were consanguineous would also greatly strengthen the transmission of a recessive trait with incomplete penetrance.

ACKNOWLEDGMENTS

We should like to acknowledge the help of Professor Maurice Hickey who performed the post-mortem on patient M.L., and reported on the histological specimen.

REFERENCES

- BAYLISS, R.I.S. & IRVINE, W.J. (1970) (In preparation).
- BEAVEN, D.W., NELSON, D.H., RENOLD, A.E. & THORN, G.W. (1959) Diabetes mellitus and Addison's disease; a report on eight patients and a review of 55 cases in the literature. *New. Engl. J. Med.* **261**, 443.
- BLIZZARD, R.M., CHEE, D. & DAVIS, W. (1967) The incidence of adrenal and other antibodies in the sera of patients with idiopathic adrenal insufficiency (Addison's disease). *Clin. exp. Immunol.* **2**, 19.
- CARPENTER, C.J., BLOMON, N., SILVERBERG, S.G., BLEDSOE, T., NORTHCUTT, R.C., KLINENBERG, J.R., BENNET, I.L. & MCGEEHEE, H.A. (1964) Schmidt's syndrome (thyroid and adrenal insufficiency) a review of the literature and a report of 15 new cases including 10 instances of co-existent diabetes mellitus. *Medicine (Baltimore)*, **43**, 153.

- CRAIG, J.M., SCHIFF, L.H. & BOONE, J.E. (1955) Chronic moniliasis associated with Addison's disease. *Amer. J. Dis. Child.* **89**, 669.
- DUNLOP, D.M. (1963) Eighty-six cases of Addison's disease. *Brit. med. J.* **ii**, 887.
- GOUDIE, R.B., STUART-SMITH, D.A., BOYLE, I.T. & FERGUSON, A. (1969) Serological diagnosis of idiopathic Addison's disease in patients on prolonged prednisolone therapy for steatorrhoea. *Lancet*, **i**, 186.
- HEGGARTY, H. (1968) Addison's disease in identical twins. *Brit. med. J.* **i**, 559.
- HUNG, W., MIGEON, C.J. & PARROT, R.H. (1963) A possible autoimmune basis for Addison's disease in three siblings, one with idiopathic hypoparathyroidism, pernicious anaemia and superficial moniliasis. *New. Engl. J. Med.* **269**, 658.
- IRVINE, W.J. (1964) Thyroid auto-immunity as a disorder of immunological tolerance. *Quart. J. exp. Physiol.* **49**, 324.
- IRVINE, W.J., STEWART, A.G. & SCARTH, L. (1967) A clinical and immunological study of adrenocortical insufficiency (Addison's disease). *Clin. exp. Immunol.* **2**, 31.
- IRVINE, W.J., CHAN, M.M.W., SCARTH, L., KOLB., F.O., HARTOG, M., BAYLISS, R.I.S. & DRURY, M.I. (1968) Immunological aspects of premature ovarian failure associated with idiopathic Addison's Disease. *Lancet*, **ii**, 883.
- IRVINE, W.J. (1968) Clinical and immunological associations in adrenal disorders. *Proc. roy. soc. Med.* **61**, 374.
- IRVINE, W.J., CHAN, M.M.W. & SCARTH, L. (1969) The further characterization of autoantibodies reactive with extra-adrenal steroid-producing cells in patients with adrenal disorders. *Clin. exp. Immunol.* **4**, 489.
- IRVINE, W.J. (1970a) Adrenalitis, hypoparathyroidism and associated diseases. *Immunological Diseases*, 2nd edn. (Ed. by Santer), Chapter 70. Little, Brown, Boston.
- IRVINE, W.J. (1970b) Autoimmune ovarian failure. *Reproductive Endocrinology, Symposium of Section of Endocrinology, Royal Society of Medicine* (Ed. by W. J. Irvine), p. 106. Livingstone, Edinburgh.
- KOLB, F.O., IRVINE, W.J., STEINBACK, H.L., GOLDMAN, L. & WEBB, G. (1970) Primary hypoparathyroidism, Addison's disease and ovarian failure. *Reproductive Endocrinology, Symposium of Section of Endocrinology, Royal Society of Medicine* (Ed. by W. J. Irvine), p. 116. Livingstone, Edinburgh.
- MEECHAN, J. & JONES, E. WYN (1967) Addison's disease and Addisonian anaemia. *Lancet*, **i**, 535.
- MORSE, W.I., COCHRANE, W.A. & LANDRISAN, P.L. (1961) Familial hypoparathyroidism with pernicious anaemia, steatorrhoea and adrenocortical insufficiency. A variant of mucoviscidosis. *New. Engl. J. Med.* **264**, 1021.
- PRICE, W.H. & IRVINE, W.J. (1969) Autoimmunity in women with sex chromosome aneuploidy, and in their parents compared to controls. *Clin. exp. Immunol.*, **4**, 365.
- SMITH, M.E., GOUGH, J. & GALPIN, O.P. (1963) Addison's disease in identical twins. *Brit. med. J.* **ii**, 1316.
- SPINNER, M.W., BLIZZARD, R.M. & CHILDS, B. (1968) Clinical and genetic heterogeneity in idiopathic Addison's Disease and hypoparathyroidism. *J. clin. endocr. Metab.* **28**, 795.
- TURKINGTON, R.W. & LEBOVITZ, H.E. (1967) Extra-adrenal endocrine deficiencies in Addison's Disease. *Amer. J. Med.* **43**, 499.
- WHITAKER, J., LANDING, B.H., ESSELBORN, V.M. & WILLIAMS, R.R. (1956) The syndrome of familial juvenile hypoadrenocorticism, hypoparathyroidism and superficial moniliasis. *J. clin. Endocr.* **16**, 1374.