

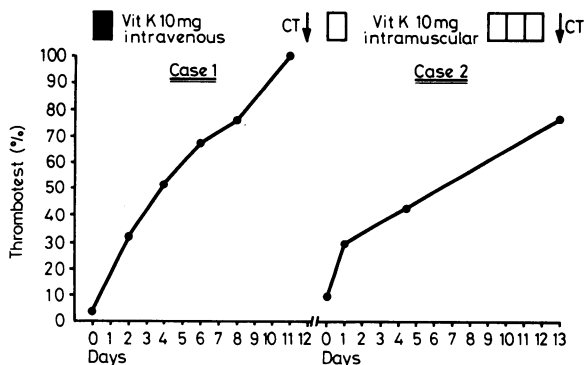
SHORT REPORTS

Cerebral thrombosis in two patients with malabsorption syndrome treated with vitamin K

Thrombosis may be a complication in inflammatory bowel disease.^{1,2} We report the occurrence of cerebral arterial thrombosis in two patients with malabsorption syndromes due to coeliac disease treated with vitamin K.

Case reports

(1) A 59-year-old woman had for 20 years suffered from episodes of abdominal pains and diarrhoea and had been constantly underweight. She was admitted to hospital in 1977 because of increasing diarrhoea, progressive weight loss, and fluid retention. She weighed only 40 kg and had generalised oedema and subcutaneous ecchymosis. Her erythrocyte sedimentation rate (ESR) was 6 mm in 1 h, haemoglobin concentration 12.6 g/dl, platelet count $370 \times 10^9/l$ ($370\,000/mm^3$), and thrombotest (TT) <5%. Serum concentrations were: calcium 1.05 mmol/l (4.2 mg/100 ml), iron 8 $\mu\text{mol/l}$ (44.6 $\mu\text{g}/100\text{ ml}$), total iron binding capacity 14 $\mu\text{mol/l}$ (74 $\mu\text{g}/100\text{ ml}$), albumin 25 g/l, cholesterol 3.13 mmol/l (120.8 mg/100 ml). Jejunal biopsy showed partial villous atrophy and infiltration of chronic inflammatory cells. She was treated immediately with fluids, electrolytes, albumin, vitamin K 10 mg intravenously, and a gluten-free diet. The subsequent TT values are shown in the figure. Twelve days later she developed left-sided hemiplegia. She died three months later. Necropsy showed slight atheroma, old ischaemic infarctions in the left hemisphere and pons, and a recent thrombus in the left hemisphere. Extensive histological examination of the small intestine confirmed the findings of earlier biopsies.



Thrombotest (TT) values before and after vitamin K substitution in two patients with malabsorption syndromes. Onset of cerebral thrombosis (CT) indicated by arrow.

(2) A 60-year-old man had since childhood suffered from episodes of watery, non-bloody diarrhoea and was constantly underweight. In 1971 he had severe osteoporosis and steatorrhoea. In 1979 he was operated on for an ileocaecal volvulus. No resection was needed. After that his diarrhoea increased. On admission to hospital four months later he weighed 41 kg and had generalised oedema. His ESR was 12 mm in 1 h, haemoglobin concentration 11.7 g/dl, platelet count $298 \times 10^9/l$ ($298\,000/mm^3$), TT 10%. Serum concentrations were: calcium 2.02 mmol/l (8.2 mg/100 ml), cholesterol 2.61 mmol/l (100.7 mg/100 ml), and albumin 23.7 g/l. His faecal fat was 32 g/24 h. Biopsy of the small intestine showed partial villous atrophy with chronic inflammation. The patient was given a gluten-free diet, corticosteroids, and vitamin K 10 mg intramuscularly. The subsequent TT values are shown in the figure. Twelve days after starting vitamin K treatment the patient developed right-sided hemiplegia. Cerebral computed tomography showed a large ischaemic infarction in the left hemisphere.

Comment

Both these patients had chronic intestinal inflammation and malabsorption. Both had partial villous atrophy but neither responded clinically to a gluten-free diet. That is not unusual in older patients with a life-long history of idiopathic steatorrhoea. Thrombotic events

have been described in chronic intestinal diseases,¹⁻³ but the only case we know of with coeliac disease and thrombosis was in a 49-year-old patient who developed disseminated intravascular coagulation three months after starting on a gluten-free diet.² Our patients had a major cerebral thrombosis during treatment for malabsorption. Both had a severe deficiency of the vitamin-K-dependent coagulation factors and responded to vitamin K treatment with a return of the prothrombin time to normal. Their thrombotic episodes were directly associated with the resolution of the vitamin K deficiency. Perhaps, like patients with other intestinal inflammatory diseases,^{4,5} they had an increased tendency to thrombosis and this was prevented so long as their blood coagulation was deficient as a consequence of malabsorption.

These two cases suggest that great care should be taken not to treat a long-standing vitamin K deficiency in coeliac disease too abruptly. This may also apply to patients with other chronic intestinal diseases associated with a secondary malabsorption syndrome. If bleeding does occur treatment with plasma infusions or small doses of vitamin K would be preferable, guided by observation of the prothrombin time. Otherwise the vitamin K deficiency should not be specifically treated since it will gradually diminish as treatment with a gluten-free diet or corticosteroids, or both, takes effect.

¹ Borda IT, Southern RF, Brown WF. Cerebral venous thrombosis in ulcerative colitis. *Gastroenterology* 1973;**64**:116-9.

² Ryan FP, Timperley WR, Preston FE, Holdsworth CD. Cerebral involvement with disseminated intravascular coagulation in intestinal disease. *J Clin Path* 1977;**30**:551-5.

³ Gvaef V, Baggenstoss AH, Sauer WG, Spittell JA. Venous thrombosis occurring in non-specific ulcerative colitis. A necropsy study. *Arch Intern Med* 1966;**117**:377-82.

⁴ Lam A, Borda II, Inwood MJ, Thomson S. Coagulation studies in ulcerative colitis and Crohn's disease. *Gastroenterology* 1975;**68**:245-51.

⁵ Lee JC, Spittell JA, Sauer WG, Owen CA, Thomson JH. Hypercoagulability associated with chronic ulcerative colitis: changes in blood coagulation factors. *Gastroenterology* 1968;**54**:76-9.

(Accepted 9 May 1980)

Department of Medicine, Regjonsykehuset, University of Tromsø, 9012 Tromsø, Norway

JON FLORHOLMEN, MD, resident in medicine
HELGE WALDUM, MD, lecturer in medicine
ARNE NORDØY, MD, professor in medicine

Dangers of storing glass syringes in surgical spirit

Dangers associated with using surgical spirit instead of industrial methylated spirit for storing insulin syringes may not be well known. We report details of a patient in whom severe complications developed.

Case report

A 28-year-old woman was referred to the microbiology laboratory because of bilateral abscesses of the thigh. She had had moderately severe diabetes for 14 years and currently was using Actrapid MC 14 units and Monotard MC 32 units daily. For the past two years she had been storing her insulin syringe (Everett) in surgical spirit prescribed by the diabetic outpatient department and her general practitioner. Previously she had always used industrial methylated spirit. After using surgical spirit for about six months she noticed that she had developed several swellings of varying sizes in the deep tissues of her thighs at injection sites. The swellings were only slightly painful but some were becoming superficial and she had received medical advice that this was an uncommon but unfortunate complication of multiple injections. She was referred to the accident department at Wycombe Hospital in July 1979 with large bilateral painful swellings in both thighs, which appeared to be multiloculated abscesses. As these were thought to be infected they were incised and a sample of the pus was sent for culture; ampicillin and flucloxacillin were prescribed. Culture was sterile, however, and healing was slow with poor granulation and excessive scar tissue. Staphylococci were presumed to be the likely infecting organism, so the patient, her husband and their son were screened for nasal carriage: findings were negative. Our patient attended the laboratory at intervals over the next few months with further