

# Clinicopathological Conference

## Immunodeficiency and cryptosporidiosis

DEMONSTRATION AT THE ROYAL COLLEGE OF PHYSICIANS OF LONDON

At the quarterly clinicopathological conference held at the Royal College of Physicians on 26 July 1979 Dr C C Booth (1) took the chair. He opened the conference by saying that it would take an unusual reverse form in which a pathologist, Dr I Doniach, would be invited to comment on the pathological findings and reconstruct the clinical history and that the true clinical history would be revealed at the end.

DR BOOTH: When we were looking for a patient for Professor Doniach to discuss we remembered his interest in gastrointestinal pathology. Dr Slavin chose the case and will present the post-mortem findings.

### Pathological findings

DR G SLAVIN (2): For the moment I will discuss only two of the relevant biopsies—one performed in October 1975 and the second in May 1978, just before the death of this 12-year-old boy. The first specimen that we had at Northwick Park was from a jejunal biopsy. It had tall villi covered by columnar epithelium and contained numerous plasma cells in the lamina propria. Immunoperoxidase staining showed a relative lack of IgA-containing cells but many IgM-containing cells in the lamina propria. In the next jejunal biopsy specimen the mucosa showed crypt hyperplasia and partial villous atrophy with degeneration of the surface cells. Numerous small bodies about 2  $\mu\text{m}$  in diameter were also noted along the luminal edge of the epithelium on the villi and in the crypts. These stained poorly with haematoxylin and eosin but were more easily seen with a Giemsa stain (fig 1). They were identified as cryptosporidia by electron microscopy.

After death necropsy was performed within three hours. The body weighed 14 kg and the height was 132 cm. Externally the body was jaundiced and showed the stigmata associated with modern intravenous therapy. Internally, the liver was abnormal. It weighed 1720 g and was pale and fatty, which was confirmed microscopically as gross fatty change. It showed marked cholestasis though there was no

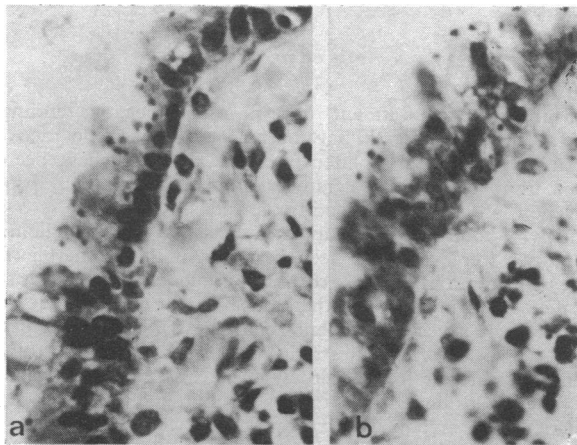


FIG 1—(a) Jejunal mucosa showing parasites present at the surface in association with degenerate epithelial cells. Haematoxylin and eosin. (b) Parasites are much more clearly defined by Giemsa staining.

mechanical cause for it. The biliary tree was normal and bile drained freely. The head of the pancreas appeared normal but the middle third of the body was swollen and haemorrhagic. Microscopically there was a large area of pancreatic necrosis which was associated with interstitial fibrosis and a degree of chronic pancreatitis. The large ducts in the head of the pancreas showed gross squamous metaplasia of the ductular epithelium.

The gastrointestinal tract was macroscopically normal, but while searching microscopically for the cryptosporidia seen in the biopsy specimens we found numerous parasites in the jejunum and ileum, but they were less prominent in the colon. They were also identified in the pharynx and the oesophagus related to squamous epithelium and to minor salivary glands. Throughout the intestine there was a hypoplasia of lymphoid tissue with absent Peyer patches and a lack of lymphoid follicles in the appendix. There was a minor infiltrate in the lamina propria of the small intestine of lymphocytes and plasma cells. Immunoperoxidase staining showed the plasma cells to contain mainly IgM; IgA-containing cells were sparse.

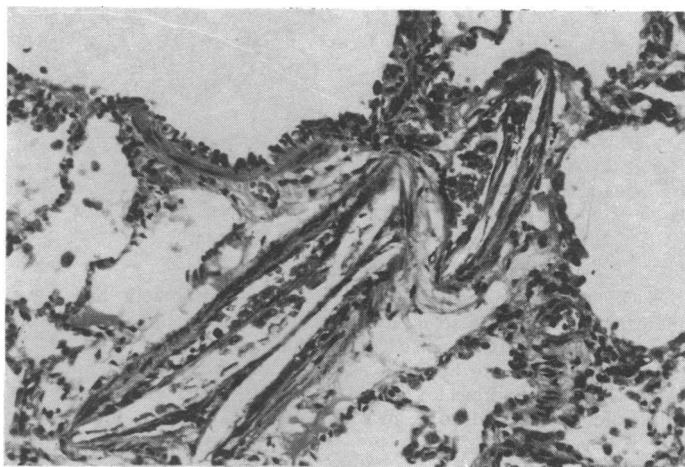


FIG 2—Calcification in wall of pulmonary artery beneath endothelium, with distortion of artery, which remains patent.

Lymph nodes were enlarged in the abdomen. They contained small cortical lymphoid aggregates but no true germinal centres. The sinusoids were full of histiocytes showing pronounced erythrophagocytosis. Plasma cells were prominent and immunoperoxidase stains showed many cells containing IgM but none containing IgG or IgA. The spleen weighed 90 g and was congested with a scanty white pulp. A prolonged search for the thymus, both macroscopically and in multiple sections, revealed no remnants. The bone marrow was hypoplastic with relatively few haemopoietic precursors. The bony trabeculae showed pronounced osteoporosis.

In the respiratory system there was pronounced pulmonary oedema and focal bronchopneumonia. There was some replication of the epithelium in the terminal bronchioles, suggesting a viral cause for the pneumonia. In the pulmonary arteries there was a curious calcification which looked like bamboo rods. Figure 2 shows a medium-sized pulmonary artery with lumen and intima distorted by a mass of calcium, over which the endothelium could be seen. The appearances

were quite distinct from the idiopathic arterial calcification that has been described in children. Some minor dystrophic calcification was also seen in the alveolar walls. A search for the parasite showed that the tracheal mucosa and glands were affected, but it had not penetrated deeper into the lungs.

The cardiovascular system showed no abnormalities and there was no evidence of congestive cardiac failure. The central nervous system was normal except for a small haemangioma in the left hemisphere. The endocrine system was normal, including the "stressed" adrenals associated with prolonged illness.

To summarise, therefore, this little boy had evidence of: immune deficiency, cryptosporidiosis, pancreatic fibrosis and necrosis, gross fatty change in the liver, bronchopneumonia and pulmonary oedema, a curious calcification of the pulmonary arterioles, marrow hypoplasia, and osteoporosis. I now ask Dr Dourmashkin whether he can identify the intestinal parasite for us.

DR R R DOURMASHKIN (3): This parasite has to be identified electron microscopically and the electron micrograph showed the parasite on the surface of the intestinal mucosa, which was itself flattened and damaged. Figure 3 shows a high-power electron micrograph of the trophoblastic form of the organism. The trophoblast

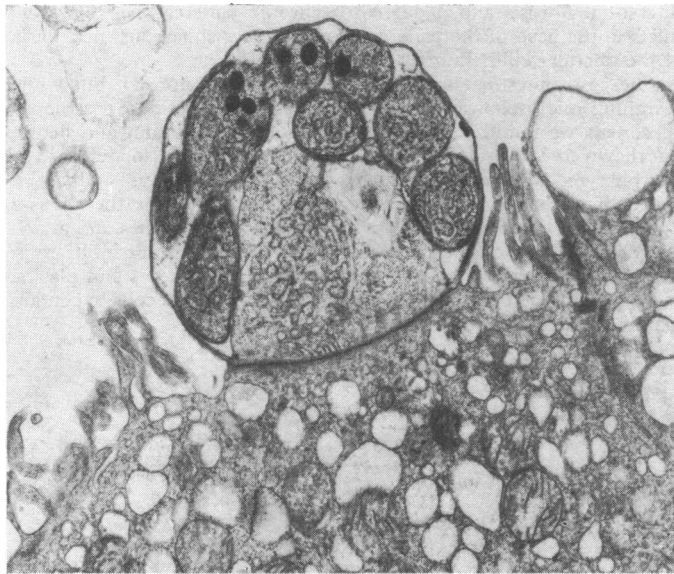

FIG 3—High-power electron micrograph of trophoblastic form of parasite.

surface was fused with the cell surface. The schizont had eight merozoites inside, the structural details of which helped to identify the organism. There was also a macrogametocyte form.

DR BOOTH: It is hardly fair to ask even clinicians to invent a history to go with these findings let alone a pathologist, but I am now going to ask Professor Doniach to do just that.

## Diagnosis

PROFESSOR I DONIACH (4): Excluding the terminal lesions, the main pathological conditions in this case were immunodeficiency, malabsorption, retarded growth, and the parasitic infestation. There was little IgA in the gut, lots of IgM, and little IgG in the gut and none in the nodes. I would have expected him to have been about 147 cm tall at the age of 12 but he was in fact 132 cm, which is the average height of a boy of 9. This gives a picture of a wasted, stunted little boy, probably with a history of chronic diarrhoea. How long had he been ill?

There are two possibilities. Either he failed to grow well from birth, or he did well enough until hit by an illness, when he stopped growing. I think that in view of his present size and his age at the time of his first jejunal biopsy he was hit by an illness when he was 7 or 8 and more or less stopped growing from then on. Although he had hypogammaglobulinaemia he did have plentiful IgM and I think he could have coped with infections until that age. I am assuming that he had a general practitioner who took a thorough history and made a thorough clinical examination and decided to send him to a paediatrician with

an interest in gastroenterology or a gastroenterologist interested in paediatric problems.

I think the general practitioner would have found a series of signs and symptoms which would have included diarrhoea, steatorrhoea, abdominal distension, vomiting, wasting, weakness, anorexia, abdominal pain, and oedema, and I think he probably had an enlarged fatty liver, which is the type of liver you might see in protein deficiency due to protein-losing enteropathy. There are, incidentally, practically no case reports of humans with cryptosporidia, so I have not been able to work out the symptoms due to the infestation. I suspect it would have caused abdominal pain.

The physician would have had to decide about the possible diagnosis, including coeliac disease, cystic fibrosis, chronic enteritis, Crohn's disease, and possibly hypogammaglobulinaemia. The age of 8 is perhaps a little late for childhood coeliac disease, and cystic fibrosis would probably have presented earlier. By chronic enteritis I mean either enteritis persisting after an acute attack or the sort of enteritis that might have been caused by *Giardia lamblia*. Crohn's disease would be a possibility as it does occur in children.

## INVESTIGATIONS

As for investigations, one would look for fat in the stools. At 8 he might have had watery diarrhoea but this would have been followed by steatorrhoea. Absorption tests such as a xylose test might have been done. The blood picture would have shown definite iron deficiency, probably also folate deficiency, but the serum B<sub>12</sub> concentration would not necessarily have been reduced because vitamin B<sub>12</sub> would have been stored in the liver and still have been present at the beginning of his illness. But the Schilling test would have shown malabsorption of vitamin B<sub>12</sub> with parasitic infestation—that spread right through the length of the gut. I would expect the blood protein to have been measured. The serum electrolytes might have shown a reduced potassium concentration if the diarrhoea was severe and also a reduced calcium concentration. The necropsy showed no chronic lung disease such as bronchiectasis so I think the chest radiograph would have been normal. Barium studies would have ruled out Crohn's disease but might have shown some coarsening of the mucosal folds. Bone radiographs would have shown osteoporosis, and rickets would have been ruled out. His assessed bone age would then have been that of a child of 8. A special x-ray examination of the pharynx might have been done to see whether there was reduction in adenoid tissue. He might have had duodenal intubation from the point of view of pancreatic function to measure the secretion of trypsin after a stimulant, and a parasite would have been looked for. Lastly, and perhaps most important, the jejunal biopsy would have been done, which in this case did not show the flat appearance of coeliac disease but crypt hyperplasia, suggesting organic disease of some sort.

The physicians were dealing with a difficult case. There would have been plenty to investigate concerning the hypogammaglobulinaemia. I imagine that his lymphocytes were examined for proportions of B and T cells, the immunoglobulins they were carrying, and whether they responded to stimulation. And his relatives' lymphocytes may have been looked at to see what genetic factors were taking part. The physicians might also have been interested in what stops growth when children are ill and have measured the basal growth hormone and its response to stimulants.

## TREATMENT

Turning now to treatment, in spite of the negative findings for giardiasis the patient would have been given, for example, metronidazole and probably also a gluten-free diet. He would have been prescribed iron, folate B<sub>12</sub>, calcium, vitamin D, antibiotics, probably intravenous albumin, and blood transfusions.

Finally, I found in the kidney sections that the juxtaglomerular apparatuses were very well seen in many of the glomeruli (fig 4). These make renin in response to a drop in blood volume. This stimulates the zona glomerulosa of the adrenal cortex to make aldosterone, and there was a very prominent zona glomerulosa in this patient's adrenals (fig 5). It was quite striking in both adrenals, so I think this patient was suffering from severe hypovolaemia. The physicians must have fought a losing battle trying to keep him going in the face of his infestation. The hypoplastic marrow may have resulted from blood transfusions, and the strange calcification in the lungs might have been related to intravenous feeding, particularly with lipids. But the battle was being lost and he developed bronchopneumonia with a fever,

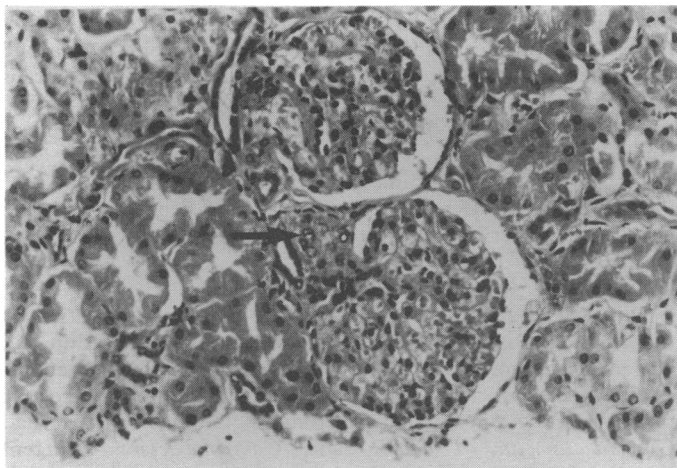


FIG 4—Section of kidney showing prominent juxtaglomerular apparatus (arrowed). Haematoxylin and eosin  $\times 300$  (original magnification).

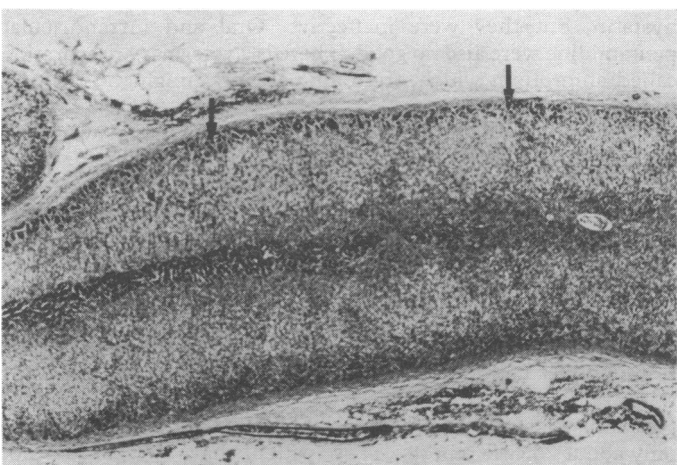


FIG 5—Section of adrenal showing prominence of zona glomerulosa (arrowed). Haematoxylin and eosin  $\times 30$  (original magnification).

moist sounds in the chest, a cough, and breathlessness, and he became jaundiced and semi-conscious. Then the "last rites" were performed—intravenous fluids, antibiotics, corticosteroids, repeated blood urea and electrolyte estimations and blood culture examinations.

DR BOOTH: I will now ask Dr David Webster to tell you the truth of so many things that you've said.

### Clinical course

DR DAVID WEBSTER (5): This boy started off normal and healthy. He was born in Bermuda, which might be relevant. At 6 months he was badly scalded and developed a septicaemia, which may have been the first clue that something was wrong. He then came to England at 2 years and continued to have minor skin infections such as boils and infected cuts. At 2½ years an astute physician found that he had hypogammaglobulinaemia. From then on he was given weekly injections of human gammaglobulin. He came to us when he was 5 with a swollen knee.

He was a normal-looking child of average height and weight. He had large tonsils and we did not take radiographs of the adenoids. Large tonsils often go with high IgM concentrations; before gammaglobulin treatment he had an IgG level of under 1 g/l, the IgA was unrecordable, and the IgM was 1.2 g/l. His spleen was just palpable. The effusion in his right knee had been present for about a year and was relatively painless. Synovial biopsy showed chronic inflammation but there were no plasma cells in the inflammatory infiltrate. A radiograph of the knee showed that he had hypertrophy of the medial femoral condyle but no other abnormality.

He had a normal lymphocyte count but there was neutropenia ( $0.95 \times 10^9/l$ ). He also had eosinophilia ( $0.9 \times 10^9/l$ ), which we made nothing of at the time since we had not seen this in other patients with

hypogammaglobulinaemia. Bone-marrow aspirate was normal. He admitted to some episodic diarrhoea but a faecal fat estimation was normal. He also had a normal serum albumin value, which virtually excluded a protein-losing enteropathy.

As regards his cellular immunity he had normal delayed hypersensitivity skin reactions to purified protein derivative (PPD) and *Candida albicans*; normal lymphocyte transformation to mitogens such as phytohaemagglutinin, and a normal percentage of T cells (E rosettes) in his peripheral blood. We sent him home confident that his knee would get better, as usually happens in this type of monoarthritis in children with primary hypogammaglobulinaemia.

The arthritis did improve over the next two years; but his general health deteriorated and his weight gradually fell from the 50th to the 3rd percentile by the age of 7 years. He developed the typical "pot belly" and wasting of coeliac disease, and these features persisted until he died at 12½ years. This was all due to chronic steatorrhoea, and the faecal fat at 8 years was 30 g/day. A jejunal biopsy in another hospital showed partial villous atrophy and possible giardiasis. In view of the known association of giardiasis with hypogammaglobulinaemia he was given metronidazole but without effect. The jejunal biopsy which Dr Slavin showed you (taken later at Northwick Park) was normal, which surprised us because we thought he had coeliac disease. We then thought about some of the other diagnoses already mentioned by Professor Doniach. We considered pancreatic disease but a sweat test was normal, and the jejunal juice contained normal levels of trypsin, lipase, and amylase during a Lundh test. We looked hard for increased numbers or unusual bacteria in the jejunal juice but found nothing significant. The  $^{14}C$  deoxycholate breath test was also normal. One might expect patients with hypogammaglobulinaemia to have problems with their bowel flora but, in fact, this is very unusual in our experience. The serum gastrin was normal.

At this stage we were rather at a loss about how to treat him but gave him various drugs including mepacrine, colistin, oxytetracycline, and piperazine at various times. We tried him for about a month on prednisolone (20 mg/day) but he continued to deteriorate. We tentatively diagnosed an allergic gastroenteropathy and concentrated on this right up to a few days before his death. We tried him on a milk-free diet, which he did not like as he was fond of milk. We did a milk challenge test with jejunal biopsies before and after, which were absolutely normal. We tried a gluten-free diet but that did not help.

After that his progress was unsatisfactory. He attended school some of the time but was always lethargic. At 10½ years he was admitted to another hospital with an acute pneumonia and was then transferred to Northwick Park.

On the day of arrival he developed torrential cholera-like diarrhoea with severe electrolyte and water loss requiring intravenous therapy in the intensive care unit. He was given antibiotics, including cotrimoxazole, and improved. He had very little diarrhoea for the subsequent three weeks although the diarrhoea then relapsed. The splenomegaly had disappeared but he had an enlarged liver and clubbing of the fingers and toes. The neutropenia, which he had had for five years, disappeared and he had normal or raised neutrophil counts until his death. The serum IgM had risen to 6.5 g/l. He remained in chronic ill health until his final admission at the age of 12½ years.

The final admission came about because of recurrent vomiting and epigastric pain. We tried to "rest" his bowel by giving him low-strength Vivonex, which he could not tolerate. We proceeded to intravenous alimentation for about three weeks through a subclavian vein. He again developed cholera-like diarrhoea which seemed to respond to high doses of steroids. Four weeks after admission he became mildly jaundiced and then quite suddenly and unexpectedly died.

I suspect that the bronchopneumonia found at necropsy had been masked by steroids. The diagnosis of coccidiosis came only a couple of days before death with the last jejunal biopsy, which was the fifth biopsy he had had over the previous six years.

In conclusion, this boy had primary hypogammaglobulinaemia with raised IgM. The neutropenia, which has been described in other patients with this type of hypogammaglobulinaemia, mysteriously disappeared when he developed coccidiosis.

### Discussion

DR BOOTH: Thank you. Much of that was predicted by Professor Doniach. Here we have a patient with hypogammaglobulinaemia, and such patients are apt to develop parasitic infections. This must be an exceptionally rare parasitic infection,

so, firstly, we want to know something about it and, secondly, was this what killed him?

DR R G BIRD (6): From among the tens of thousands of protozoa there are in the world, we are fortunate that fewer than 30 species interest themselves in man. This one from among the cryptosporidia is apparently the latest to draw attention to itself through electron microscopy. No doubt it has been overlooked by pathologists because of its small size. This parasite prefers the cell surface, just within the host cell membrane, as its site for schizogony—a site that helps to differentiate it from the larger coccidia usually found deeper in the cytoplasm. Only seven human cases have been reported. Figure 6 shows the

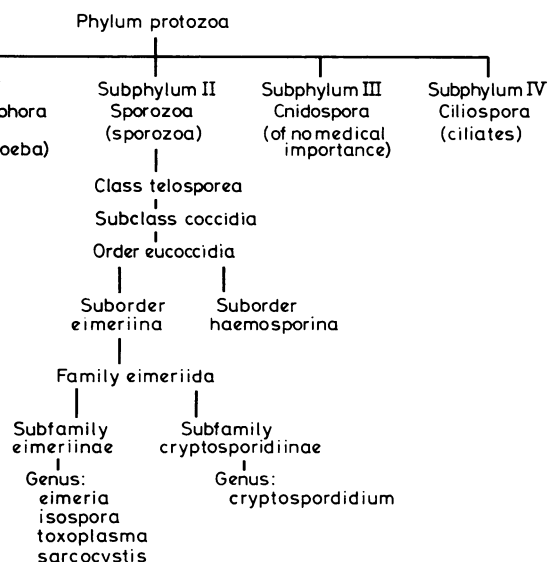


FIG 6—Position of cryptosporidia within phylum protozoa.

organism's position within the phylum protozoa. The *Eimeria* are irrelevant in that they just pass through the gut in cyst form whereas *Isospora toxoplasma* and *Sarcocystis* are parasitic in man. Figure 7 shows what is known and unknown of the cryptosporidial life cycle. I remind you that there is both an asexual and a sexual phase and that at some stage in the total cycle microgametes and macrogametes are formed instead of merozoites. These gametes fuse to form a zygote, which then develops through an oocyte into an oocyst. This latter part of the cycle

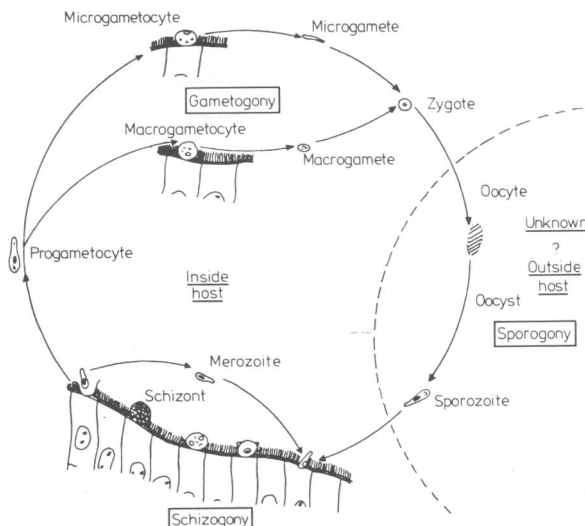


FIG 7—Life cycle of cryptosporidia.

probably takes place outside the original host and results in the formation of mature sporozoites capable of infecting another host. At the surface of the cell where the merozoite is attached there is a dark area of contact and in the underlying cell there is an electron dense area manifested by swollen, and occasionally vacuolated, mitochondria. This contact and reaction needs further investigation.

DR BOOTH: Do you think this is what killed the patient?

DR BIRD: No. If one looks at published reports there is a growing list of cryptosporidia affecting animals. It appears to be an opportunist infection.

DR BOOTH: How would you treat it?

DR ANTHONY BRYCESON (7): We have had a similar patient at the Tropical Diseases Hospital. He was, however, an adult and had an even more severe immune deficiency with no demonstrable T-cell function at all, defective neutrophil and defective monocyte function, but normal immunoglobulins. He also had *Giardia lamblia*, *Trichuris*, and *Campylobacter*, recurrent pneumonia and scabies, and a herpes-like virus in the gut. We managed to eliminate all these infections except the cryptosporidium and herpes virus. The cryptosporidium was treated with co-trimoxazole, soluble and insoluble sulphonamides, and nystatin, but they were ineffective. Oral and intramuscular pentamidine were also no good. There is a veterinary preparation called amprolium which, from animal work, might be effective in humans.

DR G L ASHERSON (8): An enormous amount of work has been done on the treatment of coccidia in chickens. Some of the toxicity of the drugs has been studied in mammals because the residua of these drugs are found in the chicken meat that we eat. As most of these agents are coccidiostatic, treatment needs to be prolonged. Different agents are thought to act at different points in the life cycle and should therefore be given simultaneously. Having tried the drugs which are currently in use for humans, we should look at the new drugs which are used for animals such as quinolines and ionophores and thiamine analogues.

I would like to comment on the question of hypogammaglobulinaemia with raised IgM and low IgG and IgA. There are only about 26 case reports. These patients have two features not usually seen in ordinary hypogammaglobulinaemia. They have a neutropenia that persists despite immunoglobulin therapy, and this may be important as some of the patients have died of pseudomonas septicaemia. Three patients have had *Pneumocystis carinii* pneumonia. This is traditionally associated with severe T-cell defects and is not a feature of uncomplicated hypogammaglobulinaemia. These patients may have had normal T-cell function. This suggests that patients with hypogammaglobulinaemia and raised IgM may be unduly susceptible to pneumocystis infection and by analogy perhaps to other parasitic infections.

SIR DOUGLAS BLACK (9): Does this infestation ever occur in people who are not naturally or artificially immune deficient and is it pathogenic?

DR WEBSTER: In Chile coccidiosis is an endemic disease—a self-limiting disorder that may affect anyone and cause a rather nasty diarrhoea for several weeks or sometimes months.

DR BOOTH: There are at least two cases of isospora infection in the literature which when treated the patient got better, so this suggests that it is pathogenic. I had a case in a man who had a partial gastrectomy whose gut was obviously compromised because of that.

DR BIRD: I think we should distinguish between isospora and cryptosporidium. Isospora also occur in the Mediterranean area and are certainly pathogenic. The question of the pathogenicity of cryptosporidium is still open, and the incidence of cryptosporidial infection in healthy subjects is unknown.

DR ASHERSON: On reviewing the sections did Dr Slavin see the organisms in the previous biopsies?

DR SLAVIN: In the most recent specimen, the fourth one, the disease was diagnosed. In the second and third there were no protozoa. In the first specimen seen at our hospital the protozoa were sparse but were definitely there on review. He had also

undergone biopsy in another hospital when he was 6. In that specimen there were both giardia and cryptosporidia, though only the giardiasis was recognised at the time.

PROFESSOR HAROLD LAMBERT (10): I would like to hear some comment about the pancreatitis.

DR BERNARD VALMAN (11): Studies in Uganda suggested that malnutrition could cause pancreatitis,<sup>1</sup> but other investigations in the same area by Dr Shafer showed that at least half the patients were taking excessive amounts of alcohol.<sup>2</sup> Subsequently reports from the State of Kerala in India<sup>3</sup> noted that epidemics of pancreatitis in patients aged 16 to 20 years were associated with malnutrition, but these epidemics were not found in other parts of India where malnutrition was common. These studies suggest that both malnutrition and an additional factor such as a toxin from food or infection are needed before pancreatitis occurs. In this patient it may have been malnutrition with the cryptosporidia. This boy also had recurrent severe lung infections, which may have provided an additional infective factor in the development of pancreatitis.

DR BOOTH: Well that concludes this reverse CPC, in which I think you will agree that Professor Doniach made a masterly reconstruction of the case from the pathological findings.

### Appointments of speakers

- (1) Dr C C Booth, MD, FRCP, director, Clinical Research Centre, Northwick Park Hospital, Harrow
- (2) Dr G Slavin, FRCPGLAS, FRCPATH, consultant pathologist, Northwick Park Hospital, Harrow
- (3) Dr R R Dourmashkin, MD, head, section of electron micro-

scopy, Clinical Research Centre, Northwick Park Hospital, Harrow

- (4) Professor I Doniach, MD, FRCP, honorary lecturer in histopathology, St Bartholomew's Hospital, London EC1A 7BE
- (5) Dr David Webster, MB, MRCP, consultant physician (immunology), Clinical Research Centre, Northwick Park, Harrow
- (6) Dr R G Bird, PHD, DTM&H, reader in cellular fine structure, Electronmicroscope Laboratory, London School of Hygiene and Tropical Medicine, London WC1
- (7) Dr Anthony Bryceson, MD, FRCPED, consultant physician, Hospital for Tropical Diseases, London
- (8) Dr G L Asherson, DM, FRCP, head of division of immunological medicine, Clinical Research Centre, Northwick Park Hospital, Harrow
- (9) Sir Douglas Black, MD, FRCP, President of the Royal College of Physicians, London
- (10) Professor Harold Lambert, MD, FRCP, professor of microbial diseases, St George's Medical School, London SW17
- (11) Dr Bernard Valman, MD, FRCP, consultant physician, Northwick Park Hospital and Clinical Research Centre, Harrow

### References

- <sup>1</sup> Banwell JG, Hutt MRS, Leonard PJ, *et al.* Exocrine pancreatic disease and the malabsorption syndrome in Tropical Africa. *Gut* 1967;8:388.
- <sup>2</sup> Shaper AG. Aetiology of chronic pancreatic-fibrosis with calcification seen in Uganda. *Br Med J* 1964;i:1607.
- <sup>3</sup> Pitchumoni CS. Pancreas in primary malnutrition disorders. *Am J Clin Nutr* 1973;26:374-9.

## MATERIA NON MEDICA

### Music

The influence of music never ceases to amaze me. I frequently come home to a pulsating cacophony of uncoordinated noise emitted loudly from the radio by a group of people with a totally illogical name. An immediate character change occurs. I roar at my son to switch the thing off. The fond father has instantly become a bad-tempered oaf. I apologise, as often as not, but the damage is done. He retreats to his room to practise his music. Unfortunately, this is a bass guitar—he plays with a local pop group, also with a weird name. The sound of "Thump, thump, thumpity, thump" fills the house and my irritation returns. It is not soothed by his mother, who reminds me that it could be worse. His best friend is a drummer.

A few nights ago my wife and I had a meal at a riverside restaurant. A piano played softly as we ate. All my old favourites from the musicals of my youth. It was a perfect complement to the food and wine and made the evening a real success. We talked of our college years; the dance at which we met; and of the friends of those halcyon days. Nostalgia from a few simple songs. What is the magic of different combinations of notes and rhythms that can vary one's mood from anger and aggression to peace and pleasure? I wish I knew.—WILLIAM THOMSON (chief administrative medical officer, Lanarkshire).

### Of buses and men

The untimely death of my frog during the 2nd MB physiology examination sent me on a long vacation which lasted until the resit, and thus I found myself an employee of the North Western Bus Company as a conductor. It was a sought-after job. If you worked double shifts you could earn much-needed money, and students from all walks of life were fighting for just such an opportunity. Rising at 4 am knowing that the day will not end till midnight is not the best of prospects, but being in uniform had its advantages. You were a brotherhood and could board any bus and immediately start a conversation with the guard, totally ignoring the passengers, who also ignored you. Speech was crammed with jargon: "Any cream?"

"Done the 49 Dupe?" "Lil OK?" This last referred to a fiery blonde clippie with a bust that did more for serum testosterone than ever did rapid eye movement sleep. She showed the students how to cope with the public rampant, but added on numerous occasions, "You might all be bright, but when it comes to common sense, cats have more." Students were given the most menial routes and often put on with inexperienced drivers—more than once we had to stop so that some kindly old lady could tell us the correct route, often reinforcing her directions by gesturing with an umbrella.

One afternoon our bus arrived, somewhat empty, to find that we were behind its doppelganger. An amicable exchange occurred between our two crews, made more strange by the fact that the conductor of the other vehicle was an Oxford philosophy student. "We both cannot be the 4.00 pm 41 Dupe," I stated.

"Why not?" he argued, "Impossible but not impossible." After more of this we consulted our timetables to find that I had looked at tomorrow's sheet. My driver, of some months' experience, said he knew how to get back on to the right road. We set off, and he turned on to a footpath and across a field. As we passed the backs of some houses, a man, shaving in his bathroom with the window open, gaped uncontrollably. Perhaps he thought we were a hallucination—a doubledecker bus on a footpath. To my surprise we did join our correct route for that day, albeit some miles along it. We kept a low profile lest someone waiting at the stages we had omitted complained, but no one did.

On one Sunday I arrived in Piccadilly, Manchester, to find my driver, a weatherbeaten A-sheet man (absolute slumming for him to have me that day), leaning laconically against the bus stop. A long angry queue of passengers were muttering ominously. "Where is the bus?" he inquired with genuine interest.

"Bus?" I stammered. Apparently the previous crew were supposed to have left it at the stop for us, the rule for Sunday, but as that crew had consisted of a student and a brand new driver, and nobody had thought to tell them, they had taken the bus back to the depot. It took us a fevered twenty minutes to find another bus.

In my dreams I still do those routes, Disley to Buxton in moonlight, over the moors to Barnsley. A guard with whom I trained, although no haematologist, was quite right when he said, "Buses, they kind of get into your blood."—RE GOODMAN (general practitioner, Northenden, Manchester).