

Cytogenetic Findings in a Prospective Series of Patients with DiGeorge Anomaly

Frank Greenberg, Fred F. B. Elder, Paula Haffner, Hope Northrup, and David H. Ledbetter

Institute for Molecular Genetics, Baylor College of Medicine, Houston

Summary

High-resolution cytogenetics analysis of peripheral blood lymphocytes was done prospectively on 27 of 28 patients with features of DiGeorge anomaly. Twenty-two patients (81%) had normal chromosome studies with no detectable deletion in chromosome 22. Five patients (18%) had demonstrable chromosome abnormalities. Three patients had monosomy 22q11, one due to a 4q;22q translocation, one due to a 20q;22q translocation, and one due to an interstitial deletion of 22q11. One patient had monosomy 10p13, and one patient had monosomy 18q21.33, although the latter had subsequent resolution of T-cell defects. These findings are consistent with the heterogeneity of DiGeorge anomaly but confirm the association with monosomy 22q11 in some cases. However, monosomy 10p13 may also lead to this phenotype. Because of these associated chromosome findings, cytogenetic analyses should be done on patients with suspected DiGeorge anomaly. This is particularly important since many of the abnormalities involving chromosome 22 are translocations that can be familial with a higher recurrence risk. Since only one subtle, interstitial deletion of chromosome 22 was observed, it is not clear whether high-resolution cytogenetic analysis is cost beneficial for all such patients.

Introduction

DiGeorge anomaly (DGA) is a development defect of the third and fourth branchial arches. Since its description by A. M. DiGeorge (1965), numerous retrospective studies have been done to delineate the defects associated with thymic and parathyroid hypoplasia. Variability has been noted in both the types and severity of the defects, so that both complete and partial forms of the sequence can be recognized (Conley et al. 1979). Although most patients have evidence of heart defects, some may present with only hypocalcemic seizures (Conley et al. 1979).

DGA is also known to be associated with several recognizable syndromes, such as Zellweger syndrome, teratogenic exposures (alcohol and retinoic acid), and chromosome abnormalities, primarily monosomy 22q11 (Lammer and Opitz 1986).

In 1981, de la Chapelle et al. reported familial DGA associated with an unbalanced 20;22 translocation producing monosomy for 22q11 (de la Chapelle et al. 1981). This association of DGA and monosomy 22q11 was confirmed by Kelley et al. (1982), who reported three of 14 patients with DGA and monosomy 22q11 due to unbalanced translocations involving chromosomes 3, 10, and 20. These cases were all identified as gross translocations after routine chromosome analysis and suggested the possibility that, analogous to the situation in Prader-Willi syndrome (Ledbetter et al. 1982), small interstitial deletions of 22q11 might be present in some patients, but some deletions would only be detectable by high-resolution chromosome techniques. Thus, we began a prospective study of patients with DGA, using routine and high-resolution chromosome analysis to investigate the frequency of both monosomy 22q11 and other chromosome abnormalities in this group.

Received March 28, 1988; revision received June 6, 1988.

Address for correspondence and reprints: Frank Greenberg, M.D., Institute for Molecular Genetics, Baylor College of Medicine, One Baylor Plaza, Houston, TX 77030.

© 1988 by The American Society of Human Genetics. All rights reserved. 0002-9297/88/4305-0006\$02.00

Material and Methods

Patients with suspected DGA who were seen between

1982 and 1987 were referred after prospective ascertainment by presentation with one or more of the following findings: (1) conotruncal cardiac malformations (truncus arteriosus, right sided aortic arch, interrupted aortic arch), (2) persistent hypocalcemia with or without seizures, (3) thymic aplasia noted at surgery or autopsy, and (4) family history of DGA.

Whenever possible, peripheral blood-lymphocyte chromosome analysis, determination of PTH levels, and T-cell function studies were done. High-resolution chromosome analysis on peripheral blood samples were done using methotrexate synchronization (Yunis 1976) and trypsin G-banding. Immunologic studies were performed using standard methods of indirect immunofluorescence and flow cytometry as well as functional evaluation measured by tritiated thymidine incorporation in several concentrations of phytohemagglutinin,

pokeweed mitogen, and concanavalin A. PTH levels were determined by the method of Mallette et al. (1982).

Results

A summary of patient data is given in table 1. There were an equal number of male and females among the 28 patients evaluated. The majority of patients (75%) were ascertained primarily because of a congenital heart defect which was subsequently determined to be a conotruncal defect. Three patients (11%) were ascertained because of neonatal hypocalcemia, with or without seizures but without cardiac defects. In addition, two patients were known to have had a positive family history of complete or partial DGA.

Seven patients had absence or severe hypoplasia of the thymus, noted at surgery or autopsy. These patients

Table 1

Summary of Clinical Information

Patient No., sex (Birth Date)	Ascertainment ^a	Family History of DEA	CHD ^b	Other Defects	DGA Types ^c	Status	Chromosomes
1, M (2/80)	MCA,CHD	Yes	TA, RAA, VSD	Cleft lip Clubfoot	P	Dead	46,XY
2, F (12/80)	CHD, HCA	No	PDA,VSD	Micrognathia Scoliosis Developmental delay	P	Alive	46,XX
3, M (2/81)	HCA, SZ	No	None	None noted	P	Alive	46,XY
4, M (4/81)	CHD, HCA	No	RAA, PST	None noted	P	Alive	46,XY
5, M (5/81)	CHD, HCA	No	VSD, PST	Microstomia Polythelia	P	Alive	46,XY
6, M (12/81)	CHD, HCA	Yes	TA	See text	P	Alive	45,XY,t(4;22) ^d
7, M (4/82)	HCA, SZ	No	None	Del 10p Phenotype	P	Alive	46,XX,del(10p) ^d
8, M (7/82)	CHD, HCA	No	AVC, PDA, RAA	Coloboma, cleft lip and palate Microcephaly (CHARGE assoc)	C	Dead	46,XY
9, F (7/82)	HCA, SZ	No	None	Dysmorphic facial features	P	Alive	46,XX
10, M (7/82)	MCA, CHD	No	DORV	Cleft lip and palate, coloboma, Holoprosencephaly	C	Dead	46,XX
11, F (12/82)	CHD, HCA	No	TA, IAA, VSD PFO, PDA	Low-set ears	C	Dead	46,XX
12, M (3/83)	CHD, HCA	No	PS, RAA, MVSD	Posteriorly rotated ears	C	Dead	46,XY
13, M (4/83)	CHD, HCA	No	IAA, SC-VSD BAV, PDA	Dysmorphic facial features	P	Dead	46,XX
14, F (8/83)	CHD, HCA	No	IAA	Dysmorphic facial features	P	Dead	46,XX

(continued)

were designated as having "complete" DGA. In the remainder, T-cell deficits or dysfunction were documented by immunologic testing. The latter were designated as having "partial" DGA. All patients had at least prolonged episodes of hypocalcemia requiring calcium supplementation for varying periods of time.

All patients with complete thymic aplasia died within several months of birth. At least six of 21 patients with partial defects died within the first year of life, usually from causes related to their cardiac defect.

Cytogenetics analysis, using peripheral blood lymphocytes, could be performed in all but one patient. In that patient, the diagnosis was made postmortem and there was no growth of skin fibroblasts. Twenty-two patients (79%) had normal chromosome studies, and high-resolution analysis showed no demonstrable

deletion of 22q11. This group included one familial case in which a patient had two previous sibs with DGA. Five patients (18%) had a demonstrable cytogenetic abnormality. Four of the five cases were detectable by routine chromosome studies, while patient 28 had a subtle interstitial deletion which was suspected by routine analysis but could only be confirmed with certainty by extensive high-resolution analysis.

Patient 6 (table 1) has been reported elsewhere (Greenberg et al. 1984). He had a positive family history (two affected sibs) and was subsequently shown to have an unbalanced 4q;22q translocation with monosomy 22q11 [45,XY,-4,-22,+der(4),t(4;22)(q35.2;q11)mat]. This derivative chromosome 4 was inherited from his mother, who also had monosomy 22q11 with only mild, subclinical expression of DGA. At 5 years of age, he

Table 1 (continued)

Patient No., sex (Birth Date)	Ascertainment ^a	Family History of DEA	CHD ^b	Other Defects	DGA Types ^c	Status	Chromosomes
15, M (9/83)	CHD, HCA	No	PVA, RAA MVSD	None noted	C	Dead	46,XX
16, F (9/83)	CHD, HCA	No	TOF	Cleft palate Posteriorly rotated ears	P	Alive	46,XX
17, M (10/83)	CHD, HCA	No	IAA, PDA, MVSD	None noted	C	Dead	ND
18, M (11/83)	CHD, HCA	No	TOF	del 18q phenotype	P	Alive	46,XY,del(18q) ^d
19, M (3/83)	CHD, HCA	No	TOF	Cleft palate	P	Dead	46,XY
20, F (8/84)	CHD, HCA	No	TA, RAA	Dysmorphic facial features	P	Alive	46,XX
21, M (9/84)	CHD, HCA	No	IAA, VSD	Low-set ears	P	Alive	46,XY
22, M (10/84)	CHD, HCA	No	TA, IAA, VSD	Asymmetric facies	P	Dead	46,XY
23, F (2/85)	CHD, HCA	No	TOF, PVA	Dysmorphic facial features	P	Alive	46,XX
24, M (2/86)	CHD, HCA	No	TA	Telecanthus	P	Dead	46,XY
25, F (11/85)	CHD, HCA	No	IAA, VSD	Cupped ears	P	Alive	46,XX
26, F (6/86)	HCA	No	VSD	Dysmorphic facial features	P	Alive	45,XX,t(20;22) ^d
27, M (4/87)	CHD, HCA	No	TAI, RAA, VSD	Hypertelorism, Low-set ears	C	Dead	del(22)(q11.21.23) ^d
28, M (5/87)	CHD, HCA, SZ	No	ASD, VSD	Posteriorly rotated ears	P	Alive	46,XY

^a CHD = congenital heart defect; MCA = multiple congenital anomalies; HCA = hypocalcemia; SZ = seizures; FH = family history of DGA.

^b AVC = AV canal; BAV = bicuspid aortic valve; DORV = double-outlet right ventricle; IAA = interrupted aortic arch; MVSD = membranous ventricular septal defect; PDA = patent ductus arteriosus; PFO = patent foramen ovale; PS = pulmonic-valve stenosis; PST = pseudotruncus; PVA = pulmonic-valve atresia; RAA = right-sided aortic arch; SC-VSD = supracistal ventricular septal defect; TA = truncus arteriosus; TOF = tetralogy of Fallot; VSD = ventricular septal defect.

^c C = Complete DGA (thymic aplasia); P = partial DGA (thymic hypoplasia or T-cell deficit).

^d See text for details.

is normocalcemic, has mild immune deficiency, and is mildly delayed. However, his cardiac status is still of significant concern despite a shunting procedure for his truncus arteriosus.

Patient 7 (table 1), who has also been reported elsewhere (Greenberg et al. 1986), has a de novo deletion of 10p [46,XX,del(10)(p.13)]. She was initially ascertained because of hypocalcemia and seizures. Although she has no cardiac defect, she does have persistent T-cell dysfunction, suggesting partial DGA. Her other clinical features—such as prominent forehead, epicanthal folds, anteverted nares, and short neck—are consistent with the monosomy 10p13 phenotype.

Patient 18 (table 1) had a de novo deletion of 18q [46,XY,del(18)(q21.33)] (not shown). This patient had features consistent with monosomy 18q phenotype (features such as midface hypoplasia, small ear canals, and widely spaced nipples) and also had tetralogy of Fallot and persistent hypocalcemia. Although his DGA was initially diagnosed based on these findings with T-cell deficits, he subsequently had resolution of his T- and B-cell defects over time. Thus, he probably did not have true DGA but may have had a transient or partial defect.

Patient 26 (table 1) was found to have monosomy 22q11 due to a de novo unbalanced 20q;22q translocation with breakpoints at q13.3 and q11.2, respectively [45,XX,-20,-22,+der(20),t(20;22)(q13.3;q11.2)] (fig. 1). Her clinical findings include downslanting palpebral fissures, broad nasal bridge, broad philtrum, and mild micrognathia in addition to persistent hypocalcemia and T-cell dysfunction.

Patient 27 (table 1) was found to have an interstitial deletion of 22q11.21–11.23 (fig. 2). A discrepancy in length between the two homologues was suspected by

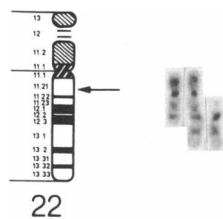


Figure 1 Cytogenetics results of patient 26. An idiogram of chromosome 22 at approximately the 850-band stage of resolution (ISCN 1985) is shown to the left, with an arrow indicating the approximate breakpoint in proximal 22q of the unbalanced 20q;22q translocation. To the right is a G-banded partial metaphase (approximately 500-band stage) from patient 26, with the normal 20 on the left, the normal 22 on the right, and the derivative 20 in the middle. The breakpoint in chromosome 20 appears to be at the telomere of the q arm, with no detectable deletion.

routine chromosome studies. Extensive high-resolution analysis was facilitated by a polymorphism in the short arm which allowed distinction of the maternal and paternal homologues. The paternal homologue had a relatively short stalk region, and in good-quality prometaphase cells the q11.22 subband could be visualized. The maternal homologue had a longer stalk, the distance between the centromere and band q12 was consistently shorter than that in the paternal homologue, and subband q11.22 could never be visualized. The ability to distinguish the two homologues, therefore, increased our confidence that the homologue discrepancy was not simply differential contraction. High-resolution studies on both parents were normal, indicating a maternal de novo deletion. The patient's clinical findings included hypertelorism and low-set ears with truncus arteriosus; type 1, right-sided aortic arch; and ventricular septal defect. He had persistent hypocalcemia. Although his T-cell function studies were normal, he had no demonstrable thymus or parathyroid glands at post-mortem examination at age 1 mo.

Thus, in our experience, 19% of patients with confirmed or suspected DGA had a demonstrable chromosome abnormality, over half of such cases being monosomy 22q11.

Discussion

DGA is a multifactorial development field defect affecting the third and fourth branchial arches. A recent review by Lammer and Opitz (1986) discussed the

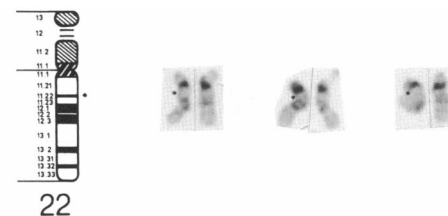


Figure 2 Cytogenetics results of patient 28. An idiogram of chromosome 22 at approximately the 850-band stage of resolution (ISCN 1985) is shown to the left, with a dot marking subband 22q11.22. To the right are G-banded partial metaphases from three different cells, showing the normal 22 to the left of each pair and the deleted 22 to the right of each pair. Subband 22q11.22 is marked by a dot in the normal homologue of each pair and cannot be seen in the deleted homologue, either because the breakpoints flank this subband or because deletion of q11.21 has caused q11.22 to merge with the centromeric region. Note that in all three cells the normal 22 has a relatively short stalk, which was inherited from the father, while the deleted homologue has a longer stalk and was inherited from the mother.

heterogeneity of this condition. On the basis of our prospective study of complete and partial DGA, these defects may be more common than previously thought, as children with partial defects may be missed. Since DGA may not always be an obvious diagnosis, we attempted to ascertain cases by at least two of DGA's three predominant components—namely, conotruncal cardiac defects, persistent hypocalcemia, and thymic or T-cell defects.

Since 1972, a number of chromosome abnormalities have been reported in association with DGA (table 2). The majority of these involve monosomy 22. Although the patients reported by Rosenthal et al. (1972) and DeCicco et al. (1973) had complete monosomy 22, most of the others have unbalanced translocations involving chromosome 22 and various chromosomes (3, 3, 4, 10, 11, 18, 20, 20, and X). The two translocations involving chromosome 3 and the two translocations in-

volving chromosome 20 each occur at different breakpoints. In addition, there is one balanced 2;22 translocation and our patient with an interstitial deletion of 22q11. This brings the number of reported patients with abnormalities of chromosome 22 and DGA to 14.

There have been at least four patients reported with monosomy 10p and features of DGA. A patient of Gencik et al. (1982) had persistent hypercalcemia and absence of a thymic shadow on chest x-ray and was suspected of having DGA. No autopsy was done to document this. Three additional patients with deletion 10p and partial DGA have been reported (Herve et al. 1984; Koenig et al. 1985; Greenberg et al. 1986). Another patient with both monosomy 10p and trisomy 14q also had evidence of partial DGA (Bridgman and Butler 1980). Thus, there are at least five patients with monosomy 10p and evidence of at least partial DGA. A recent patient reported with monosomy 10p had

Table 2
Cytogenetic Abnormalities Reported in Association with DGA

Reference	Cytogenetic Abnormalities
A. Monosomy 22	
Rosenthal et al. 1972	45,XY, - 22
DeCicco et al. 1973	45,XX, - 22
Back et al. 1980	45,XX, - 11, - 22, + der(11),t(11;22)(p15;q11)
de la Chapelle et al. 1981	45, - 20, - 22, + der(20),t(20;22)(q11;q11)
Kelley et al. 1982	45,XX, - 10, - 22, + der(10),t(10;22)(q26;q11)
	45,XX, - 3, - 22, + der(3),t(3;22)(q29;q11)
	46,XY, - 22, + der(20),t(20;22)(q11;q11)
Greenberg et al. 1984	45, - 4, - 22, + der(4),t(4;22)(q35;q11)
Augusseau et al. 1986	46,XX,t(2;22)(q14.1;q11.1)
Bowen et al. 1986	46,XY, - 22, + der(18),t(18;22)(q12;q11)
Faed et al. 1987	45,XX, - 3, - 22, + der(3),t(3;22)(p25;q11)
Schwanitz and Zerres 1987	45,X,t(X;22)(q21;q11)
Current series, patient 26	45,XX, - 20, - 22, + der(20),t(20;22)(q13;q11)
Current series, patient 27	46,XY,del(22)(q11.21;q11.23)
B. Monosomy 10p	
Bridgman and Butler 1980	46,XX, - 10, + der(10),t(10;14)(p14;q22)
Gencik et al. 1982	46,XY,del(10)(p13)
Herve et al. 1984	46,XY,del(10)(p13)
Koenig et al. 1985	46,XY,del(10)(p13)
Greenberg et al. 1986	46,XX,del(10)(p13)
C. Other	
Van den Berghe et al. 1973	46,XY, - 12, + der(1),t(1q;12p)
Townes and White 1978	46,X,dup(8)(q22-qter)
Taylor and Josifek 1981	46,XX,del(5)(p13)
Schinzel 1984	Trisomy 18
Greenberg et al., in press	46,XX,del(17)(p13)

hypocalcemia and a conotruncal cardiac defect, although thymic abnormalities or T-cell dysfunction were not mentioned (Debevec and Brezigar 1986).

In individual cases, at least five other chromosomes have been noted to be associated with DGA. These include trisomy 18 (Schinzel 1984, pp. 628–633), monosomy 12p with trisomy 1q (van den Berghe 1972), monosomy 5p (Taylor and Josifek 1981), partial trisomy 1q (Townes and White 1978), and monosomy 17p13 (Greenberg et al., in press). The last patient is of interest, since one of the patients in the series of Conley et al. (1979) had lissencephaly in addition to DGA, suggesting that DGA could be part of the spectrum of defects in the Miller-Dieker syndrome and monosomy 17p13.

On the basis of our findings, we feel that chromosome analysis should be performed on infants with suspected DGA. Since the clinical diagnosis of DGA may be difficult without postmortem examination, the diagnosis can be suspected on the basis of conotruncal cardiac defects, persistent hypocalcemia, and T-cell dysfunction. However, difficulties in diagnosis may occur, as in our patient with monosomy 18q. In addition, since T-cell function may deteriorate over time, chromosome analysis should be performed as early as possible. Clinically, there were no discernable characteristics to distinguish the infants with monosomy 22q11 from DGA infants with normal chromosomes. Since several of the patients reported with translocations had a positive family history of DGA, familial cases may have a greater likelihood of having an unbalanced translocation. However, the majority of DGA patients with translocations were sporadic. Although monosomy 22q11 has become the most frequent chromosome abnormality associated with DGA, it is not common and a variety of other chromosomes may be involved.

In approximately 81% of the cases that we studied there were no rearrangements involving chromosome 22. We were able to detect only one interstitial deletion of chromosome 22. We are aware of only one other case of DGA associated with an interstitial deletion of chromosome 22 (J. Mascarello, personal communication). Such interstitial deletions of 22q11 are difficult to detect even with high-resolution cytogenetic techniques, and its cost-effectiveness at this time is uncertain. Good-quality routine chromosome studies may lead to a suspicion of interstitial deletion on the basis of homologue length discrepancy, which could then be confirmed by high-resolution analysis. The availability of DNA probes from chromosome 22 may help to elucidate this further. Recently, the anonymous poly-

morphic probe D22S9 has been shown to map proximal to the 22q11 breakpoint in four different DGA translocation cases (Fibison and Emanuel 1987). This suggests it may be within or close to the critical region for DGA.

Acknowledgments

This work was supported in part by Biomedical Research Support grant RR05-425-23, the Texas Department of Health, and the Robert J. Kleberg Center for Human Genetics. We thank numerous individuals who assisted with ascertainment and evaluation and without whose cooperation these studies would have been impossible. These individuals include members of the Divisions of Neonatology, Pediatric Cardiology, Pediatric Endocrinology, and Pediatric Allergy and Immunology and the Pediatric House Staff of the Department of Pediatrics, Baylor College of Medicine, and the Department of Pathology, Texas Children's Hospital. The Baylor Genetics Service (Drs. A. L. Beaudet, C. T. Caskey, J. F. Hejtmanck, R. L. Nussbaum, and V. M. Riccardi) assisted with the genetic evaluations. We give special thanks to Dr. William Shearer for T-cell studies, to Dr. John Kirkland for PTH studies, to Dr. Celine Guerra for evaluation of patient J. C., to Dr. Jeffrey Chinsky for assistance with patient S.S., and to Gayle Wakefield and Sylvia Perez for manuscript preparation.

References

- Augusseau, S., S. Jouk, P. Jalbert, and M. Prieur. 1986. DiGeorge syndrome and 22q11 rearrangements. *Hum. Genet.* 74:206.
- Back, E., R. Stier, N. Bohsen, A. Adlung, and H. Hameister. 1980. Partial monosomy 22 pter-q11 in a newborn with the clinical features of trisomy 13 syndrome. *Ann. Genet.* 23:244–248.
- Bowen, P., H. Pabst, D. Berry, R. Collins-Nakai, and J. J. Hoo. 1986. Thymic deficiency in an infant with a chromosome t(18;22)(q12.2;p11.2) pat arrangement. *Clin. Genet.* 29:174–177.
- Bridgman, G., and L. J. Butler. 1980. A child trisomic for the distal part of chromosome 14q. *Arch. Dis. Child.* 55:474–477.
- Conley, M. E., J. B. Beckwith, J. F. K. Mancier, and L. Tenckhoff. 1979. The spectrum of the DiGeorge syndrome. *J. Pediatr.* 94:883–890.
- Debevec, M., and A. Brezigar. 1986. Phenotype of monosomy and trisomy 10p. 7th International Congress of Human Genetics (Berlin), Abstracts 1:74.
- DeCicco, F., M. W. Steele, S. Pan, and S. C. Park. 1973. Monosomy of chromosome no. 22: a case report. *J. Pediatr.* 83:836–838.
- de la Chapelle, A., R. Herva, M. Koivisto, and O. Aula. 1981. A deletion in chromosome 22 can cause DiGeorge syndrome. *Hum. Genet.* 57:253–256.

- DiGeorge, A. M. 1965. Discussions on a new concept of the cellular basis of immunology. *J. Pediatr.* **67**:907.
- Faed, M. J. W., J. Robertson, J. Swanson Beck, J. I. Cater, B. Bose, and M. M. Madlom. 1987. Features of DiGeorge syndrome in a child with 45,XX,-3,-22,+der(3),t(3;22)(p25;q11). *J. Med. Genet.* **24**:225-234.
- Fibison, W. J., and B. Emanuel. 1987. Molecular mapping in DiGeorge syndrome. *Am. J. Hum. Genet.* **41**:A119.
- Gencik, A., U. Bronniman, R. Tobler, and P. Auf der Maur. 1982. Partial monosomy of chromosome 10 short arms. *J. Med. Genet.* **20**:107-111.
- Greenberg, F., K. B. Courtney, R. Wessels, J. Huhta, R. J. Carpenter, and D. H. Ledbetter. Prenatal diagnosis of deletion 17p13 associated with DiGeorge anomaly. *Am. J. Med. Genet.* (in press).
- Greenberg, F., W. E. Crowder, V. Paschall, J. Colon-Linares, B. Lubianski, and D. H. Ledbetter. 1984. Familial DiGeorge syndrome and associated partial monosomy of chromosome 22. *Hum. Genet.* **65**:317-319.
- Greenberg, F., C. Valdes, H. M. Rosenblatt, J. L. Kirkland, and D. H. Ledbetter. 1986. Hypoparathyroidism and T-cell immune defect in a patient with 10p deletion syndrome. *J. Pediatr.* **109**:489-492.
- Harnden, D. G., and H. P. Klinger eds. 1985. An international system for human cytogenetic nomenclature. (published in collaboration with Cytogenet. Cell Gene. Karger, Basel).
- Herve, J., J. F. Warnet, E. Jeaneau-Bellego, M. F. Portnoi, J. L. Taillemitte, and F. Herve. 1984. Monosomie partielle du bras court d'un chromosome 10, associee a un syndrome de Rieger at a un deficit immunitaire partiel, type DiGeorge. *Ann. Pediatr.* **31**:77-80.
- Kelley, R. I., E. H. Zackai, B. S. Emanuel, M. Kistenmacher, F. Greenberg, and H. H. Punnett. 1982. The association of the DiGeorge anomaly with partial monosomy of chromosome 22. *J. Pediatr.* **101**:197-200.
- Koenig, R., E. Kessel, and W. Schoenberger. 1985. Partial monosomy 10p syndrome. *Ann. Genet.* **28**:173-176.
- Lammer, E. J., and J. M. Opitz. 1986. The DiGeorge anomaly as a developmental field defect. *Am. J. Med. Genet.* [Suppl.] **2**:113-127.
- Ledbetter, D. H., J. T. Mascarello, V. M. Riccardi, V. D. Harper, S. D. Airhart, and R. J. Strobel. 1982. Chromosome 15 abnormalities and the Prader-Willi syndrome: a follow-up report of 40 cases. *Am. J. Hum. Genet.* **34**:278-285.
- Mallette, L. E., S. N. Tuma, R. E. Berger, and S. L. Kirkland. 1982. Radioimmunoassay for the middle region of human parathyroid hormone using an homologous antiserum with a carboxy-terminal fragment of bovine parathyroid hormone as radioligand. *J. Clin. Endocrinol. Metab.* **54**:1017-1024.
- Rosenthal, I. M., M. Bocian, and E. Krmpotik. 1972. Multiple anomalies including thymic aplasia associated with monosomy 22. *Pediatr. Res.* **6**:358.
- Schinzel, A. 1984. Catalogue of unbalanced chromosome aberrations in man. Walter de Gruyter, New York.
- Schwanitz, G., and K. Zerres. 1987. Partial monosomy 22 as a result of an X/22 translocation in a newborn with DiGeorge syndrome. *Ann. Genet.* **30**:80-84.
- Taylor, M. J., and K. Josifek. 1981. Multiple congenital anomalies, thymic dysplasia, severe congenital heart disease, and oligosyndactyly, with a deletion of the short arm of chromosome 5. *Am. J. Med. Genet.* **9**:5-11.
- Townes, P. L., and M. R. White. 1978. Inherited partial trisomy 8q (22-qter). *Am. J. Dis. Child.* **132**:498-501.
- van den Berghe, H., M. van Eygen, J. P. Fryns, W. Tanghe, and H. Verresen. 1972. Partial trisomy 1, karyotype 46,XY,12,-t(1q,12p)+. *Humangenetik* **18**:225-230.
- Yunis, J. J. 1976. High resolution of human chromosomes. *Science* **191**:1268-1270.